

Received: 2017.05.17
Accepted: 2017.07.10
Published: 2017.08.19

Preoperative Halo-Gravity Traction for Severe Thoracic Kyphoscoliosis Patients from Tibet: Radiographic Correction, Pulmonary Function Improvement, Nursing, and Complications

Authors' Contribution:

Study Design A
Data Collection B
Statistical Analysis C
Data Interpretation D
Manuscript Preparation E
Literature Search F
Funds Collection G

AB 1 Xiaojin Li*
CE 2 Liwen Zeng*
CDF 3 Xiaoyin Li
EF 1 Xuexia Chen
E 1 Caixia Ke

1 Nursing Department, The Eastern Hospital of the First Affiliated Hospital, Sun Yat-sen University, Guangzhou, Guangdong, P.R. China
2 Department of Spine Surgery, The Eastern Hospital of the First Affiliated Hospital, Sun Yat-sen University, Guangzhou, Guangdong, P.R. China
3 Department of Interventional Radiology, The First Affiliated Hospital of Sun Yat-sen University, Guangzhou, Guangdong, P.R. China

* Xiaojin Li and Liwen Zeng contributed equally to this work as co-first authors

Corresponding Author: Xiaojin Li, e-mail: stewieiwln@163.com
Source of support: Departmental sources

Background: This study investigated the outcomes of preoperative HGT as an adjunct treatment for severe thoracic kyphoscoliosis, its role in radiographic correction, and pulmonary function improvement, together with nursing strategy and incidence of complications.





Material/Methods: Eleven patients with a mean age of 18.8 years were retrospectively reviewed. Inclusion criteria were: patients with severe kyphoscoliosis (coronal Cobb angle and kyphosis angle $\geq 80^\circ$); duration of HGT ≥ 8 weeks; patients undergoing HGT for at least 12 h per day; traction weight no less than 40% of body weight; and patients not receiving physical therapies. All patients underwent respiratory training.

Results: The major coronal curve scoliosis averaged $114.00 \pm 24.43^\circ$ and was reduced to $80.55 \pm 17.98^\circ$ after HGT. The major kyphosis was $103.91 \pm 18.95^\circ$ and was reduced to $80.55 \pm 17.98^\circ$. Significantly improved percent-predicted values for FVC was found after HGT ($p=0.014$), and significantly increased forced expiratory volume in 1 s (FEV1%) was also observed ($p<0.001$), with significantly improved percent-predicted values for PEF ($p=0.003$) after HGT.

Conclusions: Our data reveal that preoperative HGT can be performed safely, and can help achieve excellent curve correction in both the coronal and sagittal planes, together with improved respiratory function and no severe complications in patients with severe thoracic kyphoscoliosis.

MeSH Keywords: **Respiratory Function Tests • Scoliosis • X-Ray Film**

Full-text PDF: <https://www.medscimonit.com/abstract/index/idArt/905358>

 2979  1  2  35



Background

The surgical treatment of severe spinal deformities remains a great challenge, with high risks of morbidity and mortality [1]. To minimize these risks and complications, especially neurological complications, numerous authors advocated halo-gravity traction for the reduction of stiff curves prior to the operation and to reduce the use of acute corrective maneuvers [2].

Previous studies demonstrated that preoperative HGT can obtain 15% to 38% correction in scoliosis and 17% to 35% correction in kyphosis [2], and some reported significant improvement in pulmonary function with HGT [3]. Despite these observations, there are no published studies investigating the outcome of HGT in severe spinal deformity patients from Tibet, who usually present severe thoracic kyphoscoliosis. Therefore, the aim of this study was to investigate the outcomes of preoperative HGT as an adjunct treatment for severe thoracic kyphoscoliosis, its role in radiographic correction and pulmonary function improvement, together with nursing strategy and incidence of complications.

Material and Methods

This prospective study was approved by the Ethics Committee of the First Affiliated Hospital of Sun Yat-sen University. From Sep 2014 to Apr 2017, patients who met the following inclusion criteria were recruited in the study: (1) patients with severe kyphoscoliosis (coronal Cobb angle and kyphosis angle $\geq 80^\circ$); (2) duration of HGT ≥ 8 weeks; (3) patients undergoing HGT for at least 12 h per day; (4) traction weight no less than 40% of body weight; (5) patients not receiving physical therapy. Exclusion criteria were: (1) patients who had prior spine surgery; (2) patients with revision surgery or anterior release; (3) patients with neurologic deficit. Informed consents were obtained from patients or their parents before recruitment. Demographic data included age, sex, standing height, body weight, diagnosis, duration of traction, and maximum weight of traction. Body mass index (BMI) was calculated by dividing body weight (kg) by standing height squared (m^2).

Halo-gravity traction protocols

Local anesthesia was prescribed to each patient before the application of the halo ring with 6 to 8 pins. Pins were tightened to 6–8 Newton-meters (N·m) of torque, depending on the skull size and bone density. The pins are not typically tightened after 24 to 48 h unless there is evidence of loosening. The initial traction weight was 4 kg. If there were no traction-related symptoms, the traction weight was added by 2 kg per day and finally reached a target weight (about 50% of the body weight, depending on patient tolerance to HGT). The patients

were instructed to undergo HGT more than 12 h per day, and each patient received at least 1 h of sunlight exposure outside during daytime. Daily cranial nerve and upper/lower extremity neurological examinations were performed every 8 h at initial placement and after each increase in traction weight. If complications such as transient nystagmus and upper-extremity numbness occurred, the traction weight was reduced to the previous weight. The traction duration was determined by the improvement of the major coronal curve, global kyphosis, pulmonary function, and neurological function. In-traction X-ray films were obtained every 4 weeks until a plateau of correction was reached [4].

To achieve normal exercise level, the patients were asked to walk about 6000 steps tracked by a pedometer while in traction, as it is easy to walk along with a wheelchair, and this can reduce the potential for disuse osteoporosis and general de-conditioning that may occur if they sit in the halo-gravity wheelchair or stand by the wheelchair for prolonged periods of time.

Radiographical measurements

The main curve of scoliosis and kyphosis were measured on pre-traction and post-traction standing radiographs. The major scoliosis and kyphosis (Cobb angle) was extracted from biplanar, full-standing, standard radiographs. The initial magnitude of major coronal and sagittal curve were measured on standing posterior-anterior (PA) and lateral radiographs of the whole spine. Kyphosis was measured between the maximally tilted upper and lower-end vertebrae using the standard Cobb's method. The correction rates for both coronal and sagittal plane were calculated as follows [5]:

$$\text{Correction rate} = \frac{\text{preHGT angle} - \text{postHGT angle}}{\text{preHGT angle}} \times 100\%$$

All measurements were performed using Surgimap software (version 2.0.8; New York, USA).

Pulmonary function tests

Pre-traction pulmonary function test (PFT) and repeated PFT were performed until the completion of traction. Pulmonary function was measured using a Cardio Touch 3000S (Bionet Co., Ltd., South Korea) while subjects were seated in a chair. The pulmonary functions measured were: forced vital capacity (FVC) [3], forced expiratory volume in one second (FEV1), FEV1/FVC, peak expiratory flow (PEF), and vital capacity (VC). FVC, FEV1, and FEV1/FVC are used to determine obstructive and restrictive lung diseases, and PEF is used to determine airway resistance. PFTs were performed before HGT (defined as pre-FVC%) and post-HGT (defined as post-HGT-FVC%). To ensure accurate and reliable data, the pulmonary functions were

Table 1. The demographic and curve characteristics of the patients.

No	Gender	Age (years)	Height (cm)	Weight (kg)	Lenke	Apical vertebral	Apical rotation	major scoliosis	Cobb angle (°)	Kyphosis T5–12 (°)	Risser sign	Traction weight (Kg)	Traction time (week)
1	F	17	150	38	1C+	T7/8	4	T5–10	135	110	3	20	8
2	M	36	163	59	1B+	T5/6	4	T1–8	105	110	5	25	9
3	M	13	132	28	1A+	T10/11	3	T7–L1	115	95	2	16	10
4	F	23	145	34	1A+	T4/5	3	T3–8	81	83	5	18	10
5	F	24	146	40	1C+	T8/9	4	T5–12	140	145	5	19	12
6	M	18	170	67	1A+	T9/10	3	T7–L1	120	100	4	29	11
7	M	11	110	17	1B+	T9/10	3	T6–12	125	110	2	10	12
8	F	9	112	18	1A+	T8/9	3	T5–L1	150	125	1	9	9
9	F	14	146	36	1C+	T8/9	2	T7–12	81	94	3	18	8
10	F	24	145	38	1A+	T7/8	2	T5–12	81	79	4	18	8
11	F	18	138	38	1C+	T8/9	3	T5–12	121	90	4	18	8

measured in triplicate with understanding and cooperation of the subjects, and the highest values were selected. According to the American Thoracic Society's guidelines for the severity of pulmonary impairment, 'no' pulmonary impairment was considered when the FVC% was >80% of the predicted value, 'mild' when the FVC% was ≤80% but >65%, 'moderate' when the FVC% was ≤65% but >50%, and 'severe' when the FVC% was ≤50% [6].

Respiratory function training

Feedback respiration exercise was performed as respiratory function training. The patient was sitting straight and holding a handle with a respiration pocket, with a mouth piece in the mouth and staring at the connector. The therapists pushed the start button of the connector. When the patients see the orange gradation of the body reaching the "in" mark, they inhale, and when it goes to "out" mark, they exhale. If there is a beeping sound with a green light when the orange mark is on "in" or "out", that means normal feedback respiration exercise. Enough explanation was given to subjects before doing the exercise to ensure they understand the method of this exercise. It was conducted within a certain range to prevent hypoxemia during inhaling and exhaling at maximum level [7].

Prevention of infection at pin sites

We disinfected the pin sites with iodine 3 times a day, and keep them dry. If there was any sign of inflammation or secretion, neel gauze was used, or oral antibiotic if possible.

Statistical analysis

All data were analyzed using SPSS version 19.0 (SPSS, Chicago, IL). Patient demographics were analyzed using descriptive statistics. Data are presented as mean ±SD. A paired *t* test was used to compare the differences between pre-HGT and post-HGT Cobb angle, as well as PFT. Statistical significance was set at *P*<0.05.

Results

Demographics

A total of 11 patients (4 males, 7 females) undergoing HGT treatment were recruited in the study. The average age was 18.82±7.65 years, height 141.10±19.31 cm, body weight 37.30±15.77 kg, and BMI 17.87±2.95. The pre-traction height was 141.10±19.31 (110–170) cm and the height after traction was 145.09±16.68 (116–173) cm. The increase averaged 3.55±2.25 cm (0–7 cm; *p*<0.001). The pre-traction body weight was 37.55±14.98 (17–67) kg preoperatively and 41.55±14.40 (21–59) kg after traction. The average increase was 4.00±2.83 kg (0–9 kg; *p*<0.001). The diagnosis included 8 idiopathic scoliosis, and 3 congenital scoliosis. The mean traction weight was 49.95±5.17% (42.4–57.1%) of patient body weight. The average traction duration was 9.55±1.57 weeks (8–12 weeks) (Table 1). Typical cases are shown in Figures 1 and 2.

Radiological

The major coronal curve scoliosis was high thoracic (C7–T4) in 1 patient (9.1%) and the thoracic region (T5–T10) in 10

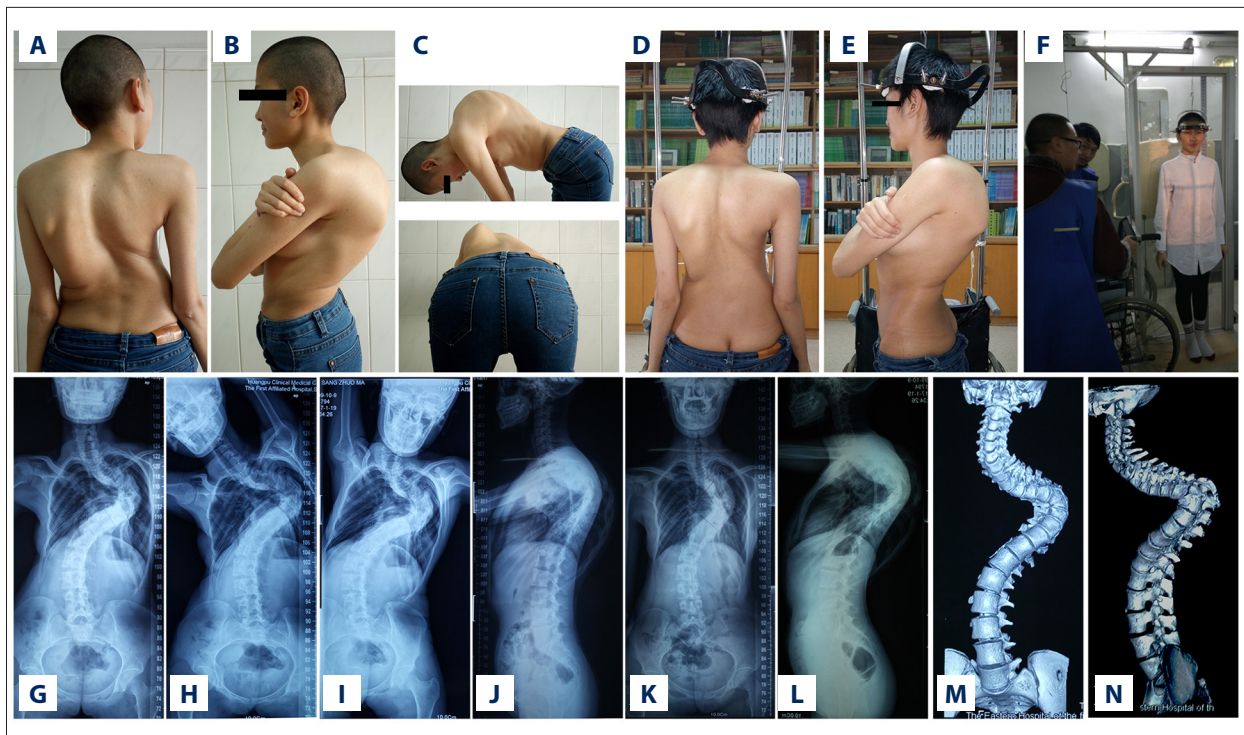


Figure 1. A 17-year-old female with severe thoracic kyphoscoliosis. (A–C) General appearance of the patients; (D, E) Clinical images after HGT show that appearance had improved significantly compared to that observed before HGT; (F) An illustration of X-ray examination under traction; (G–J) The initial Cobb angle was 135° and thoracic kyphosis was 110°; (K, L) The major curve measured 85° and thoracic kyphosis measured 78° after HGT; (M, N) Three-dimensional rebuilding of the whole spine pre-HGT.

patients (90.1%). Preoperatively, the apical vertebral rotation was $3.09 \pm 0.70^\circ$. The pre-traction major scoliosis measured $114.00 \pm 24.43^\circ$ ($81\text{--}150^\circ$). Scoliosis on the bending radiographs was corrected to $100.91 \pm 22.60^\circ$ ($72\text{--}140^\circ$) with a bending-flexibility of $11.25 \pm 7.56\%$ ($2\text{--}32^\circ$), and it was significantly different from the neutral radiographs ($p=0.001$). The degree of scoliosis on final-HGT radiographs was $80.55 \pm 17.98^\circ$ ($53\text{--}113^\circ$) with a traction flexibility of $28.63 \pm 10.41\%$ ($9\text{--}50\%$), which was significantly different from the neutral radiographs ($p<0.001$) and from the values achieved for bending-flexibility ($p=0.001$). With increasing age and scoliosis, the degree of pre-traction coronal curve was not significantly correlated with the correction rate of traction ($p=.287$, $r=0.353$, $n=11$), and age was not significantly correlated with the correction rate of traction ($p=.424$, $r=-0.269$, $n=11$).

The major kyphosis was located in the high thoracic region (C7–T4) in 1 patient (9.1%) and in the thoracic region (T5–T10) in 10 patients (90.1%). The pre-traction kyphosis was $103.91 \pm 18.95^\circ$ ($81\text{--}145^\circ$) on neutral radiographs and $80.55 \pm 17.98^\circ$ ($53\text{--}113^\circ$) on the final-HGT radiographs. The improvement was $23.45 \pm 12.27^\circ$ ($10\text{--}45^\circ$, $p<0.001$). The mean correction rates for kyphosis were $22.19 \pm 10.63\%$ ($9.1\text{--}43\%$).

Pulmonary function

We analyzed the effect of HGT on pulmonary function in terms of FVC%, FEV1%, FEV1/FVC, and PEF% changes. The pre-FVC% in 11 patients was $60.94 \pm 13.16\%$ ($46\text{--}92.4\%$; $n=11$). The pre-FVC% was not correlated with the extent of the scoliosis on the neutral radiographs ($p=0.66$, $r=0.15$, $n=11$). The post-HGT-FVC% was $67.67 \pm 13.72\%$ ($47.5\text{--}94.6\%$; $n=11$). The difference averaged $6.73 \pm 7.47\%$ (-1.5 to 22.9% , $n=11$) and was significant ($p=0.014$). The pre-FEV1% in 11 patients was $49.73 \pm 15.44\%$ ($26\text{--}81.6\%$; $n=11$). The pre-FEV1% was not correlated with the extent of scoliosis on the neutral radiographs ($p=0.72$, $r=-0.122$, $n=11$). The post-HGT-FVC% was $55.79 \pm 15.60\%$ ($29.7\text{--}83.7\%$; $n=11$). The difference averaged $6.06 \pm 3.96\%$ (0.6 to 14.6% , $n=11$) and was significant ($p<0.001$). The pre-FEV1/FVC in 11 patients was $83.78 \pm 8.25\%$ ($67.7\text{--}93.1\%$; $n=11$). The pre-FEV1/FVC was not correlated with the extent of the scoliosis on the neutral radiographs ($p=0.726$, $r=0.12$, $n=11$). The post-HGT-FEV1/FVC was $85.49 \pm 7.29\%$ ($69.7\text{--}95\%$; $n=11$). The difference averaged $1.71 \pm 2.79\%$ (-3.5 to 6.3% , $n=11$) and was not significant ($p=0.068$). The pre-PEF% in 11 patients was $50.74 \pm 20.14\%$ ($27\text{--}97\%$; $n=11$). The post-HGT-PEF% was not correlated with the extent of the scoliosis on the neutral radiographs ($p=0.567$, $r=0.194$, $n=11$). The post-HGT-FVC% was

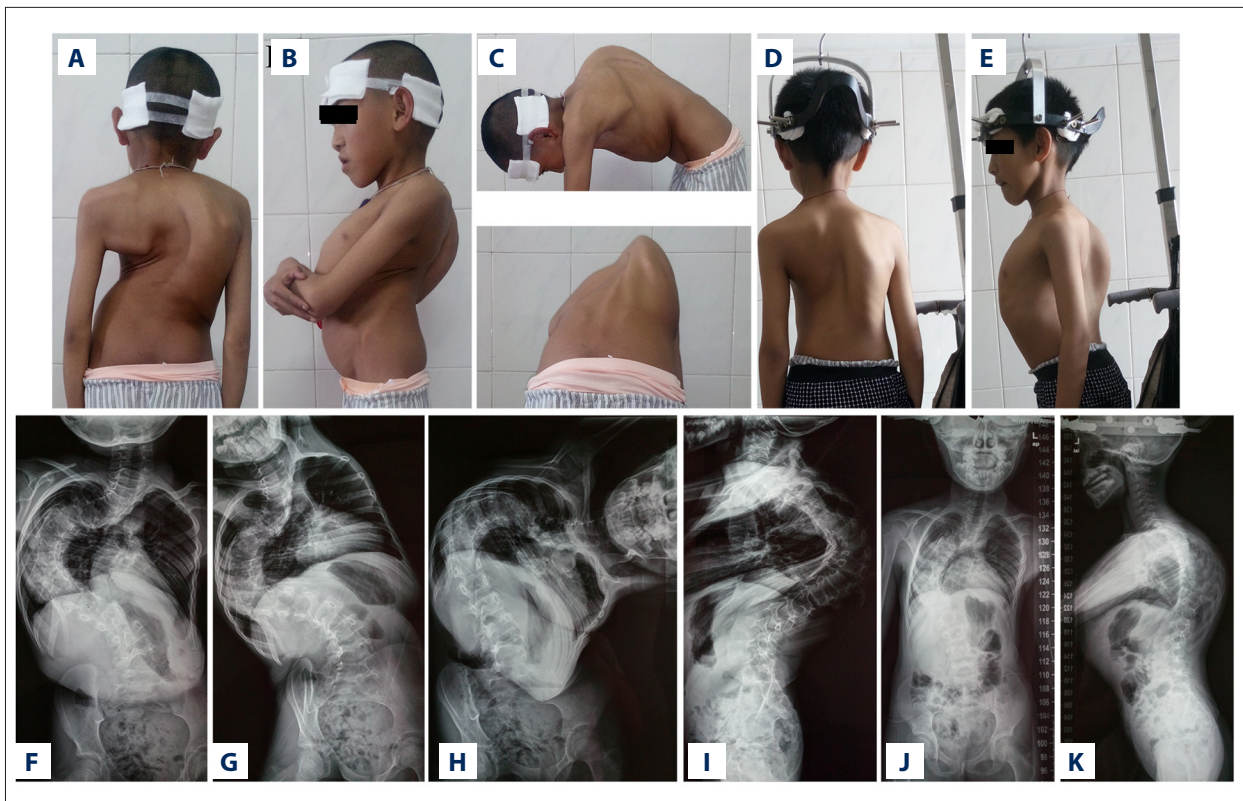


Figure 2. A 9-year-old female with severe thoracic kyphoscoliosis. (A–C) General appearance of the patients; (D, E) Clinical images at after HGT show that appearance had improved significantly compared to that observed before HGT; (F–I) The initial Cobb angle was 150° and thoracic kyphosis was 125°; (J, K) The major curve measured 85° and thoracic kyphosis measured 80° after HGT.

58.89±21.28% (27.6–107.7%; $n=11$). The difference averaged 8.16±7.08% (0.6 to 23.2%, $n=11$) and was significant ($p=0.003$).

Although a previous study showed that HGT-FVC% largely depended on the pre-traction-FVC%, but we did not obtain a similar result, possibly due to the large age span, relatively small sample size, and development stage of lung function, which can influence the analysis results. It is clear that pulmonary function improved after traction treatment.

Complications

In terms of halo-related complications, 2 patients experienced nausea and vomiting that resolved 1 week after halo placement, and 1 patient experienced dizziness that resolved 5 days after halo placement. There was no halo pin loosening, pin site infection, nystagmus, paraplegia, cranial nerve injury, hypoglossal nerve injury, or any other kind of neurological complication. Patients often had cervical discomfort and trapezial soreness due to the traction weight being applied to the neck musculatures; however, no psychological intolerance was seen. Normally, a light muscle relaxant and massage was provided for this kind of complaint.

Discussion

Severe thoracic kyphoscoliosis is usually complicated with cardio-pulmonary impairment which results in significantly increased morbidity and mortality compared with pure scoliosis. Neurologic compromise due to acute corrective maneuvers, vertebral column resections, and spinal osteotomy present great challenges to spine surgeons. HGT was developed by Stagnara [8] as a preoperative treatment for patients with severe scoliosis. The primary goal of HGT is to avoid major neurological risk, to improve pulmonary function, and to obtain correction of severe scoliosis. It can improve preoperative nutritional status and pulmonary function. It provides a slow and gradual correction while the patients are awake, making the continuous monitoring of neurological status possible and thereby reducing the risk of spinal cord injury that might occur from rapid correction [9]. Therefore, HGT is a safe method for gradual correction of severe scoliosis [10,11].

Regarding the deformity correction of HGT, most previous studies detected significant correction. Garabekyan et al. [2] observed a 38% reduction in the main coronal curve and a 25% correction in the sagittal plane with HGT applied to a

pediatric population. Bogunovic et al. [12] showed a 35% correction of both the coronal and sagittal curve with HGT, whereas Sink et al. [13] also showed a 35% improvement in curve magnitude with HGT in pediatric patients. However, Koller et al. [14] reported that HGT did not significantly improve severe curves without prior anterior or posterior surgical release. Sponseller et al. [3] found HGT did not increase the main coronal curve or sagittal plane correction in a multi-center, retrospective, nonrandomized comparison study. The present study recruited both adult and pediatric patients, indicating that with the help of HGT, the correction rate after HGT was $28.63 \pm 10.41\%$ in the coronal plane and $22.19 \pm 10.63\%$ in the sagittal plane. Moreover, the spinal deformity was more rigid, as patients have severe thoracic kyphoscoliosis, and the initial Cobb angle averaged $114.00 \pm 24.43^\circ$ in our study, which is much larger than in previous reports.

Kyphoscoliosis damages respiratory system compliance due to decreased lung capacity caused by deformation of the thoracic cage by mechanical dynamics [15]. Severe kyphoscoliosis has a poor prognosis, accounting for up to 5% of chronic ventilator failures in adulthood [16], with high mortality [17]. If scoliosis is $>100^\circ$, respiratory system compliance is decreased to levels comparable to adult respiratory distress syndrome. HGT has been recommended for kyphoscoliosis patients whose pulmonary function might be lethal [18]. However, the current literature lacks reproducible data regarding the impact of HGT on PFT [19]. Nepple et al. [20] reported the FVC% improved from 31% to 47% after 4 weeks of HGT. Wazeka et al. [21] reported that only 3 of 21 scoliosis patients with mean age of 11 years showed PFT improvement after HGT. In our sample, most of the patients had moderate or severe pulmonary impairment before HGT, and our results showed that a significant increase of $6.73 \pm 7.47\%$ in the FVC% was achieved after HGT, similar to previous reported data on pediatric and adolescent populations [22]. In summary, preop-HGT is a useful tool to improve a patient's pulmonary condition. In our study, a feedback breathing exercise was also used in our patients, which can obtain inhalation flow or inhalation pressure set as aims using resistant respiration during training for improvements of respiratory function [23]; it helps to improve endurance and muscle strength by applying load to inhalation synergist and diaphragm [24]. Feedback breathing exercise can significantly increase tidal volume, inspiratory reserve volume, aspiratory capacity, and breathing capacity [25].

Currently, there is no consensus on the optimal duration of traction. Most previous studies reported the duration of HGT varied from 2 to 12 weeks [9]. The length of traction depended on the response of the various curves to the traction. Other important considerations include the patient's overall systemic, respiratory, nutritional, and social conditions. Extended courses of traction (8–12 weeks) were often based on maximizing

pulmonary function and nutritional optimization as opposed to being purely based on radiographic improvement.

HGT was not without inherent risks; complications are common, with the prevalence of 22% [26]. The most common complications were pin loosening, and superficial and deep pin tract infections [26]. Pin tract infections can be avoided by cleaning the site regularly, removing the pin and debriding the site if necessary [27]. Several authors noted deep intracranial lesions related to halo-pins [28], in addition to cranial osteomyelitis, and the intradural and extradural infections also associated with halo-pins [29]. In our study, we used strict protocols, including daily pin checks, re-tightening of pins, and prudent hygiene to avoid complications.

Neurological function complications in use of HGT for severe scoliosis have been reported. The most common cause of neurological injury was excessive traction or traction applied too rapidly. Tindall et al. [30] reported traction-related complications as high as 53%, with 31% suffering from transient HGT-related neurologic compromise. Wilkins et al. [31] reported the cranial nerve complication rate was 8.6% in 70 patients with skeletal traction. Ginsburgh et al. [32] reported a hypoglossal nerve injury caused by HGT with 40% of body weight. A previous study provided neurologic improvement by preop-HGT in patients with severe kyphoscoliosis and progressive neurologic deficits [14]. However, no major HGT-related neurological injury complications occurred in the series by Rinella [22] or in ours.

Several authors describe loss of cervical lordosis in HGT, often with associated degenerative changes of the cervical apophyseal joints, even with the incidence of 47.4% in patients with halo-pelvic distraction [33], perhaps due to high traction forces or prolonged traction times. High traction forces are also related to avascular necrosis of the proximal tip of the dens. In our series, the cervical spine on all final radiographs could not be completely visualized; therefore, assessment of cervical degeneration was not performed.

Osteoporosis was also noted by several authors in patients treated with halo-pelvic traction due to prolonged immobilization [5]. Disuse osteoporosis can occur with complete immobilization during halo-femoral traction, and 76% of patients sustained fractures after completing immobilization [34]. Abu et al. [35] provided further evidence by showing histological evidence of "low-turnover" osteoporosis in patients with scoliosis treated with halo traction for an average of 80 days. These studies showed that traction across the spine or extremities for extended periods leads to the development of local disuse osteoporosis. In contrast, there was no need for immobilization when using HGT, and osteoporosis can be avoided [5].

Several limitations of the present study should be addressed. The first limitation is the relatively small sample size. The second limitation is the lack of post-operative data, since we just focused on the preoperative HGT for severe thoracic kyphoscoliosis not combined with surgery. Another limitation includes the heterogenous characteristics of patients managed with halo-gravity traction. Some patients were unable to perform pulmonary function tests with good effort and others had greater restriction in pulmonary function for a given level of curve magnitude. In addition, pulmonary function tests or SPO₂ do not fully reflect the true situation of the human body, as they can run or climb stairs without restriction. We did not detect

a statistically significant trend in the various parameters studied with duration of traction.

Conclusions

Our data reveal that preoperative HGT can be performed safely, and can help achieve excellent curve correction in both the coronal and sagittal planes, together with improved respiratory function and no severe complications in patients with severe thoracic kyphoscoliosis.

References:

1. Newton PO, Faro FD, Gologly S et al: Results of preoperative pulmonary function testing of adolescents with idiopathic scoliosis. A study of six hundred and thirty-one patients. *J Bone Joint Surg Am*, 2005; 87(9): 1937–46
2. Garabekyan T, Hosseinzadeh P, Iwinski HJ et al: The results of preoperative halo-gravity traction in children with severe spinal deformity. *J Pediatr Orthop B*, 2014; 23(1): 1–5
3. Sponseller PD, Takenaga RK, Newton P et al: The use of traction in the treatment of severe spinal deformity. *Spine*, 2008; 33(21): 2305–9
4. Bouchoucha S, Khelifi A, Saied W et al: Progressive correction of severe spinal deformities with halo-gravity traction. *Acta Orthop Belg*, 2011; 77(4): 529–34
5. Han X, Sun W, Qiu Y et al: Halo gravity traction is associated with reduced bone mineral density of patients with severe kyphoscoliosis. *Biomed Res Int*, 2016; 2016: 8056273
6. Quanjer PH, Tammeling GJ, Cotes JE et al: Lung volumes and forced ventilatory flows. Report Working Party Standardization of Lung Function Tests, European Community for Steel and Coal. Official Statement of the European Respiratory Society. *Eur Respir J Suppl*, 1993; 16: 5–40
7. Kang JI, Jeong DK, Choi H: The effects of breathing exercise types on respiratory muscle activity and body function in patients with mild chronic obstructive pulmonary disease. *J Phys Ther Sci*, 2016; 28(2): 500–5
8. Stagnara P: [Cranial traction using the "Halo" of Rancho Los Amigos]. *Rev Chir Orthop Reparatrice Appar Mot*, 1971; 57(4): 287–300 [in French]
9. Yang C, Wang H, Zheng Z et al: Halo-gravity traction in the treatment of severe spinal deformity: A systematic review and meta-analysis. *Eur Spine J*, 2017; 26(7): 1810–16
10. Bao H, Yan P, Bao M et al: Halo-gravity traction combined with assisted ventilation: an effective pre-operative management for severe adult scoliosis complicated with respiratory dysfunction. *Eur Spine J*, 2016; 25(8): 2416–2422.
11. Nickel VL, Perry J, Garrett A, Heppenstall M: The halo. A spinal skeletal traction fixation device. *J Bone Joint Surg Am*, 1968; 50(7): 1400–9
12. Bogunovic L, Lenke LG, Bridwell KH, Luhmann SJ: Preoperative halo-gravity traction for severe pediatric spinal deformity: Complications, radiographic correction and changes in pulmonary function. *Spine Deform*, 2013; 1(1): 33–39
13. Sink EL, Karol LA, Sanders J et al: Efficacy of perioperative halo-gravity traction in the treatment of severe scoliosis in children. *J Pediatr Orthop*, 2001; 21(4): 519–24
14. Koller H, Zenner J, Gajic V et al: The impact of halo-gravity traction on curve rigidity and pulmonary function in the treatment of severe and rigid scoliosis and kyphoscoliosis: A clinical study and narrative review of the literature. *Eur Spine J*, 2012; 21(3): 514–29
15. Gonzalez C, Ferris G, Diaz J et al: Kyphoscoliotic ventilatory insufficiency: Effects of long-term intermittent positive-pressure ventilation. *Chest*, 2003; 124(3): 857–62
16. Smiljanic I, Kovac V, Cimic M: Changes in pulmonary functional parameters after surgical treatment of idiopathic scoliosis. *Coll Antropol*, 2009; 33(Suppl. 2): 145–52
17. Vitale MG, Matsumoto H, Bye MR et al: A retrospective cohort study of pulmonary function, radiographic measures, and quality of life in children with congenital scoliosis: An evaluation of patient outcomes after early spinal fusion. *Spine*, 2008; 33(11): 1242–49
18. Winter RB, Lonstein JE: The Moe Maximal Correction Test to determine true curve flexibility: A historical note with current application. *Spine*, 2010; 35(18): 1733–35
19. Qiu Y, Liu Z, Zhu F et al: Comparison of effectiveness of Halo-femoral traction after anterior spinal release in severe idiopathic and congenital scoliosis: A retrospective study. *J Orthop Surg Res*, 2007; 2: 23
20. Nepple JJ, Lenke LG: Severe idiopathic scoliosis with respiratory insufficiency treated with preoperative traction and staged anteroposterior spinal fusion with a 2-level apical vertebrectomy. *Spine J*, 2009; 9(7): e9–13
21. Wazeka AN, DiMaio MF, Boachie-Adjei O: Outcome of pediatric patients with severe restrictive lung disease following reconstructive spine surgery. *Spine*, 2004; 29(5): 528–34; discussion 535
22. Rinella A, Lenke L, Whitaker C et al: Perioperative halo-gravity traction in the treatment of severe scoliosis and kyphosis. *Spine*, 2005; 30(4): 475–82
23. Scherer TA, Spengler CM, Owassapian D et al: Respiratory muscle endurance training in chronic obstructive pulmonary disease: Impact on exercise capacity, dyspnea, and quality of life. *Am J Respir Crit Care Med*, 2000; 162(5): 1709–14
24. Moodie L, Reeve J, Elkins M: Inspiratory muscle training increases inspiratory muscle strength in patients weaning from mechanical ventilation: A systematic review. *J Physiother*, 2011; 57(4): 213–21
25. Seo K, Park SH, Park K: Effects of diaphragm respiration exercise on pulmonary function of male smokers in their twenties. *J Phys Ther Sci*, 2015; 27(7): 2313–15
26. Saeed MU, Dacuycu MA, Kennedy DJ: Halo pin insertion-associated brain abscess: Case report and review of literature. *Spine*, 2007; 32(8): E271–74
27. Garfin SR, Botte MJ, Nickel VL: Complications in the use of the halo fixation device. *J Bone Joint Surg Am*, 1987; 69(6): 954
28. Williams FH, Nelms DK, McGarahan KM: Brain abscess: A rare complication of halo usage. *Arch Phys Med Rehabil*, 1992; 73(5): 490–92
29. Tindall GT, Flanagan JF, Nashold BS Jr.: Brain abscess and osteomyelitis following skull traction. A report of three cases. *Arch Surg*, 1959; 79: 638–41
30. Teixeira da Silva LE, de Barros AG, de Azevedo GB: Management of severe and rigid idiopathic scoliosis. *Eur J Orthop Surg Traumatol*, 2015; 25(Suppl 1): S7–12
31. Wilkins C, MacEwen GD: Cranial nerve injury from halo traction. *Clin Orthop Relat Res*, 1977; (126): 106–10
32. Ginsburg GM, Bassett GS: Hypoglossal nerve injury caused by halo-suspension traction. A case report. *Spine*, 1998; 23(13): 1490–93
33. Tredwell SJ, O'Brien JP: Apophyseal joint degeneration in the cervical spine following halo-pelvic distraction. *Spine*, 1980; 5(6): 497–501
34. Bonnett C, Perry J, Kirkman-Brown JC, Greenberg BJ: Halo-femoral distraction and posterior spine fusion for paralytic scoliosis. *J Bone Joint Surg Am*, 1972; 54: 202
35. Abu Salim F, Zielke K: [Osteoporosis and halo traction in scoliosis patients (author's transl)]. *Z Orthop Ihre Grenzgeb*, 1982; 120(3): 330–32 [in German]