

Intracerebral Hemorrhage with Multiple Intracranial Arterial Stenoses in a Synthetic Cannabinoid “Spice” User

Abstract

Synthetic cannabinoids (spice), which are used frequently worldwide, are more potent than herbal compounds and also have more side effects in comparison. A 23-year-old male was admitted to the emergency unit with altered consciousness. There was no sign of trauma, and his medical history did not reveal any chronic illness. Computed tomography revealed a large frontal hematoma extending to the ventricular system. The outcomes of cerebral angiography were consistent with multiple intracranial arterial stenoses (MIAS) which can also be seen after cannabis usage. The patient made a good recovery with treatment, and during the follow-up, his medical condition was stable. In addition to the psychological symptoms, encephalopathy, ischemia, and seizures have also been described as side effects of synthetic cannabinoids. This paper reports an intracerebral hematoma due to synthetic cannabinoids and its association with MIAS.

Keywords: Intracerebral hemorrhage, multiple intracranial arterial stenoses, side effect, synthetic cannabinoid

Introduction

Delta-9-tetrahydrocannabinol (THC) is the main psychoactive component of cannabinoids. Synthetic cannabinoids are formed in laboratories using substances that show similar effects to them. Although there are various names for synthetic cannabinoids, the most common marketing name is “Spice.” Spice is popular among young people, especially in uneducated and low socioeconomic groups. These synthetic products have serious psychiatric, neurologic, cardiovascular, and metabolic side effects. In this article, we present a case of intracerebral hemorrhage due to synthetic cannabinoids as a very rare complication.

Case Report

A 23-year-old male was admitted to the emergency unit with sudden altered consciousness, and no preceding symptom was reported. Physical examination revealed a Glasgow Coma Scale score of 12/15 (E3, M5, V4). The pupils were isochoric with positive light reflex. There was neither a sign of trauma nor a specific sign of other disorders that could result in altered mental status.

This is an open access journal, and articles are distributed under the terms of the Creative Commons Attribution-NonCommercial-ShareAlike 4.0 License, which allows others to remix, tweak, and build upon the work non-commercially, as long as appropriate credit is given and the new creations are licensed under the identical terms.

For reprints contact: reprints@medknow.com

The medical history obtained from the relatives revealed the use of “Spice,” called “Bonzai” in Turkey, for over a year. He was a heavy smoker (two packs a day) but had no regular alcohol consumption. This information was confirmed by the patient after recovery, and he stated that he has been using spice for a year, particularly 3–4 times a week for 7 months and 5–6 times a week in the past 4 months, and he had never used any other illicit substance. A urine screening test (Alere Triage® TOX Drug Screen), including ten distinct drug classes, was performed and the results were negative for all substances.

The patient had alcohol (approx. 100 ml) while smoking spice on the day of the event. Cranial computed tomography (CT) showed a 6 cm × 5 cm × 4 cm sized right frontal intracerebral hematoma without a subarachnoid component, extending into the lateral ventricles [Figure 1]. An external ventricular drainage was applied in the intensive care unit. In the following day, diagnostic cerebral angiography showed multiple intracranial arterial stenoses (MIAS). There was neither aneurysm nor arteriovenous malformation nor cerebral venous sinus thrombosis [Figure 2]. The mental status

How to cite this article: Aydin S, Yuksel O, Aydin AE, Kizilkilic O, Celik SE. Intracerebral hemorrhage with multiple intracranial arterial stenoses in a synthetic cannabinoid “Spice” user. *Asian J Neurosurg* 2018;13:522-4.

**Seckin Aydin,
Odhan Yuksel¹,
Aysegul Esen
Aydin,
Osman Kizilkilic²,
Suat Erol Celik**

Department of Neurosurgery, Okmeydani Education and Research Hospital, ²Department of Neuroradiology, Istanbul University Cerrahpasa Medical Faculty, Istanbul, ¹Department of Neurosurgery, Siverek State Hospital, Sanliurfa, Turkey

Address for correspondence:

*Dr. Seckin Aydin,
Department of Neurosurgery,
Okmeydani Education and
Research Hospital, Darulaceze
Street, No: 27, PO Box: 34384,
Sisli, Istanbul, Turkey.
E-mail: seckin047@hotmail.com*

Access this article online

Website: www.asianjns.org

DOI: 10.4103/ajns.AJNS_48_16

Quick Response Code:



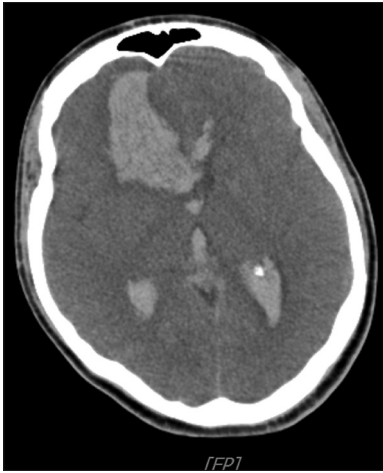

Figure 1: Axial computed tomography image showing right frontal lobar hematoma opening to the ventricular system

of the patient improved gradually within a week, and the several CT scans showed total resolution of the hematoma after 20 days. During the patient's hospital stay, no other complication occurred, and he was discharged with full recovery.

Discussion

Synthetic cannabinoids have been used worldwide for approximately 10 years and are becoming even more popular.^[1] These compounds are preferred because of their simple production and easy access. The difficulty in screening for the substance with routine urine and blood tests and the lack of prohibiting laws are also the encouraging factors on this issue.

The primary cannabinoid in natural cannabis is delta-9-THC, also known as marijuana, and it is a partial agonist of the cerebral cannabinoid receptor 1 (CB1) in the central nervous system. In contrast to marijuana, synthetic cannabinoids are produced in the laboratory to target these receptors as full or partial agonists. Nevertheless, synthetics are more potent CB1 agonists than the herbal derivative THC. These synthetic products are called "Spice" in the illegal market.^[2] The half-life of the synthetic product is longer, and its cannabinomimetic toxicity is more severe.^[3] The unexpected varieties in cannabinoid concentrations among the marketed agents make them even more dangerous.

Synthetic cannabinoids are especially popular among young people. Those who have family problems, low education level, or low socioeconomic status are prone to addiction. The main cannabinoid compound is usually mixed with herbal substances for smoking.^[4] The highly lipophilic feature of synthetic cannabinoids lets them easily pass through the blood-brain barrier and spread all over the central nervous system.^[5] The effect on the brain actually depends on the type of the synthetic agent used, the dose, and the route of application.

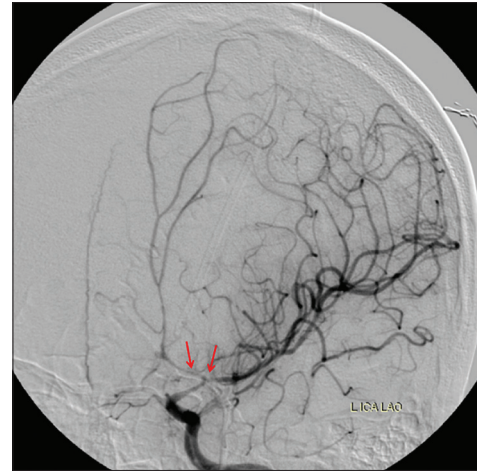


Figure 2: Cerebral angiography image showing left anterior and middle cerebral artery stenosis (red arrows)

The first effect starts in 10 min and decreases gradually in 2–6 h.^[6] The side effects are grouped as physiological and psychological. Psychological side effects including anxiety, agitation, paranoid ideation, delusion, and hallucination are more common with synthetic compounds.^[7] The main physiological side effects are nausea and vomiting, headache, tachycardia, hypertension, hyperglycemia, and seizures. The simultaneous use of other psychoactive drugs can aggravate and alter the clinical picture.^[8] A few cases with ischemic stroke related to synthetic cannabinoid use have been reported.^[9,10] Some patients present with the serotonin-like syndrome (myoclonus and mydriasis). One must remember that the patients can present with primary seizure following the use of synthetic cannabinoids.^[11] Most subjects recover within a day in emergency departments even though they may show exaggerated psychological symptoms such as severe anxiety, fear of death, or suicidal behavior on initial admission.^[12] Although not established in the literature yet, but discussed among users on the internet, some spice users experience a "bad trip," and this is a state, in which patients are almost unresponsive to any outer stimuli, but vital functions such as breathing or brainstem reflexes are not affected.

Cerebrovascular injury due to the use of synthetic cannabinoids is very rare. Our patient had a large right frontal lobe hematoma which drained to the ventricles, giving an impression of an underlying vascular pathology. Angiographic findings strongly supported the evidence of MIAS, which is only considered if a stenosis is found in at least two different arteries or two different segments in any artery.^[13] The relationship of MIAS with illicit drug consumption and vasoactive medication use is well defined. MIAS and catastrophic events such as stroke have been reported following the use of cannabis.^[14]

In moyamoya disease, accompanying MIAS usually causes hemorrhage. The angiographic and clinical diagnostic criteria of moyamoya disease were not disclosed in this patient.^[15] Although radiologic evaluation did not reveal subarachnoid hemorrhage, vasospasm may have

developed as a result of arterial stenosis. Vasospasm due to subarachnoid hemorrhage occurs at least three days later, yet this patient underwent diagnostic cerebral angiography within only 24 h after admission.

Cerebral venous thrombosis may have a sudden onset, but the initial symptom is usually headache. Digital subtraction angiography is the gold standard modality for diagnosis, and in this particular situation, accompanying arterial stenosis is not expected.^[16]

Reversible cerebral vasoconstriction syndrome (RCVS) has almost the same etiology with MIAS. Both pathologies have similar angiographic features and both may occur following the consumption of illicit substances. However, RCVS is typically characterized by a headache which can be the only initial symptom.^[17] Sudden neurological onset is not typical for RCVS. In addition, our case did not have the well-known risk factors mentioned above. This paper indicates a strong suspicion that synthetic cannabinoids may cause MIAS, which later may deteriorate into intracerebral hemorrhage. A second angiography should be performed to exclude RCVS, but our patient did not accept this procedure.

Our patient had synthetic cannabinoids and alcohol together on the day of admission. Some studies report that consuming alcohol increases plasma cannabinoid levels.^[18] Alcohol consumption with the use of cannabis-like synthetic compounds is, therefore, expected to increase blood levels of bioactive cannabinoid metabolites. Alcohol could be considered as a predisposing factor in cerebral hemorrhage, but there are no data supporting this notion.

Only two cases have been reported in a similar article recently, and designer drug guidelines do not include such a complication.^[19] This report addresses a different and unexpected side effect of synthetic cannabinoids, raising questions about the current knowledge. We believe that any new findings need serious consideration due to the high risk of cerebral damage following a hemorrhagic stroke, and these important side effects should be kept in mind while monitoring these patients.

Financial support and sponsorship

Nil.

Conflicts of interest

There are no conflicts of interest.

References

- Weaver MF, Hopper JA, Gunderson EW. Designer drugs 2015: Assessment and management. *Addict Sci Clin Pract* 2015;10:8.

- Spaderna M, Addy PH, D'Souza DC. Spicing things up: Synthetic cannabinoids. *Psychopharmacology (Berl)* 2013;228:525-40.
- Uchiyama N, Kikura-Hanajiri R, Ogata J, Goda Y. Chemical analysis of synthetic cannabinoids as designer drugs in herbal products. *Forensic Sci Int* 2010;198:31-8.
- Bhatty S, Wu W. Organic and synthetic cannabinoid use in adolescents. *Pediatr Ann* 2013;42:31-5.
- Wiebelhaus JM, Poklis JL, Poklis A, Vann RE, Lichtman AH, Wise LE. Inhalation exposure to smoke from synthetic "marijuana" produces potent cannabimimetic effects in mice. *Drug Alcohol Depend* 2012;126:316-23.
- Gunderson EW, Haughey HM, Ait-Daoud N, Joshi AS, Hart CL. "Spice" and "K2" herbal highs: A case series and systematic review of the clinical effects and biopsychosocial implications of synthetic cannabinoid use in humans. *Am J Addict* 2012;21:320-6.
- Schifano F, Orsolini L, Duccio Papanti G, Corkery JM. Novel psychoactive substances of interest for psychiatry. *World Psychiatry* 2015;14:15-26.
- Vardakou I, Pistos C, Spiliopoulou CH. Spice drugs as a new trend: Mode of action, identification and legislation. *Toxicol Lett* 2010;197:157-62.
- Freeman MJ, Rose DZ, Myers MA, Gooch CL, Bozeman AC, Burgin WS. Ischemic stroke after use of the synthetic marijuana "spice". *Neurology* 2013;81:2090-3.
- Bernson-Leung ME, Leung LY, Kumar S. Synthetic cannabis and acute ischemic stroke. *J Stroke Cerebrovasc Dis* 2014;23:1239-41.
- Louh IK, Freeman WD. A 'spicy' encephalopathy: Synthetic cannabinoids as cause of encephalopathy and seizure. *Crit Care* 2014;18:553.
- Harris CR, Brown A. Synthetic cannabinoid intoxication: A case series and review. *J Emerg Med* 2013;44:360-6.
- Wolff V, Armspach JP, Beaujeux R, Manisor M, Rouyer O, Lauer V, *et al.* High frequency of intracranial arterial stenosis and cannabis use in ischaemic stroke in the young. *Cerebrovasc Dis* 2014;37:438-43.
- Wolff V, Lauer V, Rouyer O, Sellal F, Meyer N, Raul JS, *et al.* Cannabis use, ischemic stroke, and multifocal intracranial vasoconstriction: A prospective study in 48 consecutive young patients. *Stroke* 2011;42:1778-80.
- Burke GM, Burke AM, Sherma AK, Hurley MC, Batjer HH, Bendok BR. Moyamoya disease: A summary. *Neurosurg Focus* 2009;26:E11.
- Qu H, Yang M. Early imaging characteristics of 62 cases of cerebral venous sinus thrombosis. *Exp Ther Med* 2013;5:233-6.
- Ducros A. Reversible cerebral vasoconstriction syndrome. *Lancet Neurol* 2012;11:906-17.
- Hartman RL, Brown TL, Milavetz G, Spurgin A, Gorelick DA, Gaffney G, *et al.* Controlled cannabis vaporizer administration: Blood and plasma cannabinoids with and without alcohol. *Clin Chem* 2015;61:850-69.
- Rose DZ, Guerrero WR, Mokin MV, Gooch CL, Bozeman AC, Pearson JM, *et al.* Hemorrhagic stroke following use of the synthetic marijuana "spice". *Neurology* 2015;85:1177-9.