



How to Discriminate Lung Cancer From Benign Pulmonary Nodules and Masses? Usefulness of Diffusion-Weighted Magnetic Resonance Imaging With Apparent Diffusion Coefficient and Inside/Wall Apparent Diffusion Coefficient Ratio

Clinical Medicine Insights: Oncology
Volume 15: 1–9
© The Author(s) 2021
Article reuse guidelines:
sagepub.com/journals-permissions
DOI: 10.1177/11795549211014863


Katsuo Usuda¹ , Shun Iwai¹, Aika Yamagata¹, Yoshihito Iijima¹, Nozomu Motono¹, Mariko Doai², Munetaka Matoba², Keiya Hirata³ and Hidetaka Uramoto¹

¹Department of Thoracic Surgery, Kanazawa Medical University, Uchinada, Japan. ²Department of Radiology, Kanazawa Medical University, Uchinada, Japan. ³MRI Center, General Hospital, Kanazawa Medical University, Uchinada, Japan.

ABSTRACT

BACKGROUND: Although diffusion-weighted imaging (DWI) is useful for differential diagnosis between lung cancers and benign pulmonary nodules and masses (BPNMs), it is difficult to differentiate pulmonary abscesses from lung cancers because pulmonary abscesses show restricted diffusion. With this research we will present how to assess the total apparent diffusion coefficient (ADC) and inside/wall ADC ratio for these pulmonary nodules and masses (PNMs).

METHODS: The pulmonary lesions were divided into next 3 groups. There were 40 lung cancers, 41 inflammatory benign PNMs (mycobacteria disease 13, pneumonia 12, pulmonary abscess 10, other 6) and 7 noninflammatory benign PNMs. Definitions were as follows: wall ADC = ADC value in outer one-third of the lesion; inside ADC = ADC value in central two-thirds of the lesion; inside/wall ADC ratio = ratio of inside ADC/wall ADC.

RESULTS: Mean total ADC ($1.26 \pm 0.32 \times 10^{-3} \text{ mm}^2/\text{s}$) of the lung cancers was remarkably lower than that (1.53 ± 0.53) of the BPNMs. The mean total ADC values were 1.26 ± 0.32 in lung cancer, 1.45 ± 0.47 in inflammatory BPNM and 2.04 ± 0.63 in noninflammatory BPNM, and there were significant differences among them. The mean inside ADC value (1.33 ± 0.32) of the lung cancers was remarkably higher than that (0.94 ± 0.42) of the pulmonary abscesses. The mean inside/wall ADC ratio (1.20 ± 0.28) of the lung cancers was remarkably higher than that (0.74 ± 0.14) of the pulmonary abscesses.

CONCLUSIONS: Although ADC of DWI could differentiate lung cancer from BPNM, the inside/wall ADC ratio of DWI is efficient for differentiation between lung cancer and lung abscess. The inside/wall ADC ratio of DWI strengthens a weak point of DWI.

KEYWORDS: Diffusion-weighted magnetic resonance imaging (DWI), lung cancer, pulmonary nodule and mass (PNM), pulmonary abscess, apparent diffusion coefficient (ADC)

RECEIVED: October 30, 2020. **ACCEPTED:** April 12, 2021.

TYPE: Original Research Article

FUNDING: The author(s) disclosed receipt of the following financial support for the research, authorship, and/or publication of this article: This study was supported by a Grant-in-Aid for Scientific Research from the Ministry of Education, Culture, Sports, Science and Technology, Japan (grant number: 20K09172).

DECLARATION OF CONFLICTING INTERESTS: The author(s) report no conflicts of interest with regard to the research, authorship, and/or publication of this article.

CORRESPONDING AUTHOR: Katsuo Usuda, Department of Thoracic Surgery, Kanazawa Medical University, 1-1 Daigaku, Uchinada 920-0293, Ishikawa, Japan. Email: usuda@kanazawa-med.ac.jp

Introduction

Pulmonary nodules and masses (PNMs) are common findings on chest radiographies. Of the causes of cancer-related deaths, lung cancer is one of the high mortality in PNMs and its correct diagnosis is essential for all patients. 18-fluoro-2-deoxy-glucose positron emission tomography/computed tomography (FDG-PET/CT) has become a recognized method for imaging PNMs. Its maximum standardized uptake value (SUV_{max}) means glucose metabolism and shows how aggressive the tumor is. The FDG-PET/CT is efficient for discriminating benign from malignant pulmonary nodules.¹ However, FDG-PET/CT is easy to express false-negative outcomes for small volumes of metabolic tumors,² or well-differentiated adenocarcinoma,³ and false-positive outcomes for inflammatory lesions.⁴

Partly due to the report of the Radiologic Diagnostic Oncology Group in 1991, magnetic resonance imaging (MRI) for lung cancer has only been narrowly used for over the past 30 years for mediastinal invasion or chest wall invasion of lung cancer.⁵ Diffusion-weighted magnetic resonance imaging (DWI) uses the random motion of water molecules found in biological tissue to generate images. Creating a quantitative parameter of the diffusion of water molecules in biological tissues will give us an apparent diffusion coefficient (ADC) value. As the ADC of malignant tumors is quite a bit lower than that of benign tissues, DWI can be an effective tool in the staging or the diagnosing of lung cancers.⁶ Its ADC value shows a quantitative parameter of the diffusion of water molecules in biological tissues and is usually significantly lower in



Creative Commons Non Commercial CC BY-NC: This article is distributed under the terms of the Creative Commons Attribution-NonCommercial 4.0 License (<https://creativecommons.org/licenses/by-nc/4.0/>) which permits non-commercial use, reproduction and distribution of the work without further permission provided the original work is attributed as specified on the SAGE and Open Access pages (<https://us.sagepub.com/en-us/nam/open-access-at-sage>).

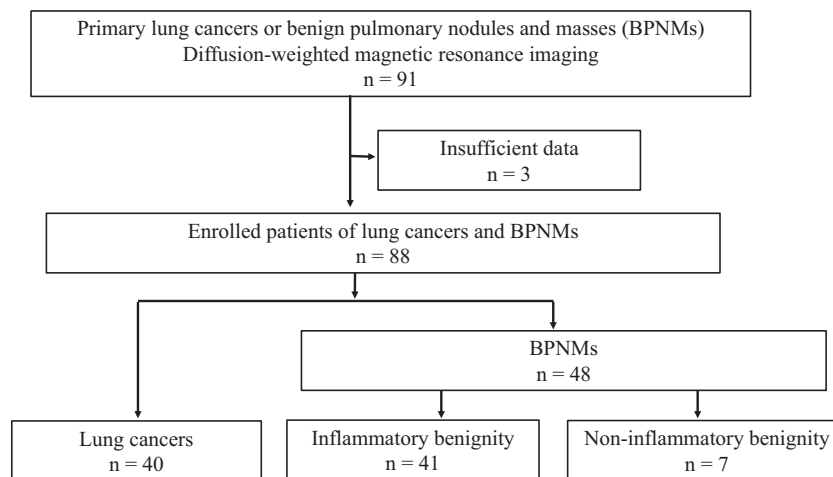


Figure 1. The flowchart of patient selection. Three patients were excluded due to insufficient data. BPNM indicates benign pulmonary nodules and masses.

malignant tumors compared with normal tissues or benign lesions.

A meta-analysis showed that DWI is able to reliably diagnose malignant from benign pulmonary lesions.⁷ The DWI can distinguish benign from malignant lesions in the lung,^{7,8} in the thorax,⁹ in the prostate,¹⁰ in the breast,¹¹ and in the liver.¹² Although DWI is able to diagnose benign from malignant lesions in the lung, it was difficult to differentiate pulmonary abscesses from lung cancers because pulmonary abscesses show strong restricted diffusion. Lung cancers show stronger diffusion in wall area of the tumor; on the contrary, pulmonary abscesses have stronger diffusion in central pus area of the lesion examined by DWI.¹³

The aim of this article is to conclude whether total ADC and inside/wall ADC ratio, which presents the ratio of the inside ADC of the lesion divided by the wall ADC of the lesion, are efficient in discriminating lung cancers from benign pulmonary nodules and masses (BPNMs), especially pulmonary abscess.

Patients and Methods

Eligibility

The research protocol for examining DWI in patients with PNM was approved by the ethical committee of Kanazawa Medical University (approval number: No. I302). After consulting patients on the risks and benefits of the examinations, written informed consent for MRI was obtained from each patient.

Patients

This was a retrospective research. In the patients who had a primary lung cancer or a BPNM and had DWI examination before pathological diagnosis or bacterial diagnosis from May 2009 to April 2018, 91 patients who qualified for this research were collected (Figure 1). Out of the 91 patients, only 88 could get ADC and inside/wall ADC ratio after examinations and became our study group. All patients had not received prior

treatment. Sixty patients were male and 28 were female. Their mean age was 68 years old (range: 46–85). There were 40 lung cancers and 48 BPNMs. The diagnosis was made pathological in 40 lung cancers and 26 BPNMs. Thirteen BPNMs were diagnosed as mycobacteria disease by a bacterial culture or resection, and remaining 9 BPNMs were diagnosed as pneumonia by decreased size or disappearance of the BPNMs.

The pulmonary lesions were divided into 3 groups (lung cancer, inflammatory, and noninflammatory BPNM) based on the cause (malignant, benign with inflammation causes, benign without inflammation causes) (Figure 1, Table 1). For 40 lung cancers, there were 28 adenocarcinomas, 10 squamous cell carcinomas, 1 large-cell neuroendocrine carcinoma, and 1 large cell carcinoma. For 48 BPNMs, there were 41 inflammatory BPNMs (pulmonary abscess 10, mycobacteria disease 13 [tuberculosis 5, nontuberculous mycobacteriosis 8], pneumonia 12, organized pneumonia 2, pulmonary scar 2, pneumoconiosis 1, and pulmonary granuloma 1), and 7 noninflammatory BPNMs (hamartoma 3, pulmonary sequestration 2, inflammatory myofibroblastic tumor 1, and encapsulated pleural effusion 1). The new definitions in UICC 8 were applied for TNM classification and the lymph node stations of lung cancer.¹⁴

MR imaging

For all MR images, a 1.5 T superconducting magnetic scanner (Magnetom Avanto; Siemens, Erlangen, Germany) was used. For the conventional MR images, a coronal T1-weighted spin-echo sequence and coronal and axial T2-weighted fast spin-echo sequences were taken. For DWIs, a single-shot echo-planar method were applied with slice thickness of 6 mm under SPAIR (spectral attenuated inversion recovery) and respiratory triggered scan with the following parameter: TR 4000 to 6000 ms, TE 65 ms, tridimensional gradients with b values of 0 and 800 s/mm²; diffusion gradient encoding in 3 orthogonal directions; matrix size, 128 × 128; field of view, 350 mm. After image reconstruction, region of interest (ROI) for the

Table 1. Relationships among diagnosis, total ADC, wall ADC, inside ADC, and inside/wall ADC ratio.

DIAGNOSIS	NO. OF PATIENTS	TOTAL ADC		WALL ADC		INSIDE ADC		INSIDE/WALL ADC RATIO	
		×10 ⁻³ MM ² /S		×10 ⁻³ MM ² /S		×10 ⁻³ MM ² /S			
Adenoca.	28								
Squamous cell ca.	10	1.26 ± 0.32	1.15 ± 0.33	1.33 ± 0.32	1.20 ± 0.28				
LCNEC	1								
Large-cell ca.	1								
Inflammatory benignity	41								
Pulmonary abscess	10	1.26 ± 0.50	1.28 ± 0.53	0.94 ± 0.42	0.74 ± 0.14				
Mycobacteria disease	13 (Tbc 5, NTM 8)	1.44 ± 0.50	1.70 ± 0.59	1.32 ± 0.51	0.79 ± 0.14				
Pneumonia	12	1.60 ± 0.36	1.73 ± 0.62	1.45 ± 0.44	1.88 ± 0.19				
Organized pneumonia	2	2.03 ± 0.74	2.77 ± 0.0	2.08 ± 0.0	0.75 ± 0.0				
Pulmonary scar	2	1.16 ± 0.29	1.18 ± 0.03	0.78 ± 0.20	0.66 ± 0.18				
Pneumoconiosis	1	1.11	1.41	0.74	0.52				
Pulmonary granuloma	1	1.37	0.96	1.28	1.33				
Noninflammatory benignity	7								
Hamartoma	3	1.90 ± 0.32	1.91 ± 0.29	1.99 ± 0.37	0.94 ± 0.03				
Pulmonary sequestration	2	2.17 ± 0.20	1.76 ± 0.18	2.36 ± 1.10	1.38 ± 0.76				
Inflammatory myofibroblastic tumor	1	1.11	1.23	1.15	0.94				
Encapsulated pleural effusion	1	3.11	2.24	3.32	1.48				
Total	88								

Bold values mean several mean values of lung cancers, inflammatory benignity, noninflammatory benignity. Abbreviations: ADC, apparent diffusion coefficient; LCNEC: large cell neuroendocrine carcinoma.

ADC was set up as follows (Figure 2): Total ADC was calculated as a total ADC value of the whole area of the lesion without excluding necrosis by free-hand ROIs on lesions which were detected visually on the ADC maps. Wall ADC was defined as the ADC value measured in the outer one-third of the lesion. Inside ADC was defined as the ADC value measured in the central two-thirds of the lesion. Inside/wall ADC ratio was the ratio of inside ADC divided by the wall ADC (Figure 3). These ADC values were obtained by drawing round, elliptical or free-hand ROIs on lesions which were identified by sight on the ADC map with reference to T2-weighted or CT image. A radiologist (M.D.) with 25 years of MRI experience, who was not informed of the patients' clinical data and a

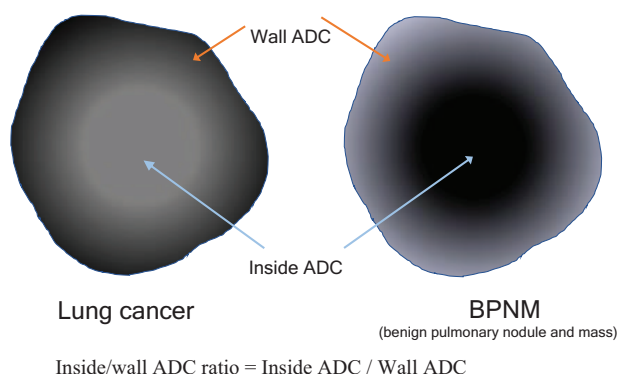


Figure 2. Schemas of ADC map for lung cancer and BPNM. Wall ADC was defined as the ADC value measured in the outer one-third of the lesion. Inside ADC was defined as the ADC value measured in the central two-thirds of the lesion. Inside/wall ADC ratio was the ratio of inside ADC divided by the wall ADC. ADC indicates apparent diffusion coefficient; BPNM, benign pulmonary nodules and masses.

pulmonologist (K.U.), who has 30 years of experience, analyzed the MRI data. They eventually had the same conclusion.

Statistical analysis

The data obtained are reported as the mean \pm standard deviation. A 2-tailed Student *t* test was performed for comparison of several values of 2 groups and analysis of variance was performed for comparison of several values of 3 or more groups in several factors. Using GraphPad Prism (Version 5.02, GraphPad Software, Inc. La Jolla, CA, USA) receiver operating characteristic (ROC) curves were obtained and optimal cutoff values of the ADC and the inside/wall ADC ratio in terms of discrimination of lung cancers from BPNMs were determined. The statistical analyses were performed using the computer software StatView for Windows (Version 5.0; SAS Institute Inc. Cary, NC, USA). A *P* value of $<.05$ was decided statistically significant.

Results

In ROC curve of total ADC for distinguishing BPNM from lung cancer for all the 88 PNMs (Figure 4A), the area under the ROC curve was 71%. When the cutoff value of total ADC was set as $1.270 \times 10^{-3} \text{ mm}^2/\text{s}$, the sensitivity was 75.6% and the specificity was 60.4%. In ROC curve of the inside/wall ADC ratio for distinguishing BPNMs from lung cancer (Figure 4B), area under the ROC curve was 87.1%. When the cutoff value of the inside/wall ADC ratio was set as 0.9695, the sensitivity was 87.5%, specificity 81.3%.

In the 10 patients with pulmonary abscesses, 2 patients showed coughing, 1 cough with blood sputum, and 1 chest pain. The remaining 6 patients showed no symptoms. No

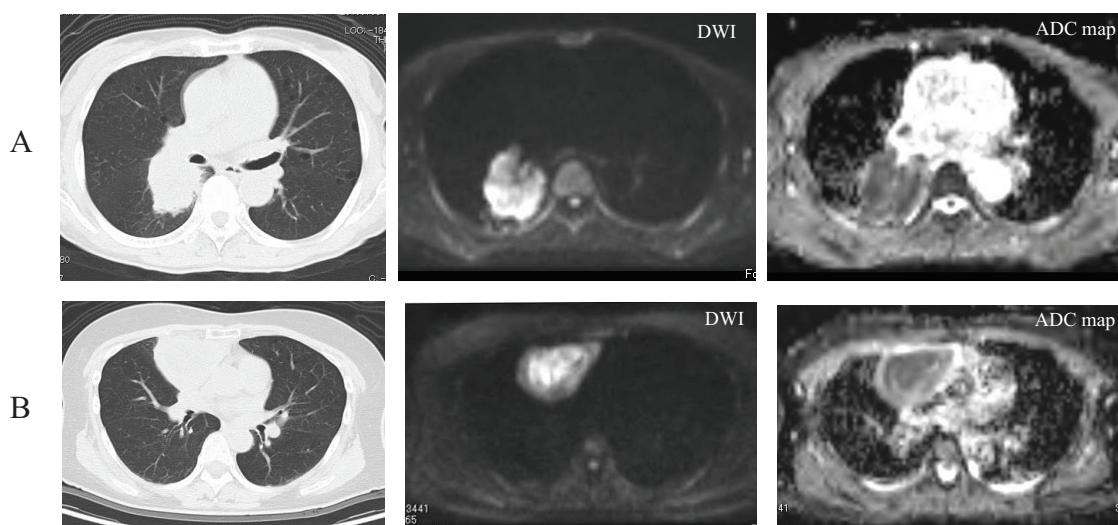


Figure 3. (A) Adenocarcinoma. Total ADC value: $1.21 \times 10^{-3} \text{ mm}^2/\text{s}$. Wall ADC: $1.18 \times 10^{-3} \text{ mm}^2/\text{s}$. Inside ADC: $1.25 \times 10^{-3} \text{ mm}^2/\text{s}$. Wall/Inside ADC ratio 1.11. (B) Pulmonary abscess. Total ADC: $1.40 \times 10^{-3} \text{ mm}^2/\text{s}$. Wall ADC: $2.00 \times 10^{-3} \text{ mm}^2/\text{s}$. Inside ADC: $1.13 \times 10^{-3} \text{ mm}^2/\text{s}$. Inside/Wall ADC ratio 0.57. ADC indicates apparent diffusion coefficient.

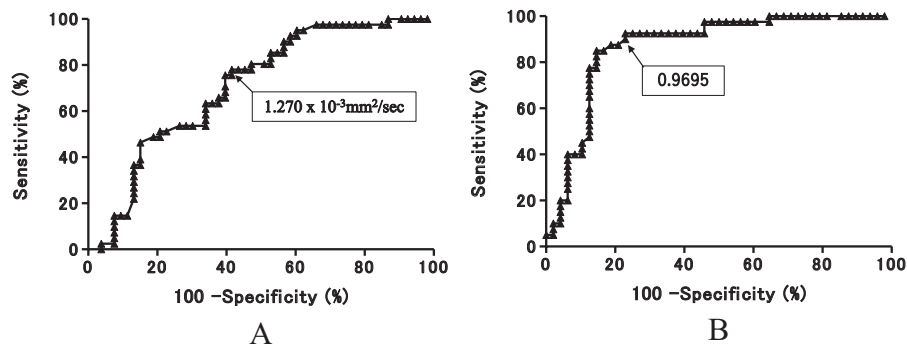


Figure 4. Receiver operating characteristic (ROC) curve shows the diagnostic performance of total ADC (A) for distinguishing benign pulmonary nodule and mass (BPNM) from lung cancer and of inside/wall ADC ratio (B) for distinguishing pulmonary abscess from lung cancer. (A) Area under the ROC curve 71%, ADC = 1.270, sensitivity 75.6%, specificity 60.4%. (B) Area under the ROC curve 87.1%, inside/wall ADC ratio = 0.9695, sensitivity 87.5%, specificity 81.3%. ADC indicates apparent diffusion coefficient; BPNM, benign pulmonary nodules and masses; ROC, receiver operating characteristic.

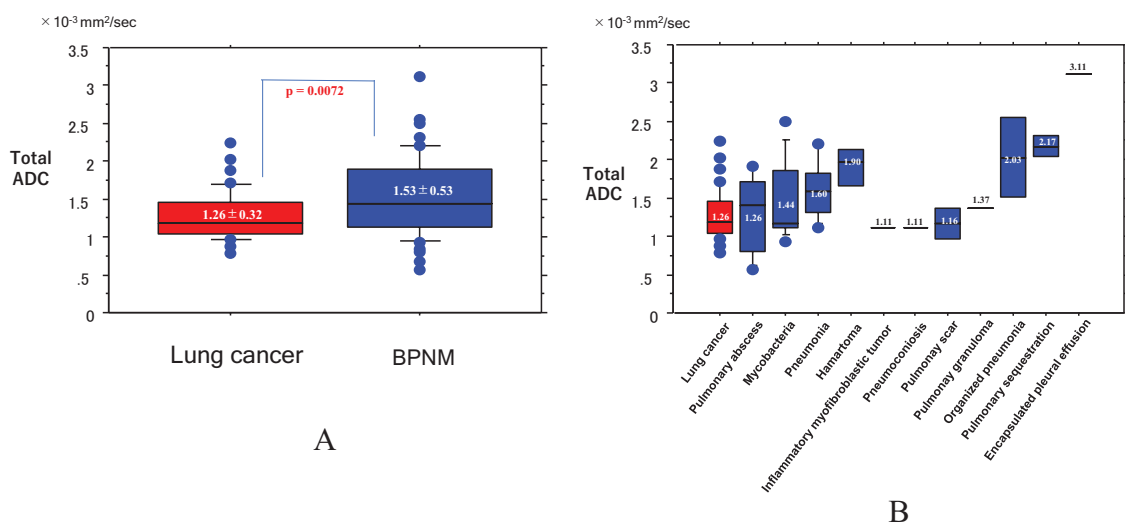


Figure 5. Total ADC value based on lung cancer or benign pulmonary nodules and mass (BPNM): (A) diagnosis and (B) detailed diagnosis. ADC indicates apparent diffusion coefficient; BPNM, benign pulmonary nodules and masses.

patients had a fever. No patients had an elevated white cell count, or a neutrophil shift. For CRP, there was 1 patient above 3.0 mg/dL, 5 patients below 1.0 mg/mL, and the remaining 4 patients showed below 0.1 mg/dL.

The mean lesion size (43.4 ± 18.3 mm) of the lung cancers was remarkably higher than that (23.7 ± 13.8 mm) of the BPNMs ($P < .0001$). The mean total ADC value ($1.26 \pm 0.32 \times 10^{-3}$ mm²/s) of the lung cancers was remarkably lower than that ($1.53 \pm 0.53 \times 10^{-3}$ mm²/s) of the BPNMs ($P = .0072$) (Figure 5A, Table 1). Total ADC values based on detailed diagnosis of PNMs were presented (Figure 5B). Although pulmonary abscesses were benign, the total ADC value ($1.26 \pm 0.50 \times 10^{-3}$ mm²/s) of the pulmonary abscesses was almost same as that ($1.26 \pm 0.32 \times 10^{-3}$ mm²/s) of the lung cancers, which could not be distinguished from lung cancers (Figure 5B, Table 1).

When the pulmonary lesions were divided into 3 groups (lung cancer, inflammatory, and noninflammatory BPNM), the mean total ADC values were $1.26 \pm 0.32 \times 10^{-3}$ mm²/s in lung cancer, $1.45 \pm 0.47 \times 10^{-3}$ mm²/s in inflammatory BPNM, and $2.04 \pm 0.63 \times 10^{-3}$ mm²/s in noninflammatory

BPNM (Figure 6, Table 1). There were notable differences among 3 groups ($P < .01$). The mean wall ADC values were $1.15 \pm 0.33 \times 10^{-3}$ mm²/s in lung cancer, $1.61 \pm 0.63 \times 10^{-3}$ mm²/s in inflammatory BPNM, and $1.87 \pm 0.37 \times 10^{-3}$ mm²/s in noninflammatory BPNM. The mean wall ADC value of the lung cancers was remarkably lower than that of the inflammatory BPNM ($P < .0001$) and than that of the noninflammatory BPNM ($P = .0007$). The mean inside ADC values were $1.33 \pm 0.32 \times 10^{-3}$ mm²/s in the lung cancer, $1.26 \pm 0.51 \times 10^{-3}$ mm²/s in the inflammatory BPNM, and $2.13 \pm 0.82 \times 10^{-3}$ mm²/s in the noninflammatory BPNM. The mean inside ADC value of the lung cancer was as same as that of the inflammatory BPNM and remarkably lower than that of the noninflammatory BPNM ($P < .0001$). The mean inside/wall ADC ratios were 1.20 ± 0.28 in the lung cancers, 0.80 ± 0.46 in inflammatory BPNMs, and 1.14 ± 0.40 in noninflammatory BPNMs. The mean inside/wall ADC ratio of the inflammatory BPNMs was remarkably lower than that of the lung cancers ($P < .0001$) and remarkably lower than that of the noninflammatory BPNMs ($P = .0007$).

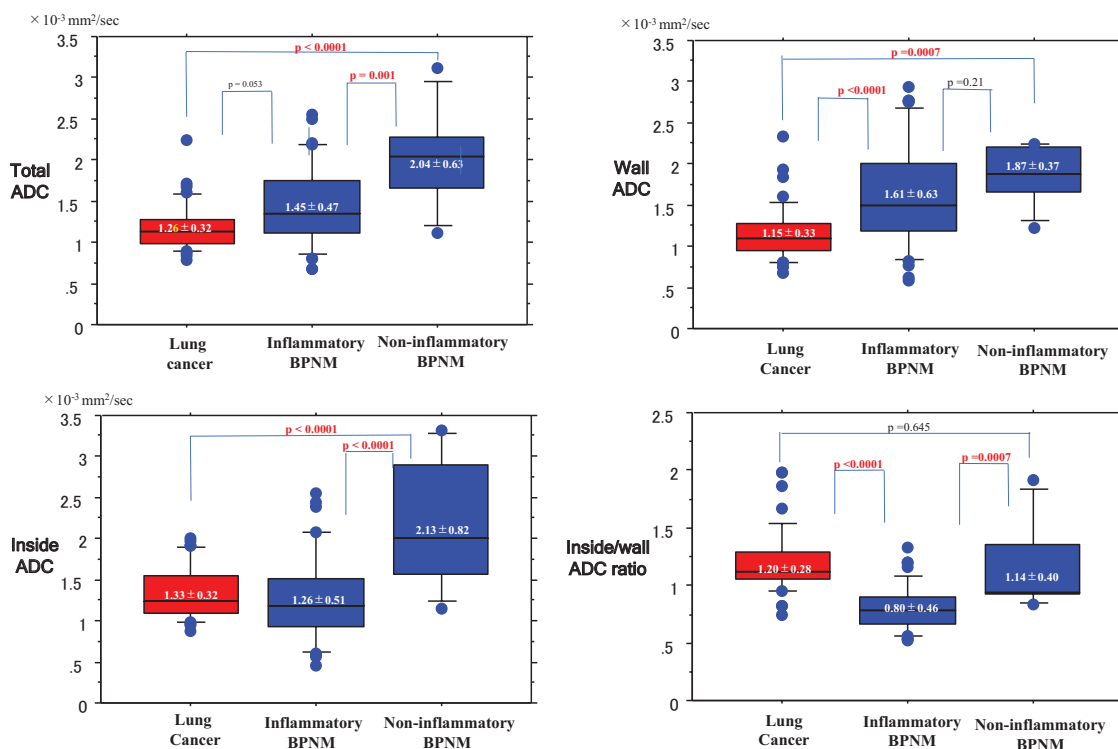


Figure 6. Total ADC, wall ADC, inside ADC, inside/wall ADC ratio based on lung cancer, inflammatory, or noninflammatory BPNM. ADC indicates apparent diffusion coefficient; BPNM, benign pulmonary nodules and masses.

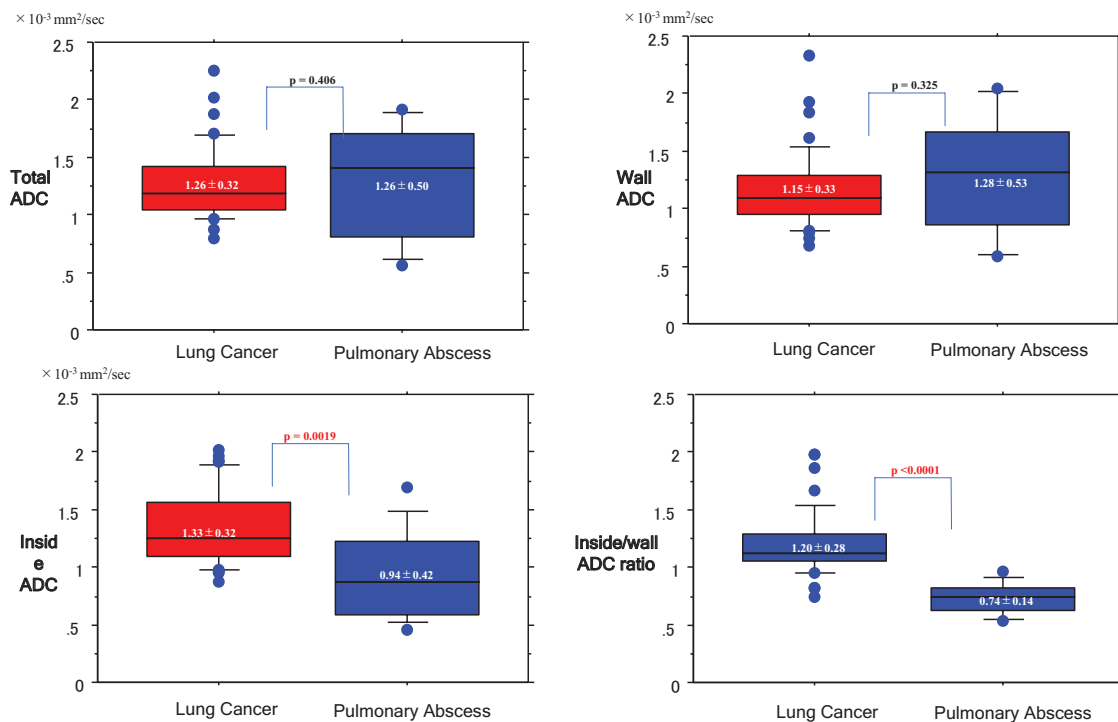


Figure 7. Total ADC, ADC wall, ADC inside, inside/wall ADC ratio based on lung cancer or pulmonary abscess. ADC indicates apparent diffusion coefficient.

Comparisons between the lung cancers and the pulmonary abscesses were done (Figure 7). The mean total ADC value ($1.26 \pm 0.32 \times 10^{-3} \text{ mm}^2/\text{s}$) of the lung cancers was same as that ($1.26 \pm 0.50 \times 10^{-3} \text{ mm}^2/\text{s}$) of the pulmonary

abscesses ($P = .406$). The mean wall ADC value ($1.15 \pm 0.33 \times 10^{-3} \text{ mm}^2/\text{s}$) of the lung cancers was not significantly lower than that ($1.28 \pm 0.53 \times 10^{-3} \text{ mm}^2/\text{s}$) of the pulmonary abscesses ($P = .325$). The mean inside ADC value (1.33

$\pm 0.32 \times 10^{-3} \text{ mm}^2/\text{s}$) of the lung cancers was remarkably higher than that ($0.94 \pm 0.42 \times 10^{-3} \text{ mm}^2/\text{s}$) of the pulmonary abscesses ($P = .0019$). The mean inside/wall ADC ratio (1.20 ± 0.28) of the lung cancers was remarkably higher than that (0.74 ± 0.14) of the pulmonary abscesses ($P < .0001$).

In the total ADC analysis, the sensitivity was 67.5% (27/40), the specificity was 62.5% (30/48), and the accuracy was 64.8% (57/88). The positive predictive value (PPV) was 60.0% (27/45) and the negative predictive value (NPV) was 70.0% (30/43). In the inside/wall ADC ratio analysis, the sensitivity was 92.5% (37/40), the specificity was 77.1% (37/48), and the accuracy was 84.1% (74/88). The PPV was 77.1% (37/48) and the NPV was 92.5% (37/40).

Discussion

Although total ADC is valuable for differential diagnosis between lung cancers and BPNMs, differential diagnosis between lung cancers and pulmonary abscess was difficult due to lower ADC value. In that situation, inside/wall ADC ratio and inside ADC are valuable for differential diagnosis between lung cancers and pulmonary abscesses. The investigation of 2 steps (ADC and inside/wall ADC ratio) is effective for an accurate diagnosis of PNM. The originality of our study is based on the DWI comparison of the wall and the inside of the pulmonary nodule and mass. There were no published researches available on PNMs.

To show the efficacy of DWI for differentiation of lung cancers from BPNMs,^{7,15,16} 3 meta-analyses were conducted. After reviewing the results of all the meta-analyses, we reached the conclusion that DWI could differentiate lung cancers from BPNMs. The evidence was proven in this article: total ADC was useful for differential diagnosis between lung cancer and BPNM.

However, it was difficult to differentiate a pulmonary abscess from a lung cancer because a pulmonary abscess showed strong restricted diffusion in DWI: the total ADC value ($1.26 \pm 0.50 \times 10^{-3} \text{ mm}^2/\text{s}$) of the pulmonary abscesses was same as that ($1.26 \pm 0.32 \times 10^{-3} \text{ mm}^2/\text{s}$) of the lung cancers, which could not be distinguished from lung cancers. Pathologic processes, such as pulmonary tuberculosis, nontuberculous mycobacteriosis, sarcoidosis, lung abscess, chronic pneumonia, scars, and other infectious or inflammatory conditions, could look like malignant lesions by presenting diffusion restriction.¹⁷⁻¹⁹ The ADC value of abscesses is low and median ADC value ($0.877 \times 10^{-3} \text{ mm}^2/\text{s}$) of abscesses was remarkably lower than that ($2.118 \times 10^{-3} \text{ mm}^2/\text{s}$) of phlegmon ($P < .001$), and that ($3.008 \times 10^{-3} \text{ mm}^2/\text{s}$) of edema ($P < .01$).²⁰ There were several reasons for restricted diffusion of a pulmonary abscess or inflammatory lesions. The thickness and decreased mobility of pus can be caused by its high viscosity and cellularity, and exhibit the low ADC values.²¹ Abscesses and thrombi decrease the diffusivity of water molecules because they have

a hyperviscous nature.^{22,23} Low ADC value of necrosis was connected to the organized abscess environment containing microorganisms, intact inflammatory cells, and macromolecules.²⁴ The possible reasons for this have been attributed to necrotic debris, viscosity, and macromolecules in the pus.^{21,23} Most brain abscesses have low ADC values, whereas nonabscess (tumor) groups have high ADC values.²⁵ However, carcinomas would show restricted diffusion and low ADC value because the wall of carcinomas shows a high cellular proliferation rate, high nucleus-cytoplasm rate, intracellular macromolecules, cells with a large size nucleus, and limited size of the extracellular matrix.^{26,27}

Using DWI, larger masses without diffusion decrease could be confirmed benign due to their higher ADC value.

In this article, we focus on lung cancers showing stronger diffusion in wall area, but a pulmonary abscess has stronger diffusion in central pus area when examined by DWI.¹³ The necrosis/wall ADC ratio would be more efficient for malignant-benign differentiation in necrotic breast lesions than for measuring only ADC of the wall.²⁸ Our article presented that the mean inside/wall ADC ratio (1.20 ± 0.28) of the lung cancers was remarkably higher than that (0.74 ± 0.14) of the pulmonary abscesses ($P < .0001$). Furthermore, the mean inside ADC value ($1.33 \pm 0.32 \times 10^{-3} \text{ mm}^2/\text{s}$) of the lung cancers was remarkably higher than that ($0.94 \pm 0.42 \times 10^{-3} \text{ mm}^2/\text{s}$) of the pulmonary abscesses ($P = .0019$).

If a PNM shows restrictive diffusion in DWI, and its inside/wall ADC ratio is higher than the cutoff value (0.9695), the lesion can be a lung cancer. However, if a PNM shows restrictive diffusion in DWI, and its inside/wall ADC ratio is lower than the cutoff value (0.9695), that is to say the inside ADC showing lower than the wall ADC, the PNM can be a pulmonary abscess. The necrosis/wall ADC ratio appears to be a reliable and a promising tool for differentiating lung carcinoma from benign necrotic lung lesions, more so than by just measuring the wall alone.¹³ As far as I searched the literature of the inside/wall ADC ratio, there were 2 articles which were cited in this study. The deficiency in the literature was how to discriminate abscess from carcinoma.

There is some worry about absence of standardization in ROI selection for ADC assessment. Many researchers suggested that areas of necrosis should be avoided from the assessment of ADC. Based on our analysis, conversely, areas of necrosis should be included for the ADC assessment for PNMs. The ADC ($1.11 \times 10^{-3} \text{ mm}^2/\text{s}$) of lung cancer with necrosis was reported to be remarkably lower than that ($1.32 \times 10^{-3} \text{ mm}^2/\text{s}$) of lung cancer without necrosis ($P = .0001$).²⁹ It may be better to not discard the necrosis from the assessment when evaluating the necrosis/wall ADC ratio.¹³ In the situation of lung cancer with necrosis, careful assessment would be necessary because wall ADC means an ADC of cancer, but inside ADC means sometimes an ADC of necrosis but other times an ADC of cancer. In the end, the combination of total

ADC, wall ADC, inside ADC and inside/wall ADC ratio would present the true characteristics of the lung cancer. This information will be useful for future analysis of lung cancer.

Two papers were reported for comparison of diagnostic efficacy between DWI and FDG-PET/CT for PNMs.^{8,19} Both the sensitivity and the accuracy of DWI were reported to be remarkably higher in one paper,⁸ whereas the other paper only reported on the sensitivity of DWI being remarkably higher¹⁹ than those of FDG-PET/CT. The DWI could possess higher diagnostic ability than FDG-PET/CT in assessing PNMs.

Magnetic resonance imaging involves no contrast mediums, and as there is no radiation involved, it is superbly suited for the examination of people that cannot be exposed to radiation such as children and pregnant women.

Both DWI and FDG-PET/CT have their own strengths:³⁰ DWI uses quantitative information regarding tissue cellularity and the diffusion of water molecules, whereas FDG-PET/CT uses glucose metabolism and presents the aggressiveness of the lesion. Gallivanone et al³¹ mentioned FDG-PET/CT expected patient prognosis and DWI respected response to neoadjuvant chemotherapy, and both examinations are useful for biological characterization and neoadjuvant chemotherapy response in breast cancer.

This research had 2 limitations. First, it was a retrospective study at a single institution and dealt small number of patients. Second, in some cases image quality was not enough to calculate the true ADC. This might be a limitation of DWI compared with FDG-PET/CT. Further studies are needed for accurate evaluation of inside/wall ADC ratio.

Conclusions

Although ADC of DWI could differentiate lung cancer from BPNM, the inside/wall ADC ratio of DWI would be efficient for differentiation between lung cancer and lung abscess. The inside/wall ADC ratio of DWI strengthens a weak point of DWI. The investigation of 2 steps (ADC and inside/wall ADC ratio) is effective for an accurate diagnosis of PNMs. Further studies are essential to evaluate diagnostic performance of the total ADC and the inside/wall ADC ratio for lung cancers and BPNMs including pulmonary abscesses.

Acknowledgements

We are grateful to Tatsunori Kuroda, Saeko Tomida, Yasuhiro Kato, Chihiro Nagasako, Eriko Sato, and Honami Sato of the MRI Center, General hospital of Kanazawa Medical University, for technical assistance. We are grateful to Dustin Keeling for proofreading this paper.

Author Contributions

KU contributed to conceptualization, data curation, writing—original draft preparation, writing—review and editing; SI and AY contributed to resources; YI and NM contributed to data curation; MM and MD contributed to methodology; KH contributed to methodology and software; HU contributed to conceptualization and supervision.

ORCID iD

Katsuo Usuda  <https://orcid.org/0000-0001-6803-9356>

REFERENCES

1. Could MK, Maclean CC, Kuschner WG, Rydzak CE, Owens DK. Accuracy of positron emission tomography for diagnosis of pulmonary nodules and mass lesions. A meta-analysis. *JAMA*. 2001;285:914-924.
2. Satoh Y, Ichikawa T, Motosugi U, et al. Diagnosis of peritoneal dissemination. Comparison of 18F-DDG PET/CT, diffusion-weighted MRI, and contrast-enhanced MDCT. *Am J Roentgenol*. 2011;196:447-453.
3. Cheran SK, Nielsen ND, Patz EF Jr. False-negative findings for primary lung tumors on FDG positron emission tomography. Staging and prognostic implications. *Am J Roentgenol*. 2004;182:1129-1132.
4. Goo JM, Im JG, Do KH, et al. Pulmonary tuberculoma evaluated by means of FDG PET. Findings in 10 cases. *Radiology*. 2000;216:117-121.
5. Webb WR, Gatsonis C, Zerhouni EA, et al. CT and MR imaging in staging non-small cell bronchogenic carcinoma. Report of the Radiologic Diagnostic Oncology Group. *Radiology*. 1991;178:705-713.
6. Szafer A, Zhong J, Gore JC. Theoretical model for water diffusion in tissues. *Magn Reson Med*. 1995;33:697-712.
7. Wu LM, Xu JR, Hua J, et al. Can diffusion-weighted imaging be used as a reliable sequence in the detection of malignant pulmonary nodules and masses? *Magn Reson Imaging*. 2013;31:235-246.
8. Mori T, Nomori H, Ikeda K, et al. Diffusion-weighted magnetic resonance imaging for diagnosing malignant pulmonary nodules/masses. Comparison with positron emission tomography. *J Thorac Oncol*. 2008;3:358-364.
9. Tondo F, Saponaro A, Stecco A, Lombardi M, Casadio C, Carriero A. Role of diffusion-weighted imaging in the differential diagnosis of benign and malignant lesions of the chest-mediastinum. *Radiol Med*. 2011;116:720-733.
10. Yamamura J, Salomon G, Buchert R, et al. Magnetic resonance imaging of prostate cancer. Diffusion-weighted imaging in comparison with sextant biopsy. *J Comput Assist Tomogr*. 2011;35:223-228.
11. Fornasa F, Pinali L, Gasparini A, Toniolli E, Montemezzi S. Diffusion-weighted magnetic resonance imaging in focal breast lesions. Analysis of 78 cases with pathological correlation. *Radiol Med*. 2011;116:264-275.
12. Koike N, Cho A, Nasu K, et al. Role of diffusion-weighted magnetic resonance imaging in the differential diagnosis of focal hepatic lesions. *World J Gastroenterol*. 2009;15:5805-5812.
13. Karaman A, Durur-Subasi I, Alper F, Durur-Karakaya A, Subasi M, Akgun M. Is it better to include necrosis in apparent diffusion coefficient (ADC) measurements? The necrosis/wall ADC ratio to differentiate malignant and benign necrotic lung lesions: preliminary results. *J Magn Reson Imaging*. 2017;46:1001-1006. doi:10.1002/jmri.25649.
14. Brierley D, Gospodarowicz MK, Wittekind C. *TNM Classification of Malignant Tumours*. 8th ed. New York, NY: John Wiley & Sons, 2017.
15. Li B, Li Q, Chen C, Guan Y, Liu S. A systematic review and meta-analysis of the accuracy of diffusion-weighted MRI in the detection of malignant pulmonary nodules and masses. *Acad Radiol*. 2014;21:21-29.
16. Shen G, Jia Z, Deng H. Apparent diffusion coefficient values of diffusion-weighted imaging for distinguishing focal pulmonary lesions and characterizing the subtype of lung cancer: a meta-analysis. *Eur Radiol*. 2016;26:556-566.
17. Liu H, Liu Y, Yu T, Ye N. Usefulness of diffusion-weighted MR imaging in the evaluation of pulmonary lesions. *Eur Radiol*. 2010;20:807-815.
18. Coolen J, De Keyzer F, Naftex P, et al. Malignant pleural disease: diagnosis by using diffusion-weighted and dynamic contrast-enhanced MR imaging-initial experience. *Radiology*. 2012;263:884-892.
19. Usuda K, Sagawa M, Motono N, et al. Diagnostic performance of diffusion weighted imaging of malignant and benign pulmonary nodules and masses: comparison with positron emission tomography. *Asian Pac J Cancer Prev*. 2014;15:4629-4635.
20. Chun CW, Jung JY, Baik JS, Jee WH, Kim SK, Shin SH. Detection of soft-tissue abscess: comparison of diffusion-weighted imaging to contrast-enhanced MRI. *J Magn Reson Imaging*. 2018;47:60-68. doi:10.1002/jmri.25743.
21. Ebisu T, Tanaka C, Umeda M, et al. Discrimination of brain abscess from necrotic or cystic tumors by diffusion-weighted echo planar imaging. *Magn Reson Imaging*. 1996;14:1113-1116.
22. Kwee TC, Takahara T, Ochiai R, et al. Complementary roles of whole-body diffusion-weighted MRI and 18F-FDG PET. The state of the art and potential application. *J Nucl Med*. 2010;51:1549-1558.
23. Desprechins B, Stadnik T, Koerts G, Shabana W, Breucq C, Osteaux M. Use of diffusion-weighted MR imaging in differential diagnosis between intracerebral necrotic tumors and cerebral abscesses. *Am J Neuroradiol*. 1999;20:1252-1257.
24. Xu XX, Li B, Yang HF, et al. Can diffusion-weighted imaging be used to differentiate brain abscess from other ring-enhancing brain lesions? A meta-analysis. *Clin Radiol*. 2014;69:909-915.

25. Mishra AM, Gupta RK, Jaggi RS, et al. Role of diffusion-weighted imaging and in vivo proton magnetic resonance spectroscopy in the differential diagnosis of ring-enhancing intracranial cystic mass lesions. *J Comput Assist Tomogr.* 2004;28:540-547.
26. Henzler T, Schmid-Bindert G, Schoenberg SO, Fink C. Diffusion and perfusion MRI of the lung and mediastinum. *Eur J Radiol.* 2010;76:329-336. doi:10.1016/j.ejrad.2010.05.005.
27. Lyng H, Haraldseth O, Rofstad EK. Measurement of cell density and necrotic fraction in human melanoma xenografts by diffusion weighted magnetic resonance imaging. *Magn Reson Med.* 2000;43:828-836. doi:10.1002/1522-2594(200006)43:6<828::aid-mrm8>3.0.co;2-p.
28. Durur-Subasi I, Durur-Karakaya A, Karaman A, Seker M, Demirci E, Alper F. Is the necrosis/wall ADC ratio useful for the differentiation of benign and malignant breast lesions. *Br J Radiol.* 2017;90:20160803. doi:10.1259/bjr.20160803.
29. Usuda K, Iwai S, Yamagata A, et al. Relationships and qualitative evaluation between diffusion-weighted imaging and pathologic findings of resected lung cancers. *Cancers (Basel).* 2020;12:E1194. doi:10.3390/cancers12051194.
30. Dubreuil J, Tordo J, Rubello D, Giammarile F, Skanjeti A. Diffusion-weighted MRI and 18F-FDG-PET/CT imaging: competition or synergy as diagnostic methods to manage sarcoma of the uterus? A systematic review of the literature. *Nucl Med Commun.* 2017;38:84-90.
31. Gallivanone F, Panzeri MM, Canevari C, et al. Biomarkers from in vivo molecular imaging of breast cancer: pretreatment 18F-FDG PET predicts patient prognosis, and pretreatment DWI-MR predicts response to neoadjuvant chemotherapy. *MAGMA.* 2017;30:359-373.