

Case Reports

Alien Limb Syndrome Responsive to Amantadine in a Patient with Corticobasal Syndrome

Francisco de Assis Aquino Gondim^{1*}, José Wagner Leonel Tavares Júnior¹, Arlindo A. Morais¹, Paulo Marcelo Gondim Sales¹ & Horta Goes Wagner¹

¹Neurology Division, Hospital Universitário Walter Cantídio, Universidade Federal do Ceará, Fortaleza, Ceará, Brazil

Abstract

Background: Corticobasal syndrome (CBS) is a complex neurodegenerative disorder associated with parkinsonism and alien limb syndrome. Dressing and ideomotor apraxia were reportedly responsive to amantadine.

Case Report: A 79-year-old female was referred for evaluation of right hemiparesis. Neurological examination showed dementia, normal ocular movements, mild facial hypomimia, and bradykinesia with right hemiparesis. Nine years later, she developed alien limb syndrome and was diagnosed with CBS. After failure to respond to several medications, alien limb syndrome markedly improved with amantadine.

Discussion: To the best of our knowledge, this is the first report of a consistent response of severe, forced dystonic alien limb syndrome to amantadine in a patient with CBS.

Keywords: Alien hand syndrome, amantadine, corticobasal syndrome

Citation: Gondim FAA, Tavares JWL, Morais AA, et al. Alien limb syndrome responsive to amantadine in a patient with corticobasal syndrome. *Tremor Other Hyperkinet Mov* 2015; 5. doi:10.7916/D83FaNQ7

*To whom correspondence should be addressed. E-mail: gondimfranc@yahoo.com

Editor: Elan D. Louis, Yale University, USA

Received: March 23, 2015 **Accepted:** May 19, 2015 **Published:** June 23, 2015

Copyright: © 2015 Gondim FAA et al. This is an open-access article distributed under the terms of the Creative Commons Attribution–Noncommercial–No Derivatives License, which permits the user to copy, distribute, and transmit the work provided that the original author(s) and source are credited; that no commercial use is made of the work; and that the work is not altered or transformed.

Funding: This study was supported by research grants from CNPq (Brazilian Research Council) and Universidade Federal do Ceará to Dr. Gondim.

Financial Disclosures: Dr. Gondim has received several research grants from the Brazilian Research Council (CNPq) and travel grants from Novartis, Genzyme, and Biogen. Dr. Horta has received travel grants from Roche, Novartis, and Biogen.

Conflict of Interest: The authors report no conflict of interest.

Introduction

The so-called corticobasal syndrome (CBS) is a complex neurodegenerative movement disorder associated with parkinsonism (variable tremor, rigidity, bradykinesia, and postural instability), dementia, oculomotor abnormalities, dysarthria, apraxia, cortical sensory loss, pyramidal signs, and alien limb syndrome.¹ It can be secondary to diverse histopathologies: corticobasal degeneration, other frontotemporal dementia FTD-related tauopathies such as progressive supranuclear palsy, vascular dementia, and even Alzheimer's disease. To date, there is no known treatment, but dressing and ideomotor apraxia are reportedly responsive to amantadine.²

Alien limb syndrome is defined by the variable combination of different types of observable involuntary motor activity and a feeling of strangeness or foreignness of one limb.³ There is no consensus about its variants, but at least two main subtypes are recognized.³ The so-called

anterior (callosal) variant is associated with apraxia while the posterior variant is characterized by arm levitation.³ Alien limb syndrome in CBS is most commonly associated with limb elevation and abnormal posturing.⁴ Clinical and pathological overlap frequently challenge this classification of anterior and posterior variants.⁴ Here, we will report a patient with CBS and amantadine-responsive alien limb syndrome with some features of both alien limb syndrome subtypes, but predominant symptoms of the posterior variant. The initial findings have been reported in abstract form elsewhere.⁵

Case Report

A 79-year-old right-handed female with diabetes mellitus type 2, hypertension, and dyslipidemia was referred for evaluation of right hemiparesis that started at the age of 77 years. She had been diagnosed with ischemic stroke, but computerized tomography (CT)

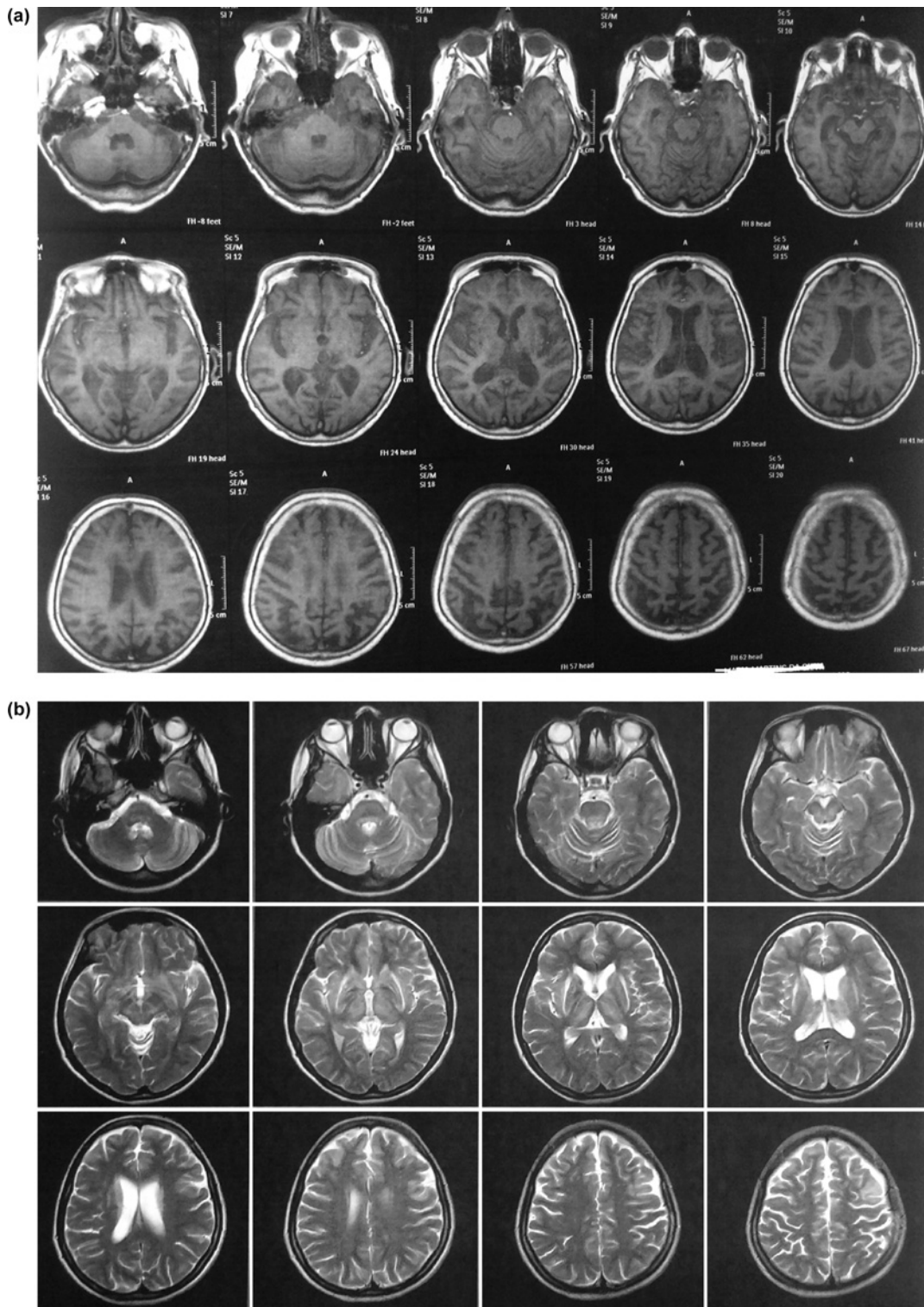


Figure 1. Brain Magnetic Resonance Imaging. (a) The T1 sequence demonstrates generalized atrophy (including significant atrophy of the temporal lobes), more pronounced on the frontal lobes and brainstem, without significant asymmetry or selective midbrain involvement. (b) The T2 sequence also reveals mild, mainly periventricular white matter disease (leukoaraiosis) and lacunar strokes.



Video 1. Segment 1. Before Amantadine Treatment. Forced, painful, retrograde elevation of the right arm. The patient can be seen constantly holding her right arm with her left hand to prevent the alien movement. The video also details the difficulty that the patient experienced performing simple tasks with her right hand, because the right hand was acting on its own. **Segment 2. After Amantadine Treatment.** Although significant right arm paresis is evident, forced arm elevation is minimally evident and she can perform simple tasks with her right arm much better. Occasionally one can see that mild to moderate alien hand symptoms persisted. Significant apraxia is also quite evident, i.e. the patient could not clap her hands and tried but could not show how to comb her hair with her hands.

of the head did not disclose any signs of ischemic or hemorrhagic stroke that could explain her symptoms. Her initial neurological examination showed predominant subcortical dementia, although subsequent testing revealed marked cognitive impairment (serial mini mental examination scores <15 repeatedly over 8 years, although she is illiterate and the cut-off for dementia in illiterate Brazilian populations varies from 13 to 19),⁶ normal ocular movements, mild facial hypomimia, bradykinesia with mild right hemiparesis, mild distal resting tremor, and distal limb atrophy consistent with peripheral neuropathy. Brain magnetic resonance imaging (MRI) was ordered and she was started on levodopa with minimal response (levodopa/benserazide with doses up to 200/50 mg three times a day). The following year, she had a fall and suffered a fracture of the right femur; she became bedridden and later wheelchair-bound. During this time, she could not undergo brain MRI and was treated with amitriptyline for depression/emotional lability. Nerve conduction studies/electromyography (NCS/EMG) revealed axonal sensorimotor peripheral neuropathy. Cognitive decline progressed. She was started on rivastigmine and then galantamine for vascular dementia, without a significant response. Rivastigmine, levodopa, and galantamine were discontinued due to lack of response. Over the last 2 years, she developed right arm dystonia and was seen constantly holding her right hand with her left hand. Brain MRI revealed generalized atrophy (including significant atrophy of the temporal lobes, Figure 1A), multiple lacunar strokes, and leukoaraiosis (mild, mainly periventricular white matter disease, Figure 1B), but no asymmetric hemispheric atrophy (Figures 1A and 1B). Since approximately June 2014 (age 86), she developed severe alien limb syndrome affecting her

right arm. This consisted in frequent episodes of involuntary, forced, retrograde elevation of the right arm leading to constant pain. The act of holding her right hand with her left hand prevented arm elevation (*geste antagonistique* like). As can be seen in Video 1, her last neurological examination did not disclose homonymous hemianopsia, hemianesthesia, right/left disorientation, or intermanual conflict, but she had some features suggestive of anosognosia (although cognitive impairment affected the accurate evaluation of anosognosia) and she was unable to perform complex crossed (lateralized) commands (touch the right ear with her left hand). Alien limb phenomena prevented normal performance of voluntary movements with her right arm, but she did not display grasping, groping, or utilization behaviors (Video 1). She was started on low doses of carbamazepine (up to 200 mg twice a day) and subsequently haloperidol (up to 2 mg every day), without any improvement in arm levitation. However, amantadine 100 mg twice a day led to moderate improvement of the alien limb symptoms, especially of the forced retrograde right arm elevation, as can be seen in Video 1, Segment 2. In her most recent visit (January 2015), she had no alien limb syndrome, but experienced cognitive decline due to a urinary tract infection (delirium). Mental status changes were not related to amantadine use. The patient and her family gave full consent for video recording of the clinical findings. The family was convinced of the improvement in the alien limb symptoms, which had been quite distressing until amantadine was started. Since she had been wheelchair bound for several years, other activities of daily living were not improved by amantadine, except right arm pain, distress, and the ability to perform tasks with her right arm.

Discussion

CBS is a rare disorder with complex phenomenology; it is frequently diagnosed late because of the early absence of its cardinal features. Our patient was initially diagnosed with stroke. However, she had a clinical picture of parkinsonism not responsive to levodopa that progressed to marked gait impairment and subcortical dementia. This led to an initial diagnosis of atypical or Parkinson-plus syndrome. Since brain MRI was not performed until very late, the diagnosis of ischemic stroke and vascular parkinsonism and dementia could not be ruled out. The final diagnosis of CBS possibly due to corticobasal degeneration syndrome (CBGD) was not made until 8–9 years after disease onset, when she developed alien limb syndrome. CBGD is a possible diagnosis considering her clinical history findings, which are not otherwise consistent with progressive supranuclear palsy or Alzheimer's disease. She was also started on rivastigmine and galantamine; dementia was more consistent with a subcortical pattern rather than with Alzheimer's disease, although it still could be a variant of Alzheimer's disease. Brain MRI was not characteristic of CBGD, showing mild white matter disease, leukoaraiosis, and symmetric atrophy (including of the bilateral temporal lobes). Atrophy can be symmetric in CBGD,⁷ but unfortunately cerebral single photon emission CT could not be performed. To the best of our knowledge, this is the first report of a consistent response of severe, forced dystonic alien limb symptoms to amantadine in a patient with CBS. The mechanisms underlying the response of apraxia² or alien limb syndrome to amantadine in CBS patients are still not understood.

Further studies should evaluate the role of amantadine on the management of abnormal motor symptoms in CBS.

References

1. Wolpe N, Moore JW, Rae CL, et al. The medial frontal-prefrontal network for altered awareness and control of action in corticobasal syndrome. *Brain* 2014;137:208–220. <http://dx.doi.org/10.1093/brain/awt302>.
2. Yasuoka T, Ikeda M, Maki N, Hokoishi K, Komori K, Tanabe H. A case of corticobasal degeneration of which movemental disturbances were improved by administration of amantadine. *No To Shinkei* 2001;53:781–785.
3. Gondim FA, Oliveira GR, Cruz-Flores S. Position-dependent levitation of the dominant arm after left parietal stroke: An unreported feature of posterior alien limb syndrome? *Mov Disord* 2005;20:632–633. <http://dx.doi.org/10.1002/mds.20404>.
4. Graff-Radford J, Rubin MN, Jones DT, et al. The alien limb phenomenon. *J Neurol* 2013; 260:1880–1888. <http://dx.doi.org/10.1007/s00415-013-6898-y>.
5. Gondim FAA, Morais AA, Tavares JWL Jr., et al. Alien hand syndrome responsive to amantadine in a patient with corticobasal ganglionic degeneration syndrome. *Arq Neuropsiq* 2014;72:240.
6. Nitrini R, Caramelli P, Bottino CMC, et al. Diagnosis of Alzheimer's disease in Brazil: Cognitive and functional evaluation. Recommendations of the Scientific Department of Cognitive Neurology and Aging of the Brazilian Academy of Neurology. *Arq Neuropsiq* 2005;63:720–727. <http://dx.doi.org/10.1590/S0004-282X2005000400034>.
7. Anhar H, Whitwell JL, Boeve BF, et al. Symmetric corticobasal degeneration. *Parkinsonism Relat Disord* 2010;16:208–214.