

Clinical utility of ozone therapy and hyperbaric oxygen therapy in degenerative disc disease

Kaitlyn Re¹, Jason Gandhi^{1,2}, Raymond Liang¹, Shrey Patel¹, Gunjan Joshi³, Noel L. Smith⁴, Inefta Reid¹, Sardar Ali Khan^{1,5,*}

¹ Department of Physiology and Biophysics, Renaissance School of Medicine at Stony Brook University, Stony Brook, NY, USA

² Medical Student Research Institute, St. George's University School of Medicine, Grenada, West Indies

³ Department of Internal Medicine, Stony Brook Southampton Hospital, Southampton, NY, USA

⁴ Foley Plaza Medical, New York, NY, USA

⁵ Department of Urology, Renaissance School of Medicine at Stony Brook University, Stony Brook, NY, USA

*Correspondence to: Sardar Ali Khan, MD, FACS, FRCS, skysalik@gmail.com.

orcid: 0000-0002-4759-530X (Sardar Ali Khan)

Abstract

Ozone can be medically useful concerning healing wounds and relieving pain in various conditions, such as disc disease. The aspects of human blood ozonation have been reviewed, as well as potential complications that may arise. The mechanisms of ozone therapy are discussed in detail. It is imperative to recognize ozone as a useful proxy in oxidative-stress related diseases, consolidating other medical gases recognized for their therapeutic importance. The utility of hyperbaric oxygen therapy is also discussed. Disc herniation is very common, as more than 3 million cases are treated per year. Herein we review the medical, surgical, and gene-based therapies that ozone therapy can provide regarding disc disease.

Key words: disc degeneration; disc disease; disc herniation; healing; hyperbaric oxygen therapy; ozone therapy; silent electron discharge

doi: 10.4103/2045-9912.351890

How to cite this article: Re K, Gandhi J, Liang R, Patel S, Joshi G, Smith NL, Reid I, Khan SA. Clinical utility of ozone therapy and hyperbaric oxygen therapy in degenerative disc disease. *Med Gas Res.* 2023;13(1):1-6.

INTRODUCTION

Pain associated with the back and lower region of the body is commonly attended to amongst a majority of the population, about 80%. Pain amongst the body as a result of a lumbar disc herniation directly negatively affects the quality of life and longevity of the patient. Discogenic pain as a result of intervertebral disc (IVD) degeneration (IDD) is a major cause of disability in the United States. It was reported that higher than half of the population older than 50 years old suffer from periods of back pain.¹ Most commonly, the L5–S1 nerve roots level is the source of the pain. The L5–S1, also known as the lumbosacral joint is a term used to characterize the part of the spine that is composed of the last bone in the lower back, known as the L5 and the bone directly beneath the spine, the sacrum. L5–S1 is the exact location where the lumbar spine ends and the sacral spine begins. The lumbosacral joint connects these two bones.²

Ozone therapy works to decrease the pain within the lumbosacral joint by dehydration. Surgical treatment of discectomy is a viable option, in which the degenerated disc is removed succeeded by the fusion of the adjacent vertebrae. Although this approach manages pain, it severely decreased spinal mobility, which becomes an issue for patients who depend upon treatment of multiple disc levels.³

SEARCH STRATEGY

An extensive literature search was performed on Medline using the search queries “ozone therapy,” “hyperbaric oxygen therapy,” and “disc disease.” Although there was no date restriction on the search, we placed an emphasis on the past 5 years. No specific exclusion criteria were set. Publication

quality was assessed using the relative citation ratio derived from iCite bibliometrics. We selected papers that revealed information regarding ozone therapy and hyperbaric oxygen therapy and its use in the clinic.

BACKGROUND OF HYPERBARIC OXYGEN AND OZONE

Hyperbaric oxygen therapy (HBOT) allows for increased oxygen flow to tissues in our body. It promotes wound healing and minimizes typical recovery times.⁴ HBOT is defined as the allocation of oxygen at pressures greater than 1.4 atm. These allocations are performed in a series of treatments.⁵ With HBOT, the patient is directed to stand inside a hyperbaric chamber. It is used for wound care in patients within conventional and dental medicine.⁶ HBOT operates by manipulation of physiological principles of gases under pressure. There is a direct, linear relationship between the concentration of oxygen in dissolved liquid and the diffusion gradient. An increase in oxygen concentration dissolved in solution allows for a rise in the diffusion gradient for tissue delivery. According to Henry's Gas Law, the concentration of gas dissolved in liquid is proportional to the partial pressure of that gas above the liquid at constant temperatures.⁷ Upon conclusion of treatment, oxygen tension decreases, allowing for the accumulation of neutrophils. These neutrophils are a subset of white blood cells and act quickly in fighting infection and regrowing tissue.⁸ Conclusively, HBOT may alter tissue response to diseases and injuries, and may even prevent amputation or death.⁹ HBOT is commonly used at a compression rate of 0.067 atmospheres absolute per minute. However, a study concluded that pressure equalization could lead to middle ear, teeth, and cranial sinus pain. It is recommended that patients who suffer from peripheral circulatory



disorders should be treated with special care.¹⁰

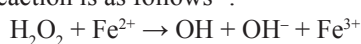
The use of ozone as an advocate for healing has been broadly studied for decades. Ozone was initially identified as a gas containing three relatively unstable oxygen molecules in a mesmeric state, a conjugated system. The gas is colorless and stable, whereas the solid and liquid form is very explosive. Ozone has a half-life of 40 minutes and 140 minutes at temperatures of 20°C and 0°C, respectively. To date, ozone is known to treat many diseases. The most prominent function of ozone is to protect humans from ultraviolet radiation and its potentially harmful effects. Medical grade oxygen has various health benefits: reduced dental caries, decreases blood pressure and cholesterol, modifies oxygenation in resting the muscle, and stimulation of antioxidative responses.¹¹

MECHANISM OF OZONE THERAPY

The mechanism of ozone therapy requires the inactivation of bacteria, fungi, viruses, yeast, and protozoa. Through oxidation of the phospholipids and lipoproteins, ozone therapy deranges the integrity of the bacterial cell envelope. However, in viruses, ozone works to damage the viral capsid and disrupts the reproductive cycle by punctuating the virus-to-cell contact with peroxidation, the oxidative degradation of lipids.¹² In this case, free radicals thief electrons from the lipids in cell membranes, thus damaging the cell. This mechanism is broken into two steps: Initiation and propagation. This process provides a weak coating on the cells which aids the attack by virus invasion as they are not susceptible to oxidation and elimination from the body, where healthy cells are brought in to replace them.¹³

Ozone therapy was concluded to aid in the red blood cell glycolysis rate. As a result, there is a significant stimulation of the 2,3-diphosphoglycerate thus increasing the amount of oxygen released to the tissues. Through the enhancement of oxidative carboxylation of pyruvate, resulting in a stimulation of ATP, ozone activates the citric acid cycle. Ozone aids in oxidizing cytochrome C, thus resulting in a significant reduction in nicotinamide adenine dinucleotide. There is an increase in the number of enzymes which scavenge free radicals and protect cell walls. Some examples include glutathione, peroxidase, catalase, and superoxide dismutase. Production of prostacyclin, a vasodilator, is also prompted by ozone.¹⁴

The production of lipid ozonation products via the inhalation of oxygen occurs when the polyunsaturated fatty acids, found in the lipids of the alveolar lining layer. There is also the potential for ozone to react with unsaturated fatty acids to manufacture Criegee ozonide in the nonattendance of the production of lipid ozonation products via the inhalation of oxygen occurs when the polyunsaturated fatty acids, found in the lipids of the alveolar lining layer. There is also the potential for ozone to react with unsaturated fatty acids to manufacture Criegee ozonide in the nonattendance of H₂O. Although, when H₂O is available, the body will produce and release aldehydes and hydrogen peroxide (H₂O₂). The main reaction with ozone will be the formation of aldehydes and hydrogen peroxide as the pulmonary system has H₂O readily available. The net reaction is as follows¹⁵:



APPLICATION OF OZONE

Medical ozone is administered as a combination of ozone and oxygen through the mechanism of silent electron discharge. It is most common within a concentration range of 0.05% ozone to maximum 5.0% ozone. In doing so, the combination of medical ozone and oxygen is orchestrated with the avoidance of the exposure of the respiratory tract, to minimize the potential toxic effects on the pulmonary epithelium.¹⁶

Silent electron discharge

Silent electron discharge occurs in the air at a very high voltage and consumes a relatively large amount of energy in doing so. Ozone is produced in high density by passing dry air between two concentric-tube or plate electrodes connected to an alternating high voltage known as silent electron discharge method.¹⁷ The reaction is initiated by sparkles or silent electric discharge, to produce less heat in prevention of ozone decomposition into oxygen. Hence, ozone is prepared in an apparatus known as an ozonizer for facilitation of these existing conditions.¹⁸

Classifying intervertebral disc changes

According to the collective endeavor of the North American Spine Society, American Society of Spine Radiology, and American Society of Neuroradiology, changes associated with the IVD can be classified as either herniation or degeneration. Degeneration can be categorized into many subgroups – bulging of the annulus, complications in the endplate (EP), fissuring, fibrosis, narrowing of the disc height, and more. A herniation is a displacement of IVD material. Herniation encompasses all components of the IVD. The EP of the vertebral bodies defines the IVD space, while the outer portion of the vertebra ring apophyses define the peripheral region.¹⁹ Herniations are arranged according to two groups: broad-based and circumferential.¹⁹

Intervertebral disc degeneration

IDD is known to be a prominent cause of back pain. IVD is made of fibrocartilaginous connective tissue located between two adjoined vertebrae. IVD contains three components: the nucleus pulposus (NP), the annulus fibrosus (AF) which surrounds the NP, and two cartilage EPs. These EPs provide an interface between the vertebrae and the disc by cranially covering both the NP and AF at the same time. The main function of IVD is to provide limited flexibility to the lower half of the body, protect the spinal nerve and spinal cord, and ensure mechanical stability during axial motion and compression.²⁰

IDD occurs naturally as aging progresses.²¹ Various experimental risk factors can contribute to the effect of IDD that is experienced: an unhealthy lifestyle, a poor diet, lack of exercise, smoking, mechanical and occupational exposures, and heavy lifting. The initial response can be verified as necessary inflammation of the tissues in the disc, the gradation of the NP and AF, and the decreased viability of the resident cells. As a result, the IVD can be classified as aberrant innervation through the prolapse or herniation of the NP outside a fissured AF, or the complete demolition of the NP inside the AF.²² The tissues become inflamed in the peridiscal space and the



degenerating IVD upon IDD. Studies on disc samples with varying degrees of degeneration have been performed to analyze the expression or secretion in the tissue once placed into the culture medium of pro-inflammatory factors during IDD.²³ As a result, it was proved that healthy and degenerated tissues contain increased inflammatory cytokines and chemokines produced by IVD cells as well as circulating immune cells. Activated immunocytes include macrophages, T and B cells, and natural killer cells.²⁴ These are activated as a result of the expression of chemokines by IVD cells, and are prolonged by the miniscule structural integrity of the disc extracellular matrix located in the outer AF. Inside the disc tissues, the inflammation is enhanced when the inflammatory mediator producing immune cells in the IVD lacks a resident cell population in physiological conditions.²⁵ The inception of the inflammatory conditions inside the degenerating IVD initiates pathogenic responses such as cell apoptosis, matrix destruction, and nerve and vascular ingrowth. Studies show that the following events activate a massive degeneration and could potentially cause pain.²⁶

COMPOSITION OF NORMAL INTERVERTEBRAL DISCS

The IVD is composed of cartilaginous vertebral EPs, AF, and NP.²⁷ Regarding the whole disc, the EPs are located in the superior and inferior parts of the drive. The AF is composed of the inner and outer layer which contain different anatomies. The structure of the outer annulus is collagenous concentric lamellae. This is organized into cells that produce type I collagen. The inner annulus is fibrocartilaginous, composed of type I and type II collagen. The AF experiences strain when a tensile force deforms the relative length of the specimen. The NP lies within the AF. Healthy NP is gelatinous in nature and mostly composed of proteoglycans. Proteoglycans have a protein containing keratin and chondroitin sulfate. These proteins are hydrophilic and allow for counteraction of compressive loading of the spine. This is a result of the hydrostatic properties governing the NP.²⁸ Although the NP is highly cellular, it lacks proteoglycans during the early stages. Eventually, extracellular proteoglycans become abundant with minute cells. Many NP cells are large vacuolated cells in infancy and may be of notochordal origin. The proportion of these cells is diminished dramatically with the associated increase in the chondrocyte-like cell in adult NP tissue. Notochordal cells play a pivotal role in stimulating the synthesis of glycosaminoglycans and proteoglycans by NP cells. These cells may also serve as precursor cells to preserve and control the number of NP cells.²⁹ The loss of notochordal cells has intense effects concerning the overall disc quality as a result of these anabolic effects.³⁰ A herniated disc is the condition in which the AF, the outer portion, of the IVD is torn, thus enabling the NP, the inner portion, to herniate or extrude through the fibers.³¹ Adequate studies show 29% of the adult population in the United States is affected by pain resulting from disc herniation.³² Structural impairments such as fissures and cracks within the AF could potentially allow the NP material to prolapse and the disc to herniate, thus leading to constriction of root ganglion nerves and bring upon the severity of pain.³³

A discectomy is a surgery to remove lumbar herniated disc material that is pressing on a nerve root or the spinal cord. Often, a microdiscectomy is performed, in which a special microscope is used to view the disc and nerves. Discectomy tends to result in reduced tissue invasiveness, limited blood loss, a shorter duration of surgery and a faster postoperative recovery in comparison to other procedures done to treat lumbar disc herniation.³⁴ The foraminal cervical disc herniation is better approached from the opposite side. For a midline herniation, the best approach is from the right side by a right-handed surgeon and the left side by a left-handed surgeon.³⁵

WHY DO DISCS HERNIATE?

A lack of homeostatic balance within a catabolic metabolic profile directly leads to IDD.³⁶⁻³⁸ Long term accumulative stress can lead to progressive degenerative changes, also referred to as disc herniation. Disc herniation can also bear from a sudden injury or trauma. Sudden jerking movement of the body can put too much pressure on the disc, causing it to herniate. Under these circumstances, the development and activation of IDD lead to changes in the cell; thus long term weakening the disc structure. The AF undergoes myxomatous degeneration and cyst formation. The myxomatous is damaged due to non-inflammatory mechanisms.³⁹ The damaging of the myxomatous and cyst formation effectuates the swelling of the AF fibers, indirectly causing disorganization and disruption of fiber bundles.^{40,41}

The NP will bear changes of dehydration, fibrosis, and necrosis. The NP is exposed to potential herniation preceding exorbitant pressure and loading. The NP herniation results in annual tears, as a result of the weakened AF, fissures in the vertebral EPs, or the severance of the vertebral EP junction.²⁹

EFFECT OF AGING ON DISC DEGENERATION

In brief, IDD corresponds to biochemical changes within the body followed by macroscopic alterations, tears, and fissures. An IVD is a stable ligament that connects one vertebral bone to the next. IVDs have evolved to contain a durable outer ring of fibers, commonly referred to the AF, which connects each vertebra. The predominance of the AF makes it so susceptible to tears and strain. A majority of damages resulting from the natural aging process, as the neck and back bear preponderance of the human body weight.⁴²

STAGES OF DISC DEGENERATION

There are four stages of disc degeneration: (1) disc protrusion, (2) prolapsed disc, (3) disc extrusion, and (4) sequestered disc. Stages 1 and 2 are commonly considered incomplete, whereas stages 3 and 4 are complete herniations.⁴³

Degenerative disc disease stage 1

The initial manifestation of disc degeneration is that the spine loses its traditional balance. The joints and nerves become stressed and begin to age more rapidly. It has been reported that in some cases there is a lack of overall energy and even a potential loss of height. It is also common for there to be very little pain or discomfort at the stage in the herniation process.⁴⁴



Degenerative disc disease stage 2

As the condition retrogrades, there is a higher degree of disc decay, as the discs begin to narrow and bone spurs become more readily available. At this point, the changes in posture appear to be more evident as the spinal canal begins to close. There is an increase in the level of pain and discomfort and height can continue to decrease.

Degenerative disc disease stage 3

At this point, the posture is substantially altered. The thinning of the discs worsen, thus potentially leading to severe nerve damage and formation of scar tissue across the area. These complications can harm the patients physical and mental condition, as there is a profound loss of energy.⁴⁵

Degenerative disc disease stage 4

Stage 4 is classified with severe damage to the spine. Discal thinning is at the maximum potential or could be completely nonexistent. The postural imbalance is acute, and motion and flexibility are minimal. Patients are likely to suffer from profound nerve damage, while the bones begin to fuse as a result of the formation of permanent scar tissue. The level of pain is highly increased, thus leading to progressive physical and mental deterioration. Stage 4 is irreversible despite the level of treatment applied.⁴⁶

COMPLICATIONS OF OZONE USE

Due to ozone's unstable nature, it is challenging to produce and store long term. This is a significant limitation to its extensive use. The production of ozone is quite simplified. Ozone is produced naturally when sunlight meets the oxygen in the air. However, various chemicals work to dismantle the compound, such as chlorofluorocarbons. When chlorofluorocarbons reach the upper atmosphere, they are exposed to ultraviolet rays which cause them to deplete into substances, for example, chlorine. The chlorine reacts with oxygen atoms in the ozone and rips apart the ozone molecule. One molecule of chlorine has the potential to destroy more than one hundred thousand ozone molecules.⁴⁷ Therefore, it is impractical to manufacture large quantities of ozone and store it. If the production of ozone is necessary, as it is here, it is common to install generators and produce the ozone as needed. By doing so, it incorporates the mechanism of injecting oxygen in air form or pure oxygen form, and subjecting it to a high voltage electric discharge. Thus the spark creates ultraviolet light that detaches the oxygen molecule O_2 , into two oxygen ions. As a result, the two oxygen molecules will react with another one to make ozone.⁴⁸

IMPACT OF HYPERBARIC OXYGEN THERAPY

Anti-inflammatory effects of hyperbaric oxygen therapy in animals

The initial response the human body has to infection, injury, or irritation is inflammation. This is provoked through the regulation of various inflammatory cytokines, known to be nitrous oxide, interleukins, non-cytokine mediator, prostaglandin E2, and more.⁴⁹ Inflammatory mediators recruit leukocytes to the inflammation site and activate blood vessels. Blood inflow is

manifested by redness and swelling. Compression of nerve endings elicits pain. The latter combined with altered mechanical properties or organs may disturb their function. Swelling results in impaired oxygen tissue supply and glycolytic shift with lowered pH. Local tissue acidification is also related to pain.⁵⁰ HBOT has the potential to decrease the inflammatory response proceeding injury, such as a disc herniation, proved by an adequate amount of studies. The measurement of decreased paw edema following injury is indicative of this statement, as per the study conducted by Sutherland et al.⁵¹

TREATMENT OF DISC DISEASE

Medical management

Medical treatment for IDD varies depending upon the severity and the health condition the patient is currently in. Treatment may include occupational and/or physical therapy, medications, and losing weight. Most commonly doctors alleviate the pain by injecting the joints with steroids and an anesthetic, known as facet joint injections. Lumbar facet joints are paired synovial joints between the fifth lumbar vertebra and the sacrum. Facet joint pain is defined as pain that arises from any structure that is part of the facet joints. This pain is typically treated with the injections discussed above, despite the concern that they are not standardized.⁵²

Facet rhizotomy is another option, where a radiofrequency current deadens the nerves around the facet joint. The purpose of a facet rhizotomy injection is to provide pain relief by disabling the sensory nerve. In this procedure, a needle with a probe is inserted outside of the joint. The examination is then heated with radio waves and applied to the sensory nerve to the joint to disable the nerve. The theory is that by deactivating the sensory nerve, a facet rhizotomy prevents the pain signals from reaching the brain. Adequate studies prove that a facet rhizotomy injection is successful in providing pain relief for roughly half of all patients.⁵³

Surgical management

The two main surgical procedures for lumbar IDD are lumbar fusion: traditional standard surgical treatment and lumbar disk arthroplasty, or lumbar total disk replacement. The goal of lumbar fusion is to relieve pain by creating a sturdy interbody union.⁵⁴

Lumbar interbody fusion is a surgery used to correct small bones in the vertebrae. The basic idea is to fuse two or more vertebrae. The purpose of this is to restore stability to the spine by eliminating painful motion.⁵⁵ Degenerative changes within a lumbar spine motion are best depicted by the presence of tears or fissures in the AF, disc space desiccation and collapse, and the formation of radial osteophytes.⁵⁶ The following morphological changes within the spinal motion segment will inevitably lead to the inability of the IVD to handle normal stresses, thus causing pain.⁵⁷ Fusion of the degenerative and unstable spinal motion segment can give notable relief.

Other solutions

A study done by Magalheas et al.⁵⁸ concludes that there is a direct positive relationship between ozone therapy and the treatment of chronic low back pain. The group of scientists



found this theory by injecting ozone into the disc and the perforaminum within the posterior lateral hypothalamus and or at the paravertebral muscles located along the dorsal spine. 74% of 86 patients with disc disease reported having complete remission of pain preceding the treatment stated above.⁵⁸

A study was done with steroids to compare the results: Among 306 patients, Bonetti et al.⁵⁹ noted that 58% containing disc disease treated with steroids depicted positive results. This experiment also concluded that 63% of 70 patients that did not undergo disc disease at this particular time showed positive results after steroid infiltration.⁵⁹

Overall, Gallucci et al.⁶⁰ concluded that there was the highest success rate with ozone therapy combined with intraforaminal and intradiscal steroid and anesthetic injection compared to steroid or ozone therapy alone, as expected. A study was done by Gallucci et al.⁶⁰ with the intention of understanding the effectiveness of intraforaminal and intradiscal injections containing a mixture of a steroid, a local anesthetic, and oxygen-ozone, also known as chemodiscolysis in comparison to intraforaminal and intradiscal injections of a steroid and a local anesthetic regarding their ability to manage pain related to acute lumbar disc herniation. After running this experiment for six months, they concluded that the treatment containing ozone therapy in conjunction to the local anesthetics and steroids had a 74% success rate whereas the treatment independent of ozone therapy had a minor success rate of 47%. The results obtained indicate a significant difference ($P < 0.01$).⁶⁰

Zambello et al.⁶¹ conducted an experiment with 351 patients that suffered with lower back pain with the intention of preventing the discredit of patients who fail to respond to treatment after a 4 week period of time by treating all patients with either ozone therapy or epidural steroid injection and successfully crossed over during the follow up to those who did not respond as expected to the initial treatment. The overall results concluded to be notable within 47.3% of 171 patients treated exclusively with epidural steroids and within 77.1% of 180 patients treated with oxygen-ozone therapy. 11/351 total patients who were initially treated with ozone therapy were subjected to crossover with epidural steroids whereas 38/351 patients initially treated with epidural steroid injections were submitted to crossover and received ozone therapy treatment. As a result, only 36.4% of patients who underwent a secondary injection displayed notable alleviation of pain whereas 70.8% of patients who underwent secondary oxygen therapy reported complete reduction. Based off of these results, it can be determined that ozone therapy is more successful in targeting lower back pain within four weeks in comparison to epidural injection.⁶¹

IMPACT OF OZONE ON DISC DISEASE

Degenerative disc disease is best known as the condition which a damaged vertebral disc causes chronic pain in various parts of the body, such as the lower back, legs, within the lumbar spine, neck, arm and or the cervical spine. This condition is irreversible and progressive, as it begins to worsen and symptoms increase with aging.⁶² With aging, the strength, flexibility, and health of the spine's IVDs are significantly altered. Balance, stability, and equilibrium are imperative for

a healthy drive. When equilibrium is deranged, a variety of catabolic events on a molecular level are disrupted, leading to the increase in production of cytokines, increased production of enzymes, and a loss of matrix proteins.⁶³ Ozone works by reacting with the polyunsaturated fatty acids; thus, catalyzing oxidative mediators. H_2O_2 is produced as a result of this method of action. Thus, the nuclear factor erythroid 2-related factor 2 pathways were initiated and catalyzed as indicated by the translocation within the nucleus as it increases the heme oxygenase-1 gene expression.⁶⁴

CONCLUSION

IVD occurs when the AF pushes out through a tear in the more robust exterior within the spine, manifestation as herniated disc. Ozone therapy and HBOT are both increasingly popular methods to target the inflammation arising from the pathologic disc process. The goal is to minimize symptoms such as low back pain.

Acknowledgements

The authors are thankful to Drs. Kelly Warren, Todd Miller, and Peter Brink from Department of Physiology and Biophysics, Renaissance School of Medicine at Stony Brook University, Stony Brook, NY, USA for departmental support, as well as Mrs. Wendy Isser and Ms. Grace Garey from Northport VA Medical Center Library, Northport, NY, USA for literature retrieval.

Author contributions

KR designed, organized, and wrote the review article; designed the outline; solved queries related to scientific publications from the journals. JG performed Medline searches, aided in writing, and critiqued the literature. RL revised the article to add logical reasoning and corrected the literature. SP and GJ critiqued and applied logical reasoning to the literature. NLS, IR, and SAK formulated clinical concepts, reviewed the article, and corrected the reference. All authors have read and approved a manuscript provided.

Conflicts of interest

The authors have no conflicts of interest to declare.

Open access statement

This is an open access journal, and articles are distributed under the terms of the Creative Commons AttributionNonCommercial-ShareAlike 4.0 License, which allows others to remix, tweak, and build upon the work non-commercially, as long as appropriate credit is given and the new creations are licensed under the identical terms.

REFERENCES

- Hassett G, Hart DJ, Manek NJ, Doyle DV, Spector TD. Risk factors for progression of lumbar spine disc degeneration: the Chingford study. *Arthritis Rheum.* 2003;48:3112-3117.
- Sicard A. Abnormalities of the lumbosacral joint. *Presse Med.* 1950;58:1112-1113.
- Olson EJ, Hanley EN, Jr., Rudert MJ, Baratz ME. Vertebral column allografts for the treatment of segmental spine defects. An experimental investigation in dogs. *Spine (Phila Pa 1976).* 1991;16:1081-1088.
- Hexdall E, Brave R, Kraft K, Siewers J. Diving deep into hyperbaric oxygen therapy. *Nursing.* 2016;46:28-36.
- Lam G, Fontaine R, Ross FL, Chiu ES. Hyperbaric oxygen therapy: exploring the clinical evidence. *Adv Skin Wound Care.* 2017;30:181-190.
- Carney AY. Hyperbaric oxygen therapy: an introduction. *Crit Care Nurs Q.* 2013;36:274-279.
- Gerth WA. Applicability of Henry's law to hydrogen, helium, and nitrogen solubilities in water and olive oil at 37 degrees C and pressures up to 300 atmospheres. *Arch Biochem Biophys.* 1985;241:187-199.
- Devaraj D, Srisakthi D. Hyperbaric oxygen therapy - can it be the new era in dentistry? *J Clin Diagn Res.* 2014;8:263-265.
- Edwards ML. Hyperbaric oxygen therapy. Part 1: history and principles. *J Vet Emerg Crit Care (San Antonio).* 2010;20:284-288.
- Leopardi LN, Metcalfe MS, Forde A, Maddern GJ. Ite Boerema-surgeon and engineer with a double-Dutch legacy to medical technology. *Surgery.* 2004;135:99-103.



11. Pankhurst CL, Scully C, Samaranyake L. Dental unit water lines and their disinfection and management: a review. *Dent Update*. 2017;44:284-285, 289-292.
12. Mizuno H, Roy AK, Zaporozhan V, Vacanti CA, Ueda M, Bonassar LJ. Biomechanical and biochemical characterization of composite tissue-engineered intervertebral discs. *Biomaterials*. 2006;27:362-370.
13. Smith NL, Wilson AL, Gandhi J, Vatsia S, Khan SA. Ozone therapy: an overview of pharmacodynamics, current research, and clinical utility. *Med Gas Res*. 2017;7:212-219.
14. Almaz ME, Sönmez I. Ozone therapy in the management and prevention of caries. *J Formos Med Assoc*. 2015;114:3-11.
15. Sagai M, Bocci V. Mechanisms of action involved in ozone therapy: is healing induced via a mild oxidative stress? *Med Gas Res*. 2011;1:29.
16. Re L, Mawsouf MN, Menéndez S, León OS, Sánchez GM, Hernández F. Ozone therapy: clinical and basic evidence of its therapeutic potential. *Arch Med Res*. 2008;39:17-26.
17. Dudek FE, Andrew RD, MacVicar BA, Hatton GI. Intracellular electrophysiology of mammalian peptidergic neurons in rat hypothalamic slices. *Fed Proc*. 1982;41:2953-2958.
18. Voloschin LM, Décima E, Tramezzani JH. Electronmicroscopic and electrophysiological studies of the test branch of the XIII thoracic nerve: relationship with lactation in the rat. *J Endocrinol*. 1988;118:471-483.
19. Fardon DF, Milette PC. Nomenclature and classification of lumbar disc pathology. Recommendations of the combined task forces of the North American Spine Society, American Society of Spine Radiology, and American Society of Neuroradiology. *Spine (Phila Pa 1976)*. 2001;26:E93-113.
20. Raj PP. Intervertebral disc: anatomy-physiology-pathophysiology-treatment. *Pain Pract*. 2008;8:18-44.
21. Virtanen IM, Karppinen J, Taimela S, et al. Occupational and genetic risk factors associated with intervertebral disc disease. *Spine (Phila Pa 1976)*. 2007;32:1129-1134.
22. Smith LJ, Nerurkar NL, Choi KS, Harfe BD, Elliott DM. Degeneration and regeneration of the intervertebral disc: lessons from development. *Dis Model Mech*. 2011;4:31-41.
23. Takahashi H, Suguro T, Okazima Y, Motegi M, Okada Y, Kakiuchi T. *Inflammatory cytokines in the herniated disc of the lumbar spine*. *Spine (Phila Pa 1976)*. 1996;21:218-224.
24. Geiss A, Larsson K, Rydevik B, Takahashi I, Olmarker K. Autoimmune properties of nucleus pulposus: an experimental study in pigs. *Spine (Phila Pa 1976)*. 2007;32:168-173.
25. Shamji MF, Setton LA, Jarvis W, et al. Proinflammatory cytokine expression profile in degenerated and herniated human intervertebral disc tissues. *Arthritis Rheum*. 2010;62:1974-1982.
26. Huang KY, Lin RM, Chen WY, Lee CL, Yan JJ, Chang MS. IL-20 may contribute to the pathogenesis of human intervertebral disc herniation. *Spine (Phila Pa 1976)*. 2008;33:2034-2040.
27. Lotz JC, Hsieh AH, Walsh AL, Palmer EI, Chin JR. Mechanobiology of the intervertebral disc. *Biochem Soc Trans*. 2002;30:853-858.
28. Urban JP, Maroudas A. Swelling of the intervertebral disc in vitro. *Connect Tissue Res*. 1981;9:1-10.
29. Rajasekaran S, Bajaj N, Tubaki V, Kanna RM, Shetty AP. ISSLS Prize winner: The anatomy of failure in lumbar disc herniation: an in vivo, multimodal, prospective study of 181 subjects. *Spine (Phila Pa 1976)*. 2013;38:1491-1500.
30. Risbud MV, Shapiro IM. Notochordal cells in the adult intervertebral disc: new perspective on an old question. *Crit Rev Eukaryot Gene Expr*. 2011;21:29-41.
31. Amin RM, Andrade NS, Neuman BJ. Lumbar disc herniation. *Curr Rev Musculoskelet Med*. 2017;10:507-516.
32. Aichmair A, Du JY, Shue J, et al. Microdiscectomy for the treatment of lumbar disc herniation: an evaluation of reoperations and long-term outcomes. *Evid Based Spine Care J*. 2014;5:77-86.
33. Kirkaldy-Willis WH, Farfan HF. Instability of the lumbar spine. *Clin Orthop Relat Res*. 1982;110-123.
34. Goald HJ. Microlumbar discectomy: follow-up of 477 patients. *J Microsurg*. 1980;2:95-100.
35. Carette S, Fehlings MG. Clinical practice. Cervical radiculopathy. *N Engl J Med*. 2005;353:392-399.
36. Battié MC, Videman T, Gill K, et al. 1991 Volvo Award in clinical sciences. Smoking and lumbar intervertebral disc degeneration: an MRI study of identical twins. *Spine (Phila Pa 1976)*. 1991;16:1015-1021.
37. Boos N, Weissbach S, Rohrbach H, Weiler C, Spratt KF, Nerlich AG. Classification of age-related changes in lumbar intervertebral discs: 2002 Volvo Award in basic science. *Spine (Phila Pa 1976)*. 2002;27:2631-2644.
38. Buckwalter JA, Smith KC, Kazarian LE, Rosenberg LC, Ungar R. Articular cartilage and intervertebral disc proteoglycans differ in structure: an electron microscopic study. *J Orthop Res*. 1989;7:146-151.
39. Martins CO, Demarchi L, Ferreira FM, et al. Rheumatic heart disease and myxomatous degeneration: differences and similarities of valve damage resulting from autoimmune reactions and matrix disorganization. *PLoS One*. 2017;12:e0170191.
40. Gordon SJ, Yang KH, Mayer PJ, Mace AH, Jr., Kish VL, Radin EL. Mechanism of disc rupture. A preliminary report. *Spine (Phila Pa 1976)*. 1991;16:450-456.
41. Kuga N, Kawabuchi M. Histology of intervertebral disc protrusion: an experimental study using an aged rat model. *Spine (Phila Pa 1976)*. 2001;26:E379-384.
42. Nerurkar NL, Baker BM, Sen S, Wible EE, Elliott DM, Mauck RL. Nano-fibrous biologic laminates replicate the form and function of the annulus fibrosus. *Nat Mater*. 2009;8:986-992.
43. Karademir M, Eser O, Karavelioglu E. Adolescent lumbar disc herniation: impact, diagnosis, and treatment. *J Back Musculoskelet Rehabil*. 2017;30:347-352.
44. Jordan J, Konstantinou K, O'Dowd J. Herniated lumbar disc. *BMJ Clin Evid*. 2011;2011.
45. Lachman D. Analysis of the clinical picture in patients with osteoarthritis of the spine depending on the type and severity of lesions on magnetic resonance imaging. *Reumatologia*. 2015;53:186-191.
46. Gunasekaran A, de Los Reyes NKM, Walters J, Kazemi N. Clinical presentation, diagnosis, and surgical treatment of spontaneous cervical intradural disc herniations: a review of the literature. *World Neurosurg*. 2018;109:275-284.
47. Bais AF, McKenzie RL, Bernhard G, et al. Ozone depletion and climate change: impacts on UV radiation. *Photochem Photobiol Sci*. 2015;14:19-52.
48. Braidy N, Izadi M, Suredda A, et al. Therapeutic relevance of ozone therapy in degenerative diseases: Focus on diabetes and spinal pain. *J Cell Physiol*. 2018;233:2705-2714.
49. Zhu F, Du B, Xu B. Anti-inflammatory effects of phytochemicals from fruits, vegetables, and food legumes: A review. *Crit Rev Food Sci Nutr*. 2018;58:1260-1270.
50. Kuprash DV, Nedospasov SA. Molecular and cellular mechanisms of inflammation. *Biochemistry (Mosc)*. 2016;81:1237-1239.
51. Sutherland AM, Clarke HA, Katz J, Katznelson R. Hyperbaric oxygen therapy: a new treatment for chronic pain? *Pain Pract*. 2016;16:620-628.
52. Snidvongs S, Taylor RS, Ahmad A, et al. Facet-joint injections for non-specific low back pain: a feasibility RCT. *Health Technol Assess*. 2017;21:1-130.
53. Lee CH, Chung CK, Kim CH. The efficacy of conventional radiofrequency denervation in patients with chronic low back pain originating from the facet joints: a meta-analysis of randomized controlled trials. *Spine J*. 2017;17:1770-1780.
54. Schnake KJ, Rappert D, Storzer B, Schreyer S, Hilber F, Mehren C. Lumbar fusion-Indications and techniques. *Orthopade*. 2019;48:50-58.
55. Yavin D, Casha S, Wiebe S, et al. Lumbar fusion for degenerative disease: a systematic review and meta-analysis. *Neurosurgery*. 2017;80:701-715.
56. Frantzides CT, Zeni TM, Phillips FM, et al. L5-S1 laparoscopic anterior interbody fusion. *JSL*. 2006;10:488-492.
57. Crock HV. Anterior lumbar interbody fusion: indications for its use and notes on surgical technique. *Clin Orthop Relat Res*. 1982:157-163.
58. Magalhaes FN, Dotta L, Sasse A, Teixeira MJ, Fonoff ET. Ozone therapy as a treatment for low back pain secondary to herniated disc: a systematic review and meta-analysis of randomized controlled trials. *Pain Physician*. 2012;15:E115-129.
59. Bonetti M, Fontana A, Cotticelli B, Volta GD, Guindani M, Leonardi M. Intraforaminal O(2)-O(3) versus periradicular steroid infiltrations in lower back pain: randomized controlled study. *AJNR Am J Neuroradiol*. 2005;26:996-1000.
60. Gallucci M, Limbucci N, Zugaro L, et al. Sciatica: treatment with intradiscal and intraforaminal injections of steroid and oxygen-ozone versus steroid only. *Radiology*. 2007;242:907-913.
61. Zambello A, Fara B, Tabaracci G, Bianchi M. Epidural steroid injection vs paravertebral O2 O3 infiltration for symptomatic herniated disc refractory to conventional treatment a prospective randomized study. *J Ital Oxygen Ozone Ther*. 2006;5:123-127.
62. Hemanta D, Jiang XX, Feng ZZ, Chen ZX, Cao YW. Etiology for degenerative disc disease. *Chin Med Sci J*. 2016;31:185-191.
63. Kadow T, Sowa G, Vo N, Kang JD. Molecular basis of intervertebral disc degeneration and herniations: what are the important translational questions? *Clin Orthop Relat Res*. 2015;473:1903-1912.
64. Valacchi G, Sticozzi C, Zanardi I, et al. Ozone mediators effect on "in vitro" scratch wound closure. *Free Radic Res*. 2016;50:1022-1031.

Date of submission: August 27, 2019

Date of decision: September 23, 2019

Date of acceptance: October 28, 2019

Date of web publication: July 24, 2022