



Case report

Colonic pseudo-obstruction in a patient with dyssynergic defecation: A case report

Yejun Jeong^a, Yongjae Kim^a, Wonhyun Kim^a, Seoyeon Park^a, Su-Jin Shin^b, Eun Jung Park^{c,*}^a Yonsei University College of Medicine, Seoul, Republic of Korea^b Department of Pathology, Gangnam Severance Hospital, Yonsei University College of Medicine, Seoul, Republic of Korea^c Division of Colon and Rectal Surgery, Department of Surgery, Gangnam Severance Hospital, Yonsei University College of Medicine, Seoul, Republic of Korea

ARTICLE INFO

Keywords:

Colonic-pseudo obstruction
 Dyssynergia
 Hypoganglionosis
 Constipation
 Intestinal obstruction

ABSTRACT

Introduction and importance: Colonic pseudo-obstruction (CPO) is characterized by massive colonic dilatation of the large intestine without mechanical obstruction. In this study, we report our surgical experience in treating refractory CPO with increased anal sphincter tone, suggested as type IV dyssynergia.

Case presentation: A 48-year-old man with intellectual disability, depression, heart failure, and end-stage renal disease presented with acute exacerbation of CPO. He had a history of chronic constipation and abdominal distension. Colonic dilatation and defecation difficulty persisted despite medication and repeated colonoscopic decompression. Anal manometry results indicated type IV dyssynergia with increased rectal pressure. Hartmann's operation was performed to resect the redundant megacolon and to avoid increased anal sphincter pressure during defecation. Hypoganglionosis was observed in the resected colon, which could worsen the chronic process of CPO.

Clinical discussion: Meticulous evaluation and careful management are required to treat CPO patients because the pathophysiology of CPO has not yet been clearly identified. Proper surgical treatment is needed for patients with refractory CPO.

Conclusion: CPO requires meticulous evaluation and careful management owing to the risk of bowel perforation. Precise evaluation to identify other factors affecting defecation problems accompanied by CPO is required to make appropriate treatment decisions.

1. Introduction

Colonic pseudo-obstruction (CPO) is characterized by massive colonic dilatation of the large intestine without mechanical obstruction, and was first reported by Ogilvie in 1948 [1]. CPO can be either acute or chronic, and presents with a clinical manifestation of organic obstruction. It most commonly occurs in hospitalized inpatients with severe disease or who are under postoperative management. The three most common underlying conditions are trauma, infection, and heart disease, each of which is related to 10 % of cases [2–4]. This syndrome is relatively common, with an incidence of 100 out of 100,000 hospitalized patients per year [5]; however, the pathogenesis remains poorly elucidated [6].

The coordination of increasing rectal pressure and a relaxed external

anal sphincter is required for normal defecation. However, incoordination of the autonomic nervous system of the colon, such as decreased parasympathetic tone or enhanced sympathetic tone, may result in CPO [7]. Dyssynergic defecation results from an abnormality in this synchronized process, which may cause insufficient pushing pressure, paradoxical contraction of the anal sphincter, poor relaxation of the anal sphincter, or a combination of these mechanisms [8,9]. Medication therapies and colonoscopic decompression techniques to relieve such symptoms, such as enemas, laxatives, and cisapride, are used to treat CPO. Surgery may be considered when the disease is refractory to medication [10]. Cecostomy or subtotal resection of the colon with primary anastomosis can be considered, but Hartmann's operation is also often performed [6]. Here, we report a case of refractory CPO and its surgical treatment in a patient with type IV dyssynergia.

Abbreviations: APCT, abdominopelvic computed tomography; CPO, colonic pseudo-obstruction; ESRD, end-stage renal disease; TA, transverse-anastomosis.

* Corresponding author at: Division of Colorectal Surgery, Department of Surgery, Yonsei University College of Medicine, 20, Eonju-ro 63-gil, Gangnam-gu, 06229 Seoul, Republic of Korea.

E-mail address: camp79@yuhs.ac (E.J. Park).

<https://doi.org/10.1016/j.ijscr.2022.107524>

Received 13 July 2022; Received in revised form 12 August 2022; Accepted 13 August 2022

Available online 17 August 2022

2210-2612/© 2022 Published by Elsevier Ltd on behalf of IJS Publishing Group Ltd. This is an open access article under the CC BY-NC-ND license (<http://creativecommons.org/licenses/by-nc-nd/4.0/>).

2. Case presentation

A 48-year-old man visited the emergency department complaining of watery melena that started the previous day. He had experienced abdominal pain for 10 days, and had a history of chronic constipation and abdominal distension for five years. He further had a history of intellectual disability, depression, heart failure, and end-stage renal disease (ESRD) managed with hemodialysis three times a week. His hemoglobin level was 8.2 g/dL, and he did not exhibit any active bleeding on digital rectal examination or nasogastric tube irrigation. Abdominal radiography revealed marked distension of the large bowel loop (Fig. 1A). Accordingly, an abdominopelvic computed tomography (APCT) scan was performed, revealing massive dilatation of the sigmoid colon and rectum (maximum diameter: 12 cm) with diffuse colorectal wall thickening, especially in the rectosigmoid area, with further absence of any intrinsic mechanical obstruction of the intestinal lumen (Fig. 1B). Accordingly, the CPO was diagnosed as chronic stercoral proctocolitis.

Rectal tube insertion and decompression with medications such as osmotic laxatives, chloride channel activators, and 5-HT4 receptor agonists were performed. However, constipation and abdominal distension persisted. In the anorectal manometry and balloon expulsion tests, there was no adequate pushing force or sphincter relaxation, indicating type 4 dyssynergic defecation. More than six months of biofeedback with diet intervention showed no improvement in refractory outcomes. After two more visits to the emergency department for refractory CPO, the patient was referred for surgical management. APCT before surgery still showed a markedly distended sigmoid colon (maximal diameter $r \geq 11$ cm) and rectum (≥ 9 cm), with diffuse colorectal wall thickening.

Diagnostic laparoscopy was initially planned, but open conversion was required because of the discovery of the tremendously distended colon in the entire abdomen (Fig. 2). Intraoperative findings demonstrated a megarectum due to dyssynergia with rectal wall hypertrophy, indicating a chronic etiology. In addition, an anal dilator with a 2 cm diameter was unable to pass through the anal canal because of pelvic floor hypertrophy and increased anal sphincter tone. Hartmann's operation was performed to ensure adequate stool passage because of the complete dilatation of the rectosigmoid wall with anal stenosis from hypertrophy. Since the rectal wall was thickened and edematous after the distal rectal resection using transverse-anastomosis (TA) staplers, lembert sutures were performed at the rectal stump to prevent

disruption of the stapling site. The pathology report of the colon specimen showed a segmentally decreased number of ganglion cells (24 ganglion cell counts per centimeter), with marked dilatation of the entire specimen, suggestive of hypoganglionosis (Fig. 3). There were few ectopic ganglion cells in the muscularis mucosa or lower mucosa. No other abnormal features were observed, including immature ganglion cells, nerve plexus hypertrophy, inflammation, or gliosis. The patient began to consume sips of water on postoperative day 1, and a soft diet on postoperative day 7. The patient was discharged without complications on postoperative day 9. This case used the SCARE 2020 guideline to report clinical progress completely [11].

3. Discussion

In this study, we report our surgical experience in treating refractory CPO with increased anal sphincter tone, suggested as type IV dyssynergia. Although the pathophysiology of CPO has not yet been clearly identified, the most likely hypothesis is an autonomic imbalance of the colonic enteric nervous system [12]. Before the recent exacerbation, the patient constantly experienced constipation and abdominal distension for several years. The course of the patient indicates that the etiology of CPO may be a deteriorating chronic process, specifically hypoganglionosis. In this study, the involved colonic segment of the CPO showed that the ganglion cell count per centimeter decreased to 24. Ectopic ganglion cells were observed in the muscularis mucosae and lower mucosa. A decreased number of ganglion cells in the myenteric plexus can be the cause of CPO [13]. Given the patient's advanced age, acquired ganglion cell degeneration is the cause of constipation and CPO. Furthermore, various conditions, such as postoperative states, cardiopulmonary disorders, and systemic diseases, have been reported to be associated with CPO. Thus, ESRD, congestive heart failure, and a history of taking anti-parkinsonian drugs may have also contributed to CPO in the current patient.

Dyssynergic defecation is the failure to complete a series of defecation processes. The defecation process occurs completely when the abdominal, rectal, pelvic floor, and anal sphincter muscles effectively coordinate [8,14,15]. One important aspect of childhood development is the acquisition of toileting skills and establishment of continence. The establishment of bowel control usually starts between 21 and 36 months of age, and is completed by the age of four [16]. Thus, dyssynergic defecation is an acquired behavioral problem. The present patient's

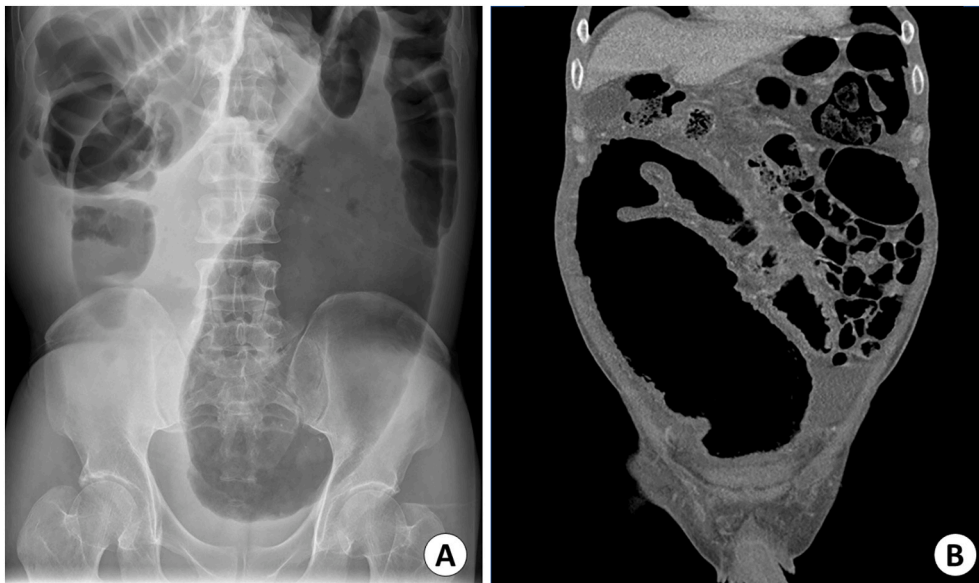

Fig. 1. (A) Abdominal X-ray finding of marked distension of large bowel loops; (B) AP-CT findings of dilated sigmoid colon and rectum (maximum diameter: 12 cm, sigmoid colon).

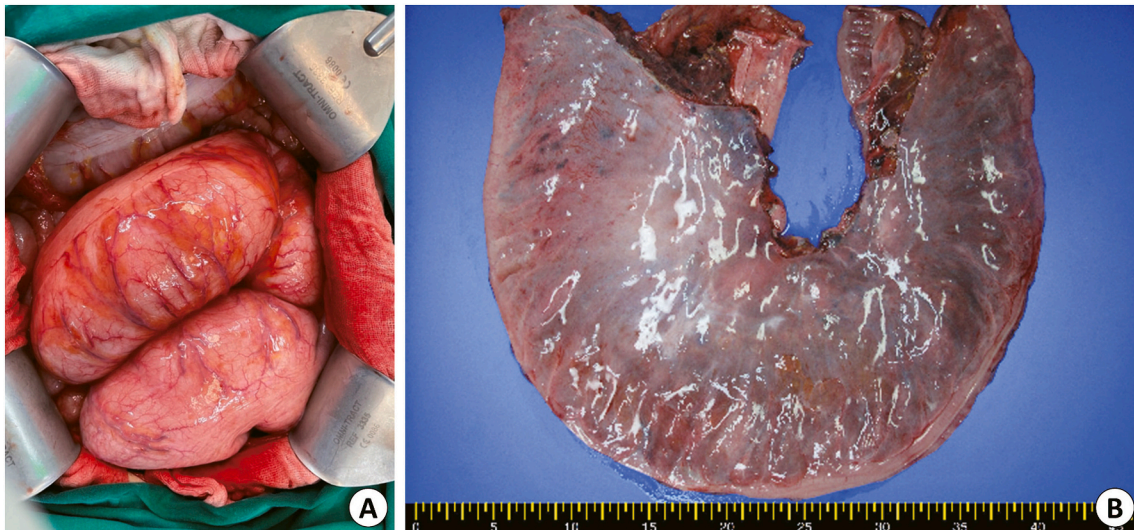


Fig. 2. (A) A picture showing operative finding (B) A picture showing the resected dilated sigmoid colon.

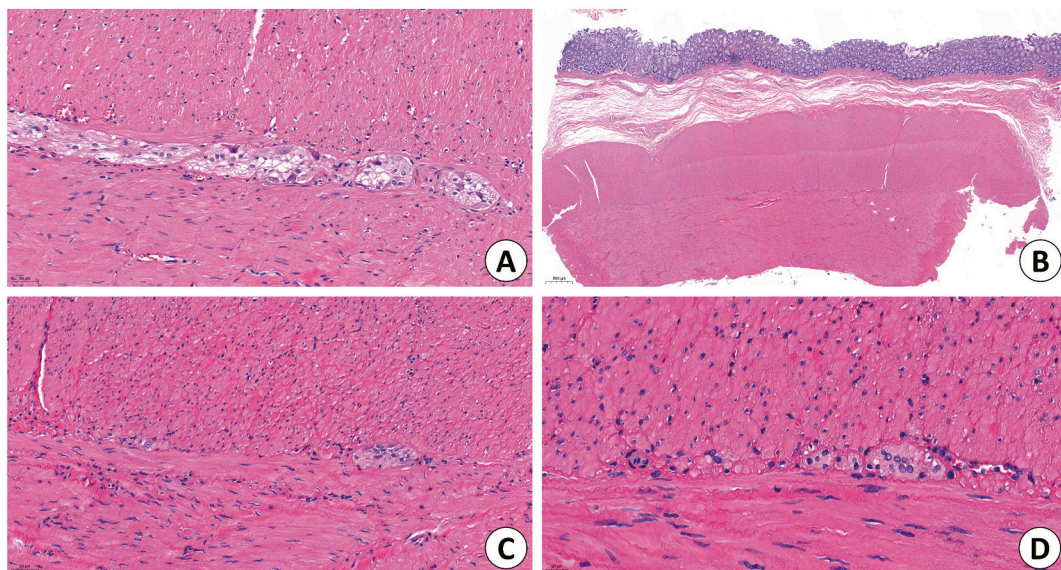


Fig. 3. H&E pathology staining of the resected sigmoid colon with a decreased number of ganglion cells. (A) Normal mucosa; (B) 2 \times ; (C) 20 \times ; (D) 40 \times .

defecation disorder may have been caused by a previous intellectual disorder. In fact, in the anorectal motility test, there were many difficulties empowering the patient to defecate because of communication limitations. The probable formation of incorrect bowel habits and long-standing fixed dyssynergic defecation may have caused chronic constipation and prolonged bowel distension. It is well known that chronic constipation is common in patients with intellectual disabilities [17]. However, there have been few studies on how intellectual disability causes constipation, or whether it can cause dyssynergia.

Biofeedback, which has been shown to be effective for constipation patients in several randomized controlled trials [18], was not effective for our patient. Several studies have been conducted on factors that reduce the efficacy of biofeedback. Such factors include long-lasting dyschezia history, lack of obvious process during biofeedback therapy, less accessibility to therapy, and less defecation index (maximum rectal pressure during attempted defecation/minimum anal residual pressure during attempted defecation), which are the factors that our patient had [19,20]. In addition, the treatment alone may have been insufficient because the patient had a colonic motility disorder that caused CPO.

Dyssynergic defecation may affect the treatment of colonic motility disorders. This could explain the unresponsiveness to pharmacological agents. Additionally, it could have affected the surgical management. The initial surgical management plan included resection and anastomosis. The transitional point of CPO determines the proximal line of colonic resection. The serial radiologic examinations and related patient symptoms should be fully evaluated before surgery. In this case, Hartmann's operation was finally performed because of the risk of anastomotic disruption due to paradoxically increased sphincter pressure and edematous bowel wall dilatation in the entire rectum. Hypoganglionosis of the dilated proximal colon and combined type IV dyssynergia resulted in marked colonic dilatation and defecation difficulties.

4. Conclusion

We report a case of CPO with dyssynergic defecation in a patient who underwent Hartmann's operation. CPO requires meticulous evaluation and careful management owing to the risk of bowel perforation, which can result in mortality. Precise evaluation to identify other factors

affecting defecation problems accompanied by CPO is required to make appropriate treatment decisions.

Funding

There was no funding for this research.

Ethical approval

This study was approved by the Institutional Review Board of Yonsei University Gangnam Severance Hospital. (IRB No. 3-2022-0158).

Consent

Written informed consent was obtained from the patient for publication of this case report and accompanying images. A copy of the written consent is available for review by the Editor-in-Chief of this journal on request.

Author contribution

Yejun Jeong, Yongjae Kim, Wonhyun Kim and Seoyeon Park collected data and wrote the first draft of this manuscript. All authors had full access to all the information of the cases. Su-Jin Shin contributed to interpret pathologic results of this study. Eun Jung Park contributed for study design and reviewed for this manuscript.

Research registration

Not applicable.

Guarantor

Eun Jung Park M.D., Ph.D., FACS.

Declaration of competing interest

All authors have no disclosure for any financial and personal relationships.

References

- [1] H. Ogilvie, Large-intestine colic due to sympathetic deprivation; a new clinical syndrome, *Br. Med. J.* 2 (4579) (1948) 671–673.
- [2] V.W. Vanek, M. Al-Salti, Acute pseudo-obstruction of the colon (Ogilvie's syndrome). An analysis of 400 cases, *Dis. Colon Rectum* 29 (3) (1986) 203–210.
- [3] K. Lee, H.-K. Oh, J.R. Cho, M. Kim, D.-W. Kim, S.-B. Kang, et al., Surgical management of sigmoid volvulus: a multicenter observational study, *Ann. Coloproctol.* 36 (6) (2020) 403–408.
- [4] M. Gonzalez-Urquijo, M. Rodarte-Shade, G. Gil-Galindo, Acute colonic volvulus in a Mexican population: a case series, *Ann. Coloproctol.* 36 (1) (2020) 48–53.
- [5] S.W. Ross, B. Oommen, B.A. Wormer, A.L. Walters, V.A. Augenstein, B.T. Heniford, et al., Acute colonic pseudo-obstruction: defining the epidemiology, treatment, and adverse outcomes of Ogilvie's syndrome, *Am. Surg.* 82 (2) (2016) 102–111.
- [6] R. De Giorgio, C.H. Knowles, Acute colonic pseudo-obstruction, *Br. J. Surg.* 96 (3) (2009) 229–239.
- [7] C.I. Wells, G. O'Grady, I.P. Bissett, Acute colonic pseudo-obstruction: a systematic review of aetiology and mechanisms, *World J. Gastroenterol.* 23 (30) (2017) 5634–5644.
- [8] S.S. Rao, J. Valetin, C.K. Brown, B. Zimmerman, K. Schulze, Long-term efficacy of biofeedback therapy for dyssynergic defecation: randomized controlled trial, *Am. J. Gastroenterol.* 105 (4) (2010) 890–896.
- [9] Y. Yune, H.Y. Jeong, D.H. Park, J.K. Lee, Three-dimensional pelvic floor ultrasound assessment of pelvic organ prolapse: minimal Levator hiatus and Levator ani deficiency score, *Ann. Coloproctol.* 37 (5) (2021) 291–297.
- [10] M.P. Bernardi, S. Warrior, A.C. Lynch, A.G. Heriot, Acute and chronic pseudo-obstruction: a current update, *ANZ J. Surg.* 85 (10) (2015) 709–714.
- [11] R.A. Agha, T. Franchi, C. Sohrabi, G. Mathew, A. Kerwan, The SCARE 2020 guideline: updating consensus surgical CAse REport (SCARE) guidelines, *Int. J. Surg.* 84 (2020) 226–230.
- [12] Y. Jang, S.M. Jung, T.G. Heo, P.W. Choi, J.I. Kim, S.-W. Jung, et al., Determining the etiology of small bowel obstruction in patients without intraabdominal operative history: a retrospective study, *Ann. Coloproctol.* (2021), <https://doi.org/10.3393/ac.2021.00710.0101>. In press.
- [13] M.Y. Do, S.J. Myung, H.J. Park, J.W. Chung, I.W. Kim, S.M. Lee, et al., Novel classification and pathogenetic analysis of hypoganglionosis and adult-onset Hirschsprung's disease, *Dig. Dis. Sci.* 56 (6) (2011) 1818–1827.
- [14] H.Y. Jeong, S.-J. Yang, D.H. Cho, D.H. Park, J.K. Lee, Comparison of 3-dimensional pelvic floor ultrasonography and defecography for assessment of posterior pelvic floor disorders, *Ann. Coloproctol.* 36 (4) (2020) 256–263.
- [15] S. Büyükaşık, M.A. Bozkurt, S. Kapan, H. Alis, Analyzing the role of anal sphincter pressure in rectocele formation, *Ann. Coloproctol.* 36 (5) (2020) 330–334.
- [16] I.J.N. Koppen, M.A. Benninga, Functional constipation and dyssynergic defecation in children, *Front. Pediatr.* 10 (2022), 832877.
- [17] M. Bellini, L. Rappelli, P. Alduini, C. Nisita, A. Barbanera, F. Costa, et al., Pelvic floor dyssynergia and psychiatric disorders. Does the snake bite its tail? *Minerva Gastroenterol. Dietol.* 49 (2) (2003) 135–139.
- [18] M. Hite, T. Curran, Biofeedback for pelvic floor disorders, *Clin. Colon Rectal Surg.* 34 (1) (2021) 56–61.
- [19] B.H. Lee, N. Kim, S.B. Kang, S.Y. Kim, K.H. Lee, B.Y. Im, et al., The long-term clinical efficacy of biofeedback therapy for patients with constipation or fecal incontinence, *J. Neurogastroenterol. Motil.* 16 (2) (2010) 177–185.
- [20] L. Siproudhis, S. Dautrême, A. Ropert, H. Briand, C. Renet, C. Beusnel, et al., Anismus and biofeedback: who benefits? *Eur. J. Gastroenterol. Hepatol.* 7 (6) (1995) 547–552.