



Contents lists available at [ScienceDirect](#)

AACE Clinical Case Reports

journal homepage: www.aaceclinicalcasereports.com



Case Report

A Case of Severe Hypocalcemia Caused by Malabsorption Due to Partial Gastrectomy and Small Bowel Resection

John O. Knight, MD, Lucia F. Cotten, MD, Thomas R. Ziegler, MD, Priyathama Vellanki, MD *

Division of Endocrinology, Metabolism, and Lipids, Department of Internal Medicine, Emory University School of Medicine, Atlanta, Georgia

ARTICLE INFO

Article history:

Received 22 January 2021

Accepted 2 April 2021

Available online 16 April 2021

Key Words:

achlorhydria
gastrectomy
hypocalcemia
malabsorption
small bowel resection

ABSTRACT

Objective: Calcium is an essential mineral involved in the functioning of nearly every human cell. Calcium levels are regulated by dietary absorption, vitamin D status, and parathyroid hormone (PTH). This report describes a patient in whom childhood bowel resection and partial gastrectomy resulted in malabsorptive hypocalcemia in adulthood.

Case Report: A 21-year-old man presented with syncope and a fall resulting in a right femoral neck fracture. His medical history included small bowel obstructions at age 9 requiring bowel resection, and at age 12 with gastric perforation and partial gastrectomy. Laboratory values showed calcium level of 4.9 mg/dL (8.9–10.3 mg/dL), PTH level was 273 pg/mL (12.0–88.0 pg/mL), 25-hydroxy-vitamin D was 28 ng/dL (30–100 ng/mL), and 1,25-dihydroxy-vitamin D was 54 pg/dL (18–72 pg/mL). Furthermore, magnesium and phosphorus levels were 2.1 mg/dL (1.5–2.6 mg/dL) and 4.4 mg/dL (2.4–4.7 mg/dL), respectively. Calcium levels improved to 9.5 mg/dL on 10% calcium gluconate drip but could not be maintained above 7 mg/dL on oral calcium carbonate supplementation, despite doses as high as 3750 mg three times daily with calcitriol 0.75 mcg twice daily. After switching from calcium carbonate to calcium citrate 3500 mg three times daily, the calcium level improved and was maintained between 8.3 and 9.0 mg/dL.

Discussion: High calcium needs, other nutrient deficiencies, and response to calcium citrate versus calcium carbonate suggest malabsorption from achlorhydria and small bowel resection.

Conclusion: This case emphasizes the gastrointestinal physiology in calcium homeostasis and highlights the recognition of hypocalcemia as a complication of gastric and bowel resection.

© 2021 AACE. Published by Elsevier Inc. This is an open access article under the CC BY-NC-ND license (<http://creativecommons.org/licenses/by-nc-nd/4.0/>).

Introduction

Calcium is an essential mineral involved in the functioning of nearly every cell in the human body. Extracellular fluid (ECF) concentrations of calcium are maintained within a narrow range through interactions of a number of hormones, including parathyroid hormone (PTH), 1,25-hydroxy vitamin D [1,25(OH)2D], calcitonin, and fibroblast growth-factor 23, with various organ systems, including the bone, gastrointestinal tract, and kidneys.^{1,2}

Principal among clinically important calcium regulatory hormones are PTH and D[1,25(OH)2D] levels. Under physiologic conditions, PTH facilitates both the formation and resorption of bones

by increasing numbers of both osteoblasts and thereby indirectly increasing the number of osteoclasts. In pathologic states of PTH excess, bone resorption predominates, increasing ECF calcium concentrations. Furthermore, PTH influences mineral exchange in the kidney, facilitating renal calcium reabsorption and increasing phosphaturia. Another important function of PTH in the kidney is increasing the expression of 1- α hydroxylase, facilitating the conversion of 25-hydroxy vitamin D [25(OH)D] into D[1,25(OH)2D].¹ D [1,25(OH)2D] in turn acts in the enterocyte by increasing the expression of a number of proteins, the net effect of which is to increase the absorption of both calcium and phosphorus.²

Despite tremendous reserves of calcium in the bone and a number of hormonal mechanisms contributing to calcium homeostasis, the maintenance of adequate ECF calcium concentrations is ultimately contingent on dietary intake and absorption from the gastrointestinal tract.² We describe a case in which surgical resections of the gastrointestinal tract in childhood potentially led to malabsorptive hypocalcemia in early adulthood.

Abbreviations: D[1,25(OH)2D], 1,25-hydroxy vitamin D; D[25(OH)D], 25-hydroxy vitamin D; ECF, extracellular fluid; PTH, parathyroid hormone.

* Address correspondence and reprint requests to Dr Priyathama Vellanki, Associate Professor, Division of Endocrinology, Metabolism and Lipids, 69 Jesse Hill Jr Dr SE, Atlanta GA, 30303.

E-mail address: pvellan@emory.edu (P. Vellanki).

<https://doi.org/10.1016/j.aace.2021.04.002>

2376-0605/© 2021 AACE. Published by Elsevier Inc. This is an open access article under the CC BY-NC-ND license (<http://creativecommons.org/licenses/by-nc-nd/4.0/>).

Table
Laboratory Evaluation of Hypocalcemia and Possible Malabsorption

Laboratory measure	Value	Reference range
Parathyroid hormone (pg/mL)	273	12.0–88.0
25-hydroxy vitamin D	28 ng/dL	30–100 ng/mL
1,25-hydroxy vitamin D	54 pg/dL	18–72 pg/mL
Magnesium level (mg/dL)	2.1	1.5–2.6
Phosphorus level (mg/dL)	4.4	2.4–4.7
Hemoglobin (g/dL)	12.0	13.2–17.7
Mean corpuscular volume (fL)	95	81–100.2
Folate (ng/mL)	6.7	≥7.8
Vitamin B12 (pg/mL)	286	180.0–914.0
Ferritin (ng/mL)	167	24.0–336.0

Case Report

A 21-year-old man presented to the hospital after an unwitnessed syncope, complicated by an acute fracture of the right femoral neck. He was found to have an albumin-corrected calcium level of 4.9 mg/dL (8.9–10.3 mg/dL). He did not have oral or acral paresthesia, palpitations, postictal symptoms, or muscle spasms, including carpedal spasms. He denied recent drug or alcohol use. He was not taking any medications or supplements, including vitamin D supplements.

His past medical history was significant for Nissen fundoplication as a neonate, indications for which were not known to the patient or explicitly stated in available records. At the age of 9 years, he had an adhesive small bowel obstruction requiring a 15-cm resection of the proximal small bowel adherent to the liver. He had another small bowel obstruction at age 12, this time complicated by gastric perforation resulting in hemigastrectomy. Pediatric records also note an intertrochanteric brown tumor of the right femur at age 9, although no work-up was detailed.

Physical examination findings were remarkable for a thin young man with diffuse tenderness upon palpation of the right hip and thigh, decreased range of motion, and leg held in external rotation. He had well-healed abdominal surgical scars. Chvostek and Trousseau signs were negative. Facies were normal with normal-appearing teeth. There was no bowing of long bones, truncation of the fourth metacarpal, or any other apparent skeletal abnormalities other than those related to his fracture. He was of normal stature, with a height of 1.77 m, weight of 62.1 kg, and a body mass index of 19 kg/m².

Hypocalcemia was evaluated biochemically to determine the etiology. The initial laboratory findings are presented in the [Table](#). PTH was elevated, D[25(OH)D] was very slightly low, and D [1,25(OH)2D] was within the reference range, suggesting an appropriate PTH response. His renal function was normal. He took no medications before hospitalization, and no clinical evidence of acute pancreatitis, such as abdominal pain, nausea, or elevation of pancreatic enzyme levels, was observed.

The patient's calcium levels and hypocalcemia treatment are outlined in the [Figure](#). His calcium levels responded well to intravenous calcium gluconate infusion and calcium citrate replacement, although it could not be maintained with calcium carbonate as outlined below. This indicated that impaired calcium absorption might play a role in his hypocalcemia.

Calcium replacement was initiated with oral calcium carbonate (40% elemental) 2500 mg every 8 hours and calcitriol 0.25 mcg every 12 hours as well as a 10% calcium gluconate infusion at 50 mL/h. After 18 hours on the calcium gluconate infusion, the serum albumin-adjusted calcium significantly improved to 9.5 mg/dL. On the second hospital day, calcium gluconate infusion was discontinued. He remained on oral calcium carbonate and calcitriol, and he underwent open reduction and internal fixation of the

femoral neck fracture. On the postoperative laboratory check 16 hours after the infusion was discontinued, his serum calcium level had dropped to 6.1 mg/dL despite continuing oral calcium carbonate and calcitriol. The 10% calcium gluconate infusion was restarted at 75 mL/h, and doses of oral calcium carbonate and calcitriol were increased to 3750 mg every 8 hours and 0.5 mcg every 12 hours, respectively. The calcium infusion was continued for 36 hours and stopped. However, over the next 4 days, calcium levels remained below the reference range, between 7.2 and 8.2 mg/dL, despite increasing the doses of calcium carbonate and calcitriol. Overnight, on his ninth hospital day, calcium levels dropped to 6.9 mg/dL. At that time, his calcium carbonate dose was 3750 mg three times daily with meals, and his calcitriol dose was 0.75 mg twice daily.

On further review of his laboratory results, the patient was noted to have anemia, with a hemoglobin level of 12.0 g/dL (13.2–17.7 g/dL), which was further evaluated with ferritin, folate, and vitamin B12 levels ([Table](#)). In addition to his low D[25(OH)D] level, folate levels were also found to be low. These modest vitamin deficiencies further supported malabsorption as a possible etiology. Celiac screen was negative.

Given the low folate levels and suboptimal vitamin B12 levels, the patient's history of partial gastrectomy and bowel resection, and improvement in his serum calcium with intravenous calcium gluconate without improvement on oral calcium carbonate, there was a high suspicion for malabsorption as an etiology of his hypocalcemia. Calcium carbonate was switched to oral calcium citrate (21% elemental) 3500 mg three times daily. The calcium citrate dose was later increased to 4750 mg three times daily, and the calcium gluconate drip was discontinued within 24 hours. Over the next 2 days, serum calcium rapidly improved and stabilized between 8.3 mg/dL and 9.0 mg/dL (8.9–10.3 mg/dL).

He was discharged in stable condition with prescriptions for calcium citrate 4750 mg three times daily and calcitriol 0.75 mg twice daily. During follow-up, his calcium levels remained within the reference range, at 9.6 mg/dL 3 weeks after discharge. His D [25(OH)D] levels were normalized on follow-up, with no supplementation.

Discussion

This case illustrates an instance of severe hypocalcemia, presumably due to malabsorption from remote small bowel resection coupled with achlorhydria from partial gastrectomy, both resulting from childhood surgical procedures.

Gastric pH has an inverse relationship with calcium solubility, and an impaired gastric acid secretion has long been recognized as a contributor to calcium absorption and bone health.^{2,3} Before the advent of endoscopic intervention, the surgical management of peptic ulcer disease involved partial gastrectomy, which often resulted in impaired gastric acid secretion. In older series, hypocalcemia and folate deficiency secondary to high gastric pH was observed in patients who underwent partial gastrectomy.^{4,5} In the modern era, bariatric surgery can result in hypocalcemia, which complicates 9.3% of sleeve gastrectomy and 10% of biliopancreatic diversion, also known as the duodenal switch operations.⁶

The patient's improvement after switching from calcium carbonate supplementation to calcium citrate supplementation further supports the hypothesis that our patient had an impaired gastric acid secretion, as calcium citrate is absorbed more effectively in patients with low gastric pH than calcium carbonate.^{7,8}

Although not overtly abnormal, the patient's suboptimal vitamin B12 levels are also potentially supportive of achlorhydria contributing to malabsorption.^{9,10}

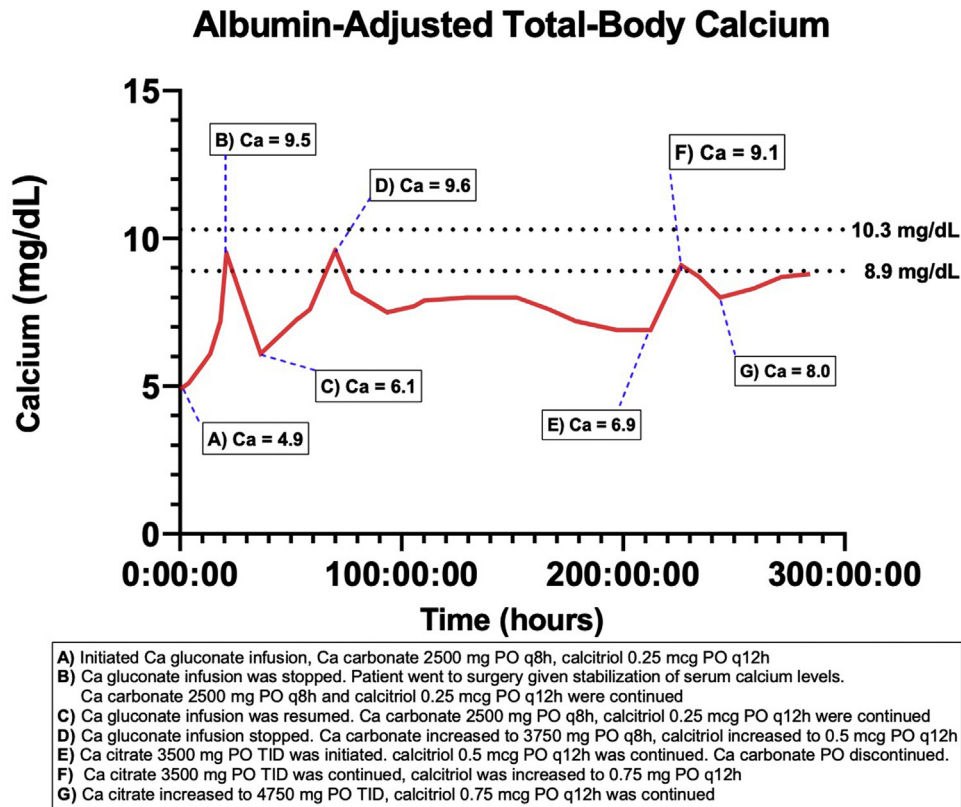


Fig. Albumin-adjusted serum calcium levels and interventions plotted over time.

Resection of any portion of the bowel can impair calcium absorption by decreasing the available surface area for absorption. Calcium is absorbed by both active and passive transport depending on the location in the gut. The duodenum is the primary site of active transport, mediated by PTH and D[1,25(OH)2D]. In hypocalcemic states, duodenal active transport can account for the majority of intestinal calcium absorption.² Passive calcium absorption predominates in the more distal portions of the small intestine, and the colon contributes to calcium intake by both mechanisms.^{2,6} In our patient, the resected bowel was adherent to the liver capsule, suggesting proximal small bowel resection. The absence of proximal small bowel would disproportionately impair active calcium absorption, which explains our patient’s hypocalcemia despite appropriately elevated PTH levels and normal levels of both D[25(OH)D] and D[1,25(OH)2D].

The evaluation of our patient’s hypocalcemia was limited in that a few causes of hypocalcemia were not formally investigated.¹ We did not perform a 24-hour urine collection, which would have been expected to have low levels of calcium in the case of malabsorption. Furthermore, we did not perform genetic testing or Ellsworth-Howard test, which evaluates the characteristic renal PTH resistance of pseudohypoparathyroidism by measuring urinary cyclic adenosine monophosphate and phosphorus after exogenous PTH administration. Both measures show a minimal response in patients with pseudohypoparathyroidism.^{11,12} Given the lack of family history, normal phosphorus levels, and pertinent physical examination findings, it is unlikely that the patient has pseudohypoparathyroidism.¹² While the patient did not display any characteristic features of Albright hereditary osteodystrophy, pseudohypoparathyroidism type 1B remains a differential consideration, although these patients more often present with hyperphosphatemia, which was not the case for our patient.¹² The common signs and

symptoms of hypocalcemia include neuromuscular excitability, central nervous system manifestations, and a prolonged QTc interval predisposing overt arrhythmia.¹ Given the absence of any of these findings, we suspect the patient’s hypocalcemia was chronic. In the setting of chronic hypocalcemia, secondary hyperparathyroidism could have predisposed his presentation with fracture. It is unclear whether his fracture was traumatic or nontraumatic, as we do not know how far the patient was from the bottom of the escalator when he fell. A bone density scan has not yet been performed.

Conclusion

Malabsorptive hypocalcemia as a result of surgical resection of portions of the gastrointestinal tract is an uncommonly reported phenomenon outside of the bariatric surgery population in the modern era. Given the numerous indications for gastrectomy or bowel resection, it is important for clinicians to recognize hypocalcemia as a potential long-term metabolic consequence of these operations and accordingly monitor and treat hypocalcemia when it occurs.

Disclosure

P.V. is supported in part by NIH/NIDDK K23 DK11324-01A1. The other authors have no multiplicity of interest to disclose.

References

1. Bove-Fenderson E, Mannstadt M. Hypocalcemic disorders. *Best Pract Res Clin Endocrinol Metab.* 2018;32(5):639–656.
2. Bronner F, Pansu D. Nutritional aspects of calcium absorption. *J Nutr.* 1999;129(1):9–12.

3. Recker RR. Calcium absorption and achlorhydria. *N Engl J Med.* 1985;313(2):70–73.
4. Deller DJ, Begley MD, Edwards RG, Addison M. Metabolic effects of partial gastrectomy with special reference to calcium and folic acid. I. Changes in calcium metabolism and the bones. *Gut.* 1964;5(3):218–225.
5. Deller DJ, Begley MD, Edwards RG, Addison M. Metabolic effects of partial gastrectomy with special reference to calcium and folic acid. II. The contribution of the folic acid deficiency to the anaemia. *Gut.* 1964;5(3):225–229.
6. Shah M, Sharma A, Wermers RA, Kennel KA, Kellogg TA, Mundi MS. Hypocalcemia after bariatric surgery: prevalence and associated risk factors. *Obes Surg.* 2017;27(11):2905–2911.
7. Straub DA. Calcium supplementation in clinical practice: a review of forms, doses, and indications. *Nutr Clin Pract.* 2007;22(3):286–296.
8. Weerapol Y, Cheewatanakornkool K, Sriamornsak P. Impact of gastric pH and dietary fiber on calcium availability of various calcium salts. *Silpakorn Univ Sci Technol J.* 2010;4(1):15–23.
9. Marcuard SP, Albernaz L, Khazanie PG. Omeprazole therapy causes malabsorption of cyanocobalamin (vitamin B12). *Ann Intern Med.* 1994;120(3):211–215.
10. Doscherholmen A, Swaim WR. Impaired assimilation of egg Co 57 vitamin B 12 in patients with hypochlorhydria and achlorhydria and after gastric resection. *Gastroenterology.* 1973;64(5):913–919.
11. Ogata E, Yamamoto M, Matsumoto T, et al. Standard procedure and the diagnostic criteria for the Ellsworth-Howard test using human PTH-(1-34). *Nihon Naibunpi Gakkai Zasshi.* 1984;60(8):971–984. Japanese.
12. Mantovani G. Clinical review: pseudohypoparathyroidism: diagnosis and treatment. *J Clin Endocrinol Metab.* 2011;96(10):3020–3030.