

Available online at www.sciencedirect.com

journal homepage: www.elsevier.com/locate/radcr

Case Report

Massive upper gastrointestinal bleeding caused by an intercostal arterio-esophageal fistula: A rare case report [☆]

Kai-Chun Yang, M.D.^a, Men-Ying Lin, M.D.^a, Li-Ting Huang, M.D.^b,
Wei-Lun Chang, M.D., Ph.D.^{a,*}

^a Department of Internal Medicine, National Cheng Kung University Hospital, College of Medicine, National Cheng Kung University, 138 Sheng Li Road, Tainan, Taiwan

^b Department of Medical Imaging, National Cheng Kung University Hospital, College of Medicine, National Cheng Kung University, Tainan, Taiwan

ARTICLE INFO

Article history:

Received 15 June 2020

Revised 27 July 2020

Accepted 28 July 2020

Keywords:

Arterio-esophageal fistula

Intercostal artery

Transcatheter arterial embolization

ABSTRACT

Arterio-esophageal fistula (AEF) is a rare life-threatening cause of upper gastrointestinal bleeding. Realizing the risk factors and clinical presentations of AEF will enable us to provide timely diagnosis, efficient treatment, and better outcome. We present a 43-year-old Taiwanese man who had histories of destructive lung, innominate artery-trachea fistula, and received bilobectomy. He was admitted to our hospital with fresh blood drainage from nasogastric tube. He was diagnosed as right fifth intercostal artery esophageal fistula by computed tomography angiography and transcatheter arterial embolization was performed. The bleeding stopped and the patient was discharged uneventfully. The risk factors of AEF include esophageal foreign body, vascular surgery, thoracic arterial malformations, and concurrent chemoradiotherapy in T4-esophageal cancer. Computed tomography angiography may be the most sensitive diagnostic test. Transcatheter arterial embolization or endovascular stent grafting may be considered as the first-line treatment of AEF in the future.

© 2020 The Authors. Published by Elsevier Inc. on behalf of University of Washington.

This is an open access article under the CC BY-NC-ND license.

(<http://creativecommons.org/licenses/by-nc-nd/4.0/>)

Introduction

Arterio-esophageal fistula (AEF) is a rare life-threatening cause of upper gastrointestinal bleeding that may be caused

by a variety of etiologies. It will almost lead to fatal condition if AEF is not diagnosed immediately. We present a case of fifth intercostal artery-esophageal fistula that was treated successfully with transcatheter arterial embolization (TAE). This is a rare case with AEF caused by previous vascular

[☆] Competing interests: The authors have no conflicts of interest relevant to this article. Disclosure: informed consent was obtained from the patient's family after making a phone call to his family.

* Corresponding author.

E-mail address: weilun1@mail.ncku.edu.tw (W.-L. Chang).

<https://doi.org/10.1016/j.radcr.2020.07.083>

1930-0433/© 2020 The Authors. Published by Elsevier Inc. on behalf of University of Washington. This is an open access article under the CC BY-NC-ND license. (<http://creativecommons.org/licenses/by-nc-nd/4.0/>)

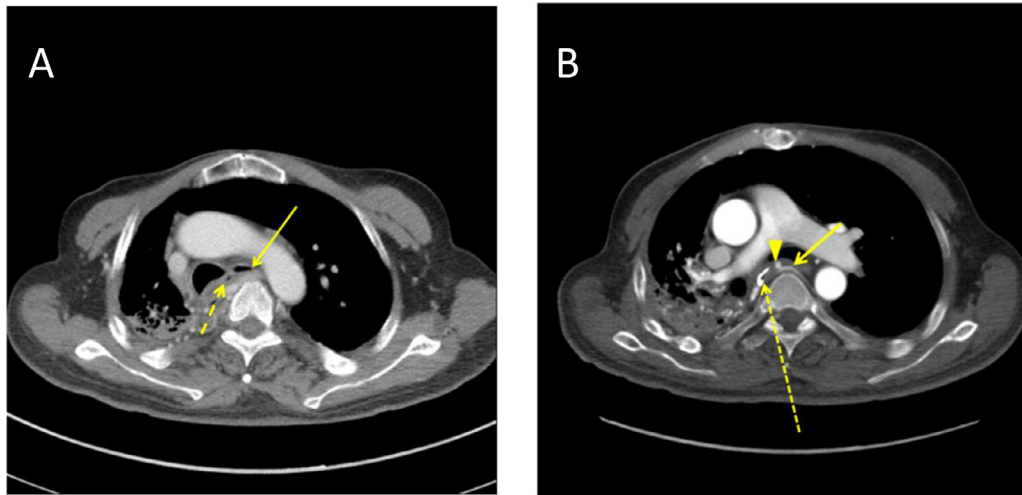


Fig. 1 – Thoracic contrast CT and CT angiography. (A) Contrast CT only showed a small gas collection in the right para-esophageal region (dotted arrow). Esophagus (arrow). (B) CT angiography showed right fifth intercostal artery pseudoaneurysm (arrowhead) and an AEF between the right fifth intercostal artery (arrow) and the esophagus (dotted arrow) which has intramural lipiodol retention (injected during first EGD for marking).

surgery and long-term nasogastric (NG) tube insertion. Understanding the risk factors and clinical presentations of AEF will enable us to provide timely diagnosis, efficient treatment, and better outcome.

Case report

A 43-year-old Taiwanese man was sent to our emergency department due to intermittent bloody content draining from NG tube for 2 days. He had a history of traumatic intracranial hemorrhage 20 years ago and became vegetative with NG feeding since then. Besides, he has destructive lung and right lung empyema caused by pneumonia 18 years ago, and right lung decortications were done at that time. He also had an experience of hemoptysis 15 years ago and was diagnosed as innominate artery-trachea fistula. It was treated by surgical resection of right middle and lower lobes.

The initial vital signs at our emergency department showed a body temperature of 38.1°C, a heart rate of 124 beats/min, a blood pressure of 114/83 mm Hg, and a respiratory rate of 20 breaths/min. Fresh blood drainage was noted from NG tube and his hemoglobin level dropped from 11.8 g/dL to 5.6 g/dL. Hemorrhagic shock was noticed and blood transfusion with 6 units of packed red blood cells, 4 units of fresh frozen plasma, and 1 unit of apheresis platelets was given. The contrast chest computed tomography (CT) revealed small gas collection in the right para-esophageal region (Fig. 1A) and esophageal perforation was suspected. Emergent esophagogastroduodenoscopy (EGD) showed a spurting visible vessel at esophagus (Fig. 2A) which stopped spontaneously and revealed a white nipple sign over the bleeder (Fig. 2B). Thus, esophageal fistula to the surrounding vessels rather than perforation was diagnosed. Consequently, thoracic computed tomography angiography was done and revealed a pseudoaneurysm at right fifth intercostal artery with a fistula between

it and the esophagus (Fig. 1B). Then, angiography showed right fifth intercostal artery pseudoaneurysm with active bleeding (Fig. 3A) and TAE was performed with microcoils (Fig. 3B).

The patient's vital sign was stable after TAE. The second look EGD revealed an esophageal ulcer without active bleeding, and one coil in the ulcer area (Fig. 2C). The follow-up EGD at 7 days later showed the esophageal ulcer with coil inside started to re-epithelize (Fig. 2D). The patient discharged with signs of improvement half month later.

Discussion

AEF is a rare and serious disease of upper gastrointestinal bleeding. We searched papers from PubMed using the keywords "arterio-esophageal fistula" to figure out the etiologies of AEF. Eleven cases of nonaortic AEF have been reported in recent 20 years (1997–2017). They were mainly male and middle-aged (30s to 70s-year-old), except for a 17-month-old female [1]. The responsible artery for nonaortic AEF included aberrant right subclavian artery (ARSA), bronchial artery, broncho-intercostal arterial trunk, intercostal artery, and left subclavian artery. The treatment included TAE, surgery, and stent-graft. According to these cases, we have divided the causes of AEF into 3 categories. The first category is caused by foreign body in the esophagus. The reported foreign body included fish bone [2], chicken bone [3], and a paper star [4]. They are caused by direct instrumentation with esophageal trauma or prolonged intubation [5]. Among them, merely NG tube placement was enough to cause AEF [6]. Lewandrowski et al. observed linear esophageal and gastric mucosal erosions along the pathway of NG tube at autopsy of a patient with NG tube insertion [7]. It is proposed that pressure from NG tube can cause deep ulcer and then esophageal perforation happened. The aortoesophageal fibrous adhesions will develop if esophageal contents leak from the area of perforation. Fibrous

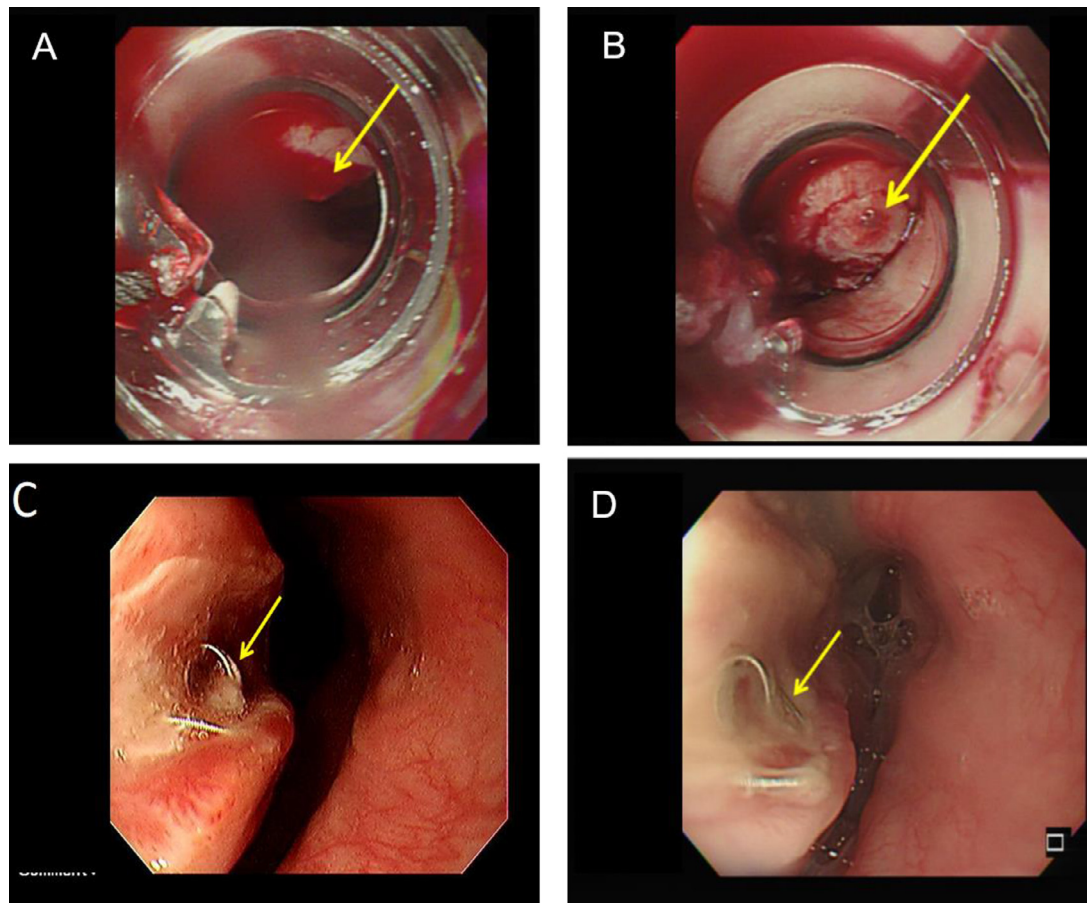


Fig. 2 – The findings from emergent and follow-up EGD. (A) Emergent EGD showed a spurting visible vessel in the esophagus (arrow) at 24 cm below incisor. (B) The bleeding stopped spontaneously and there is a white nipple sign (arrow). (C) The second look EGD after TAE showed an esophageal ulcer without active bleeding, and one coil in it (arrow). (D) The third look EGD at 7 days after TAE revealed re-epithelization of the ulcer with a coil inside (arrow).

adhesion then brings the distance between the artery and esophagus closer and then esophageal contents could erode arterial wall. Eventually, AEF is formed. The second category is vascular surgery and thoracic arterial malformations which includes ARSA [1]. The ARSA is a rare anomaly and happened in about 0.5%–2.0% of the population [8]. If an aneurysm developed from ARSA, there will be a high risk of AEF formation and aneurysm rupture. The third category is concurrent chemoradiotherapy in patients with T4-esophageal cancer. Taniguchi et al. reported a retrospective study which pointed out relatively high incidence of treatment-related AEF [9]. Treatment-related AEF was observed in 7 patients (14.6%, total 48 cases) and 4 of them died of massive bleeding due to aortic AEF. Aoki et al. and Tajima et al. also reported cases with chemoradiotherapy related AEF [10,11]. Our case had history of previous vascular surgery. In addition, due to the vegetative status, long-term NG tube placement was necessary. Both of them are risk factors of AEF; therefore, it is not surprising that the patient suffered from AEF due to these comorbidities.

The diagnostic tests for AEF include endoscopy, aortography, CT, and barium esophagography. Each test has advantages and limitations for diagnosing AEF. Endoscopy may reveal a pulsatile blood or pulsatile submucosal mass with adherent

clot [12]. Besides, endoscopy also plays an important role for excluding alternative upper gastrointestinal bleeding sources. Aortography is believed to be the best test for AEF during active hemorrhage but may have a false-negative result during symptom-free interval. Barium esophagography, compared to aortography and endoscopy, has a low sensitivity for AEF but may demonstrate narrowing and deviation of the esophagus when it is compressed by thoracic aortic aneurysm [13]. CT can also diagnose AEF and meanwhile rule out esophageal perforation, a foreign body, a mediastinal abscess, and esophageal malignancy. In our case, CT failed to identify AEF, whereas computed tomography angiography confirmed the diagnosis.

A 2-step surgical strategy is current accepted approach and maybe the gold standard for the treatment of AEF [3]. The first step is endovascular repair, including TAE and endovascular stent grafting, which allows quick hemodynamic stabilization. Then the second step is definitive open surgical repair of the fistula. The first step therapy is an expedient and a bridge therapy to open surgical repair. Although TAE and endovascular stent grafting are a relative minimally invasive approach that prevent exsanguinations and allow for fluid resuscitation, graft infection is a concern if definitive surgical repair is not performed [3]. Therefore, definitive surgical

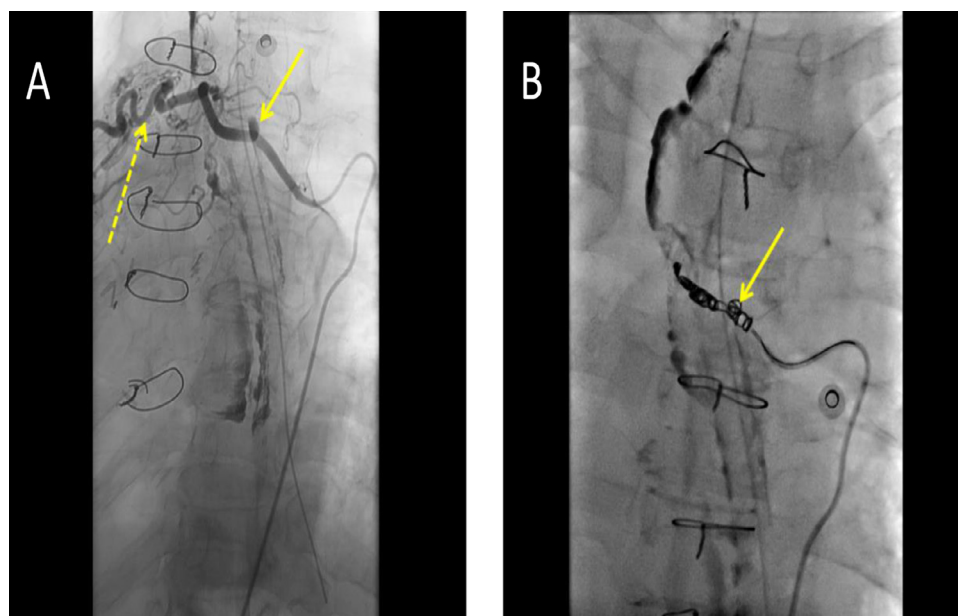


Fig. 3 – The angiography and TAE treatment of the AEF. (A) The angiography showed a pseudoaneurysm in the proximal right fifth intercostal artery (arrow). In addition, dilated and tortuous intercostal artery was also noted (dotted arrow). (B) The TAE is performed with microcoils (arrow) injected into the right fifth intercostal artery.

repair of the fistula should be done as soon as possible after successful endovascular stent grafting. However, according to the previous case reports, most cases did not undergo surgical repair after endovascular graft stenting. One of them was reported by Floré et al. [3]. The surgical repair was substituted by extensive clinical and imaging follow-up to detect graft infection. The case had no graft infection during the 5-year follow-up, and successfully avoided tissue damage, bleeding, wound infection, disability, and long recovery time which may be brought from surgical repair. Along with the recent progress in techniques of TAE, endovascular stent grafting and convenience of medical resource, TAE or endovascular stent grafting may be the first-line treatment of AEF in the near future. Back to our case, the patient received TAE and prophylactic antibiotics for 7 days without additional surgical repair. It represents another successful case of a single-stage treatment without surgical repair.

Conclusion

Realizing the risk factors of AEF will enable us to diagnose AEF early and provide timely treatment to improve patient outcome. The TAE or endovascular stent grafting may be considered as the initial treatment of cases with AEF.

Consent

Informed consent was obtained from the patient's family after making a phone call to his family.

REFERENCES

- [1] Joynt MR, Grifka RG. Spontaneous aberrant right subclavian arterio-oesophageal fistula in a previously healthy child. *Cardiol Young* 2015;25:1425–7.
- [2] Leow CK. Subclavian arterio-esophageal fistula secondary to fish bone impaction: report of a case. *Jpn J Surg* 1998;28:409–11.
- [3] Floréa B, Heyea S, Naftauxb P, Maleuxa G. Single-stage endovascular treatment of an infected subclavian arterio-oesophageal fistula. *Eur J Cardiothorac Surg* 2014;45:570–2.
- [4] Lin CS, Lin CW. Left subclavian artery-esophageal fistula induced by a paper star: a case report. *Biomedicine (Taipei)* 2016;6(3):18.
- [5] Fuentes S, Cano I, López M, Moreno C, Tejedor R, Marianeschi S, et al. Arterial-esophageal fistula: a severe complication in children with cardiovascular abnormalities. *Pediatr Surg Int* 2010;26:335–7.
- [6] Lescot T, Karvellas CJ, Sanchez-Pena P, Deme M, Abdenmour L. Massive upper gastrointestinal hemorrhage caused by an arterio-esophageal fistula. *Intensive Care Med* 2011;37:1551–2.
- [7] Lewandrowski KB, Southern JF, Medeiros LJ, Jacobs M. Aorto-esophageal fistula arising as a complication of pro-longed nasogastric tube placement. *Hum Pathol* 1989;20:709–11.
- [8] Takahashi S, Okada K, Orihashi K, Sueda T. Arterio-oesophageal fistula caused by aberrant right subclavian artery aneurysm. *Interact Cardiovasc Thorac Surg* 2013;16:920–2.
- [9] Taniguchi H, Yamazaki K, Boku N, Funakoshi T, Hamauchi S, Tsushima T, et al. Risk factors and clinical courses of chemoradiation-related arterio-esophageal fistula in esophageal cancer patients with clinical invasion of the aorta. *Int J Clin Oncol* 2011;16:359–65.

- [10] Aoki M, Tokue H, Koyama Y, Tsushima Y, Oshima K. Transcatheter arterial embolization with N-butyl cyanoacrylate for arterial esophageal bleeding in esophageal cancer patients. *World J Surg Oncol* 2016;14:54.
- [11] Tajima T, Haruki S, Usui S, Ito K, Matsumoto A, Matsuhisa A, et al. Transcatheter arterial embolization for intercostal arterio-esophageal fistula in esophageal cancer. *Surg Case Rep* 2017;3:70.
- [12] Heckstall RL, Hollander JE. Aortoesophageal fistula: Recognition and diagnosis in the emergency department. *Ann Emerg Med* 1998;32:502–5.
- [13] Hollander JE, Quick G. Aortoesophageal fistula: a comprehensive review of the literature. *Am J Med* 1991;91:279–87.