

ORIGINAL RESEARCH

Characterization of outcomes and practices utilized in the management of internal carotid artery injury not requiring definitive endovascular management

Nyall R. London Jr MD, PhD^{1,2,3}  | Abdulaziz AlQahtani MD⁴  | Siani Barbosa BS¹ | Paolo Castelnuovo MD⁵  | Davide Locatelli MD⁶ | Aldo Stamm MD, PhD⁷ | Aaron A. Cohen-Gadol MD⁸ | Hussam Elbosraty MD⁹ | Roy Casiano MD¹⁰ | Jacques Morcos MD¹¹ | Ernesto Pasquini MD¹² | Georgio Frank MD¹³ | Diego Mazzatenta MD¹³ | Garni Barkhoudarian MD¹⁴ | Chester Griffiths MD¹⁴ | Daniel Kelly MD¹⁴ | Christos Georgalas PhD, DLO, FRCS (ORL-HNS)¹⁵  | Trichy N. Janakiram MD¹⁶ | Piero Nicolai MD¹⁷ | Daniel M. Prevedello MD^{3,18} | Ricardo L. Carrau MD, MBA^{3,18} 

¹Sinonasal and Skull Base Tumor Program, Head and Neck Surgery Branch, National Institute on Deafness and Other Communication Disorders, National Institutes of Health, Bethesda, Maryland, USA

²Department of Otolaryngology – Head & Neck Surgery, Johns Hopkins Medicine, Baltimore, Maryland, USA

³Department of Otolaryngology – Head & Neck Surgery, Wexner Medical Center at The Ohio State University, Columbus, Ohio, USA

⁴Department of Otorhinolaryngology – Head & Neck Surgery, King Fahad Medical City, Riyadh, Saudi Arabia

⁵Division of Otorhinolaryngology, Department of Biotechnology and Life Sciences, University of Insubria, Varese, Italy

⁶Division of Neurosurgery, Department of Biotechnology and Life Sciences, University of Insubria, Varese, Italy

⁷Complexo Hospitalar Edmundo Vasconcelos, Centro de Otorrinolaringologia e Fonoaudiologia (COF), São Paulo, São Paulo, Brazil

⁸Indiana University, Department of Neurosurgery and Goodman Campbell Brain and Spine, Indianapolis, Indiana, USA

⁹Department of Otorhinolaryngology, Faculty of Medicine, Cairo University, Giza, Egypt

¹⁰Department of Otolaryngology, Head & Neck Surgery, University of Miami, Miller School of Medicine, Miami, Florida, USA

¹¹Department of Neurosurgery, University of Miami, Miami, Florida, USA

¹²ENT Department, Ospedale Bellaria, Bologna, Italy

¹³Center of Pituitary and Endoscopic Skull Base Surgery, Istituto delle Scienze Neurologiche di Bologna, Bologna, Italy

¹⁴Pacific Brain Tumor Center and Pituitary Disorders Program, John Wayne Cancer Institute at Providence Saint John's Health Center, Santa Monica, California, USA

¹⁵Medical School, University of Nicosia, Cyprus and Hygeia Hospital, Athens, Greece

¹⁶Department of Otorhinolaryngology, Royal Pearl Hospital, Tiruchirapally, Tamil Nadu, India

¹⁷Unit of Otorhinolaryngology – Head and Neck Surgery, Department of Medical and Surgical Specialties, Radiological Sciences, and Public Health, University of Brescia, Brescia, Italy

¹⁸Department of Neurosurgery, Wexner Medical Center, The Ohio State University, Columbus, Ohio, USA

This study was presented as an oral presentation at the virtual annual North American Skull Base Society meeting February 13, 2021.

This is an open access article under the terms of the Creative Commons Attribution-NonCommercial-NoDerivs License, which permits use and distribution in any medium, provided the original work is properly cited, the use is non-commercial and no modifications or adaptations are made.

© 2021 The Authors. *Laryngoscope Investigative Otolaryngology* published by Wiley Periodicals LLC. on behalf of The Triological Society.

Correspondence

Ricardo L. Carrau, MD, Lynne Shepard Jones
Chair in Head and Neck Oncology,
Department of Otolaryngology – Head & Neck
Surgery, The Ohio State University, 320 W
10th Ave., Columbus, OH 43210, USA.
Email: ricardo.carrau@osumc.edu; carraurl@
gmail.com

Funding information

NIDCD; Intramural Research Program of the
NIH

Abstract

Background: After internal carotid artery (ICA) injury during endoscopic skull base surgery, the majority of patients undergo ICA embolization or stenting to treat active extravasation or pseudoaneurysm development. However, management practices when embolization or stenting is not required have not been well described. The objective of this study was to determine how patients with ICA injury but no embolization, stenting, or ligation do long-term and ascertain the reconstruction methods utilized.

Methods: Twenty-nine cases of ICA injury were identified in an international multi-institutional retrospective review. Of these, we identified six cases that were not treated with embolization, stenting, or ICA sacrifice. Information was available for five cases.

Results: A muscle patch was used in the immediate repair of each case. A nasoseptal flap was used in one case. Prefabricated nasal tampons were used in all cases. Nasal packing was initially left in for a median of 7 days prior to removal. The initial muscle patch was reinforced with a second muscle graft in one case. One case demonstrated ICA bleeding at the time of packing removal and was repacked an additional week. Follow-up for each of these cases was at least 2 years. No cases of subsequent carotid rupture were found and none of these cases ultimately underwent endovascular stenting. Radiation or proton therapy has not been subsequently used in any of these patients.

Conclusions: This study details the reconstruction, lessons learned, and long-term follow-up for five cases of ICA injury not treated with embolization, stenting, or ligation.

KEYWORDS

carotid artery injury, carotid artery ligation, embolization, endoscopic skull base surgery

1 | INTRODUCTION

Injury of the internal carotid artery (ICA) during endoscopic endonasal skull base surgery is a feared complication which may lead to profuse bleeding, stroke, neurologic deficits, pseudoaneurysm, and death.¹ Reported rates of ICA injury range from 0.16% to 1.1% for transphenoidal hypophysectomy to 2%-9% for lesions requiring extensive skull base approaches such as chordoma.²⁻⁴ Injury of the ICA during endoscopic endonasal surgery is a rare event; however, this potentially catastrophic event is likely under reported.^{1,5} The ICA is commonly divided into seven segments, namely the cervical/parapharyngeal, petrous, lacerum, cavernous, clinoid, ophthalmic, and communicating.⁶⁻⁹ While the cavernous portion of the carotid has been regularly reported to be the most commonly injured segment during endoscopic endonasal surgery, extended approaches frequently place multiple segments at risk for injury.¹

Multiple potential anatomic risk factors for ICA injury have been identified. The bone overlying the ICA may be dehiscence and intersinus septations regularly attach to the ICA canal.¹⁰⁻¹² Bulging of the

ICA into the sphenoid sinus is common, and may be variable dependent on sphenoid sinus pneumatization patterns.¹³ The distance between the ICA cavernous segments may be narrow, and aneurysms of the ICA may predispose to inadvertent intra-operative rupture.^{11,14} Furthermore, tumors of the skull base can displace the ICA, obscure visualization, and distort normal anatomic landmarks. Tumors may also encircle the ICA and be adherent to or infiltrate the vessel wall increasing the risk of injury during tumor dissection. The risk of injury may be further increased by a history of previous surgery, radiation, or chemotherapy.¹⁵ Lack of experience may also contribute to ICA injury and a greater risk has been suggested earlier in the learning curve prior to achieving proficiency.¹⁶ A recent international multi-institutional root cause analysis of 28 cases of ICA injury found that these cases are typically characterized by more than one risk factor and the study provided a case-by-case event description and recommendations.¹⁷

Several management algorithms for control of an ICA injury have been reported and address methods to visualize and identify the site of injury and achieve hemostasis.^{11,18} After immediate control of

hemostasis, patients are typically taken for neuroendovascular evaluation to assess for pseudoaneurysm formation and options for potential definitive management. The majority of patients undergo ICA stenting or embolization to treat active extravasation or for pseudoaneurysm control due to the high risk of pseudoaneurysm rupture.¹⁹ Even when a pseudoaneurysm is not initially observed, it is important to perform repeated evaluation to assess for delayed pseudoaneurysm formation.^{11,18} However, management practices in the absence of pseudoaneurysm formation and when embolization or stenting is not required have not been well described. The objective of this study was to determine how patients with ICA injury during endoscopic endonasal skull base surgery but no embolization, stenting, or ligation do long-term and ascertain the reconstruction methods utilized.

2 | METHODS

An international multi-institutional retrospective study was performed of cases of ICA injury during endoscopic endonasal skull base surgery not treated with embolization, stenting, or ligation. This is a follow up study to the previously reported ICA injury root cause analysis.¹⁷ This study underwent Institutional Review Board review and approval. Twenty-nine cases of ICA injury were identified from 1993 to 2019. Of these, 6 cases were not treated with embolization, stenting, or ICA sacrifice and information was available on 5 cases. A new questionnaire was completed by surgeons from these 5 cases including questions regarding the injury location, angiography frequency and findings, reconstruction methods utilized, and follow up (Table 1). Follow up for all cases was at least 2 years.

3 | RESULTS

Four injuries occurred to the main ICA while one case was to an ICA branch. A lack of available resources influenced the decision not to perform embolization or stenting in only one case. The average number of post-injury angiography performed per case was 3 (range: 1-5; Table 2). Angiography was negative for pseudoaneurysm each time in 2 cases and positive in 1 case (Figure 1). In one case a micro-pseudoaneurysm was detected which resolved on later angiography. In one case, the ICA was noted to be thrombosed/occluded. Preoperative angiography had not been performed for this patient, thus although occlusion was suspected to be due to a combination of packing, thrombosis, and/or arterial spasm, whether this ICA was occluded prior to surgery is unknown. The median time for the first follow-up angiography was 8.5 days (range: 2 days to 2 months; Table 2). Computed tomography angiography (CTA) or magnetic resonance angiography (MRA) was also used in 3 of the 5 cases. For the case of ICA branch injury, bipolar electrocautery was briefly attempted but was not effective as the vessel retracted into the tumor mass within the cavernous sinus. The instrumentation used when the injury occurred included coarse diamond drill (two cases), sharp microscissors, rongeur, and Blakesley forceps.

TABLE 1 Questionnaire

- Where was injury, was it main ICA or a branch?
- What was the reason for not intervening, was it based purely on the disease itself or was then a lack of availability of resources for embolization or stenting?
Angiography
- How many times was diagnostic angiography performed?
- Was the diagnostic angiography negative every time or was there ever any evidence of pseudoaneurysm?
- What was the time interval between diagnostic angiography was performed?
- Was CTA/MRA used in place of diagnostic angiography?
Reconstruction
- What was used for the initial reconstruction? Muscle patch vs other?
- What type of packing was initially used?
- Was the packing reinforced with a foley catheter or merocel?
- How many days was the packing left in prior to being removed?
- Was the original reconstruction sufficient or was it reinforced with additional muscle or other graft?
- Was there any carotid bleeding after packing removal?
- Was the muscle graft viable or need debridement?
- Was an intranasal flap used as part of the reconstruction?
- Was the nose repacked after the first look?
- What packing was performed on additional looks and how did it differ from the initial packing?
- Any evidence of complications or problems related to the packing?
Follow up
- Did the patient ultimately develop a pseudoaneurysm or cavernous carotid fistula?
- Did the patient ultimately develop carotid rupture? If there was rupture, how was it managed?
- Any complications (such as stroke or residual deficits) and is the patient still alive and well?
- Did the patient ultimately require carotid stenting or embolization?
- Did you return to the operating room to complete the EEA or was the surgery completed previously or left for other treatment/observation?
- Did the patient receive radiation or proton after carotid injury?

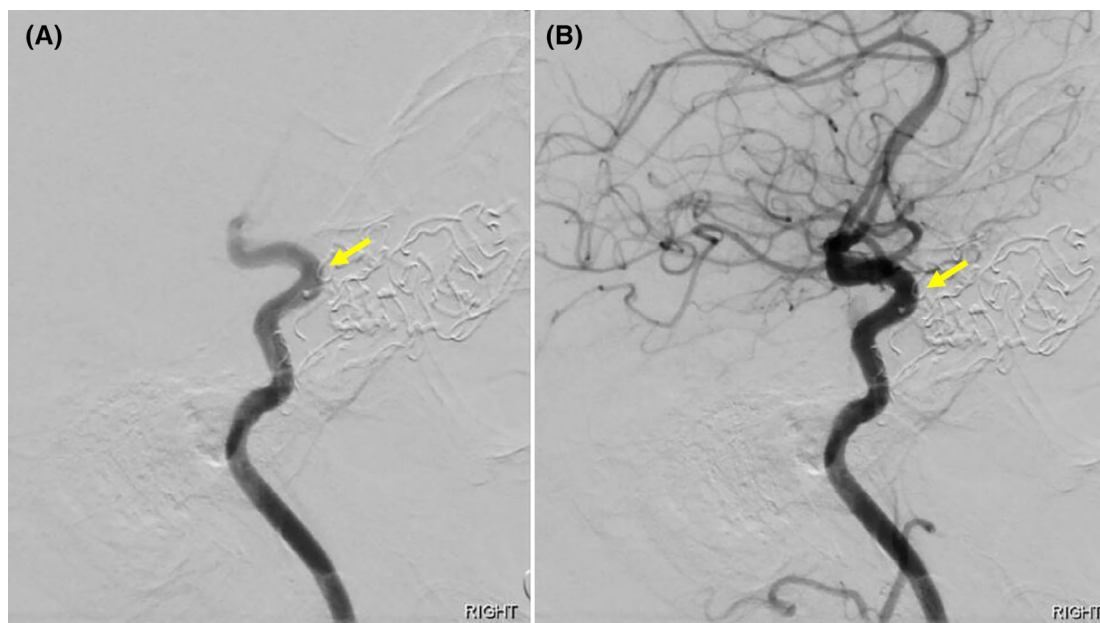
Abbreviations: CTA, computed tomography angiography; EEA, expanded endonasal approach; ICA, internal carotid artery; MRA, magnetic resonance angiography.

A muscle patch was used in the immediate repair of all five cases (Table 3). An intranasal flap (nasoseptal flap) was added to the reconstruction in only one case. Additional non-absorbable packing such as pledgets or gauze were used in 3 cases. Absorbable hemostatic matrix or foam was reported in 3 cases and use of oxidized cellulose was reported in 2 cases (Table 3). Abdominal fat or mucosal grafts were not used in any case. Prefabricated nasal tampons were used in all cases and a foley balloon was used to support the packing in one case. Nasal packing was initially left in for a median of 7 days (range: 5 days-11 days) prior to removal (Table 3). No complications with the

TABLE 2 Injury location and angiography

Case	Disease pathology	Injury location	Reason for no embolization or stenting	Angiography	CTA/MRA use	Pseudoaneurysm
1	Tuberculum sellae meningioma	Main ICA	Physician decision	4 (POD 0, 3, 11, 20)	POD 28, 50, 75	No
2	Nonsecreting pituitary macroadenoma	Main ICA	Physician decision	5 (POD 0, 14; 1, 3, 6 months)	None	Microaneurysm at 4 weeks, resolved at 3 and 6 months
3	Growth hormone secreting pituitary adenoma	Right ICA branch	Physician decision	2 (POD 0, 2)	“Multiple and frequent”	No
4	Aggressive skull base fibromatosis	Main parasellar ICA	ICA occlusion	1 (POD 0)	None	No, ICA thrombosed/occluded
5	Craniopharyngioma	Main ICA	Lack of available resources	3 (POD 0; 2, 9 months)	With angiography	Yes

Abbreviations: CTA, computed tomography angiography; ICA, internal carotid artery; MRA, magnetic resonance angiography; POD, post-op day.

**FIGURE 1** Diagnostic angiography early, A, and late, B, filling after ICA injury demonstrate no pseudoaneurysm in case #1

nasal packing such as infection were noted. On packing removal, the initial muscle patch not found to be non-viable or to require debridement in any of the cases. However, the muscle patch was covered by the nasoseptal flap in one case and thus not directly visualized. The initial muscle patch was reinforced with a second muscle graft in one case. One case demonstrated ICA bleeding at the time of packing removal and was re-packed an additional week (case #5). Three cases were not reported to be repacked after packing removal. One case was repacked two additional times, first with oxidized cellulose, gelatin, hemostatic matrix, and strip gauze and secondly with oxidized cellulose and hemostatic matrix (Table 3).

The follow up for each case was at least 2 years. A pseudoaneurysm was noted in case #5 and no permanent pseudoaneurysm or carotid-cavernous fistula developed in the other cases (Table 4). No cases of

subsequent carotid rupture were found and none of these cases ultimately underwent endovascular stenting. All patients survived and three patients had no complications or deficits as a result of the ICA injury. One patient had resultant neurologic deficits. One patient with acromegaly did not have a surgical remission (Table 4). Only one patient returned to the operating room and an open approach was used in this case. Radiation or proton therapy has not been subsequently used in any of these patients.

4 | DISCUSSION

Injury of the ICA during endoscopic endonasal skull base surgery, although uncommon, may lead to devastating consequences for the patient. As with many catastrophic surgical events, injury does not

TABLE 3 Injury reconstruction

Case	Initial reconstruction	Initial packing	Days initial packing left in place	ICA bleeding on packing removal	Reconstruction reinforcement	Additional nasal packing
1	Muscle patch	Pledgets and nasal tampons	11	No	Additional muscle graft	Yes, twice. First with oxidized cellulose, gelatin, hemostatic matrix, and strip gauze. Second with oxidized cellulose and hemostatic matrix.
2	Muscle patch, facia lata, nasoseptal flap	Patties, hemostatic matrix and nasal tampons	5	No	None	None
3	Muscle patch	Multiple types of packing, hemostatic agents, and nasal tampons	5	No	None	None
4	Muscle patch	Oxidized cellulose, nasal tampon, and foley balloon	7	No	None	None
5	Muscle patch	Oxidized cellulose and nasal tampons	7	Yes	Yes	Nasal tampon

Abbreviation: ICA, internal carotid artery.

TABLE 4 Internal carotid artery injury follow up

Case	Development of pseudoaneurysm or cavernous carotid fistula	Development of delayed carotid rupture	Complications	Did patient return to operating room
1	No	No	No	Yes, 3.5 months later for open approach
2	Microaneurysm disappeared	No	No	No
3	No	No	Did not achieve surgical remission of acromegaly	No
4	No	No	No	No
5	Pseudoaneurysm	No	Some residual dysphasia	No

typically occur as a result of an isolated circumstance, but often as the result of multiple contributing factors.^{11,17} Injury to the ICA may occur during any portion of the surgery including the approach, tumor exposure, resection, and reconstruction.⁵ Management after ICA injury may include ICA stenting, embolization, ligation, and external carotid artery-internal carotid artery bypass; however, outcomes in patients in which these interventions are not performed have not been well described. Without definitive management there may be a risk of spontaneous ICA rupture or complications, which is particularly true if a pseudoaneurysm is found. There are a variety of factors that may impact the choice of intervention after ICA injury including: (1) the lack of active extravasation or presence of a pseudoaneurysm or carotid-cavernous fistula, (2) the degree of collateral blood flow through the circle of Willis, (3) thrombosis or occlusion of the ICA, (4) lack of local resources or inability to transfer the patient to a higher level of care, (5) ability to continue to monitor or follow the site of ICA injury with serial angiography, and (6) presence of contraindications for long term anti-platelet treatment.

The objective of our study was to assess how these patients do long term and to ascertain the reconstruction methods used. Typically,

patients in this international multi-institutional cohort were initially reconstructed with a muscle patch and prefabricated nasal tampons left in for a median time of 1 week. Angiography was performed a median of 3 times at various levels in each case. For Case #1 and Case #3, the decision was made for conservative management as bleeding had stopped during surgery after use of a muscle patch, and there was no active extravasation or pseudoaneurysm on angiography. Resources were available for multiple follow up angiography and/or imaging studies for both of these cases. For Case #2, the decision was made not to intervene guided by the recommendation of the interventional radiologist. Case #4 was characterized by ICA occlusion/thrombosis and it is possible that the patient's underlying aggressive skull base fibromatosis may have contributed to a predisposition towards ICA occlusion/thrombosis. Case #5 demonstrated a pseudoaneurysm which was not stented or embolized in part due to a lack of resources. This bled again upon the initial packing removal but subsequently has not bled with further reinforcement. A variety of approaches were used in each case, and there are variable patient, disease, and systems factors in every ICA injury case. Furthermore, there may be a varying degree of surgical exposure of the carotid artery

which may significantly affect how a surgeon would choose to achieve hemostasis after ICA injury.^{11,18} Thus applicability of the implications of this study must be tailored to each case and we anticipate that these findings may not be applicable to intradural ICA injuries. Furthermore, it is not known what impact radiation or proton therapy would have as none of the patients from this series underwent subsequent radiation or proton therapy.

Several limitations of this study include selection and recall bias. The cases studied here occurred from 1993 to 2019, thus there may be some inaccuracy in the surgeon's ability to remember the circumstances and details surrounding the injury and reconstruction. There may also be selection bias as our questionnaires were limited to skull base teams at tertiary care centers across the world and may not account for contributing factors outside of these large centers. Lastly, ICA injury during endoscopic skull base surgery is rare, and even with an international multi-institutional study the number of patients in this study is low.

5 | CONCLUSIONS

This international multi-institutional study details the reconstruction, lessons learned, and long-term follow-up for five cases of ICA injury not treated with embolization, stenting, or ligation. These results need validation with additional future studies, and ICA injury not definitively managed by interventional stenting, embolization, ligation, or other approaches may be at risk for rupture and catastrophic hemorrhage or other complications.

ACKNOWLEDGMENTS

This research was supported (in part) by the Intramural Research Program of the NIH, NIDCD. We would like to thank Dr Carter Van Waes and Dr Wade Chien for critical review of the manuscript.

CONFLICT OF INTEREST

Dr London holds stock in Navigen Pharmaceuticals, was a consultant for Cooltech Inc, and receives research funding from Merck Inc, none of which are relevant to this study. Dr Casiano reported receiving ad hoc consulting fees from Medtronic, Olympus ENT, and MeilMed Inc outside the submitted work. Dr Barkhoudarian reported receiving personal fees from Vascular Technology Inc outside the submitted work. Dr Kelly reported receiving ad hoc consulting fees from Mizuho Inc outside the submitted work. Dr Prevedello reported being a consultant for Stryker, Medtronic, and Integra and receiving royalties from ACE Medical, Mizuho, KLS-Martin and honorarium from Storz. No other disclosures were reported.

ORCID

Nyall R. London Jr  <https://orcid.org/0000-0002-2902-4407>
 Abdulaziz AlQahtani  <https://orcid.org/0000-0002-1606-9999>
 Paolo Castelnuovo  <https://orcid.org/0000-0002-5184-6140>
 Christos Georgalas  <https://orcid.org/0000-0003-1158-020X>
 Ricardo L. Carrau  <https://orcid.org/0000-0003-3867-2032>

BIBLIOGRAPHY

- Chin OY, Ghosh R, Fang CH, Baredes S, Liu JK, Eloy JA. Internal carotid artery injury in endoscopic endonasal surgery: a systematic review. *Laryngoscope*. 2016;126:582-590. <https://doi.org/10.1002/lary.25748>
- Berker M, Hazer DB, Yücel T, et al. Complications of endoscopic surgery of the pituitary adenomas: analysis of 570 patients and review of the literature. *Pituitary*. 2012;15(3):288-300. <https://doi.org/10.1007/s11102-011-0368-2>
- Gardner PA, Tormenti MJ, Pant H, Fernandez-Miranda JC, Snyderman CH, Horowitz MB. Carotid artery injury during endoscopic endonasal skull base surgery: incidence and outcomes. *Neurosurgery*. 2013;73(2 suppl):261-269. <https://doi.org/10.1227/01.neu.0000430821.71267.f2>
- Padhye V, Valentine R, Wormald PJ. Management of carotid artery injury in endonasal surgery. *Int Arch Otorhinolaryngol*. 2014;18(suppl 2):S173-S178. <https://doi.org/10.1055/s-0034-1395266>
- Rowan NR, Turner M, Valappil B, et al. Injury of the carotid artery during endoscopic endonasal surgery: surveys of skull base surgeons. *J Neurol Surg B Skull Base*. 2018;79(3):302-308. <https://doi.org/10.1055/s-0037-1607314>
- Bouthillier A, van Loveren HR, Keller JT. Segments of the internal carotid artery: a new classification. *Neurosurgery*. 1996;38(3):425-432.
- Fortes FS, Pinheiro-Neto CD, Carrau RL, Brito RV, Prevedello DM, Sennes LU. Endoscopic endoscopic exposure of the internal carotid artery: an anatomical study. *Laryngoscope*. 2012;122(2):455-451. <https://doi.org/10.1002/lary.22395>
- Ho B, Jang DW, van Rompaey J, et al. Landmarks for endoscopic approach to the parapharyngeal internal carotid artery: a radiographic and cadaveric study. *Laryngoscope*. 2014;124(9):1995-2001. <https://doi.org/10.1002/lary.24601>
- Labib MA, Prevedello DM, Carrau R, et al. A road map to the internal carotid artery in expanded endoscopic endonasal approaches to the ventral cranial base. *Neurosurgery*. 2014;10(suppl 3):448-471. <https://doi.org/10.1227/NEU.0000000000000362>
- Fernandez-Miranda JC, Prevedello DM, Madhok R, et al. Sphenoid septations and their relationship with internal carotid arteries: anatomic and radiological study. *Laryngoscope*. 2009;119(10):1893-1896. <https://doi.org/10.1002/lary.20623>
- AlQahtani A, Castelnuovo P, Nicolai P, Prevedello DM, Locatelli D, Carrau RL. Injury of the internal carotid artery during endoscopic skull base surgery: prevention and management protocol. *Otolaryngol Clin North Am*. 2016;49(1):237-252. <https://doi.org/10.1016/j.otc.2015.09.009>
- Ramalho CO, Marengo HA, de Assis Vaz Guimarães Filho F, et al. Intrasphenoid septations inserted into the carotid arteries: a frequent and risky relationship in transsphenoidal surgery. *Braz J Otorhinolaryngol*. 2017;83(2):162-167. <https://doi.org/10.1016/j.bjorl.2016.02.007>
- Dal Secchi MM, Dolci RLL, Teixeira R, Lazarini PR. An analysis of anatomic variations of the sphenoid sinus and its relationship to the internal carotid artery. *Int Arch Otorhinolaryngol*. 2018;22(2):161-166. <https://doi.org/10.1055/s-0037-1607336>
- Raper DM, Ding D, Evans E, et al. Clinical features, management considerations and outcomes in case series of patients with parasellar intracranial aneurysms undergoing anterior skull base surgery. *World Neurosurg*. 2017;99:424-432. <https://doi.org/10.1016/j.wneu.2016.11.150>
- Valentine R, Wormald PJ. Carotid injury after endonasal surgery. *Otolaryngol Clin North Am*. 2011;44(5):1059-1079. <https://doi.org/10.1016/j.otc.2011.06.009>
- Snyderman CH, Fernandez-Miranda J, Gardner PA. Training in neuro-rhinology: the impact of case volume on the learning curve. *Otolaryngol Clin North Am*. 2011;44(5):1223-1228. <https://doi.org/10.1016/j.otc.2011.06.014>
- AlQahtani A, London NR Jr, Castelnuovo P, et al. Assessment of factors associated with internal carotid injury in expanded endoscopic

- endonasal skull base surgery. *JAMA Otolaryngol Head Neck Surg.* 2020;146(4):364-372. <https://doi.org/10.1001/jamaoto.2019.4864>
18. Gardner PA, Snyderman CH, Fernandez-Miranda JC, Jankowitz BT. Management of major vascular injury during endoscopic endonasal skull base surgery. *Otolaryngol Clin North Am.* 2016;49(3):819-828. <https://doi.org/10.1016/j.otc.2016.03.003>
19. Sylvester PT, Moran CJ, Derdeyn CP, et al. Endovascular management of internal carotid artery injuries secondary to endonasal surgery: case series and review of the literature. *J Neurosurg.* 2016;125(5):1256-1276. <https://doi.org/10.3171/2015.6.JNS142483>

How to cite this article: London NR Jr, AlQahtani A, Barbosa S, et al. Characterization of outcomes and practices utilized in the management of internal carotid artery injury not requiring definitive endovascular management. *Laryngoscope Investigative Otolaryngology.* 2021;6(4):634-640. <https://doi.org/10.1002/lio2.621>