

# Upper Tract Urothelial Carcinoma (UTUC): Prevalence, Impact and Management Challenge

Elizabeth Nally<sup>1</sup>, Matthew Young<sup>1</sup>, Vishwani Chauhan<sup>2</sup>, Connor Wells<sup>1</sup>, Bernadett Szabados<sup>1</sup>, Thomas Powles<sup>1</sup>, Francesca Jackson-Spence<sup>1</sup>

<sup>1</sup>Barts Cancer Institute, Queen Mary University of London, London, UK; <sup>2</sup>Department of Medical Oncology, St Bartholomew's Hospital, Barts Health NHS Trust, London, UK

Correspondence: Elizabeth Nally, Barts Cancer Institute, Queen Mary University of London, Charterhouse Square, London, EC1M 6BQ, UK, Tel +447921786256, Email [elizabethnally@nhs.net](mailto:elizabethnally@nhs.net)

**Abstract:** Upper tract urothelial carcinoma (UTUC) is an aggressive and difficult malignancy to treat. Owing to its rarity and the lack of specific high-level data, management mirrors that of urothelial cancer of the bladder (UCB). Over the past decade, UTUC has shown minimal improvement in survival rates. Its location makes the diagnosis and staging of UTUC more complex. Moreover, surgery often leads to a decline in renal function, rendering a proportion of patients ineligible for cisplatin. There is debate as to how best manage locally advanced UTUC perioperatively. Although immune checkpoint inhibitors (ICIs) have changed the treatment landscape for UCB, the response to ICIs in UTUC has been variable. With new technologies, our understanding of the molecular biology of UTUC has grown, helping to identify key molecular differences from UCB. This review summarises the evidence available on UTUC as a disease entity, discusses treatment in perioperative and metastatic settings, and considers future directions for the management of patients diagnosed with UTUC.

**Keywords:** urothelial, upper tract, immunotherapy, targeted therapy

## Introduction

The management of upper tract urothelial carcinoma (UTUC) remains challenging. UTUCs arising in the renal pelvis or ureter represent only 5–10% of urothelial carcinomas (UCs).<sup>1</sup> They behave more aggressively, with 60% being invasive at diagnosis, compared to 15–25% of urothelial cancer of the bladder (UCB), leading to poor survival rates.<sup>2</sup> There is limited UTUC-specific data and much of the literature is extrapolated from studies conducted in UC.<sup>3,4</sup>

## Risk Factors and Diagnosis

UTUC shares environmental risk factors with UCB, with an increased incidence of both associated with tobacco and aromatic amine exposure. However, UTUCs have unique epidemiological features and risk factors. Exposure to aristolochic acid, found in some Chinese herbal medicines, has been found to generate a TP53 mutation in the urothelium, resulting in an increased incidence of UTUC in certain areas.<sup>5</sup> This is evident in Taiwan, where UTUC has a high incidence and female predominance, accounting for 30% of UC cases.<sup>6</sup> This proportion of patients also exhibited more adverse pathological features compared to other international centres, suggesting variation in the pathogenesis of the disease.<sup>7</sup>

UTUCs are most commonly sporadic; however, genetic risk factors have also been identified. Hereditary predisposition to UTUC occurs in 10–20% of cases and is associated with alterations of mismatch repair (MMR) genes related to hereditary non-polyposis colorectal carcinoma (HNPCC) or Lynch syndrome.<sup>8</sup> Guidelines now recommend that those with UTUC under the age of 60 with a family history of HNPCC-associated malignancies undergo genetic testing to identify this subset of patients.<sup>9</sup>

The diagnosis of UTUC is similar in theory to that of UCB; however, the difficulty in the diagnosis and staging of UTUC in the preoperative setting is likely to contribute to poorer outcomes. The key investigation in UTUC is diagnostic ureteroscopy (URS), which provides both cytology and biopsy of suspected lesions. However, sampling tissue within the

upper tract is technically more difficult and there can be high rates of discordance between the biopsy and final pathology specimen.<sup>10</sup> As a result, UTUCs are stratified into two risk categories considering data collected from multiple sources, including endoscopy sampling, histology, imaging and a patient's medical history.<sup>11</sup>

## Molecular Landscape of UTUC

Next-generation sequencing (NGS) provides a better understanding of the distinct molecular alterations present in UC. UC arises from the epithelial layer of the urinary system along two tracts: papillary and non-papillary.<sup>12</sup> The Cancer Genome Atlas (TCGA) classified UCB into five molecular subtypes (luminal–papillary, luminal–infiltrated, luminal, basal and neuronal).<sup>13</sup> However, TCGA did not include UTUC and, as a result, its classification remains less established.<sup>14</sup>

Whilst sharing clinicopathological features with UC, UTUC has been shown to have its own distinct molecular features. Studies comparing UTUC and UCB have shown significant differences in the prevalence of common genomic alterations. Robinson et al performed RNA and whole-exome sequencing in high-grade UTUC (n=37).<sup>15</sup> Sporadic UTUC showed a lower mutational burden than UCB, and 63% (20/32) of UTUCs were of the luminal–papillary subtype compared to 27% (25/128) in TCGA UCB cohort. They also demonstrated that fibroblast growth factor 3 (*FGFR3*) was more frequently mutated in high-grade UTUC (30%) than in UCB (14%), making it a biological driver and promising therapeutic target.<sup>15</sup> This finding was supported by a study by Audenet et al (195 UTUC, 454 UCB), which found significant differences in mutation prevalence between the two groups, with a higher frequency of *FGFR3* and *HRAS* and a lower frequency of *TP53* in UTUC, which remained significant when accounting for disease grade.<sup>16</sup> However, other whole-exome sequencing studies found a significantly higher frequency of *p53* mutations in high-grade UTUC, highlighting the complex mutation pattern of UC.<sup>17</sup>

Controversy remains around the molecular profile of UTUC, particularly with regard to immune checkpoint inhibitors (ICIs). It is theorised that *FGFR* mutant UCs are less responsive to ICIs. This *FGFR3*-driven common UTUC subtype is associated with low tumour mutation burden (TMB) and a T-cell-depleted microenvironment, creating an immunologically “cold” tumour.<sup>15</sup> Moreover, UCs with *FGFR3* mutations are associated with lower programmed cell death ligand-1 (PD-L1) expression.<sup>18</sup> However, mutational analysis studies have shown similar response rates to ICIs, regardless of *FGFR3* status, and although PD-L1 expression has been shown to have some correlation with ICI response, this is limited and has not proven to be a useful predictor of response in UC.<sup>19,20</sup> Moreover, trial data has been variable and is not robust in this small UTUC population. Further studies are needed to characterise the molecular profile of UTUC in order to identify biomarkers and develop therapeutic targets.

## Management of Locally Advanced UTUC

High-risk UTUC is defined as >2 cm with possible hydronephrosis, high-grade disease at cytology/biopsy, multifocal disease, variant histology or previous treatment for bladder cancer.<sup>11</sup> Surgical management of high-risk UTUC is now standardised, with all patients recommended to undergo open or laparoscopic radical nephroureterectomy (RNU) with bladder cuff excision.<sup>2</sup> Despite surgical advances, survival rates for patients with UTUC have not improved over the past 20 years, highlighting the need to enhance the treatment pathway.<sup>21</sup>

The role of perioperative chemotherapy in this cohort of patients has been contentious and largely follows the guidelines for UBC.<sup>3</sup> There is level-one evidence supporting adjuvant chemotherapy in UTUC. The POUT trial (NCT01993979) was the first phase III randomised controlled trial (RCT) which showed an improvement in disease-free survival (DFS) for patients with locally advanced UTUC (pT2–T4 N0–N3 M0 or pT any N1–3 M0) receiving adjuvant gemcitabine and cisplatin, with 3 year DFS of 71% for chemotherapy versus 46% for surveillance (hazard ratio [HR] 0.45, 95% CI 0.38–0.68).<sup>22</sup> This led to adjuvant therapy with gemcitabine and cisplatin becoming the standard of care for such patients.<sup>3</sup> Despite this, questions regarding adjuvant therapy in UTUC remain. Although overall survival (OS) favoured the adjuvant chemotherapy arm, the difference was not statistically significant, indicating that the benefit of adjuvant chemotherapy versus chemotherapy at the time of relapse is unknown. Controversy also remains regarding the role of adjuvant carboplatin. Patients ineligible for cisplatin (Eastern Cooperative Oncology Group [ECOG] performance status >1, with grade >2 hearing loss, grade >2 neuropathy and/or New York Heart Association Class >III heart failure or inadequate renal function, defined as creatinine clearance >50 mL/min) are usually offered

carboplatin alongside gemcitabine as an alternative regimen.<sup>23</sup> Following RNU, patients have a decline in renal function after surgery, with one study identifying a fall in glomerular filtration rate (GFR) (from a preoperative GFR >60 mL/min) by one-third.<sup>7</sup> The POUT study found that patients who received carboplatin did not see the same benefit in DFS as patients receiving adjuvant cisplatin, with a DFS HR of 0.35 (95% CI 0.20–0.61;  $p=0.0002$ ) and an HR of 0.66 (95% CI 0.35–1.26;  $p=0.21$ ) in the gemcitabine/cisplatin and gemcitabine/carboplatin groups, respectively.<sup>22</sup>

Neoadjuvant chemotherapy (NC) may be beneficial in the treatment of UTUC. The advantage of NC is that more patients are eligible for cisplatin-based regimens owing to their preserved renal function. The largest prospective multicentre phase II trial to date enrolled 57 patients who received four cycles of cisplatin–gemcitabine chemotherapy prior to surgery. A pathological response was observed in 63% ( $n=36$ ) of patients, while 19% ( $n=11$ ) had a complete pathological response (pT0M0). At a median follow-up of 3.1 years, progression-free survival (PFS) was 89% at 2 years and 72% at 5 years.<sup>24</sup> A meta-analysis identified seven comparative retrospective studies, which showed a pooled 56% OS benefit in patients who received cisplatin-based NC.<sup>25</sup> Despite data showing a benefit in prolonging survival for NC, the evidence remains limited without a large-cohort RCT. One of the major disadvantages of NC in UTUC is the difficulty in preoperative staging, which leads to overtreatment and undertreatment. One study found that upstaging to muscle-invasive disease occurred in 41.7% of patients (240 of 575) diagnosed with <cT1c disease by URS.<sup>26</sup> Debate surrounding the perioperative chemotherapeutic approach in UTUC continues.

The role of ICIs in the perioperative setting in UTUC remains unclear, and specific data are sparse. A single-agent ICI in neoadjuvant and adjuvant settings has been shown to be effective in UCB; however, data for UTUC are predominantly based on subgroup analysis alone.<sup>27</sup> IMvigor010 (NCT02450331) included 54 UTUC patients (6.7%) and showed no improved DFS with adjuvant atezolizumab versus placebo (HR 0.89, 95% CI 0.74–1.08;  $p=0.24$ ).<sup>28</sup> The phase III trial CheckMate 274 (NCT02632409) demonstrated a significant improvement in DFS with adjuvant nivolumab (20.8 months) versus placebo (10.8 months) for patients with high-risk urothelial cancer after radical surgery (HR 0.7, 98.2% CI 0.55 to 0.90,  $p<0.001$ ).<sup>29</sup> However, subgroup analysis revealed no benefit within the UTUC subgroup ( $n=149$ , 21%), with the HR for disease recurrence or death being 1.23 (95% CI 0.67–2.23).<sup>29</sup> The PURE-02 trial (NCT02736266) aimed to determine whether neoadjuvant pembrolizumab was effective in the UTUC population. This prospective phase II single-arm trial found no benefit of neoadjuvant pembrolizumab in patients with high-risk, biomarker-unselected UTUC.<sup>30</sup> The lack of response to ICIs seen in the perioperative setting has been suggested to reflect the biology of UTUC, with a reduced TMB compared to UCB.

Further initial work is being conducted to assess combined ICIs in a neoadjuvant setting for UTUC. A phase II trial recruited nine patients with UTUC who underwent pretreatment sequencing via MSK-IMPACT and then received ipilimumab and nivolumab prior to surgery.<sup>31</sup> One-third ( $n=3$ , 33.3%) had a pathological complete response and the remainder ( $n=6$ , 66.6%) had pathological downgrading (<ypT2pN0). Notably, those patients with a pathological complete response had alterations in MMR, whilst those who were >ypT1 or node positive at surgery had a lower TMB.<sup>31</sup> This variation in response again highlights the significance of tumour biology in predicting the response to ICIs.

## Metastatic UTUC

Guidelines for the management of metastatic UTUC are based on studies conducted in UCB patients because of the lack of specific high-grade evidence, with UTUC cohorts being reported as subgroup analysis (Table 1). Until recently, the standard first-line management for metastatic UTUC was six cycles of platinum combination chemotherapy.<sup>32</sup> Data from three RCTs show that the PFS and OS benefits of first-line platinum-based chemotherapy for UC are not affected by the location of the tumour (upper or lower urinary tract).<sup>33</sup> However, a greater proportion of UTUC patients will be ineligible for cisplatin because they have a lower GFR related to previous radical surgery or infiltration of the tumour into the renal parenchyma.

ICIs have broadened treatment options for metastatic UC and are now the standard of care in both first- and second-line settings. Avelumab is approved as a maintenance therapy in patients who do not progress after four to six cycles of platinum-based chemotherapy, based on level 1 evidence from the JAVELIN Bladder 100 trial (NCT02603432). This phase III trial showed significantly improved OS in patients who received maintenance avelumab following first-line chemotherapy (HR 0.69, 95% CI 0.56 to 0.86,  $p<0.001$ ).<sup>34</sup> Subgroup analysis of the UTUC cohort ( $n=187$ , 27%) showed

**Table I** Clinical trials on metastatic UC which include UTUC subgroup analysis across first-, second- and third-line therapy

Trial	Line	Clinical Phase	Drug/Control	UTUC Patients n (%), total patients n	Outcomes (Primary Endpoint)	UTUC Subgroup
<b>Immunotherapy</b>						
<b>JAVELIN-100</b> <sup>34</sup>	Ist line	III	Avelumab/BSC	187 (27%), 700	Median OS: 21.4 (avelumab) vs 14.3 months (BSC) (HR 0.69, 95% CI 0.56–0.86; $p=0.001$ )	Median OS: 19.9 (avelumab) vs 17.4 months (HR 0.90, 95% CI 0.59–1.39)
<b>DANUBE</b> <sup>35</sup>	Ist line	III	Durvalumab (A)/durvalumab and tremelimumab (B)/gemcitabine and cisplatin or carboplatin (C)	221 (21%), 1032	Median OS: 14.4 (A) vs 12.1 months (C) in high PD-L1 population (HR 0.89, 95% CI 0.71–1.11; $p=0.30$ ). Median OS: 15.1 (B) vs 12.1 months (C) (HR 0.85, 95% CI 0.72–1.02; $p=0.075$ )	Median OS: 23.6 months (A) vs 9.3 months (C) (HR 0.47, 95% CI 0.27–0.79)
<b>KEYNOTE-361</b> <sup>36</sup>	Ist line	III	Pembrolizumab and cisplatin or carboplatin and gemcitabine (A)/ pembrolizumab (B)/cisplatin or carboplatin and gemcitabine (C)	211 (21%), 1010	Median OS: 17 (A) vs 14.3 months (C) (HR 0.86, 95% CI 0.72–1.02; $p=0.04$ ). Median OS: 15.6 (B) vs 14.3 months (C) (HR 0.92, 95% CI 0.77–1.11)	Median OS: HR for death in UTUC patients treated with pembrolizumab plus chemotherapy (A) vs chemotherapy (C) (HR 0.88, 95% CI 0.59–1.31)
<b>IMvigor130</b> <sup>37</sup>	Ist line	III	Atezolizumab and cisplatin or carboplatin and gemcitabine (A)/ atezolizumab (B)/cisplatin or carboplatin and gemcitabine (C)	312 (26%), 1213	Median OS: 16.0 (A) vs 13.4 months (C) (HR 0.83, 95% CI 0.69–1.00; $p=0.027$ ). Median OS: 15.7 (B) vs 13.1 months (C) (HR 1.02, 95% CI 0.83–1.24)	Median OS: 16.9 (A) vs 13.5 months (C) (HR 0.78, 95% CI 0.54–1.12)
<b>KEYNOTE-052</b> <sup>38</sup>	Ist line (platinum ineligible)	II	Pembrolizumab	69 (19%), 370	ORR: 24% (95% CI 0.20–0.29)	ORR: 22% (95% CI 0.12–0.25)
<b>IMvigor210</b> <sup>39</sup>	Ist line (platinum ineligible)	II	Atezolizumab	33 (28%), 119	ORR: 23% (95% CI 0.16–0.31)	ORR: 39% (95% CI 0.17–0.51)
<b>KEYNOTE-045</b> <sup>40</sup>	2nd line	III	Pembrolizumab/paclitaxel or docetaxel or vinflunine	75 (10%), 748	Median OS: 10.3 (pembrolizumab) vs 7.4 months (chemotherapy) (HR 0.73, 95% CI 0.59–0.91; $p=0.002$ )	Median OS: HR for death relative to chemotherapy 0.53 (95% CI 0.28–1.01)
<b>IMvigor211</b> <sup>41</sup>	2nd line	III	Atezolizumab/paclitaxel or docetaxel or vinflunine	236 (25%), 931	Median OS: 11.1 (atezolizumab) vs 10.6 months (chemotherapy) (HR 0.87, 95% CI 0.63–1.21; $p=0.41$ )	Median OS: HR for death relative to chemotherapy in renal pelvis 1.32 (95% CI 0.50–3.48) and in ureter 0.92 (95% CI 0.36–2.34)

<b>CheckMate 275</b> <sup>42</sup>	2nd line	II	Nivolumab	65 (24%), 265	ORR: 19.6% (95% CI 15.0–24.9)	ORR: 11% (95% CI 4–21)
<b>Targeted Therapy</b>						
<b>EV-301</b> <sup>43</sup>	3rd line	III	Enfortumab vedotin/paclitaxel or docetaxel or vinflunine	205 (34%), 608	Median OS: 12.8 (EV) vs 8.9 months (chemotherapy) (HR 0.70, 95% CI 0.56–0.89; $p=0.001$ )	Median OS: 12.6 (EV) vs 10.9 months (chemotherapy) (HR 0.85, 95% CI 0.57–1.27)
<b>EV-302</b> <sup>44</sup>	1st line	III	Enfortumab vedotin and pembrolizumab/cisplatin or carboplatin and gemcitabine	239 (27%), 886	Median OS: 31.5 (EV and Pem) vs 16.1 months (chemotherapy) (HR 0.47, 95% CI 0.38–0.58; $p=0.001$ )	Median OS: 12.7 (EV and Pem) vs 6.2 months (chemotherapy) (HR 0.50, 95% CI 0.35–0.71)
<b>THOR</b> <sup>45</sup>	2nd/3rd line	III	Erdafitinib/docetaxel or vinflunine	89 (33%), 266	Median OS: 12.1 (erdafitinib) vs 7.8 months (chemotherapy) (HR 0.64, 95% CI 0.47–0.88)	Median OS: 23.3 (erdafitinib) vs 10.5 months (chemotherapy) (HR 0.34, 95% CI 0.18–0.64)

**Abbreviations:** UC, urothelial carcinoma; UTUC, upper tract urothelial carcinoma; BSC, best supportive care; PD-L1, programmed cell death ligand-1; EV, enfortumab vedotin; Pem, pembrolizumab; OS, overall survival; ORR, overall response rate.

an OS of 19.9 months with maintenance avelumab (HR 0.90, 95% CI 0.59–1.39) compared to 22.5 months in lower tract urothelial carcinoma (LTUC) (HR 0.54, 95% CI 0.38–0.76).<sup>46</sup>

There are inconsistent data in the front-line setting with the use of combined chemotherapy–ICIs. KEYNOTE-361 (NCT02853305) and IMvigor130 (NCT02807636) found no benefit in the addition of pembrolizumab and atezolizumab, respectively, to platinum-based combination chemotherapy.<sup>36,37</sup> CheckMate 901 (NCT03036098) reported PFS and OS benefits with nivolumab in combination with cisplatin-based chemotherapy, which are likely to reflect the response to maintenance ICIs.<sup>47</sup>

The DANUBE trial aimed to determine whether durvalumab, with or without tremelimumab, improves survival in the first-line setting for treatment-naïve metastatic UC. This phase III RCT found that durvalumab alone, or in combination with tremelimumab, was not superior to chemotherapy as the first-line treatment for metastatic UC.<sup>35</sup> However, subgroup analysis in patients with high PD-L1 who received durvalumab revealed that UTUC patients had a significantly increased OS compared to chemotherapy (HR 0.47, 95% CI 0.27–0.79). Notably, the PD-L1 high LTUC cohort showed no improvement in OS compared to first-line chemotherapy (HR 1.04, 95% CI 0.81–1.33).<sup>35</sup> Whilst the smaller number of UTUC patients and wide 95% CI must be taken into consideration, these subgroup data suggest an unknown molecular factor, irrespective of PD-L1 status, which is present in UTUC and contributes to its response to PD-L1 inhibition.

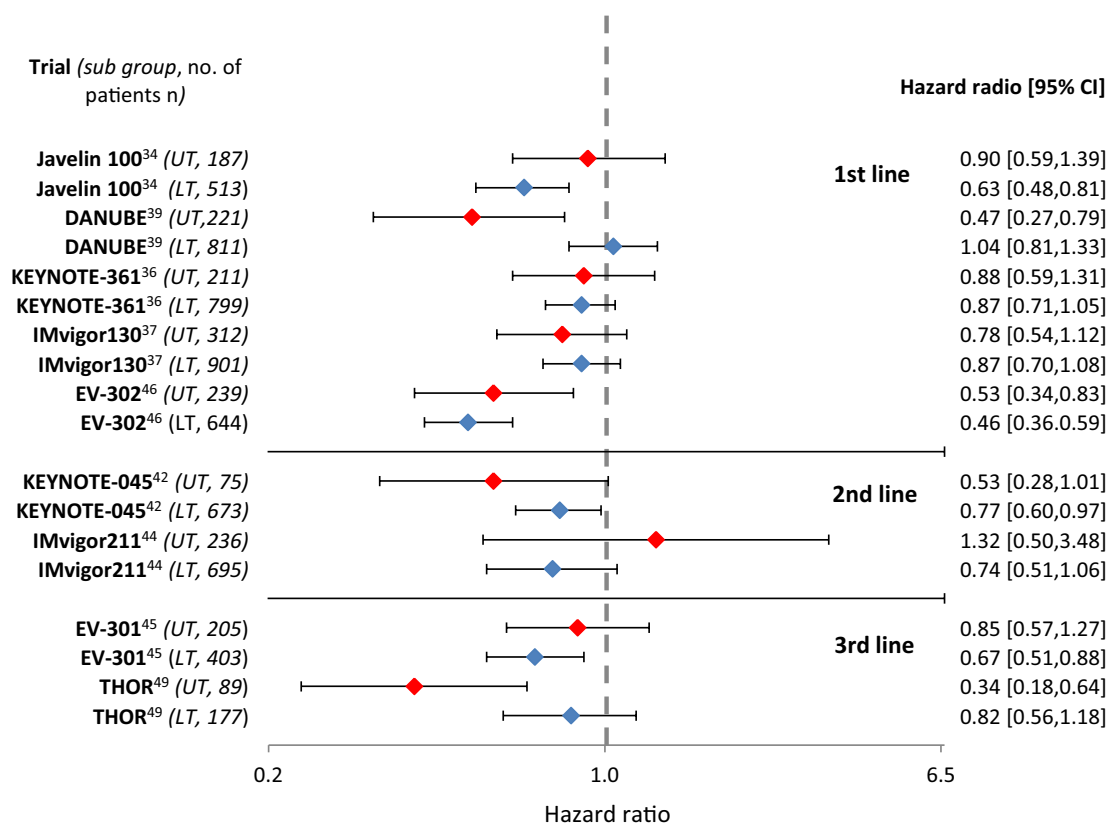
ICIs are approved for UC as first-line treatment in cisplatin-ineligible patients with PD-L1-positive tumours. Two phase II single-arm trials demonstrated the benefit of ICIs for cisplatin-ineligible UC patients and included patients with UTUC. KEYNOTE-052 (NCT02335424) recruited 69 (19%) UTUC patients and demonstrated an overall response rate (ORR) to pembrolizumab of 22% (95% CI 0.12–0.25) versus 28% (95% CI 0.23–0.34) in patients with LTUC.<sup>38</sup> IMvigor210 (NCT02951767) included 33 patients (27.7%) with UTUC. Notably, the UTUC subgroup demonstrated an ORR to atezolizumab of 39% (95% CI 0.17–0.51) compared to LTUC, where the ORR was 17% (95% CI 0.09–0.26).<sup>39</sup>

The treatment of platinum-refractory UTUC remains challenging. In the second line, a range of ICIs has been deemed effective. KEYNOTE-045 (NCT02256436) provided level 1 evidence demonstrating a significant improvement in OS in UC patients who received pembrolizumab (10.3 months) over single-agent chemotherapy (7.4 months) in a second-line setting (HR 0.73, 95% CI 0.59–0.91;  $p=0.002$ ).<sup>40</sup> UTUC subgroup analysis showed an improved OS with pembrolizumab compared to second-line chemotherapy (HR 0.53, 95% CI 0.28–1.01).<sup>39</sup> Phase II single-arm trials have also demonstrated improved ORRs with ICIs versus second-line chemotherapy. CheckMate 275 (NCT02387996) reported an ORR of 19.6% (95% CI 15–24) in response to second-line nivolumab, with an 11% (95% CI 4–21) ORR in UTUC subgroup analysis.<sup>42</sup> Whilst atezolizumab was shown to be effective in phase II trials, the only phase III RCT to date, IMvigor211 (NCT02302807), did not show an improvement in OS with atezolizumab over second-line chemotherapy, although the predefined population was selected for overexpression of PD-L1, which limited further statistical analysis. The UTUC subgroup with PD-L1 expression >5% showed no improvement in OS (HR 1.32, 95% CI 0.50–3.48).<sup>41</sup>

Overall, evidence indicates that ICIs are effective in treating metastatic UTUC. As *FGFR* mutated UCs have been associated with decreased TMB and T-cell infiltration, it has been suggested that patients with UTUC may respond poorly to ICIs. However, data from IMvigor210 and CheckMate 275 showed similar responses to ICIs in *FGFR3* mutant versus wild-type UC.<sup>19</sup> The variation in response to ICIs across several phase III RCTs (Figure 1) highlights the high degree of molecular heterogeneity in UC. At present, unknown biological factors are likely to be relevant in predicting responses, and further studies are needed to identify these factors.

## Targeted Therapy and Future Work

Targeted therapy is an effective treatment approach for metastatic UTUC. With the development of acquired resistance to chemotherapy and only a minority of UC patients showing a durable response to ICIs, there is a need to explore novel therapies. The antibody–drug conjugate (ADC) enfortumab vedotin (EV), which targets the surface protein Nectin-4 that is highly expressed in UC, was granted accelerated approval by the United States Food and Drug Administration (US FDA). EV-301 (NCT03474107), a phase III trial, was conducted in patients with metastatic UC who had progressed on platinum-based chemotherapy and ICIs. The subgroup analysis showed a significant benefit in OS, although the UTUC subgroup (205 patients, 34%) did not reach statistical significance (HR 0.85, 95% CI 0.57–1.27).<sup>43</sup> More recently, the phase III trial EV-302 (NCT04223856), which recruited nearly 900 patients with untreated metastatic UC, found that OS



**Figure 1** Forest plot of hazard ratios in upper and lower tract urothelial carcinoma subgroups across first-, second- and third-line RCTs.

doubled in patients who received EV combined with pembrolizumab compared to platinum-based chemotherapy (HR 0.47, 95% CI 0.38–0.58;  $p=0.001$ ).<sup>44</sup> This groundbreaking study has changed first-line therapy for metastatic UC, with EV combined with pembrolizumab recently becoming standard of care.<sup>48</sup> Subgroup analysis revealed similar responses in both upper and lower tract UC (Figure 1). With ADCs combining a cytotoxic yet precise effect, it is likely that these drugs will play a major role in the future treatment of UTUC, particularly as new targets emerge.

Mutational analysis revealed that UTUCs harboured a greater proportion of *FGFR3* mutations.<sup>15</sup> Erdafitinib, a pan-*FGFR* kinase inhibitor, is the first targeted therapy approved by the US FDA in metastatic and locally advanced UC. Approval followed a phase II trial (NCT02365597) which demonstrated a 40% response rate in UC patients with *FGFR* alterations.<sup>49</sup> More recently, THOR, a randomised phase III trial (NCT03390504), found significant improvement in OS in UC patients with *FGFR* alterations who received erdafitinib (12.1 months) versus single-agent chemotherapy (7.8 months) (HR 0.64, 95% CI 0.47–0.88;  $p=0.005$ ).<sup>45</sup> This demonstrated level 1 evidence supporting the use of erdafitinib in patients who progressed after one or two prior treatments, including ICIs. Moreover, the UTUC subgroup analysis highlighted even greater efficacy (HR 0.34, 95% CI 0.18–0.64;  $p=0.005$ ), suggesting that currently unknown molecular factors, independent of *FGFR*, contribute to the response.

## Conclusion

UTUC remains a challenging cancer to treat. Its rarity and subsequent lack of high-level evidence mean that its current management mirrors that of UC. EV combined with pembrolizumab is the new first-line standard of care and appears effective across both UCB and UTUC. Advances in determining the molecular landscape have highlighted differences between UTUC and UCB. Although UTUCs have been previously deemed immunogenically ‘cold tumours’, data still supports the use of ICIs in the metastatic setting. Targeted therapy has been shown to be effective and *FGFR* testing is recommended for all patients diagnosed with UC. As UTUCs express a greater frequency of *FGFR* alterations, pan-*FGFR*

inhibitors are likely to benefit more patients with UTUCs. Further collaborative work focusing on this rare population is required to explore molecular alterations and drive future precision medicine strategies.

## Disclosure

Dr Francesca Jackson-Spence reports travel expenses from EUSA and Roche, outside the submitted work. The authors report no other conflicts of interest in this work.

## References

- Munoz JJ, Ellison LM. Upper tract urothelial neoplasms: Incidence and survival during the last 2 decades. *J Urol.* 2000;164(5):1523–1525. doi:10.1016/S0022-5347(05)67019-X
- Margulis V, Shariat SF, Matin SF, et al. Outcomes of radical nephroureterectomy: a series from the upper tract urothelial carcinoma collaboration. *Cancer.* 2009;115(6):1224–1233. doi:10.1002/cncr.24135
- Powles T, Bellmunt J, Comperat E. Bladder cancer: ESMO clinical practice guideline for diagnosis, treatment and follow-up☆. *Ann Oncol.* 2022;33:244–258. doi:10.1016/j.annonc.2021.11.012
- Green DA, Rink M, Xylinas E, et al. Urothelial carcinoma of the bladder and the upper tract: disparate twins. *J Urol.* 2013;189(4):1214–1221. doi:10.1016/j.juro.2012.05.079
- Soria F, Shariat SF, Lerner SP, et al. Epidemiology, diagnosis, preoperative evaluation and prognostic assessment of upper-tract urothelial carcinoma (UTUC). *World J Urol.* 2017;35(3):379–387. doi:10.1007/s00345-016-1928-x
- Chen TS, Chen YT, Wang HJ, et al. The prognostic impact of tumor Location in pT3N0M0 upper urinary tract urothelial carcinoma: a retrospective cohort study. *Front Oncol.* 2022;12:850–874.
- Singla N, Fang D, Su X, et al. A multi-institutional comparison of clinicopathological characteristics and oncologic outcomes of upper tract urothelial carcinoma in China and the United States. *J Urol.* 2017;197(5):1208–1213. doi:10.1016/j.juro.2016.11.094
- Rouprêt M, Yates DR, Comperat E, Cussenot O. Upper urinary tract urothelial cell carcinomas and other urological malignancies involved in the hereditary nonpolyposis colorectal cancer (lynch syndrome) tumor spectrum. *Eur Urol.* 2008;54(6):1226–1236. doi:10.1016/j.eururo.2008.08.008
- Rouprêt M, Babjuk M, Compérat E, et al. European guidelines on upper tract urothelial carcinomas: 2013 update. *Eur Urol.* 2013;63(6):1059–1071. doi:10.1016/j.eururo.2013.03.032
- Margolin EJ, Matulay JT, Li G, et al. Discordance between ureteroscopic biopsy and final pathology for upper tract urothelial carcinoma. *J Urol.* 2018;199(6):1440–1445. doi:10.1016/j.juro.2018.02.002
- Lughezzani G, Burger M, Margulis V, et al. Prognostic factors in upper urinary tract urothelial carcinomas: a comprehensive review of the current literature. *Eur Urol.* 2012;62(1):100–114. doi:10.1016/j.eururo.2012.02.030
- Dinney CPN, McConkey DJ, Millikan RE, et al. Focus on bladder cancer. *Cancer Cell.* 2004;6(2):111–116. doi:10.1016/j.ccr.2004.08.002
- Cancer Genome Atlas Research Network. Comprehensive molecular characterization of urothelial bladder carcinoma. *Nature.* 2014;507(7492):315–322. doi:10.1038/nature12965
- Robertson AG, Kim J, Al-Ahmadie H, et al. Comprehensive molecular characterization of muscle-invasive bladder cancer. *Cell.* 2017;171(3):540–556.
- Robinson BD, Vlachostergios PJ, Bhinder B, et al. Upper tract urothelial carcinoma has a luminal-papillary T-cell depleted contexture and activated FGFR3 signaling. *Nat Commun.* 2019;10(1):1–11. doi:10.1038/s41467-019-10873-y
- Audenet F, Isharwal S, Cha EK, et al. Clonal relatedness and mutational differences between upper tract and bladder urothelial carcinoma. *Clin Cancr Res.* 2019;25(3):967–976. doi:10.1158/1078-0432.CCR-18-2039
- Moss TJ, Qi Y, Xi L, et al. Comprehensive genomic characterization of upper tract urothelial Carcinoma. *Eur Urol.* 2017;72(4):641–649. doi:10.1016/j.eururo.2017.05.048
- Chen S, Zhang N, Shao J, Wang T, Wang X. Multi-omics perspective on the tumor microenvironment based on PD-L1 and CD8 T-Cell infiltration in urothelial cancer. *J Canc.* 2019;10(3):697–707. doi:10.7150/jca.28494
- Wang L, Gong Y, Saci A, et al. Fibroblast growth factor receptor 3 alterations and response to PD-1/PD-L1 blockade in patients with metastatic urothelial cancer. *Eur Urol.* 2019;76(5):599–603. doi:10.1016/j.eururo.2019.06.025
- Patel SP, Kurzrock R. PD-L1 Expression as a predictive biomarker in cancer immunotherapy. *Mol Cancer Ther.* 2015;14(4):847–856. doi:10.1158/1535-7163.MCT-14-0983
- Brown GA, Busby JE, Wood CG, et al. Nephroureterectomy for treating upper urinary tract transitional cell carcinoma: time to change the treatment paradigm? *BJU Int.* 2006;98(6):1176–1180. doi:10.1111/j.1464-410X.2006.06524.x
- Birtle A, Johnson M, Chester J, et al. Adjuvant chemotherapy in upper tract urothelial carcinoma (the POUT trial): a Phase 3, open-label, randomised controlled trial. *Lancet.* 2020;395(10232):1268–1277. doi:10.1016/S0140-6736(20)30415-3
- Kim YR, Lee JL, You D, et al. Gemcitabine plus split-dose cisplatin could be a promising alternative to gemcitabine plus carboplatin for cisplatin-unfit patients with advanced urothelial carcinoma. *Canc Chemother Pharmacol.* 2015;76(1):141–153. doi:10.1007/s00280-015-2774-z
- Coleman JA, Yip W, Wong NC, et al. Multicenter phase II clinical trial of gemcitabine and cisplatin as neoadjuvant chemotherapy for patients with high-grade upper tract urothelial carcinoma. *J Clin Oncol.* 2023;41(8):1618–1625. doi:10.1200/JCO.22.00763
- Leow JJ, Chong YL, Chang SL, Valderrama BP, Powles T, Bellmunt J. Neoadjuvant and adjuvant chemotherapy for upper tract urothelial carcinoma: a 2020 systematic review and meta-analysis, and future perspectives on systemic therapy. *Eur Urol.* 2021;79(5):635–654. doi:10.1016/j.eururo.2020.07.003
- Mori K, Katayama S, Laukhtina E, et al. Discordance between clinical and pathological staging and grading in upper tract Urothelial carcinoma. *Clin Genitourin Canc.* 2022;20(1):95.e1–e95.e6. doi:10.1016/j.clgc.2021.10.002
- Necchi A, Anichini A, Raggi D, et al. Pembrolizumab as neoadjuvant therapy before radical cystectomy in patients with muscle-invasive urothelial bladder carcinoma (PURE-01): An open-label, single-arm, phase II study. *J Clin Oncol.* 2018;36(34):3353–3360. doi:10.1200/JCO.18.01148



28. Bellmunt J, Hussain M, Gschwend JE, et al. Adjuvant atezolizumab versus observation in muscle-invasive urothelial carcinoma (IMvigor010): a multicentre, open-label, randomised, phase 3 trial. *Lancet Oncol.* 2021;22(4):525–537. doi:10.1016/S1470-2045(21)00004-8
29. Bajorin DF, Witjes JA, Gschwend JE, et al. Adjuvant nivolumab versus placebo in muscle-invasive urothelial carcinoma. *N Engl J Med.* 2021;384(22):2102–2114. doi:10.1056/NEJMoa2034442
30. Necchi A, Martini A, Raggi D, et al. A feasibility study of preoperative pembrolizumab before radical nephroureterectomy in patients with high-risk, upper tract urothelial carcinoma: PURE-02. *Urol Oncol.* 2022;40(1):10.e1–e10. doi:10.1016/j.urolonc.2021.05.014
31. Teo MY, Guercio BJ, Pietzak EJ, et al. Neoadjuvant nivolumab (N) + ipilimumab (I) in cisplatin-ineligible patients with upper tract urothelial cancer (UTUC). *J Clin Orthod.* 2023;41(6):511.
32. Witjes JA, Bruins HM, Cathomas R, et al. European Association of Urology Guidelines on muscle-invasive and metastatic bladder cancer: summary of the 2020 Guidelines. *Eur Urol.* 2021;79(1):82–104. doi:10.1016/j.eururo.2020.03.055
33. Moschini M, Shariat SF, Roupřet M, et al. Impact of Primary tumor location on survival from the European Organization for the research and treatment of cancer advanced urothelial cancer studies. *J Urol.* 2018;199(5):1149–1157. doi:10.1016/j.juro.2017.11.068
34. Powles T, Park SH, Voog E, et al. Avelumab maintenance therapy for advanced or metastatic urothelial carcinoma. *N Engl J Med.* 2020;383(13):1218–1230. doi:10.1056/NEJMoa2002788
35. Powles T, van der Heijden MS, Castellano D, et al. Durvalumab alone and durvalumab plus tremelimumab versus chemotherapy in previously untreated patients with unresectable, locally advanced or metastatic urothelial carcinoma (Danube): a randomised, open-label, multicentre, phase 3 trial. *Lancet Oncol.* 2020;21(12):1574–1588. doi:10.1016/S1470-2045(20)30541-6
36. Powles T, Csőszi T, Özgüroğlu M, et al. Pembrolizumab alone or combined with chemotherapy versus chemotherapy as first-line therapy for advanced urothelial carcinoma (KEYNOTE-361): a randomised, open-label, phase 3 trial. *Lancet Oncol.* 2021;22(7):931–945. doi:10.1016/S1470-2045(21)00152-2
37. Galsky MD, Arijia JÁA, Bamias A, et al. Atezolizumab with or without chemotherapy in metastatic urothelial cancer (IMvigor130): a multicentre, randomised, placebo-controlled phase 3 trial. *Lancet.* 2020;395(10236):1547–1557. doi:10.1016/S0140-6736(20)30230-0
38. Balar AV, Castellano D, O'Donnell PH, et al. First-line pembrolizumab in cisplatin-ineligible patients with locally advanced and unresectable or metastatic urothelial cancer (KEYNOTE-052): a multicentre, single-arm, Phase 2 study. *Lancet Oncol.* 2017;18(11):1483–1492. doi:10.1016/S1470-2045(17)30616-2
39. Balar AV, Galsky MD, Rosenberg JE, et al. Atezolizumab as first-line treatment in cisplatin-ineligible patients with locally advanced and metastatic urothelial carcinoma: a single-arm, multicentre, phase 2 trial. *Lancet.* 2017;389(10064):67–76. doi:10.1016/S0140-6736(16)32455-2
40. Bellmunt J, de Wit R, Vaughn DJ, et al. Pembrolizumab as Second-Line Therapy for Advanced Urothelial Carcinoma. *N Engl J Med.* 2017;376(11):1015–1026. doi:10.1056/NEJMoa1613683
41. Powles T, Durán I, van der Heijden MS, et al. Atezolizumab versus chemotherapy in patients with platinum-treated locally advanced or metastatic urothelial carcinoma (IMvigor211): a multicentre, open-label, phase 3 randomised controlled trial. *Lancet.* 2018;391(10122):748–757. doi:10.1016/S0140-6736(17)33297-X
42. Sharma P, Retz M, Siefker-Radtke A, et al. Nivolumab in metastatic urothelial carcinoma after platinum therapy (CheckMate 275): a multicentre, single-arm, phase 2 trial. *Lancet Oncol.* 2017;18(3):312–322. doi:10.1016/S1470-2045(17)30065-7
43. Powles T, Rosenberg JE, Sonpavde GP, et al. Enfortumab vedotin in previously treated advanced urothelial carcinoma. *N Engl J Med.* 2021;384(12):1125–1135. doi:10.1056/NEJMoa2035807
44. Powles T, Valderrama BP, Gupta S, et al. Enfortumab Vedotin and Pembrolizumab in Untreated Advanced Urothelial Cancer. *N. Engl J Med.* 2024;390(10):875–888. doi:10.1056/NEJMoa2312117
45. Loriot Y, Matsubara N, Park SH, et al. Phase 3 THOR study: results of erdafitinib versus chemotherapy in patients with advanced or metastatic urothelial cancer with select fibroblast growth factor receptor alterations (FGFRalt). *J. Clin Orthod.* 2023;41(17):4619.
46. Grivas P, Park SH, Voog E, et al. Avelumab first-line maintenance therapy for advanced urothelial carcinoma: comprehensive clinical subgroup analyses from the JAVELIN Bladder 100 Phase 3 Trial. *Eur Urol.* 2023;84(1):95–108. doi:10.1016/j.eururo.2023.03.030
47. Bristol Myers Squibb. Press release, Opdivo (nivolumab) in combination with cisplatin-based chemotherapy shows overall survival and progression free survival benefit for cisplatin eligible patients with unresectable or metastatic urothelial carcinoma in the phase 3 CheckMate-901 trial. New Jersey: USA; 2023. Available from: <https://news.bms.com/news/details/2023/Opdivo-nivolumab-in-Combination-with-Cisplatin-Based-Chemotherapy-Shows-Overall-Survival-and-Progression-Free-Survival-Benefit-for-Cisplatin-Eligible-Patients-with-Unresectable-or-Metastatic-Urothelial-Carcinoma-in-the-Phase-3-CheckMate-901-Trial>. Accessed may 02, 2024.
48. Powles T, Bellmunt J, Comperat E, et al. ESMO guidelines committee. ESMO clinical practice guideline interim update on first-line therapy in advanced urothelial carcinoma. *Ann Oncol.* 2024;S0923-7534(24).
49. Dosne AG, Valade E, Goeyvaerts N, et al. Exposure-response analyses of erdafitinib in patients with locally advanced or metastatic urothelial carcinoma. *Canc Chemother Pharmacol.* 2022;89(2):151–164. doi:10.1007/s00280-021-04381-4

## Cancer Management and Research

Dovepress

### Publish your work in this journal

Cancer Management and Research is an international, peer-reviewed open access journal focusing on cancer research and the optimal use of preventative and integrated treatment interventions to achieve improved outcomes, enhanced survival and quality of life for the cancer patient. The manuscript management system is completely online and includes a very quick and fair peer-review system, which is all easy to use. Visit <http://www.dovepress.com/testimonials.php> to read real quotes from published authors.

Submit your manuscript here: <https://www.dovepress.com/cancer-management-and-research-journal>