

CASE REPORT

RING CHROMOSOME 22: A REVIEW OF THE LITERATURE AND FIRST REPORT FROM INDIA

Mahajan S¹, Kaur A^{2,*}, Singh JR³

***Corresponding Author:** Dr. Anupam Kaur, Department of Human Genetics, Guru Nanak Dev University, Grand Trunk Road, Amritsar, Punjab, 143005, India; Tel.: +91-183-225-8802, Ext. 3447; Cell: +987-223-9393; Fax: +91-183-225-8863, 225-8820; E-mail: anupamkaur@yahoo.com

ABSTRACT

Ring chromosome 22 [r(22)], a rare cytogenetic finding, has been described in nearly 70 cases to date. Cytogenetic investigations were carried out on a 5-year-old male child with microcephaly and intellectual disability. Cytogenetic investigations revealed his karyotype to be 46,XY,r(22). To the best of our knowledge, this is the first report of an r(22) anomaly from India.

Keywords: Ring chromosome 22 [r(22)]; Syndactyly; Intellectual disability

INTRODUCTION

Ring chromosome 22 [r(22)] was first described by Weleber *et al.* in 1968 [1]. Ring chromosomes arise from terminal breaks on both arms of a chromosome followed by fusion. The amount of genetic material lost in this process depends upon the breakpoints. Ring chromosome 22 is usually caused by spontaneous or *de novo* errors very early in the development of the embryo that appear to occur randomly for unknown reasons. Since r(22) is a rare disorder, its incidence is not known. Apart from the usual clinical manifestations, some variations have

also been reported in some studies such as arachnoid cyst in posterior cerebellum [2]. Further investigations by the authors revealed deletion in 22q13.3 (Arylsulphatase A region) visualized by fluorescent *in situ* hybridization (FISH). Hypertension, large ears, hand and feet and torticollis were the other varied features reported [3] (Table 1).

CASE REPORT

The proband, a 5-year-old male with microcephaly and intellectual disability, was referred to the Centre for Genetic Disorders, Guru Nanak Dev University, Amritsar, Punjab, India, for cytogenetic investigations. He was born to healthy, non consanguineous parents aged 32 (mother) and 35 (father) years old, respectively. His older sister (9 years old) was normal. The pregnancy, delivery and neonatal period were uneventful. The mother had one spontaneous abortion and one of her pregnancies was terminated as the fetal heart was absent. The present subject presented delayed milestones with microcephaly. On examination, his head circumference was found to be 46 cm (normal 52.1 cm). Physical features included brachycephalic head, flat face, pointed chin, almond shaped eyes, long eye lashes and epicanthal folds (Figure 1a). His ears were placed higher than the normal position and syndactyly of the second and third toes of right foot was present. He had hypotonia, absence of speech and only started walking at the age of 3 years. Autistic behavior and aggressive nature was also noted.

¹ Centre of Medical Genetics, Sir Ganga Ram Hospital, Rajinder Nagar, New Dehli 110060, India

² Department of Human Genetics, Guru Nanak Dev University, Amritsar, Punjab 143005, India

³ Central University of Punjab, D-13, Civil Station, Bathinda, Punjab 151001, India

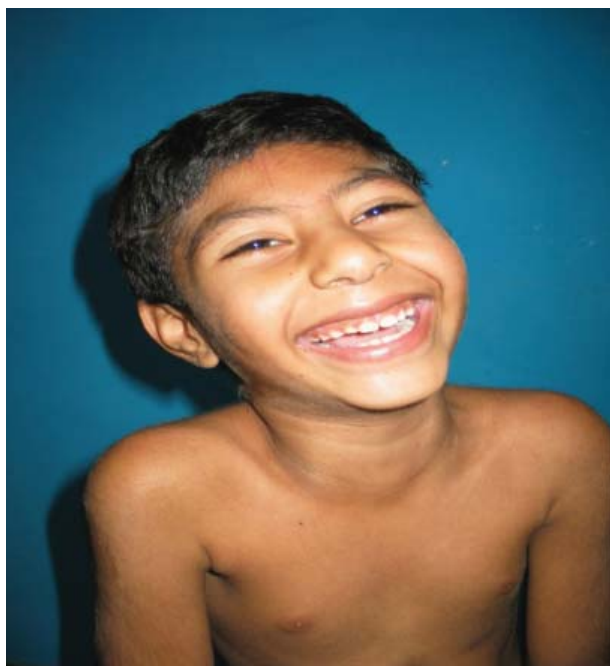

Figure 1. (a) Facial features of r(22) male;

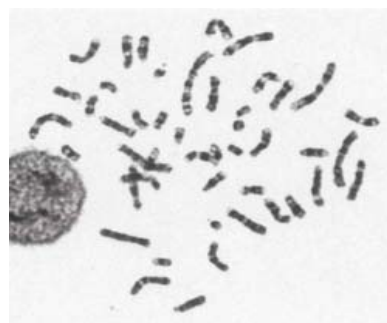

Figure 1. (b) metaphase showing r(22);

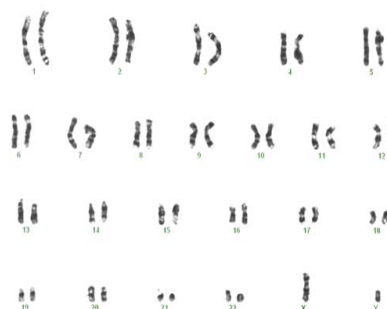


Figure 1. (c) karyotype showing 46,XY, r(22).

A magnetic resonance imaging (MRI) and urine test for metabolic screening revealed no abnormality.

Table 1. Clinical features for ring chromosome 22 syndrome ([+]: present; [-]: not reported).

References Clinical Features	15	17	18	38	26	39	3	40	30	31	32	35	36	37	2	6	This Study
Growth retardation	[+]	[+]	[+]	[+]	[+]	[+]	[+]	[+]	[+]	[+]	[+]	[+]	[+]	[+]	[-]	[+]	[+]
Absent to severe speech impairment	[+]	[-]	[-]	[+]	[+]	[+]	[+]	[+]	[-]	[+]	[+]	[+]	[+]	[+]	[+]	[+]	[+]
Microcephaly	[+]	[-]	[-]	[-]	[-]	[+]	[+]	[+]	[+]	[-]	[-]	[-]	[-]	[+]	[+]	[+]	[+]
Hypotonia	[+]	[+]	[+]	[+]	[+]	[+]	[+]	[+]	[-]	[+]	[+]	[+]	[-]	[+]	[+]	[-]	[+]
Autistic features	[+]	[-]	[-]	[-]	[-]	[+]	[+]	[+]	[-]	[+]	[-]	[+]	[+]	[+]	[+]	[+]	[+]
Hydrocephaly	[-]	[-]	[+]	[+]	[-]	[-]	[-]	[-]	[-]	[-]	[-]	[-]	[-]	[-]	[-]	[-]	[-]
Craniofacial anomalies	[-]	[+]	[-]	[-]	[-]	[+]	[-]	[-]	[-]	[-]	[-]	[-]	[+]	[-]	[-]	[+]	[-]
Epicanthal folds	[+]	[-]	[-]	[-]	[+]	[+]	[+]	[+]	[+]	[-]	[-]	[-]	[-]	[-]	[-]	[+]	[+]
Long eye lashes	[-]	[-]	[-]	[-]	[+]	[+]	[-]	[+]	[+]	[+]	[-]	[-]	[-]	[-]	[-]	[+]	[+]
Full eyebrows	[-]	[-]	[-]	[-]	[-]	[+]	[-]	[+]	[-]	[-]	[+]	[-]	[-]	[-]	[-]	[+]	[-]
Hypertelorism	[-]	[-]	[-]	[-]	[-]	[-]	[+]	[-]	[-]	[-]	[-]	[-]	[-]	[-]	[-]	[-]	[-]
Flat nasal bridge	[-]	[-]	[-]	[-]	[+]	[-]	[-]	[-]	[-]	[+]	[-]	[-]	[-]	[-]	[-]	[-]	[-]
Second and third toe syndactyly	[-]	[-]	[-]	[-]	[-]	[+]	[-]	[+]	[-]	[-]	[-]	[-]	[-]	[-]	[-]	[-]	[+]
Large ears	[+]	[-]	[-]	[-]	[-]	[-]	[+]	[+]	[+]	[-]	[+]	[-]	[-]	[-]	[+]	[-]	[-]
Dental malocclusion	[-]	[-]	[-]	[-]	[-]	[+]	[-]	[+]	[-]	[+]	[-]	[-]	[-]	[-]	[-]	[-]	[-]
High arched palate	[-]	[-]	[+]	[-]	[-]	[-]	[-]	[-]	[-]	[+]	[-]	[-]	[-]	[-]	[-]	[-]	[-]
Unsteady gait	[+]	[-]	[-]	[+]	[-]	[+]	[-]	[-]	[-]	[-]	[-]	[-]	[-]	[-]	[-]	[-]	[-]
Lymphedema	[-]	[-]	[+]	[-]	[+]	[-]	[+]	[-]	[-]	[-]	[-]	[-]	[-]	[-]	[-]	[-]	[-]
Hypertension	[-]	[-]	[-]	[-]	[-]	[+]	[-]	[+]	[-]	[-]	[-]	[-]	[-]	[-]	[-]	[-]	[-]
Seizures	[-]	[-]	[-]	[-]	[-]	[+]	[-]	[+]	[-]	[-]	[-]	[-]	[-]	[-]	[-]	[-]	[-]

Table 2. Common clinical features of ring chromosome 22 and 22q deletion syndrome ([+]: present; [-]: not reported).

References Common Clinical Features	42	43	3	40	43	30	31	35	44	45	36	37	This Study
Mental retardation	[+]	[+]	[+]	[+]	[+]	[+]	[+]	[+]	[-]	[+]	[+]	[+]	[+]
Microcephaly	[-]	[-]	[-]	[-]	[-]	[+]	[-]	[-]	[+]	[-]	[+]	[-]	[+]
Absent to severe speech impairment	[+]	[+]	[+]	[-]	[+]	[-]	[+]	[+]	[-]	[+]	[+]	[+]	[+]
Hypotonia	[+]	[+]	[+]	[-]	[+]	[-]	[-]	[+]	[-]	[+]	[+]	[+]	[+]
Autistic features	[-]	[+]	[+]	[+]	[-]	[-]	[+]	[+]	[-]	[-]	[+]	[+]	[+]
Pointed chin	[-]	[-]	[-]	[-]	[-]	[-]	[-]	[-]	[-]	[-]	[+]	[-]	[+]

RESULTS

Informed parental consent was obtained before the investigations were begun. Peripheral blood of the proband and his parents was cultured in an RPMI 1640 (Biological Industries, Kubbutz Baet Haemek 25225, Israel) using standard protocols. Slides were banded using standard GTG-banding techniques with some modifications [4] such as normal saline was used to wash the slides instead of buffer. Examination of 100 metaphases revealed 46,XY, r(22) in all cells (Figure 1c) of the proband. The parental karyotypes were normal. To the best of our knowledge, this is the first reported case with r(22) from India.

DISCUSSION

The clinical findings of our case were similar to the description in the literature (Table 1). These features overlap with patients presenting terminal 22q13.3 deletion syndrome (Table 2) except for dental malocclusion, seizures, unsteady gait, *etc.* Microcephaly may also be a part of a well recognized syndrome and intellectual disability is a common feature in these individuals [5]. Fluorescent *in situ* hybridization could not be carried out in present case due to some technical reasons.

Ring chromosomes are formed as a result of breakage and reunion in the distal p and q arms accompanying loss of the p arm and satellite materials in these regions. Ring chromosomes, though a rare chromosomal abnormality involves telomere pairing or deletion. The size of the deleted distal q arm segment affects the overall phenotype. In addition to ring formation, deletion of the 22q13 region of chromosome 22 represents a cytogenetic microde-

letion syndrome with severe speech delay, autism, hypotonia, developmental delay and minimal facial dysmorphism [6-8].

Most of the cases reported with r(22) are males and the ratio of females is very much less. There is one report of a 3-year-old girl and another is a case of familial transmission of r(22) from a phenotypically normal mother to her daughter [9,10].

Cases of ring chromosomes usually show a non specific pattern of clinical symptoms; therefore, the presence of growth retardation, microcephaly, speech delay should provide sufficient reason to consider performing a karyotype determination on the patient. Severe growth delay is more common in cases in larger chromosomal rings. The ring behavior and structure causes growth failure, which is often the sole major physical abnormality in many cases of ring syndromes [5,11].

As both the parents of proband showed a normal chromosomal constitution, the aberration found in the proband was considered to be a *de novo* event. Ring formation is associated with deletion of the terminal regions of the chromosome involved. Fluorescent *in situ* hybridization and molecular analyses would be helpful to fully characterize the present case. Testing of the proband helped both in counseling the parents regarding the cause of disease in their child as well as prevention of recurrence of the abnormality in future pregnancies.

ACKNOWLEDGMENTS

We gratefully acknowledge the cooperation of the proband, the assistance of his parents and the financial support from the Department of Biotechnology, New Delhi, India grant number BT/TF/09/21/90 awarded to JRS.

REFERENCES

1. Weleber RG, Hetch F, Giblett ER. Ring-G chromosome, a new G-deletion syndrome? *Am J Dis Child.* 1968; 115(4): 489-493.
2. Koc A, Karaer K, Ergun MA, Yirmibes-Karaoguz M, Kan D, Cansu A, Percin FA. Case with ring 22. *Turkish J Pediatr.* 2008; 50(2): 193-196.
3. Gibbons B, Tan SY, Tam PY. Ring chromosome 22 resulting on a partial monosomy in a mentally retarded boy. *Singapore Med J.* 1999; 40(4): 273-275.
4. Kaur A, Mahajan S, Singh JR. Cytogenetic profile of individuals with mental retardation. *Int J Hum Genet.* 2003; 3(1): 13-16.
5. Kaur A, Dhillon S, Garg PD, Singh JR. Ring chromosome 7 in an Indian woman. *J Intellect Dev Disabil.* 2008; 33(1): 87-94.
6. Demirahan O, Tunc E. Phenotypic correlations in a patient with ring chromosome 22. *Ind J Hum Genet.* 2010; 16(2): 97-99.
7. Kirshenbaum G, Chmura M, Rhone DP. Long arm deletion of chromosome 22. *J Med Genet.* 1998; 25(11): 780.
8. Lam AC, Lai KK, Lam ST. Distinctive phenotype in a case of ring chromosome 22 with features of 22q13.3 deletion syndrome. *Hong Kong J Paediatr.* 2006; 11(4): 317-319.
9. Severian C, Felix S, Bartholome K. Ring chromosome 22: a case report. *Clin Paediatr.* 1991; 203(6): 294-296.
10. Teyssier M, Moreau N. Familial transmission of deleted chromosome 22 [r(22)] in two normal women. *Ann Genet.* 1985; 28(2): 116-118.
11. Kosztolanyi G. Does "ring syndrome" exist? An analysis of 207 case reports on patients with a ring autosome. *Hum Genet.* 1987; 75(2): 174-179.
12. Luciani JJ, De Mas P, Depetris D, Mignon-Ravix C, Bottani A, Prieur M, Jonveaux P, Philippe A, Bourrouillou G, de Martinville B, Delobel B, Vallee L, Croquette MF, Mattei MG. Telomeric 22q13 deletions resulting from rings, simple deletions and translocations: cytogenetic, molecular and clinical analysis of 32 new observations. *J Med Genet.* 2003; 40(9): 690-696.
13. Magenis RE, Armendares S, Hetch F, Weleber RG, Overton K. Identification by fluorescence of two G rings: (46,XY,21r) G deletion syndrome II. *Ann Genet.* 1972; 15(4): 265.
14. Veal RM, Rundle AT, Chitham RC, Saldana-Gracia P. A profoundly mentally handicapped woman with a ring chromosome 22. *J Ment Defic Res.* 1975; 19(3-4): 225-243.
15. Hunter AG, Ray M, Wang HS, Thompson DR. Phenotypic correlations in patients with ring chromosome 22. *Clin Genet.* 1977; 12(4): 239-249.
16. Faed MJ, Roberson J, Field MA, Mellon JP. A chromosome survey of a hospital for the mentally subnormal. *Clin Genet.* 1979; 16(3): 191-204.
17. Fryns JP, Van den Berghe H. Ring chromosome 22 in a mentally retarded child and mosaic 45,XX,-15,-22,t(15;22)(p11;q11)/46,XX,r(22)/46,XX karyotype in the mother. *Hum Genet.* 1979; 47(2): 213-216.
18. Funderburk SJ, Sparkes RS, Klisak I. Phenotypic variation on two patients with a ring chromosome 22. *Clin Genet.* 1979; 16(5): 305-310.
19. Kondo I, Hamaguchi H, Nakajima S, Haneda T. A cytogenetic survey of 449 patients in a Japanese institution for the mentally retarded. *Clin Genet.* 1980; 17(3): 177-182.
20. Hammers AJ, Kelp-de-Pater JM, de France HF. Partial duplication in a ring chromosome 22. A mentally retarded boy with increased levels of arylsulphatase A and alpha galactosidase. *Ann Genet.* 1983; 26(1): 34-37.
21. Stoll C, Roth MP. Segregation of a 22 ring chromosome in three generations. *Hum Genet.* 1983; 63(3): 294-296.
22. Reeve A, Shulman A, Zimmerman AW, Cassidy SB. Methylphenidate therapy for aggression in a man with ring 22 chromosome. Report and literature review. *Arch Neurol.* 1985; 42(1): 69-72.
23. Gustavson KH, Arancibia W, Eriksson U, Svennerholm L. Deleted ring chromosome 22 in a mentally retarded boy. *Clin Genet.* 1986; 29(4): 337-341.
24. Kadotani T, Kanata S, Watanabe Y, Kurosaki T, Toi O. A case of ring chromosome 22 with mental retardation. *Proc Jpn Acad.* 1987; 63(3): 93-95.
25. Naritomi K, Hirayana K. Determination of the breakpoints and the parental origin of ring 22 chromosome: an analysis by high resolution banding technique, quinacrine and silver staining. *J Hum Genet.* 1988; 33(1): 67-73.
26. Severian C, Felix S, Bartholome K. Ring chromosome 22: a case report. *Klin Padiatr.* 1993; 203(6): 294-296.
27. Petrella R, Levine S, Wilmot PL, Ashar KD, Casamassima AC, Shapiro LR. Multiple meningiomas in a patient with constitutional ring chromosome 22. *Am J Med Genet.* 1993; 47(2): 184-186.
28. Snover R, Stone A, Fox C. Ring chromosome 22 and mood disorders. *J Intellect Disabil Res.* 1986; 40(Pt. 1): 82-86.
29. Gibbons B, Tan SY, Tam PY. Ring chromosome 22 resulting on a partial monosomy in a mentally retarded boy. *Singapore Med J.* 1999; 40(4): 273-275.
30. Wenger SL, Boone LY, Cummins JH, Del Vecchio MA, Bay CA, Hummel M, Mowery-Rushton PA. Newborn infant with inherited ring and de novo interstitial deletion on homologous chromosome 22. *Am J Med Genet.* 2000; 91(5): 351-354.

31. De Mas P, Chassaing N, Chaix Y, Vincent MC, Julia S, Bourrouillon G, Calvas P, Beith E. Molecular characterization of a ring chromosome 22 in a patient with severe language delay: a contribution to the refinement of the subtelomeric 22q deletion syndrome. *J Med Genet.* 2002; 39(4): e17.
32. Ishmael HA, Cataldi D, Begleiter ML, Pasztor LM, Butler MG. (2003) Five new subjects with ring chromosome 22. *Am J Med Genet A.* 2003; 63(5): 410-414.
33. Bertini V, Valetto A, Battini R, Rossi S, Giuliani C, Rapallini E, Simi P. (2003) Characterization of a 22 ring chromosome in a child with language delay and autism (Abstract). Proceedings of the 4th European Cytogenetics Conference, Bologna, Italy, 6-9 September, 2003.
34. Chen CP, Chen R, Chang TY, Lee CC, Chen LF, Tzen CY, Wang W, Lin CJ, Yang BP, Yang LS. Prenatal diagnosis of mosaic ring chromosome 22 associated with cardiovascular abnormalities and interuterine growth restriction. *Prenat Diagn.* 2003; 23(1): 40-43.
35. Battini R, Battaglia A, Bertini V, Cieni G, Parrini B, Rapalini E, Simi P, Tinelli F, Valetto A. Characterization of the phenotype and identification of the deletion in a new patient with ring chromosome 22. *Am J Med Genet.* 2004; 130(2): 196-199.
36. Jefferies AR, Curran S, Elmslie F, Sharma A, Wenger S, Hummel M, Powell J. Molecular phenotypic characterization of ring chromosome 22. *Am J Med Genet A.* 2005; 137(2): 139-147.
37. Lam AC, Lai KK, Lam ST. Distinctive phenotype in a case of ring chromosome 22 with features of 22q13.3 deletion syndrome. *HKJ Paediatr.* 2006; 11(4): 317-319.
38. Tommerup N, Lothe R. Constitutional ring chromosome and tumour suppressor genes. *J Med Genet.* 1992; 29(12): 879-882.
39. Assumpcao FB Jr. Brief report: a case of chromosome 22 aberration associated with autistic syndrome. *J Autism Dev Disord.* 1998; 28(3): 253-256.
40. MacLean JE, Teshima IE, Szatmani P, Nowaczyk MJ. Ring chromosome 22 and autism: report and review. *Am J Med Genet.* 2000; 90(5): 382-385.
41. Nesslinger NJ, Gorsky JL, Kurczynski TW, Shapira SK, Siegel-Bartelt J, Dumanski JP, Cullen RF Jr, French BR, McDermid HE. Clinical, cytogenetic, and molecular characterization of severe patients with deletions of chromosome 22q13.3. *Am J Hum Genet.* 1985; 54(3): 464-472.
42. Wong AC, Ning Y, Flint J, Clark K, Dumanski JP, Ledbetter DH, McDermid HE. Molecular characterization of a 130-kb terminal microdeletion at 22q in a child with mental retardation. *Am J Hum Genet.* 1997; 60(1): 113-120.
43. Phelan MC, Rogers RC, Saul RA, Stapleton GA, Sweet K, McDermid H, Shaw SR, Claytor J, Willis J, Kelly DP. 22q13 Deletion syndrome. *Am J Med Genet.* 2001; 101(2): 91-99.
44. Delcan J, Orera M, Linares R, Saavedra D, Palsmar A. A case of ring chromosome 22 with deletion of the 22q13.3 region associated with agenesis of the corpus callosum, formix and septum pellucidum. *Prenat Diagn.* 2004; 24(8): 635-637.
45. Manning MA, Cassidy SB, Clercuzio, C, Chery AM, Schwatz S, Hudgins Z, Enns GM, Hoyme HE. Terminal 22q deletion syndrome: a newly recognized cause of speech and language disability in the autism spectrum. *Paediatrics.* 2004; 114(2): 451-457.