

Research Article

# Low-temperature radiofrequency coblation reduces treatment interval and post-operative pain of laryngotracheal recurrent respiratory papillomatosis

Fang Hao, Liyan Yue, Xiaoyan Yin, Xiaotong Wang and  Chunguang Shan

Department of Otolaryngology, The Second Affiliated Hospital of Hebei Medical University, Shijiazhuang 050000, Hebei, China

**Correspondence:** Chunguang Shan (shanchunguang@126.com)



Laryngeal papillomatosis is a benign disease in the larynx but with the potential to develop into significant complications as a result of its high recurrence rate. CO<sub>2</sub> laser and radiofrequency controlled ablation (coblation) have been used to treat recurrent respiratory papillomatosis, but detailed comparisons of their respective treatment outcomes are not fully investigated. This retrospective study examines the procedure time, time interval between interventions, blood loss during operation, post-operative complications and pain scores among patients who received either CO<sub>2</sub> laser or radiofrequency coblation interventions for laryngotracheal recurrent respiratory papillomatosis. Compared with CO<sub>2</sub> laser intervention, radiofrequency coblation significantly reduced operation time, time interval between interventions, blood loss during operation and number of times bipolar electrocoagulation needed in each procedure. Post-operatively, pain scores after radiofrequency coblation were significantly lower than those after CO<sub>2</sub> laser intervention. Incidence rates of post-operative complications, in terms of palate pharyngeal mucosa damage, bleeding and subcutaneous emphysema, were also significantly reduced after radiofrequency coblation. Low-temperature radiofrequency coblation is a superior intervention compared with CO<sub>2</sub> laser against laryngotracheal recurrent respiratory papillomatosis.

## Introduction

Laryngeal papillomatosis is a benign disease in the larynx but with the potential to develop into significant complications as a result of its high recurrence rate. In the United States, it is estimated that the incidence rate of laryngeal papillomatosis is 4.3 cases per 100000 population in children [1], which is also a common cause of airway obstruction, aphonia and hoarseness among paediatric patients. Laryngeal papillomatosis cases are often recurrent, and its recurrence is more frequent among children than adults. Although this disease usually becomes quiescent when reaching adulthood, children often need multiple surgical procedures to control symptoms at young age [2].

In 1990, the human papilloma virus (HPV) was identified as the aetiological agent responsible for laryngotracheal papillomatosis, and HPV type 6 and type 11 in particular cause benign airway papillomata. Incidents of recurrent respiratory papillomatosis are usually unpredictable and recurrent, and frequently show resistance to treatments [2]. Although various medical and surgical approaches have been developed to treat recurrent respiratory papillomatosis, there have been few studies comparing efficacy of different treatments [1]. To date, CO<sub>2</sub> laser is still the preferred technique to treat laryngeal papillomata in many Chinese hospitals, and laryngeal microdebrider has become more popular due to shorter procedure time and less chance of scarring [3].

Recently, radiofrequency controlled ablation (coblation) has been increasingly performed in otolaryngological procedures [4–6]. The first application of radiofrequency coblation was reported in 2003 for

Received: 13 June 2019  
Revised: 04 May 2020  
Accepted: 07 May 2020

Accepted Manuscript online:  
19 May 2020  
Version of Record published:  
26 May 2020

the resection of tracheal recurrent respiratory papillomatosis [7]. The non-thermally disruptive property, as well as precision, makes radiofrequency coblation an increasingly popular therapy for laryngotracheal recurrent respiratory papillomatosis.

In this retrospective study, we examined the procedure time, time interval between interventions, blood loss during operation, post-operative complications and pain scores among patients who received either CO<sub>2</sub> laser or radiofrequency coblation treatments for laryngotracheal recurrent respiratory papillomatosis.

## Materials and methods

### Patients

All patients who met the following inclusion criteria were recruited: (1) with laryngotracheal recurrent respiratory papillomatosis; (2) treated with either CO<sub>2</sub> laser or radiofrequency coblation for a minimum of 5 years. The time interval between surgical interventions required for symptomatic control was determined, after either CO<sub>2</sub> laser or coblation interventions, respectively.

### Coblation procedure

Briefly, patients were put under general anaesthesia. The zero-eight Hopkins rod endoscope and camera were employed, together with the Storz C laryngoscope (Storz, Tuttlingen, Germany) to visualise the tracheobronchial lesion. The tip of an EICA7070-01 PROCISE LW wand (Arthrocare, U.S.A.) was used in the coblation with power level set at 800–1200 J. The tip of the wand was placed on the lesion at a 90-degree angle to minimise damage to adjacent tissues.

### CO<sub>2</sub> laser procedure

Briefly, patients were put under general anaesthesia. A 1.27-cm 3M tape was used to carefully wound 5.1 cm up the endotracheal tube balloon. Moist cottonoids attached to long strings were placed in the subglottic space for protection. Laryngoscopy was performed with a laryngoscope using a tooth guard. A model 450 Coherent CO<sub>2</sub> laser was used to vaporise the papillomas, controlled by a micromanipulator attached to a Zeiss operating microscope.

### Blood loss during operation

Blood loss in operation was assessed by swab weighing as previously reported [8]. Briefly, the swabs were weighed as soon as possible after contamination with blood so that the loss by evaporation is minimised. In the case of uncontrollable bleeding, bipolar electrocoagulation was performed, and the number of times recorded for each surgery.

### Post-operative complications and pain scores

All patients were observed overnight after the procedure, complications were treated accordingly and subsequently recorded. The next morning before being discharged, pain severity of all patients were assessed using the visual analogue scales (VAS), where patients were instructed to indicate their pain severity by marking a scale from 0 to 10 (0 for 'no pain at all' and 10 for 'maximal pain'). Pain scores were categorised into after CO<sub>2</sub> laser or after radiofrequency coblation, respectively.

### Statistical analysis

Statistical analysis was performed using SPSS software (SPSS Inc., U.S.A.). Values are mean  $\pm$  standard deviation (SD). Normality of data distribution was tested using the Kolmogorov–Smirnov test, and Student's *t* test and chi-square test were used to analyse data significance for normally and non-normally distributed data, where appropriate. *P* < 0.05 was considered as statistically significant.

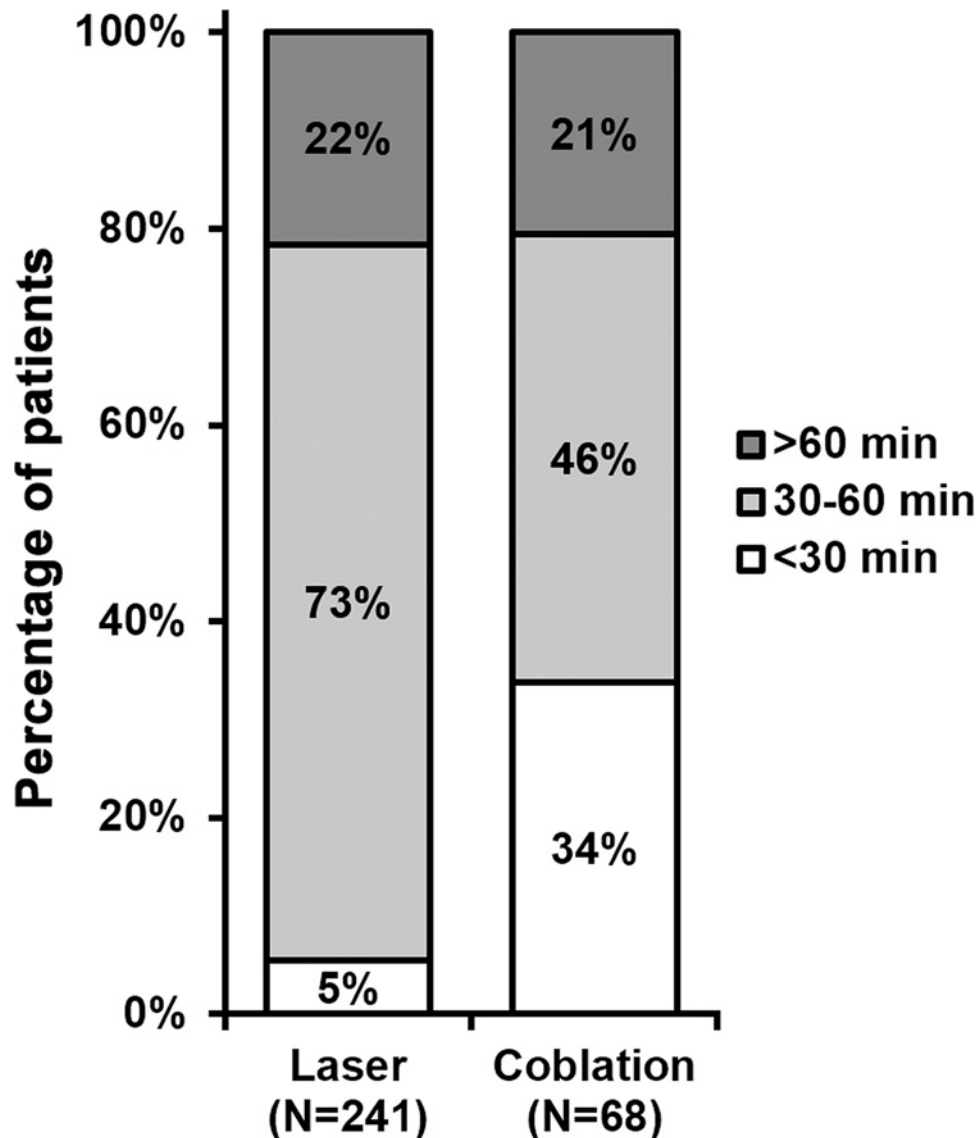
## Results

We retrieved patient records in the Second Affiliated Hospital of Hebei Medical University, and patients fitting the following criteria were analysed in the current study: (1) with laryngotracheal recurrent respiratory papillomatosis and full recorded timeline of receiving either CO<sub>2</sub> laser or radiofrequency coblation for a minimum of 5 years; (2) age > 25 years; (3) with operative records of blood loss and bipolar electrocoagulation; (4) with records of post-operative complications and pain scores. As shown in Table 1, a total of 41 patient records fulfilled the above criteria, of which 19 were males and 22 were females. Among all 41 patients, 241 CO<sub>2</sub> laser interventions and 68 radiofrequency coblation interventions were performed.

**Table 1 Patient characteristics**

Parameters	
Total number	41
Gender (male/female)	19/22
Age (years)	38.6 ± 6.1
Times of procedures (n)	
Laser	241
Coblation	68

*n* indicates number of times each procedure was performed in all patients. Values are mean ± SD.



**Figure 1. Operation time of each procedure**

*n* indicates number of times each procedure was performed in all patients. Percentages do not sum up to 100% due to rounding.

Upon examining their records, we found that percentages of operation time over 60 min were comparable between the two types of interventions (Figure 1). On the other hand, majority (73%) of CO<sub>2</sub> laser took 30–60 min to complete compared with 46% for coblation procedure. Notably, 34% coblation procedures were completed within 30 min, markedly lower than 5% for CO<sub>2</sub> laser of the same operation time category. Furthermore, the median time length of

**Table 2 Median time length of procedures**

	Laser (n=241)	Coblation (n=68)
Median time length (min)	51	39*
Range of time length (min)	25–74	22–69

\* $P < 0.05$ .

**Table 3 Post-operative complications after each procedure**

Complications [% (n)]	Laser (n=241)	Coblation (n=68)
Palate pharyngeal mucosa damage	22.0% (53)	11.7% (8)*
Bleeding	12.4% (30)	5.9% (4)*
Subcutaneous emphysema	6.6% (16)	4.4% (3)*
Vocal cord adhesion	3.7% (9)	4.4% (3)
Laryngostenosis	2.9% (7)	2.9% (2)
Asphyxia	0.8% (2)	1.4% (1)

\* $P < 0.05$ .

coblation procedure was 39 min (range: 22–69 min), while the median time length of CO<sub>2</sub> laser was 51 min (range: 25–74 min) (Table 2). In addition, the time interval between surgical interventions required for symptomatic control was determined. As shown in Figure 2, the time interval after CO<sub>2</sub> laser was significantly shorter than that after coblation intervention.

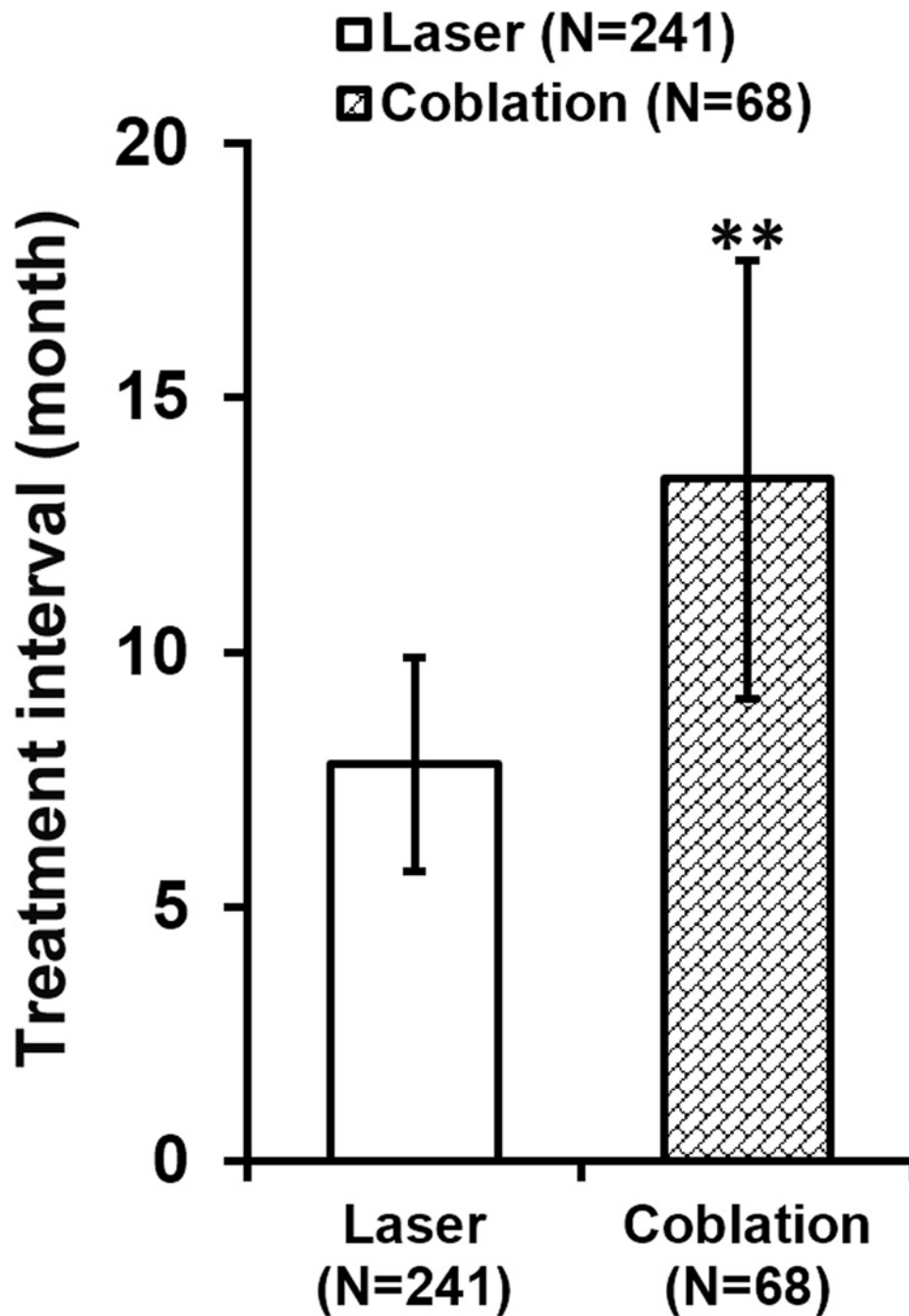
During each procedure, amount of blood loss was measured by swab weighing, and we found that on average, coblation significantly reduced the blood loss compared with CO<sub>2</sub> laser (Figure 3). Furthermore, the number of times bipolar electrocoagulation was performed to control bleeding during operation was also analysed, where bipolar electrocoagulation was used much less frequently during coblation than during CO<sub>2</sub> laser (Figure 4).

After completion of each operation, patients were monitored to record their complications (Table 3). Incidence rates of palate pharyngeal mucosa damage, bleeding and subcutaneous emphysema were significantly lowered after coblation compared with after CO<sub>2</sub> laser, while incidence rates of vocal cord adhesion, laryngostenosis and asphyxia were indistinguishable between the two interventions. After each procedure and before being discharged, post-operative pain of all patients was evaluated by VAS scores (Figure 5), which exhibited categorically reduced VAS scores following coblation as compared with following CO<sub>2</sub> laser.

## Discussion

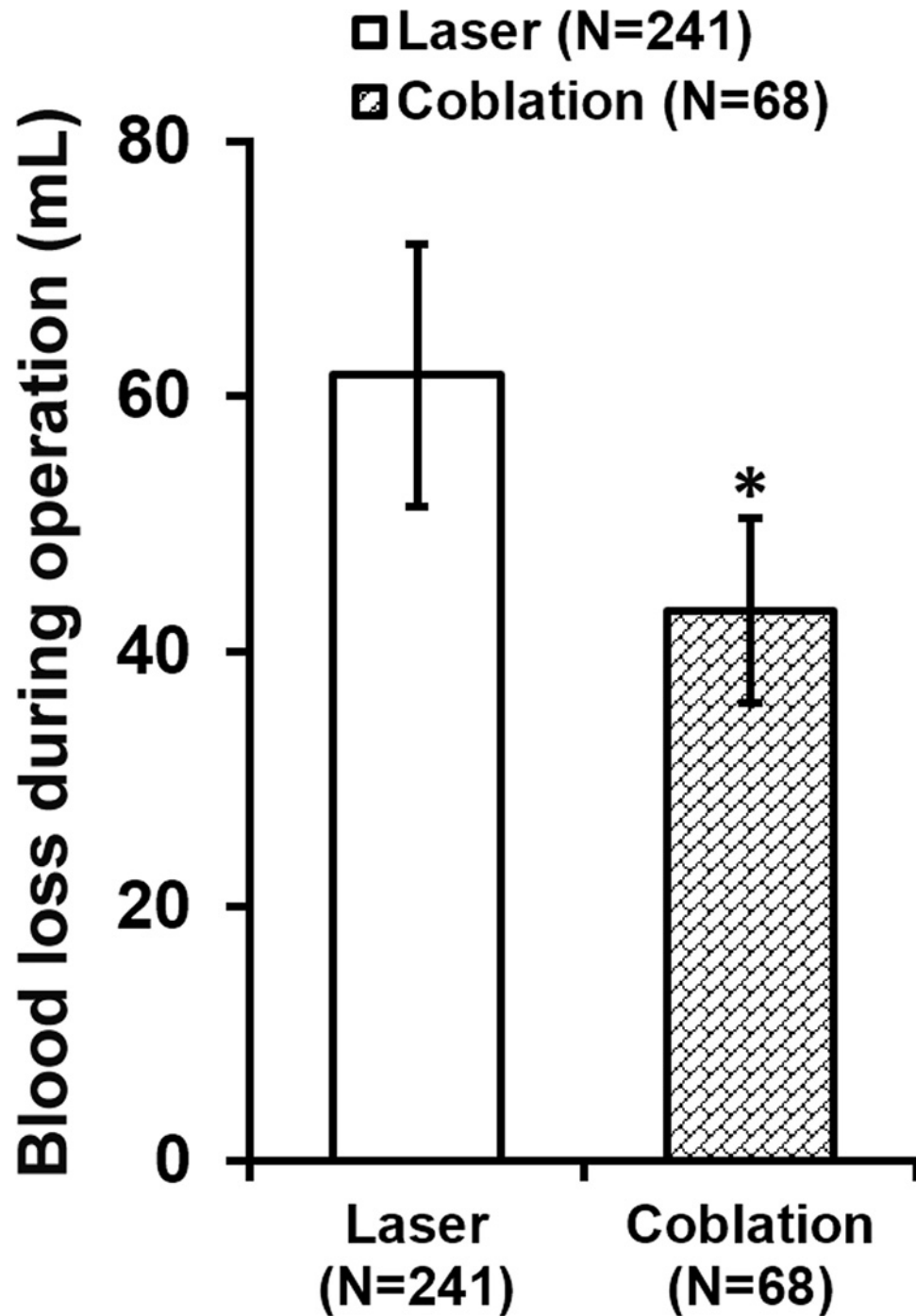
To date, CO<sub>2</sub> laser, microdebrider and radiofrequency coblation are the most commonly performed surgeries to treat recurrent respiratory papillomatosis. Laser power results in thermal vaporisation of water, causing disruption of cells, where DNA of HPV could be detected in the ing plume [9]. Such dispersion of HPV DNA has been speculated to give rise to distal seeding of lesions into the tracheobronchial tree in 13% of patients according to a previous study [3], causing potential surgical complications that are more demanding on both the anaesthetist and the otolaryngologist. These distal lesions often require a laser bronchoscope to treat, which produces a beam tangential to the lesions, potentially causing higher risk of collateral damage and further distal seeding. Laryngeal microdebrider, on the other hand, is able to rapidly control recurrent respiratory papillomatosis locally, but requires more surgical procedures [10] and causes more intra-operative bleeding [11] than CO<sub>2</sub> laser. Although bleeding caused by microdebrider can be kept under control using topical adrenaline in limited laryngeal diseases [12], it is nevertheless a major surgical complication in gross tracheal diseases, which further limits the amount of treatable diseases with a single procedure. However, both CO<sub>2</sub> laser and microdebrider approaches have clinical difficulties. CO<sub>2</sub> laser intervention requires a team of fully trained surgical personnel, during which a laser tube may also be needed that further limits surgical access. While surgery using microdebrider could be hindered by more frequent bleeding, which obstructs the view and may compromise lesion removal.

As compared, radiofrequency coblation offers significant advantage over the other two surgical approaches in treating recurrent respiratory papillomatosis, as suggested by previous studies and our current one. For instance, radiofrequency coblation has been successfully performed on patients with extensive laryngeal papillomata and a paediatric laryngeal papillomatosis patient, with minimal damage to underlying tissues and a bloodless field [13,14]. To bring



**Figure 2.** Time interval after CO<sub>2</sub> laser or radiofrequency coblation before the next intervention  
*n* indicates number of times each procedure was performed in all patients. Values are mean ± SD. \*\**P*<0.01.

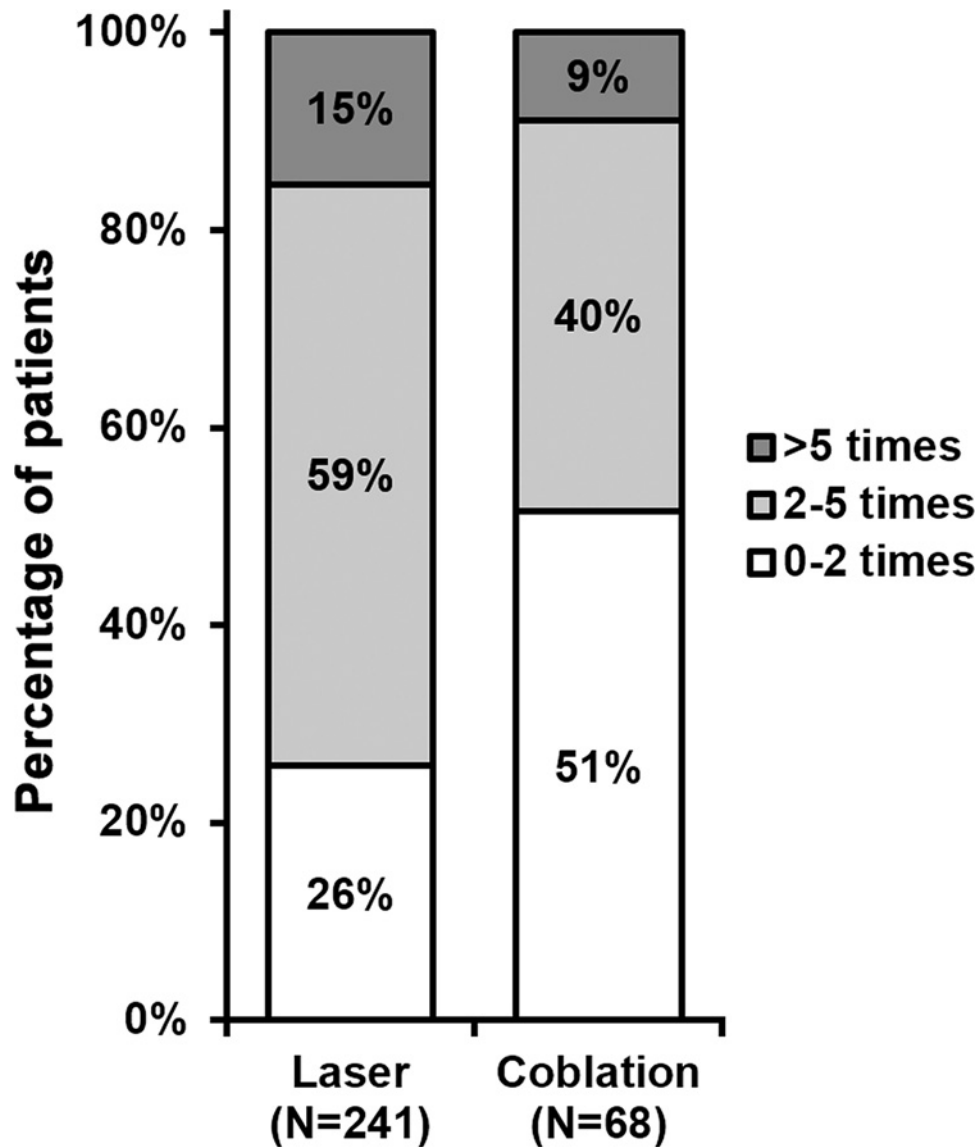
further evidences supporting the benefits of radiofrequency coblation to treat recurrent respiratory papillomatosis, our study has demonstrated that operation time, time interval between interventions, blood loss during operation and number of times bipolar electrocoagulation needed were all significantly reduced. Even post-operative complication and pain were found to be much improved after radiofrequency coblation as compared with CO<sub>2</sub> laser. Therefore, our data have further indicated that low-temperature radiofrequency coblation is a superior intervention compared with CO<sub>2</sub> laser against laryngotracheal recurrent respiratory papillomatosis.



**Figure 3. Blood loss during operation**

*n* indicates number of times each procedure was performed in all patients. Values are mean  $\pm$  SD. \**P* < 0.05.

The above observed advantages of radiofrequency collation make it an ideal clinical treatment against laryngo-tracheal recurrent respiratory papillomatosis. With this technique, physicians could efficiently and precisely remove papilloma with minimal damage to surrounding tissues hence minimising bleeding, as suggested in our study in terms of reduced blood loss during operation and number of times bipolar electrocoagulation is needed. However, of note, the swab weighing technique to measure blood loss has its own disadvantage affecting either accuracy of measurement or operation time. Because swabs are pre-moisturised with saline, and need to be measured before being used to absorb the blood, which might potentially prolong overall length of the procedure. Alternatively, measuring wet



**Figure 4.** Number of times bipolar electrocoagulation used in each procedure

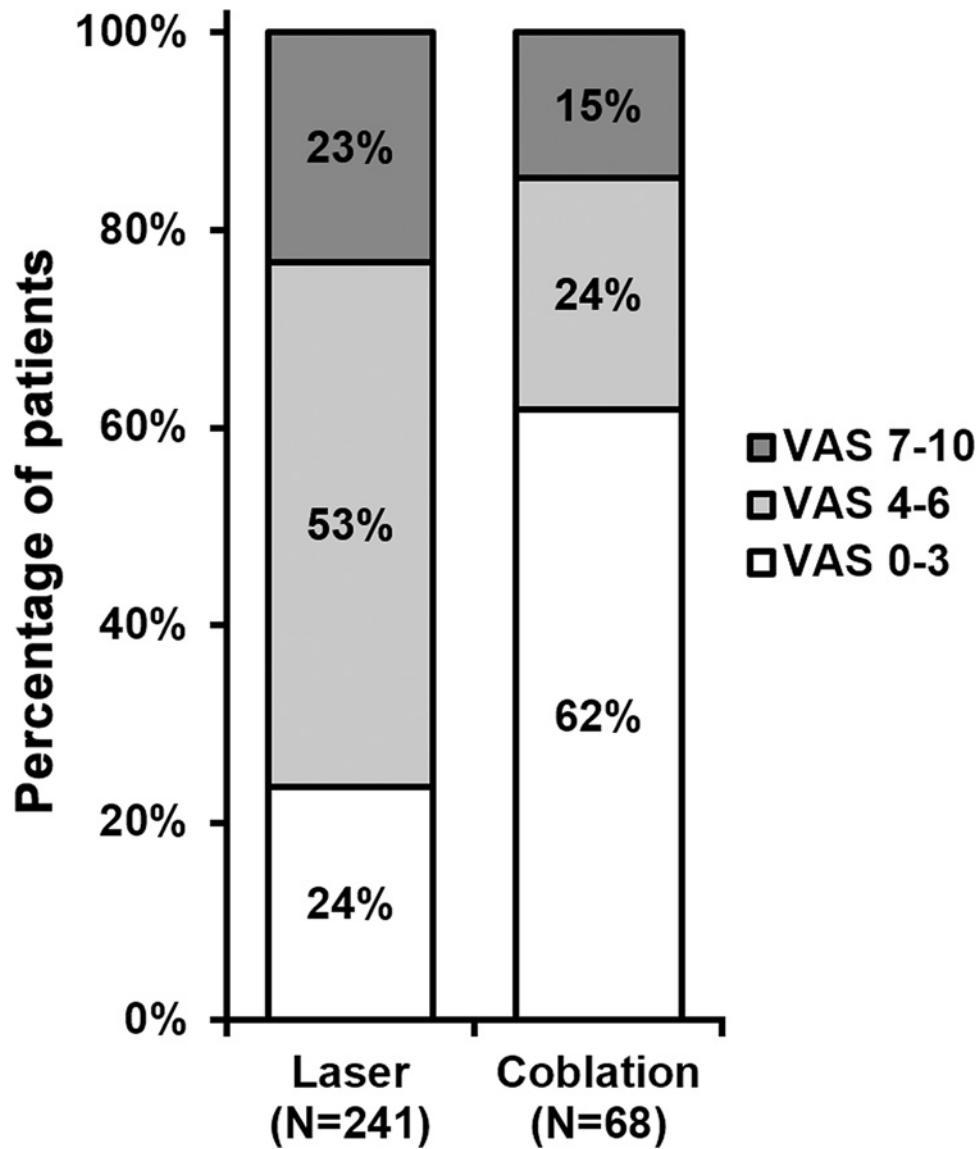
*n* indicates number of times each procedure was performed in all patients. Percentages do not sum up to 100% due to rounding.

swabs before procedure could avoid unnecessary time, but evaporation of the liquid on the swabs would make the measurement of blood loss relatively less accurate. Other methods, both accurate and quick to perform, to quantitate blood loss during procedure are needed to gain more reliable and reproducible results in evaluating not only blood loss *per se*, but also operation time.

Although earlier retrospective study has compared radiofrequency coblation with that of CO<sub>2</sub> laser vaporisation for treatment of advanced laryngotracheal recurrent respiratory papillomatosis [7], our current study still holds novelty in the following aspects: (1) larger sample size (41 vs. 6); (2) more comprehensive outcome evaluations (procedure time, time interval between interventions, blood loss during operation, post-operative complications and pain scores vs. interval between treatments only).

## Conclusion

In conclusion, data from our current retrospective study provide strong evidences supporting the efficacy of low-temperature radiofrequency coblation in treating laryngotracheal recurrent respiratory papillomatosis. Our



**Figure 5. Post-operative pain scores**

*n* indicates number of times each procedure was performed in all patients. Percentages do not sum up to 100% due to rounding.

study highlights that, for treatment against laryngotracheal recurrent respiratory papillomatosis, low-temperature radiofrequency coblation is a potentially superior intervention compared with CO<sub>2</sub> laser.

### Competing Interests

The authors declare that there are no competing interests associated with the manuscript.

### Funding

The authors declare that there are no sources of funding to be acknowledged.

### Author Contribution

Fang Hao, Liyan Yue, Xiaoyan Yin and Xiaotong Wang performed the experiments, analysed and interpreted the data. Chunguang Shan wrote the manuscript. All authors read and approved the final submission.



## Ethics Approval

Approval from the Ethics Committee of the Second Affiliated Hospital of Hebei Medical University was acquired to review the case records of the patients studied (between January 2012 and January 2018), all patients were provided signed written consent forms.

## Abbreviations

coblation, controlled ablation; HPV, human papilloma virus; VAS, visual analogue scale.

## References

- 1 Derkay, C.S. and Darrow, D.H. (2006) Recurrent respiratory papillomatosis. *Ann. Otol. Rhinol. Laryngol.* **115**, 1–11, <https://doi.org/10.1177/000348940611500101>
- 2 Bishai, D., Kashima, H. and Shah, K. (2000) The cost of juvenile-onset recurrent respiratory papillomatosis. *Arch. Otolaryngol. Head Neck Surg.* **126**, 935–939, <https://doi.org/10.1001/archotol.126.8.935>
- 3 Schraff, S., Derkay, C.S., Burke, B. and Lawson, L. (2004) American Society of Pediatric Otolaryngology members' experience with recurrent respiratory papillomatosis and the use of adjuvant therapy. *Arch. Otolaryngol. Head Neck Surg.* **130**, 1039–1042, <https://doi.org/10.1001/archotol.130.9.1039>
- 4 Bortnick, D.P. and Plastic Surgery Educational Foundation Data Committee (2001) Coblation: an emerging technology and new technique for soft-tissue surgery. *Plast. Reconstr. Surg.* **107**, 614–615, <https://doi.org/10.1097/00006534-200102000-00053>
- 5 Arya, A.K., Donne, A. and Nigam, A. (2005) Double-blind randomized controlled study of coblation tonsillectomy versus coblation tonsillectomy on postoperative pain in children. *Clin. Otolaryngol.* **30**, 226–229, <https://doi.org/10.1111/j.1365-2273.2005.00970.x>
- 6 Atef, A., Mosleh, M., El Bosraty, H., Abd El Fatah, G. and Fathi, A. (2006) Bipolar radiofrequency volumetric tissue reduction of inferior turbinate: does the number of treatment sessions influence the final outcome? *Am. J. Rhinol.* **20**, 25–31, <https://doi.org/10.1177/194589240602000105>
- 7 Carney, A.S., Evans, A.S., Mirza, S. and Psaltis, A. (2010) Radiofrequency coblation for treatment of advanced laryngotracheal recurrent respiratory papillomatosis. *J. Laryngol. Otol.* **124**, 510–514, <https://doi.org/10.1017/S0022215109992398>
- 8 Bonica, J.J. and Lyter, C.S. (1951) Measurement of blood loss during surgical operations. *Am. J. Surg.* **81**, 496–502, [https://doi.org/10.1016/0002-9610\(51\)90269-3](https://doi.org/10.1016/0002-9610(51)90269-3)
- 9 Kashima, H.K., Kessis, T., Mounts, P. and Shah, K. (1991) Polymerase chain reaction identification of human papillomavirus DNA in CO<sub>2</sub> laser plume from recurrent respiratory papillomatosis. *Otolaryngol. Head Neck Surg.* **104**, 191–195, <https://doi.org/10.1177/019459989110400206>
- 10 El-Bitar, M.A. and Zalzal, G.H. (2002) Powered instrumentation in the treatment of recurrent respiratory papillomatosis: an alternative to the carbon dioxide laser. *Arch. Otolaryngol. Head Neck Surg.* **128**, 425–428, <https://doi.org/10.1001/archotol.128.4.425>
- 11 Patel, R.S. and MacKenzie, K. (2000) Powered laryngeal shavers and laryngeal papillomatosis: a preliminary report. *Clin Otolaryngol Allied Sci.* **25**, 358–360, <https://doi.org/10.1046/j.1365-2273.2000.00389.x>
- 12 Pasquale, K., Wiatrak, B., Woolley, A. and Lewis, L. (2003) Microdebrider versus CO<sub>2</sub> laser removal of recurrent respiratory papillomas: a prospective analysis. *Laryngoscope* **113**, 139–143, <https://doi.org/10.1097/00005537-200301000-00026>
- 13 Timms, M.S., Bruce, I.A. and Patel, N.K. (2007) Radiofrequency ablation (coblation): a promising new technique for laryngeal papillomata. *J. Laryngol. Otol.* **121**, 28–30, <https://doi.org/10.1017/S0022215106003069>
- 14 Rachmanidou, A. and Modayil, P.C. (2011) Coblation resection of paediatric laryngeal papilloma. *J. Laryngol. Otol.* **125**, 873–876, <https://doi.org/10.1017/S0022215111001253>