

## ORIGINAL ARTICLE

# Further delineation of autosomal recessive intellectual disability syndrome caused by homozygous variant of the *NSUN2* gene in a chinese pedigree

Songyang Sun<sup>1</sup> | Lin Chen<sup>2</sup> | Yuchuan Wang<sup>2</sup> | Jian Wang<sup>3</sup> | Niu Li<sup>3</sup>  | Xike Wang<sup>2</sup><sup>1</sup>Guizhou University, Guiyang, China<sup>2</sup>Department of Pediatric, Guizhou Provincial People's Hospital, Guizhou University, Guiyang, China<sup>3</sup>Department of Medical Genetics and Molecular Diagnostic Laboratory, Shanghai Children's Medical Center, Shanghai Jiaotong University School of Medicine, Shanghai, China**Correspondence**Niu Li, Shanghai Children's Medical Center, Shanghai Jiaotong University School of Medicine, 1678 Dongfang Road, Shanghai 200127, P.R. China.  
Email: liniu0509@163.comXike Wang, Guizhou Provincial People's Hospital, Guizhou University, Guiyang 550002, Guizhou, P.R. China.  
Email: wangxike2008@sina.com**Funding information**

Project of Guizhou Science and Technology Department, Grant/Award Number: GZSYQCC(2016)004 and LH ( 2016 ) 7141

**Abstract**

**Background:** The enzyme NOP2/Sun RNA methyltransferase 2 (*NSUN2*) catalyzes the methylation of cytosine to 5-methylcytosine (m5C) at position 34 of tRNA(Leu; CAA) precursors containing introns that play a vital role in spindle assembly during mitosis and chromosome segregation. Biallelic variants in the *NSUN2* gene cause a rare intellectual disability that has been identified only in a few Middle Eastern patients. Affected individuals usually have other deformities, including developmental delay, short stature, microcephaly, and facial dysmorphism. The aim of this study was to identify the genetic cause of three female patients from a Chinese pedigree, who presented with similar phenotype consisting of the above clinical features.

**Methods:** Whole-exome sequencing (WES) was used to screen for causal variants in the genome, and the candidate variants were subsequently verified using Sanger sequencing.

**Results:** WES revealed a previously unreported homozygous nonsense variant (NM\_017755.5: c.1004T>A, p.Leu335\*) in exon 9 of *NSUN2*, which was consistent with the clinical phenotype of the patients and co-segregated with the disease in their family. A comparison of this phenotype with that of patients in published reports uncovered several novel clinical features related to *NSUN2* variations, including feeding difficulties, slender hands and fingers, severely restricted finger mobility, hallux valgus, varus foot, and elevated  $\alpha$ -hydroxybutyrate dehydrogenase (HBDH).

**Conclusions:** These are the first findings of a non-consanguineous Chinese pedigree with a homozygous *NSUN2* variant. We expanded the phenotypic spectrum associated with *NSUN2* variations.

**KEYWORDS**developmental delay, homozygous variant, intellectual disability, novel phenotype, *NSUN2* gene

This is an open access article under the terms of the Creative Commons Attribution-NonCommercial License, which permits use, distribution and reproduction in any medium, provided the original work is properly cited and is not used for commercial purposes.

© 2020 The Authors. *Molecular Genetics & Genomic Medicine* published by Wiley Periodicals LLC.

## 1 | INTRODUCTION

The NOP2/Sun RNA methyltransferase 2 (*NSUN2*, OMIM#610916) gene located at 5p15.31 encodes a methyltransferase comprising 767 amino acids (NP\_060225; UCSC database, <http://genome.ucsc.edu>). The *NSUN2* methyltransferase catalyzes the methylation of cytosine to 5-methylcytosine (m5C) at position 34 of tRNA(Leu; CAA) precursors containing introns, the modification of which is required to stabilize anticodon-codon pairing and correctly translate the mRNA (Brzezicha et al., 2016; Shinoda et al., 2019). Notably, *NSUN2* is involved in the regulation of cell proliferation and division through stabilizing the mitotic spindle, which is independent of its methyltransferase activity (Hussainet al., 2009). Analyses of RNA sequences from 95 humans revealed that *NSUN2* is expressed in many organs (Fagerberg et al., 2014). In addition to its enzymatic and cellular biological functions, these results implied that functionally impaired *NSUN2* would lead to a severe disease phenotype.

Indeed, biallelic variants in the *NSUN2* gene have caused syndromic congenital deformities in a few patients, who mainly had intellectual disability (ID; Abbasi-Moheb et al., 2012; Khan et al., 2012a; Khan et al., 2012b; Komara et al., 2015; Martinez et al., 2012; Yavarna et al., 2015). Other common clinical features include developmental delay (DD), short stature, microcephaly, and facial dysmorphism. However, due to the lack of defined clinical phenotypes, especially facial deformities, affected patients have sometimes been diagnosed with other conditions, such as Dubowitz and Noonan syndromes (Fahiminiya et al., 2014; Martinez et al., 2012). Moreover, some phenotypes are unique to individual patients. For example, Khan et al., (2012a), Khan et al., (2012b) described one family with problems only with feet and toes, and Komara et al. described one patient with severe osteoporosis and mild cerebellar atrophy (Komara et al., 2015). These rare clinical features might have resulted from biological effects of the races of the patients or the variants themselves, but they might also be due to incomplete phenotypic assessments of patients identified in specific cohorts (Fahiminiya et al., 2014; Mu et al., 2019; Shaheen et al., 2019). Therefore, better understanding of the phenotypes associated with *NSUN2* defects requires careful assessment of more patients.

Here, we identified a homozygous nonsense variant in *NUSN2* using whole exome sequencing (WES) in a Chinese family with three affected female members. The clinical phenotypes of the patients were consistent with each other, and mostly with reported phenotypes. We also uncovered several novel clinical features related to *NSUN2* variations which deepened our understanding of the phenotype.

## 2 | MATERIALS AND METHODS

### 2.1 | Whole-exome sequencing

We conducted whole-exome sequencing (WES) as described (Wang et al., 2014). Briefly, genomic DNA was extracted from 2 ml of peripheral blood samples of the three patients and their parents using TIANamp Genomic DNA Kits (TIANGEN, Beijing, China). We sheared 3 µg of DNA from patient II-3 into lengths of 150–200 bp using a Covaris® M220 Ultrasonicator (Covaris Inc.). An adapter-ligated library was generated using an Agilent SureSelect Target Enrichment System (Agilent Technologies, Inc.), and a capture library including both coding exons and flanking intronic regions was produced using SureSelect XT Human All Exon V6 reagent kits (Agilent Technologies Inc.). Clusters were then generated by isothermal bridge amplification using an Illumina cBot station, and sequenced using an Illumina X10 System (Illumina Inc.).

The sequence reads were aligned to a reference human genome (GRCh37/hg19) using NextGENe® software (SoftGenetics LLC). All single nucleotide variants (SNV) and indels were uploaded in VCF format for Ingenuity® Variant Analysis™ (Ingenuity Systems), bioinformatics analysis and interpretation.

### 2.2 | Sanger sequencing verification of the *NSUN2* gene

We designed primers to amplify the *NSUN2* gene (GenBank accession no. NM\_017755.5) using Primer 3 software (<http://primer3.ut.ee/>). The primers designed for exon 9 were: forward, 5'-CAGAGAAAACCCAGCTCAC-3' and reverse, 5'-CAACCCACAGTGCAGACG-3'. Exons and exon-intron boundaries were amplified by polymerase chain reaction (PCR; Takara Bio Inc.). The PCR products were sequenced using an ABI3730XL sequencer (Applied Biosystems) with both forward and backward primers, then the data were analyzed using Mutation Surveyor DNA Variant Analysis Software (SoftGenetics LLC.).

### 2.3 | Analysis of the *NSUN2*- p.Leu335\* variant *in silico*

The three-dimensional (3D) structure of the wild-type (WT) *NSUN2* protein was simulated using Pymol v.1.8.4.0 software (<https://www.pymol.org>; Schrödinger), according to its amino acid sequence (NP\_060225.4).

### 3 | RESULTS

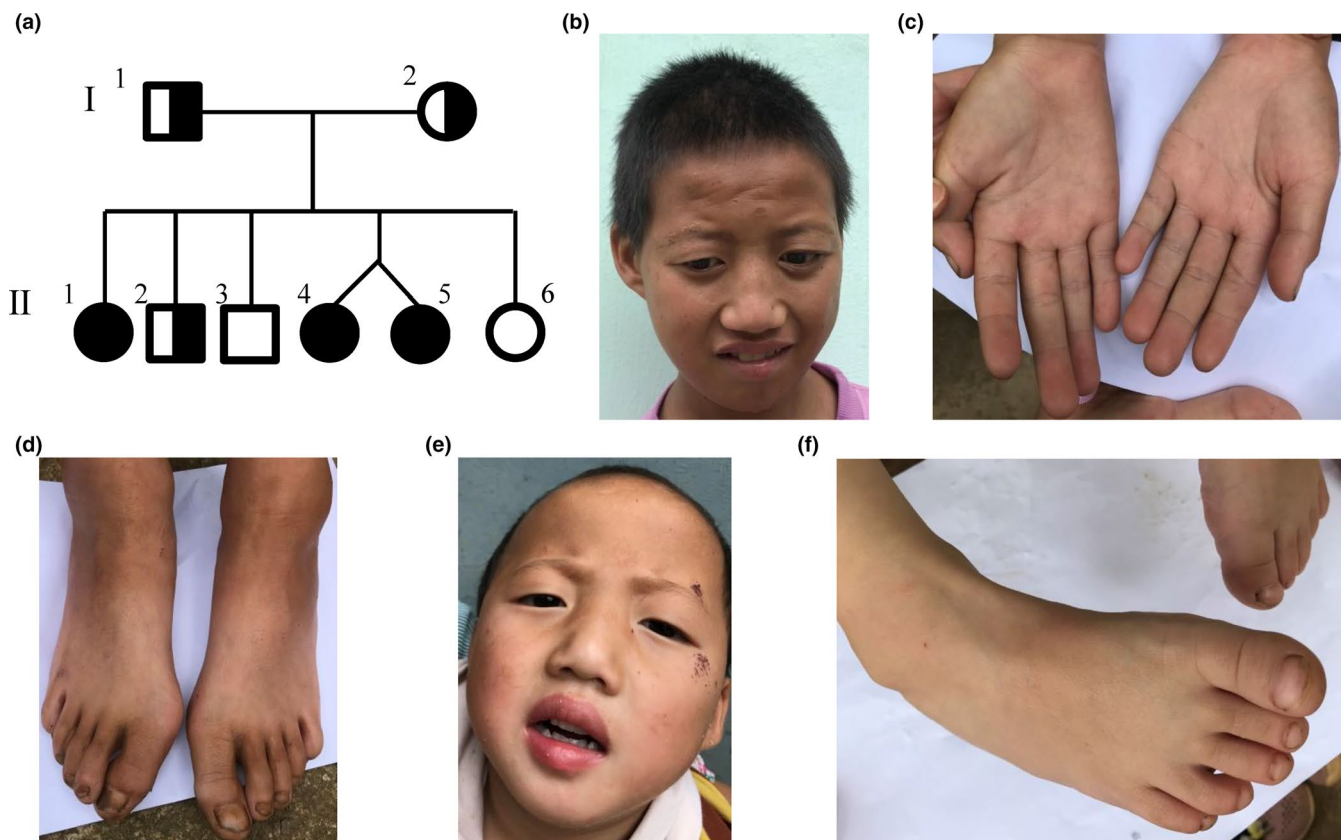
#### 3.1 | Patient description

Patient 1 (II-1) was a 20-year-old female, and the first child born to a physically healthy and non-consanguineous Chinese couple (Figure 1a). One early sign of a problem was post-partum feeding difficulties. A physical examination showed she had severe short stature (147.5 cm,  $\ll -3SD$ ), low body weight (30.6 kg), muscular hypertonia, and craniofacial deformities, including microcephaly (head circumference, 49 cm,  $\ll -3SD$ ), long face, short philtrum, hypertelorism, ptosis, long palpebral fissures, high nasal bridge, prominent nose, and micrognathia (Figure 1b, Table 1). She had slender hands and fingers, light palmar creases, and hallux valgus (Figure 1c,d). She had undeveloped breasts, no pubic hair, and amenorrhea. She crawled at the age of 4.5 years and could walk with help at age of 10 years. Her gait remains unsteady. Only two fingers of each hand could move; thus, she could not hold a pen or chopsticks. She had severe ID and no language development. She also had fecal and urine incontinence. Laboratory findings

revealed elevated creatine kinase isoenzyme-MB (CK-MB; 44 U/L, normal range: 0–25 U/L).

Patients 2 (II-4) and 3 (II-5) are 4-year-old twin sisters (Figure 1a) with clinical features that were mostly similar to those of their older sister (patient 1), including short stature, low body weight, hypertonia, craniofacial deformities, ID, language developmental delay, and the developmental retardation of gross and fine motor skills (Figure 1e, Table 1). At the age of 35 months, their gross and fine motor skills were equivalent to those of 11- and 8–9-month-old infants, respectively. Their intellectual development was probably like that of a normal 9-month-old infant. Patient 2 had normal hands and feet, whereas patient 3 had varus right foot (Figure 1f). Moreover, patients 2 and 3 had elevated CK-MB (60 and 48 U/L, respectively), and  $\alpha$ -hydroxybutyrate dehydrogenase (HBDH; 244 and 229 U/L, respectively; normal range: 53–168 U/L; Table 1). The family also has two boys and one girl who are asymptomatic.

The findings of cranial magnetic resonance imaging, electrocardiography (ECG), ultrasound of the abdomen, thyroid, and heart, and chromosome karyotyping were normal among the three patients.



**FIGURE 1** Phenotypes of the patients. (a) Family pedigree shows three affected and three unaffected offspring from non-consanguineous parents. (b) Facial appearance of patient 1 (II-1). (c-d) Malformations of hands and feet of patient 1 (II-1). (e) Facial appearance of patient 3 (II-5). (f) Varus right foot in patient 3 (II-5).

TABLE 1 Summary of the clinical features of the patients.

Features	Patients in this study		
	II-1	II-4	II-5
Sex	F	F	F
Age	20-year	4-year	4-year
Height (cm) at present	147.5 (<<<-3SD)	88 (-4.07 SD)	89 (-3.83 SD)
Weight (kg) at present	30.6	11.6 (-2.30 SD)	10.4 (-2.83 SD)
Birth height (cm)	Unknown	Unknown	Unknown
Birth weight (kg)	Unknown	2.2 (-2.77 SD)	2.3 (-2.50 SD)
Feeding difficulties	+	+	+
Craniofacial deformities			
OFC (cm)	49 (<<<-3 SD)	44 (-4.25 SD)	44 cm (-3.42 SD)
Long face	+	+	+
Prominent nose	+	+	+
High nasal bridge	+	+	+
Short philtrum	+	+	+
Hypertelorism	+	+	+
Ptosis	+	+	+
Long palpebral fissures	+	+	+
Micrognathia	+	+	+
Neurological deformities			
Hypertonia	+	+	+
Intellectual disability	+	+	+
Language skills	Cannot speak	Cannot speak	Cannot speak
Sexual development			
	Undeveloped breast, no pubic hair, amenorrhea	Not applicable	Not applicable
Skeletal deformities			
Hands and fingers	Slender hands and fingers	-	-
Feet and/or toes	Hallux valgus	-	Varus right foot
Motor skills			
Crawling	Age of 4.5-year	Age of 3-year	Age of 3-year
Walking	Age of 10-year, can walk with help, but unstable	Can walk with help, but unstable	Can walk with help, but unstable
Fine motor skills	Delay (cannot pinch pen and chopsticks), only two fingers can move	Delay	Delay
Others			
	Fecal and urine incontinence		
Laboratory examination			
CK-MB (Normal range: 0-25 U/L)	44	60	48
HBDH (Normal range: 53-168 U/L)	157	244	229

F, female; HBDH,  $\alpha$ -hydroxybutyrate dehydrogenase; M, male; OFC, occipitofrontal circumference.

### 3.2 | Identification of the novel *NSUN2* variant

We suspected a genetic intellectual disability syndrome, and therefore conducted WES. The following strategy was applied to filter variants. We excluded low-confidence

variants, common variants with allele frequencies (AF) >1% in the gnomAD database (<http://gnomad.broadinstitute.org/>), benign variants, including synonymous, harmless missense variants predicted by PolyPhen-2 and MutationTaster, and those with no impact on splicing predicted by MaxEntScan software. Thereafter, clinical



symptoms of global DD and ID served as filtering indexes to analyze candidate variants.

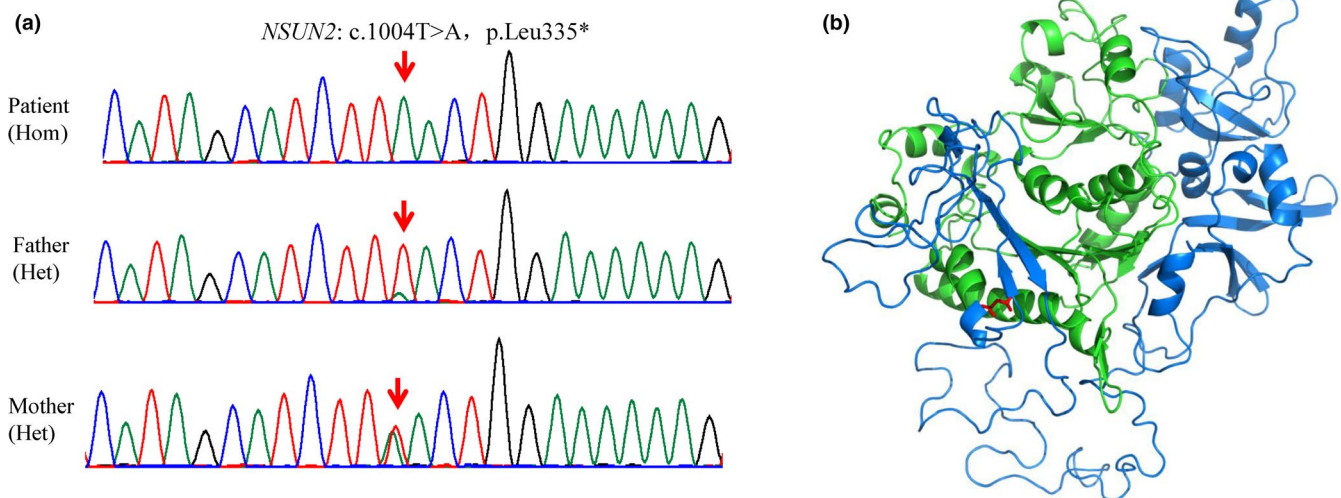
Finally, we identified a homozygous nonsense variant (c.1004T>A, p.Leu335\*) in the *NSUN2* gene (NM\_017755.5) in all three patients, and validated it using Sanger sequencing (Figure 2a). The variant located at exon 9 of *NSUN2* had an extremely low (0.0012%) allelic frequency (AF; gnomAD database) and resulted in *NSUN2* protein missing more than half of its amino acid residues (Figure 2b). This was likely to trigger nonsense-mediated mRNA degradation. Sanger sequencing revealed that the parents and the second child of the family (II-2) were heterozygous for the nonsense variant, while two of the healthy children (II-3 and II-6) had the wild-type allele. In addition, copy number variation (CNV) analysis was performed by comparing the read-depth with the WES data from the other 20 samples of the same batch as described (Yao et al., 2017, 2019), and no questionable CNVs were found.

## 4 | DISCUSSION

We uncovered a Chinese pedigree that included three females harboring a rare homozygous variant (c.1004T>A, p.Leu335\*) in exon 9 of the *NSUN2* gene that has so far remained unknown. The variant was co-segregated in the patients and in unaffected members of the family and was classified as pathogenic according to the ACMG guidelines (PVS1+PM2+PP4; Richards et al., 2015). All three patients had ID, DD, microcephaly, short stature, facial deformities (long face, prominent nose, high nasal bridge, short philtrum, hypertelorism, ptosis, long palpebral fissures, and micrognathia), hypertonia, feeding difficulties, and elevated CK-MB. Among these features, feeding difficulties were the first

feature to be recognized in the patients. We also identified several novel skeletal deformities, including slender hands and fingers, severely restricted finger mobility, and hallux valgus in patient 1 (II-1) and varus foot in patient 3 (II-5). Moreover, patient II-1 had delayed puberty, which has been identified in two other patients (one female and one male; Khan et al., 2012a; Khan et al., 2012b; Komara et al., 2015), indicating that *NSUN2* plays a vital role in sexual development. Due to the elevated CK-MB and/or HBDH levels in our patients, and in consideration of a description of one patient with elevated creatine phosphokinase and lactose dehydrogenase (Khan et al., 2012a; Khan et al., 2012b), we evaluated the cardiac function of our patients using ECG and cardiac ultrasonography. Although no abnormalities were evident, we recommended that the patients undergo regular specialist evaluation.

To date, eight homozygous *NSUN2* variants have been identified in 18 progeny of eight pairs of consanguineous parents: five with c.538-11T>G (p.Ile179Argfs\*192; Abbasi-Moheb et al., 2012), three with c.2035G>A (p.Gly679Arg; Khan et al., 2012a; Khan et al., 2012b), three with c.679C>T (p.Gln227\*; Abbasi-Moheb et al., 2012), two with c.1114C>T (p.Gln372\*; Abbasi-Moheb et al., 2012), and one with c.1020delA (p.Gly341Valfs\*15) described in three studies (Fahiminiya et al., 2014; Komara et al., 2015; Mu et al., 2019), and one each with c.538-1G>C (Martinez et al., 2012), c.1095+1G>A (Yavarna et al., 2015), and c.1478delA (p.Asn496Ilefs\*18; Shaheen et al., 2019). All these patients were born to Middle Eastern families with a consanguineous history. In addition to our three patients, we summarized the most frequent clinical features in all known patients with defective *NSUN2*. Table 2 shows that all affected patients had ID, DD, and facial deformities. The most common facial



**FIGURE 2** Results of sequencing DNA from the pedigree. (a) Sanger sequencing confirmed that patients inherited homozygous variant of c.1004T>A (p.Leu335\*) in exon 9, from both parents. Red arrows, variant base. (b) Homology model shows effects of nonsense variant on *NSUN2* protein. Green and blue, amino acid residues before and after Leu 335, respectively; red, Leu 335 residue.

TABLE 2 High frequent clinical features in patients with *NSUN2* variation.

	Patients in this study (n = 3)	Previously reported cases (n=17 <sup>a</sup> )	Total (n = 20)
Sex	3 females	10 Females, 6 males, and one unknown	13 Females, 6 males and one unknown
<b>Clinical features</b>			
Intellectual disability	3/3	17/17	20/20 (100%)
Developmental delay	3/3	17/17	20/20 (100%)
Facial deformities	3/3	17/17	20/20 (100%)
High nasal bridge	3/3	14/17	17/20 (85%)
Prominent nose	3/3	14/17	17/20 (85%)
Long face	3/3	13/17	16/20 (80%)
Short philtrum	3/3	12/17	15/20 (75%)
Microcephaly	3/3	13/17	16/20 (80%)
Short stature	3/3	11/17	14/20 (70%)
Hypotonia	0/3	9/15	9/18 (50%)
Hypertonia	3/3	4/15	7/18 (39%)
Strabismus	0/3	4/8	4/11 (36%)

<sup>a</sup>The patient reported by Shaheen *et al.* (ref 11) was excluded due to lack of detail clinical information.

features were a high nasal bridge (17/20), prominent nose (17/20), long face (16/20), and short philtrum (15/20). Most patients had microcephaly (16/20) and short stature (14/20). Hypotonia (9/18), hypertonia (7/18), and strabismus (4/11) were also evident. Compared with other manifestations, patients with *NSUN2* defects, including our three patients, tended to have significant ID, which might be due to cerebellar dysfunction (Christianson *et al.*, 1999; Ventura *et al.*, 2006). A study of expression profiles in the mouse brain has localized *NSUN2* mainly to the nucleoli of Purkinje cells in the cerebellum, as well as some cortical and brain-stem neurons (Khan *et al.*, 2012a; Khan *et al.*, 2012b).

One affected patient was considered to have Noonan-like syndrome at the age of 6 months based on DD and facial features (Fahiminiya *et al.*, 2014). Noonan syndrome (NS; OMIM#163950) is characterized by short stature, craniofacial dysmorphism, cardiac abnormalities, short and/or a webbed neck resulting from abnormal activation of RAS-MAPK signaling due to variations in several genes (e.g., *PTPN11*, *SOS1*, *RAF1*, *BRAF*, *HRAS*, *KRAS*, and *LZTR1*; Li *et al.*, 2019; Roberts *et al.*, 2013). Although patients with NS and with defective *NSUN2* are difficult to distinguish based on facial features, several other features can be compared. Congenital heart diseases (e.g., pulmonary valve stenosis, atrial septal defect, and hypertrophic cardiomyopathy) occur in 50%–80% of individuals with NS, but not so far in patients with *NSUN2* defects. The prevalence of microcephaly is rare in NS but 80% in *NSUN2* defects, and that of ID is ~25% of patients with NS compared with 100% of those with defective *NSUN2*.

Another similar autosomal recessive phenotype is Dubowitz syndrome (DS; OMIM#223370), which has been

identified in >200 patients; however, a single causative gene remains unknown. This syndrome is usually characterized by low birth weight, eczema, microcephaly, growth restriction, mild to moderate developmental delay, and a characteristic sloping forehead, epicanthal folds, blepharophimosis, widely spaced eyes, ptosis, a wide mouth, and micrognathia (Innes *et al.*, 2018; Tsukahara & Opitz, 1996). However, none of the patients with a known *NSUN2* defect had eczema, compared with ~48% of patients with DS). More significantly, ID is more severe in patients with a *NSUN2* defect than DS (~50% mild and ~25% moderate-to-severe compared with 100% moderate-to-severe in patients with *NSUN2* defects). Several other features of DS, namely a high-pitched voice, behavior problems such as hyperactivity (~40%), recurrent infections (~32%), tooth problems (~29%), congenital heart defects (~10%), and increased risk of hematological and malignant disorders have not been associated with *NSUN2* defects.

## 5 | CONCLUSION

We uncovered a novel *NSUN2* variant that caused severe ID, DD, and other congenital abnormalities in three Chinese patients from the same family. This is the first description of a non-consanguineous Chinese pedigree with *NSUN2* homozygous variants. These variants were associated with early feeding difficulties, slender hands and fingers, severely restricted finger mobility, hallux valgus, varus foot, and elevated HBDH, which further extends the phenotype spectrum of *NSUN2* variations.

## ACKNOWLEDGMENTS

We are deeply grateful to the patients and their family for participating in this study. The study was supported by the Project of Guizhou Science and Technology Department (Grant no. GZSYQCC(2016)004, LH(2016)7141).

## CONFLICT OF INTEREST

The authors declare no conflict of interest.

## AUTHOR CONTRIBUTIONS

Songyang Sun and Lin Chen gathered clinical information from the family, performed literature review, and drafted the manuscript. Jian Wang and Yuchuan Wang performed molecular genetic analysis. Songyang Sun and Niu Li generated figures and tables for the manuscript. Niu Li and Xike Wang designed the study. All authors revised the manuscript.

## ETHICAL COMPLIANCE

This study proceeded in accordance with the ethical standards of the responsible institutional committee on human experimentation and with the Declaration of Helsinki 1975, as revised in 2013. The Ethics Committee at Guizhou Provincial People's Hospital approved the protocol and the family of the patients provided written informed consent to participate in the study.

## DATA AVAILABILITY STATEMENT

The data that support the findings of this study are available on request from the corresponding authors.

## ORCID

Niu Li  <https://orcid.org/0000-0001-6504-7633>

## REFERENCES

- Abbasi-Moheb, L., Mertel, S., Gonsior, M., Nouri-Vahid, L., Kahrizi, K., Cirak, S., ... Kuss, A.W. (2012). Mutations in NSUN2 cause autosomal-recessive intellectual disability. *American journal of human genetics*, *90*(5), 847–855. <https://doi.org/10.1016/j.ajhg.2012.03.021>
- Brzezicha, B., Schmidt, M., Makalowska, I., Jarmolowski, A., Pienkowska, J., & Szwejkowska-Kulinska, Z. (2006). Identification of human tRNA:m5C methyltransferase catalysing intron-dependent m5C formation in the first position of the anticodon of the pre-tRNA Leu (CAA). *Nucleic Acids Research*, *34*(20), 6034–6043. <https://doi.org/10.1093/nar/gkl765>
- Christianson, A.L., Stevenson, R.E., van der Meyden, C.H., Pelsler, J., Theron, F.W., van Rensburg, P.L., ... Schwartz, C.E. (1999). X linked severe mental retardation, craniofacial dysmorphism, epilepsy, ophthalmoplegia, and cerebellar atrophy in a large South African kindred is localised to Xq24-q27. *Journal of Medical Genetics*, *36*(10), 759–766. <https://doi.org/10.1136/jmg.36.10.759>
- Fagerberg, L., Hallström, B.M., Oksvold, P., Kampf, C., Djureinovic, D., Odeberg, J., ... Uhlén, M. (2014). Analysis of the human tissue-specific expression by genome-wide integration of transcriptomics and antibody-based proteomics. *Molecular & Cellular Proteomics*, *13*(2), 397–406. <https://doi.org/10.1074/mcp.M113.035600>
- Fahiminiya, S., Almuriekh, M., Nawaz, Z., Staffa, A., Lepage, P., Ali, R., ... Ben-Omran, T. (2014). Whole exome sequencing unravels disease-causing genes in consanguineous families in Qatar. *Clinical Genetics*, *86*(2), 134–141. <https://doi.org/10.1111/cge.12280>
- Hussain, S., Benavente, S.B., Nascimento, E., Dragoni, I., Kurowski, A., Gillich, A., Humphreys, P., & Frye, M. (2009). The nucleolar RNA methyltransferase Misu (NSUN2) is required for mitotic spindle stability. *The Journal of Cell Biology*, *186*(1), 27–40. <https://doi.org/10.1083/jcb.200810180>
- Innes, A.M., McInnes, B.L., & Dymont, D.A. (2018). Clinical and genetic heterogeneity in Dubowitz syndrome: Implications for diagnosis, management and further research. *American journal of medical genetics. Part C, Seminars in Medical Genetics*, *178*(4), 387–397. <https://doi.org/10.1002/ajmg.c.31661>
- Khan, M.A., Rafiq, M.A., Noor, A., Hussain, S., Flores, J.V., Rupp, V., ... Vincent, J.B. (2012a). Mutation in NSUN2, which encodes an RNA methyltransferase, causes autosomal-recessive intellectual disability. *American Journal of Human Genetics*, *90*(5), 856–863. <https://doi.org/10.1016/j.ajhg.2012.03.023>
- Khan, M.A., Rafiq, M.A., Noor, A., Hussain, S., Flores, J.V., Rupp, V., ... Vincent, J.B. (2012b). Mutation in NSUN2, which encodes an RNA methyltransferase, causes autosomal recessive intellectual disability. *American Journal of Human Genetics*, *90*(5), 856–863. <https://doi.org/10.1016/j.ajhg.2012.03.023>
- Komara, M., Al-Shamsi, A.M., Ben-Salem, S., Ali, B.R., & Al-Gazali, L. (2015). A novel single-nucleotide deletion (c.1020delA) in NSUN2 causes intellectual disability in an emirati child. *Journal of Molecular Neuroscience*, *57*(3), 393–399. <https://doi.org/10.1007/s12031-015-0592-8>
- Li, X., Yao, R., Tan, X., Li, N., Ding, Y., Li, J., ... Wang, X. (2019). Molecular and phenotypic spectrum of Noonan syndrome in Chinese patients. *Clinical Genetics*, *96*(4), 290–299. <https://doi.org/10.1111/cge.13588>
- Martinez, F.J., Lee, J.H., Lee, J.E., Blanco, S., Nickerson, E., Gabriel, S., ... Gleeson, J.G. (2012). Whole exome sequencing identifies a splicing mutation in NSUN2 as a cause of a Dubowitz-like syndrome. *Journal of Medical Genetics*, *49*(6), 380–385. <https://doi.org/10.1136/jmedgenet-2011-100686>
- Mu, W., Schiess, N., Orthmann-Murphy, J.L., & El-Hattab, A.W. (2019). The utility of whole exome sequencing in diagnosing neurological disorders in adults from a highly consanguineous population. *Journal of Neurogenetics*, *33*(1), 21–26. <https://doi.org/10.1080/01677063.2018.1555249>
- Richards, S., Aziz, N., Bale, S., Bick, D., Das, S., Gastier-Foster, J., ... Laboratory Quality Assurance Committee, A.C.M.G. (2015). Standards and guidelines for the interpretation of sequence variants: a joint consensus recommendation of the American College of Medical Genetics and Genomics and the Association for Molecular Pathology. *Genetics in Medicine*, *17*(5), 405–424. <https://doi.org/10.1038/gim.2015.30>
- Roberts, A.E., Allanson, J.E., Tartaglia, M., & Gelb, B.D. (2013). Noonan syndrome. *The Lancet*, *381*(9863), 333–342. [https://doi.org/10.1016/S0140-6736\(12\)61023-X](https://doi.org/10.1016/S0140-6736(12)61023-X)
- Shaheen, R., Maddirevula, S., Ewida, N., Alsahli, S., Abdel-Salam, G.M.H., Zaki, M.S., ... Alkuraya, F.S. (2019). Genomic and phenotypic delineation of congenital microcephaly. *Genetics in Medicine*, *21*(3), 545–552. <https://doi.org/10.1038/s41436-018-0140-3>

- Shinoda, S., Kitagawa, S., Nakagawa, S., Wei, F.Y., Tomizawa, K., Araki, K., Araki, M., ... Suzuki, T. (2019). Mammalian NSUN2 introduces 5-methylcytidines into mitochondrial tRNAs. *Nucleic Acids Research*, *47*(16), 8734–8745. <https://doi.org/10.1093/nar/gkz575>
- Tsukahara, M., & Opitz, J.M. (1996). Dubowitz syndrome: review of 141 cases including 36 previously unreported patients. *American Journal of Medical Genetics*, *63*(1), 277–289.
- Ventura, P., Presicci, A., Perniola, T., Campa, M.G., & Margari, L. (2006). Mental retardation and epilepsy in patients with isolated cerebellar hypoplasia. *Journal of Child Neurology*, *21*(9), 776–781. <https://doi.org/10.1177/08830738060210091301>
- Wang, J., Zhang, W., Jiang, H., Wu, B.L., & Collaboration, P.O.I. (2014). Mutations in HFM1 in recessive primary ovarian insufficiency. *The New England Journal of Medicine*, *370*(10), 972–974. <https://doi.org/10.1056/NEJMc1310150>
- Yao, R., Yu, T., Qing, Y., Wang, J., & Shen, Y. (2019). Evaluation of copy number variant detection from panel-based next-generation sequencing data. *Molecular Genetics & Genomic Medicine*, *7*(1), e00513. <https://doi.org/10.1002/mgg3.513>
- Yao, R., Zhang, C., Yu, T., Li, N., Hu, X., Wang, X., ... Shen, Y. (2017). Evaluation of three read-depth based CNV detection tools using whole-exome sequencing data. *Molecular Cytogenetics*, *10*, 30. <https://doi.org/10.1186/s13039-017-0333-5>
- Yavarna, T., Al-Dewik, N., Al-Mureikhi, M., Ali, R., Al-Mesaifri, F., Mahmoud, L., ... Ben-Omran, T. (2015). High diagnostic yield of clinical exome sequencing in Middle Eastern patients with Mendelian disorders. *Human Genetics*, *134*(9), 967–980. <https://doi.org/10.1007/s00439-015-1575-0>

**How to cite this article:** Sun S, Chen L, Wang Y, Wang J, Li N, Wang X. Further delineation of autosomal recessive intellectual disability syndrome caused by homozygous variant of the *NSUN2* gene in a chinese pedigree. *Mol Genet Genomic Med*. 2020;8:e1518. <https://doi.org/10.1002/mgg3.1518>