

# Comparative study of urethroplasties to reduce urethral strictures in patients with severe hypospadias

Journal of International Medical Research

2019, Vol. 47(4) 1620–1627

© The Author(s) 2019

Article reuse guidelines:

sagepub.com/journals-permissions

DOI: 10.1177/0300060519826449

journals.sagepub.com/home/imr



Li-Qu Huang<sup>1, #</sup> , Jun Wang<sup>1, #</sup>, Zheng Ge<sup>1</sup>,  
Geng Ma<sup>1</sup>, Ru-Gang Lu<sup>1</sup>, Yong-Ji Deng<sup>1</sup>,  
Song-Ming Huang<sup>2, \*</sup> and Yun-Fei Guo<sup>1, \*</sup>

## Abstract

**Objective:** Transverse island pedicle flap (TIPF) plus transected urethral plate-preserving urethroplasty is increasingly used for treatment of severe hypospadias. We aimed to reduce the occurrence of urethral strictures in patients undergoing such procedures.

**Methods:** Sixty-five patients with severe hypospadias were enrolled. Thirty-two patients underwent onlay-tube-onlay urethroplasty (Group A), and 33 patients underwent modified Duplay urethroplasty (Group B). Postoperative complications were recorded, including fistulas, urethral strictures, and diverticula.

**Results:** Three patients (9.4%) in Group A and 10 patients (30.3%) in group B had urethrocutaneous fistulas. Three patients (9.4%) in Group A and 0 patients (0%) in Group B had urethral strictures. No patient in the two groups had symptoms of diverticulum or penile chordee. The results of uroflowmetry were better in Group B than Group A, when comparing uroflow patterns.

**Conclusions:** TIPF plus transected urethral plate-preserving urethroplasty can lower the occurrence of stricture, which is a challenging complication. The occurrence of stricture was lower in patients who underwent modified Duplay urethroplasty, and neourethral function and quality were better in these patient. Thus, this modified procedure can be used for treatment of severe hypospadias.

## Keywords

Severe hypospadias, transected urethral plate, urethroplasty, flap, fistula, urethral stricture, diverticulum, uroflowmetry

Date received: 3 October 2018; accepted: 4 January 2019

<sup>1</sup>Department of Urology, Children's Hospital of Nanjing Medical University, Nanjing, China

<sup>2</sup>Department of Nephrology, Children's Hospital of Nanjing Medical University, Nanjing, China

#These authors contributed equally to this work.

\*These authors contributed equally to this work.

### Corresponding author:

Song-Ming Huang, M.D. Children's Hospital of Nanjing Medical University, 72 Guangzhou Road, Nanjing 210008, China.

Email: smhuang@njmu.edu.cn



## Introduction

The precise etiology of hypospadias is not yet known. However, recent studies indicate that the occurrence of proximal hypospadias is increasing.<sup>1-3</sup> For patients with such defects, transection of the urethral plate (UP) is needed for penile straightening, and the use of tubularized flaps (Duckett technique) is common.<sup>4</sup> Importantly, anastomotic strictures can occur, even during treatment by skilled pediatric urologists; these are difficult to repair.<sup>5-7</sup> To preserve the UP, no cycling suture is made at anastomosis, which lowers the rate of stricture complications. Thus, transverse island pedicle flap (TIPF) plus transected UP-preserving urethroplasty is increasingly used for patients with severe chordee.<sup>8</sup>

For onlay-tube-onlay urethroplasty, the two ends of TIPF are sutured over the transected UP and the middle portion of the flap is tubularized. For modified Duplay urethroplasty, a new UP is constructed, with a transected native urethral plate inserted into ends of the TIPF (V-shaped); the newly reconstructed neourethral plate is tubularized. Our experience with these two single-stage techniques has shown fewer complications.<sup>8</sup> The purpose of this study was to compare these two procedures with regard to reducing the rates of urethral strictures.

## Methods

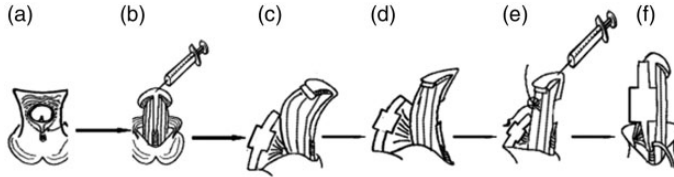
A retrospective analysis was performed of consecutive patients with proximal hypospadias who were treated from May 2012 to September 2015 at Nanjing Children's Hospital. All patients were diagnosed with proximal hypospadias with severe chordee. Patients that underwent onlay-tube-onlay urethroplasty comprised Group A, and patients that underwent modified Duplay urethroplasty comprised Group B. All surgeries were performed by the same senior

pediatric urologist who specializes in hypospadias repair. The study was performed with approval from the Institutional Ethical Committee of Nanjing Children's Hospital. Informed consent was obtained from each patient's parents for participation in this study.

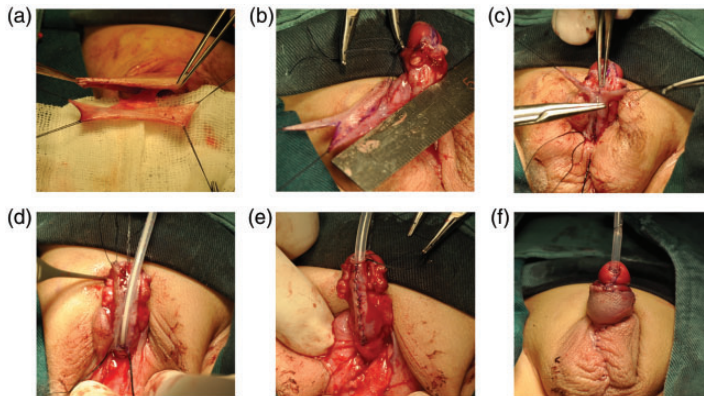
### *Surgical techniques*

**Group A (Onlay-tube-onlay urethroplasty).** After general anesthesia, the UP was protruded and carefully cut along both sides in parallel, from the glans to the opening of the urethral meatus. A circumferential incision was performed 5–10 mm proximal to the coronary sulcus; the foreskin was then degloved to the penile base and the ventral side fibrous tissue was excised to release the chordee (Figure 1a,b). The glans was dissected as two wings and the UP was transected. If necessary, dorsal albuginea plication was performed to correct chordee. Straightening was confirmed by using artificial erection. TIPF was harvested on the basis of urethral defect. The width of the middle flap was approximately 12–15 mm, and both ends of the flap were approximately 6–8 mm (Figure 1c–f). A 6–8-Fr double lumen silicon catheter was placed into the bladder and the flap was transferred to the ventral side. The ends of flap were sutured over the transected UP to reconstruct the proximal ends of the neourethra, and the wider portion of the flap was tubularized to produce the middle section of the urethra. The distal urethral was made in a similar manner to the proximal section. The new constructed urethra was covered by using subcutaneous tissue. The wings of the glans were sutured together in the midline; residual foreskin was transferred and trimmed to cover the penile shaft.

**Group B (modified Duplay urethroplasty).** The first steps of the modified Duplay technique



**Figure 1.** Method of onlay-tube-onlay urethroplasty. (a,b) The UP was protected and degloved the foreskin to the base of penile and excised the ventral side fibrous to release the chordee. (c,e) Transected the UP and made dorsal albuginea plication to correct chordee. TIPF was harvested based on urethral defect, the flap is wider at the middle portion. (f) Middle portion of the flap was tubularized, and the distal and proximal flap was sutured over the transected UP.

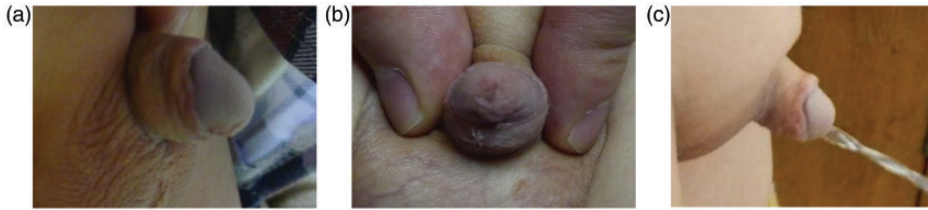

**Figure 2.** Detailed method of modified Duplay urethroplasty. (a) Transverse rectangular vascularized island flap was made in accordance with the principles of Duckett urethroplasty. (b) An appropriate length of the V-shaped block was cut at both ends of the vascularized island flap. (c, d) The urethral plate was reconstructed by using the transected native urethral plate inserted into V-shaped ends of the preputial island flap. (e) A new urethra was constructed by tubularizing the newly reconstructed urethral plate, in accordance with Duplay procedures. (f) Two wings of the glans were closed over the distal section of the neourethra. The left preputial skin was transferred ventrally to provide cover for the penile shaft.

(foreskin degloving, chordee correction, UP transection and TIPF harvest) were identical to those described above. The flap width was approximately 1.2–1.5 cm (Figure 2a). The length of midline incision on both ends of the flap was made according to the length of the transected UP. Preserved UP ends were inserted into the flap incisions and sutured together to reconstruct the neourethral plate (Figure 2b–d). Then, a 6–8-Fr double lumen silicon catheter was placed into the bladder, overlying the newly constructed UP. The newly reconstructed

UP was tubularized in accordance with Duplay procedures (Figure 2e). The suture line was made in a ventral direction. The remaining steps were performed as for patients in Group A. The repair maneuver of modified Duplay urethroplasty is shown in Figure 3.

All 65 patients received the same postoperative treatment. The dressing was removed on the fifth postoperative day; the catheter was removed at 10–12 days postoperatively. The patients received intravenous infusion of antibiotics after surgery.



**Figure 3.** Cosmetic appearance of the penis at 6 months postoperatively. (a) Completely straightened chordee. (b) Opening of the new urethra at the tip of the meatus. (c) Urinary stream shown is a smooth, slit line.

**Table 1.** Patient characteristics.

	Group A	Group B	t or $\chi^2$	P-value
N (patients)	32	33	–	–
Age (years)	$2.78 \pm 3.25$	$2.58 \pm 2.21$	0.29	0.77
Length of defect (cm)	$4.02 \pm 0.59$	$3.87 \pm 0.70$	0.87	0.39
2–3	4	5	–	–
3–4	21	19	–	–
4–5	8	8	0.20	0.91

### Follow-up

The patients visited our clinics at 1, 3, and 6 months postoperatively, then yearly thereafter. The patients' outcomes were assessed. Urethral strictures were diagnosed on the basis of symptoms and uroflowmetry. Notably, uroflowmetry was performed in accordance with a published protocol.<sup>9</sup>

### Statistical analysis

The results were analyzed using SPSS (Version 14.0; SPSS, Inc., Chicago, IL, USA) software, and were expressed as mean  $\pm$  standard deviation. Pearson's chi-squared test was used to compare differences between Group A and Group B.  $P < 0.05$  was considered statistically significant.

### Results

Thirty-two patients underwent onlay-tube-onlay urethroplasty (Group A), and the remaining 33 patients underwent modified Duplay urethroplasty (Group B). These

65 patients had the same karyotypes (46, XY), and penile chordee was straightened by using transected UP and/or dorsal plication. The width of the glans of the 65 patients was  $> 14$  mm and the UP developed well. The ages of the patients and the lengths of their urethral defects are summarized in Table 1. The mean age of the two groups was similar. The mean lengths of the urethral defect after chordee correction were  $4.02 \pm 0.59$  cm and  $3.87 \pm 0.70$  cm in the two groups. There were no statistically significant differences in the mean ages of the patients or lengths of urethral defects between the two groups.

The median follow-up durations in the two groups were 47 months and 40 months, respectively. Three patients in Group A and 10 patients in Group B demonstrated urethrocutaneous fistulas ( $P < 0.05$ ); all were minor urethrocutaneous fistulas, which were  $< 0.5$  cm in size and could be repaired by minor surgeries. Three patients in Group A and no patients in Group B demonstrated strictures. No glandular dehiscence or

**Table 2.** Outcomes of surgical complications.

	Group A (N=32)	Group B (N=33)	$\chi^2$	Odds ratio	95% Confidence interval	P-value
Complication						
Fistula	3	10	4.45	0.238	0.059–0.966	0.04
Stricture	3	0	1.463	–	–	0.226
Dehiscence	0	0	–	–	–	–
Diverticula	0	0	–	–	–	–
Uroflowmetry	11/32	17/33	–	–	–	–
Bell shaped	1	10	6.71	0.074	0.009–0.621	0.01
High platform	4	3	0.002	1.429	0.293–6.957	0.97
Other forms	6	4	0.157	1.673	0.425–6.594	0.692
Qmax (mL/second)	8.45 ± 3.72	7.58 ± 2.43	0.75	–	–	0.46

diverticula occurred, and no recurrent penile curvature was observed (Table 2). The meatus was located at the tip of the glans and the patients' parents' satisfaction with penile structure/function was good (Figure 3).

Uroflowmetry data were successfully obtained for 11 and 17 patients from the two respective groups, all of whom had no complications and urinated > 50 mL. Qmax was 8.45 ± 3.72 mL/s in Group A and 7.58 ± 2.43 mL/s in Group B. Data regarding uroflow pattern are shown in Table 2. Statistically significant differences were found in the uroflow patterns between the two groups ( $P < 0.05$ ).

## Discussion

Although many urethroplasty techniques are available for proximal hypospadias, high rates of complications continue to occur, even after treatment by skilled pediatric urologists.<sup>5</sup> For patients diagnosed with proximal hypospadias with severe chordee, transection of the UP is necessary to achieve penile straightening. In 1980, dorsal TIPF urethroplasty was reported by Duckett.<sup>10</sup> Since then, Duckett urethroplasty has been widely used for severe hypospadias; with this approach, most cases of primary hypospadias can

be repaired by single-stage surgery.<sup>11–13</sup> An important disadvantage is that rates of complications are higher, especially those involving strictures. Notably, strictures occur in 10%–30% of patient who undergo Duckett urethroplasty<sup>14–16</sup> and are particularly difficult to repair, compared with fistulas and other complications. Urethrotomy and second-stage urethroplasty are often needed; these complications have considerable impact on the use of Duckett urethroplasty.<sup>17</sup>

Although the advantages of UP are well-known, including its ability to lower the incidence of stricture, the UP-preserving procedure is generally considered unsuitable for proximal hypospadias with severe chordee.<sup>4,18</sup> Full straightening of the penis and UP transection is inevitable for such patients. In addition, full stripping and preservation of UP is needed to reduce the occurrence of stricture. Therefore, TIPF plus transected UP-preserving urethroplasty is increasingly used for proximal hypospadias.<sup>8</sup>

Onlay-tube-onlay urethroplasty, which uses TIPF plus preservation of transected UP, was first described in the 1990s.<sup>19</sup> In this procedure, the island flap is transferred to the ventral side and sutured over the proximal transected UP to construct the proximal portion of the neourethra; the wider middle portion of the flap is

tubularized to construct the middle portion of the neourethra. The distal portion of the neourethra is reconstructed in a manner similar to that of the proximal portion. Hence, there is no cycling suture needed at the anastomosis of the urethra, and the rate of strictures is lower. Thirty-two patients diagnosed with severe hypospadias underwent onlay-tube-onlay urethroplasty in our hospital, with an acceptable complication rate of 18.8% (6/32), as shown in Table 2. Three patients exhibited urethral stricture (9.4%) in Group A; this was much lower than the previously reported rates of urethral stricture in Duckett urethroplasty. However, urethral strictures continue to seriously affect the outcome of hypospadias repair, and the rates of such complications must be further reduced.

Duplay urethroplasty is well-known for its association with a few complications, especially strictures. However, Duplay urethroplasty is widely used for patients who exhibit mild or no penile chordee.<sup>20</sup> For hypospadias with severe chordee, UP transection is needed. Therefore, we modified the Duplay technique with TPIF, to further lower the rate of stricture occurrence. In this procedure, native transected UP ends are sutured with the V-shaped ends of the island flap to reconstruct the neourethral plate. Urethroplasty is then performed by tubularizing the new UP. This modified urethroplasty reduces the gap between the preserved native UP ends, and avoids the presence of a circular suture line at the junction of the urethra and the tip of the glans. Using this approach, no urethral strictures occurred among patients in Group B. The UP is a very good platform that is fixed on the ventral side of the penis; notably, it can also serve as the back wall of the reconstructed urethra. The preserved UP ends can be used as a stent to improve the quality of the new urethra.<sup>21</sup> When UP preservation is used, blood supply for neourethra is better than Duckett urethroplasty, and

healing time of suture lines is shorter. What's more, the back side of urethra attach to the corpora cavernosa of the penis, which is good for the reconstructed urethra.

This modified technique was found to lower the occurrence of stricture and improve the neourethral function. Huang et al.<sup>8</sup> reported that no strictures occurred in their patients, using this approach. Similarly, we have not encountered patients with postoperative stricture, thus far. The uroflowmetry data of 17 patients in Group B were reviewed to analyze whether the neourethra reconstructed using modified Duplay urethroplasty exhibited superior function, compared with the neourethra reconstructed using onlay-tube-onlay urethroplasty. The Qmax of 17 patients in Group B was  $7.58 \pm 2.43$  mL/s, which was better than that of patients in Group A ( $P < 0.05$ ).

Before we conducted this study, we speculated that the rates of fistula formation might be higher among patients in Group B. Indeed, 10 fistulas (30.3%) occurred among patients in Group B; this rate was significantly greater than that among patients in Group A ( $P < 0.05$ ). There are many potential causes for this disparity. Notably, the suture line of the neourethra faces the ventral side. Moreover, fistulas all occurred at the anastomosis of the urethra, where a more complex suture is used than in onlay-tube-onlay urethroplasty; in this location, blood supply is not optimal. However, all fistulas in Group B were small ( $< 0.5$  cm) and could be repaired with minor surgery. Compared with other complications, fistulas were easy to repair. During the follow-up period, no patients exhibited diverticulum in either group. This is likely because of the use of the transected UP, which served as a stent and ensured that the urethra remained smooth, which supported a robust urine stream.

There were some limitations in this study. First, the small patient sample size was

insufficient to appropriately assess the rates of complications. Second, although we achieved a good preliminary outcome, we acknowledge the need for a longer follow-up period. Therefore, future investigations with a longer follow-up period and a larger patient sample are needed to fully evaluate the outcomes of this modified urethroplasty technique.

## Conclusion

The use of TIPF plus transected UP-preserving urethroplasty, a modified Duplay urethroplasty technique, lowered the occurrence of anastomotic stricture and distal meatal stenosis, compared with onlay-tube-onlay urethroplasty. The neourethra in patients who underwent TIPF plus transected UP-preserving urethroplasty was superior to that in patients who underwent onlay-tube-onlay urethroplasty, according to the results of uroflowmetry. Therefore, the modified urethroplasty might be a useful option for repairing proximal hypospadias with severe chordee.

## Acknowledgments

We thank Dr. Fang Chen for his assistance with the manuscript and the surgical procedure. We thank the parents of all patients in this study. We also thank all members of the Department of Urology at Nanjing Children's Hospital.

## Declaration of conflicting interest

The authors declare that there is no conflict of interest.

## Funding

This research received funding from the Science and Technology Development Project of Nanjing Medical University (2017NJMUZD052) and SEU-NMU cooperation project (2242018K3DN02).

## ORCID iD

Li-Qu Huang  <http://orcid.org/0000-0001-7718-6446>

## References

1. Macedo A Jr, Rondon A and Ortiz V. Hypospadias. *Curr Opin Urol* 2012; 22: 447–452.
2. Springer A. Assessment of outcome in hypospadias surgery—a review. *Front Pediatr* 2014; 2: 2.
3. Nordenvall AS, Frisén L, Nordenström A, et al. Population based nationwide study of hypospadias in Sweden, 1973 to 2009: incidence and risk factors. *J Urol* 2014; 191: 783–789.
4. Rigamonti W and Castagnetti M. Onlay on albuginea: modified onlay preputial island flap urethroplasty for single-stage repair of primary severe hypospadias requiring urethral plate division. *Urology* 2011; 77: 1498–1502.
5. Soave A, Riechardt S, Engel O, et al. Complications of hypospadias repairs. *Urologe A* 2014; 53: 1001–1005.
6. Kraft KH, Shukla AR and Canning DA. Proximal hypospadias. *Sci World J* 2011; 11: 894–906.
7. Örtqvist L, Fossum M, Andersson M, et al. Long-term followup of men born with hypospadias: urological and cosmetic results. *J Urol* 2015; 193: 975–982.
8. Huang Y, Xie H, Lv Y, et al. One-stage repair of proximal hypospadias with severe chordee by in situ tubularization of the transverse preputial island flap. *J Pediatr Urol* 2017; 13: 296–299.
9. Austin PF, Bauer SB, Bower W, et al. The standardization of terminology of lower urinary tract function in children and adolescents: Update report from the standardization committee of the International Children's Continence Society. *Neurourol Urodyn* 2016; 35: 471–481.
10. Duckett JW. Transverse preputial island flap technique for repair of severe hypospadias. *Urol Clin North Am* 1980; 7: 423–430.
11. Standoli L. One-stage repair of hypospadias: preputial island flap technique. *Ann Plast Surg* 1982; 9: 81–88.
12. Standoli L. Vascularized urethroplasty flaps. The use of vascularized flaps of preputial and penopreputial skin for urethral

- reconstruction in hypospadias. *Clin Plast Surg* 1988; 15: 355–370.
13. Jones BC, O'Brien M, Chase J, et al. Early hypospadias surgery may lead to a better long-term psychosexual outcome. *J Urol* 2009; 182: 1744–1750.
  14. Fraumann SA, Stephany HA, Clayton DB, et al. Long-term follow-up of children who underwent severe hypospadias repair using an online survey with validated questionnaires. *J Pediatr Urol* 2014; 10: 446–450.
  15. Perera M, Jones B, O'Brien M, et al. Long-term urethral function measured by uroflowmetry after hypospadias surgery: comparison with an age matched control. *J Urol* 2012; 188: 1457–1462.
  16. Kraft KH, Shukla AR and Canning DA. Hypospadias. *Urol Clin N Am* 2010; 37: 167–181.
  17. Spinoit AF, Poelaert F, Groen LA, et al. Hypospadias repair at a tertiary care center: long-term followup is mandatory to determine the real complication rate. *J Urol* 2013; 189: 2276–2281.
  18. Erol A, Baskin LS, Li YW, et al. Anatomical studies of the urethral plate: why preservation of the urethral plate is important in hypospadias repair. *BJU Int* 2000; 85: 728–734.
  19. Flack CE and Walker RD 3rd. Onlay-tube-onlay urethroplasty technique in primary perineal hypospadias surgery. *J Urol* 1995; 154: 837–839.
  20. Steckler RE and Zaontz MR. Stent-free Thiersch-Duplay hypospadias repair with the Snodgrass modification. *J Urol* 1997; 158: 1178–1180.
  21. Zheng DC, Yao HJ, Cai ZK, et al. Two-stage urethroplasty is a better choice for proximal hypospadias with severe chordee after urethral plate transection: a single-center experience. *Asian J Androl* 2015; 17: 94–97.