

A novel approach to resolve severe mediastinal and subcutaneous emphysema occurring in *Pneumocystis jirovecii* pneumonia using vacuum-assisted closure therapy

SAGE Open Medical Case Reports
Volume 8: 1–4
© The Author(s) 2020
Article reuse guidelines:
sagepub.com/journals-permissions
DOI: 10.1177/2050313X20918989
journals.sagepub.com/home/sco



Noor H Bouwmeester¹ , Hans Kieft¹,
Ghada MM Shahin² and Arno P Nierich³

Abstract

A 50-year-old human immunodeficiency virus positive patient who was diagnosed with *Pneumocystis jirovecii* pneumonia developed severe subcutaneous and mediastinal emphysema, which was progressive despite low pressure mechanical ventilation. Infraclavicular skin incisions and vacuum-assisted closure therapy were used to resolve the emphysema. The subcutaneous emphysema decreased significantly, and after 1 week the vacuum-assisted closure therapy was ended successfully. This technique has previously been described in several case reports, where it is a promising treatment in severe subcutaneous emphysema, but it is not yet widely used. This case report supports the further use of vacuum-assisted closure therapy in subcutaneous emphysema. Successful treatment of severe mediastinal and subcutaneous emphysema in *Pneumocystis jirovecii* pneumonia can be achieved by vacuum-assisted closure therapy on infraclavicular skin incisions.

Keywords

Pneumocystis, subcutaneous emphysema, mediastinal emphysema, negative-pressure wound therapy, vacuum-assisted closure therapy

Date received: 24 May 2017; accepted: 18 March 2020

Introduction

This case report describes a case of severe subcutaneous and mediastinal emphysema without pneumothorax in a patient with *Pneumocystis jirovecii* pneumonia (PJP), which was treated with vacuum-assisted closure (VAC) therapy.

The occurrence of spontaneous pneumomediastinum in PJP is rare but has been described in several case reports.^{1–10} Pneumomediastinum in these cases was usually related to intubation or lung function tests. A few case reports describe subcutaneous emphysema together with pneumomediastinum, although not as extensive as in our patient.^{9,10} There are no reports of spontaneous subcutaneous emphysema without pneumothorax or pneumomediastinum in PJP. Subcutaneous emphysema often resolves spontaneously, but VAC therapy has been used in the treatment of subcutaneous emphysema after cardiothoracic surgery and in association with mechanical

ventilation.^{11–13} Also, “blow-hole” skin incisions have been used in the past to release air in severe subcutaneous emphysema.^{14,15} Severe subcutaneous and mediastinal emphysema can be life threatening due to compression of the heart and lungs; therefore, it requires treatment if it does not resolve spontaneously or when it leads to circulatory problems. The VAC therapy used in this case report was initiated as a last resort treatment due to a lack of other options and no spontaneous improvement.

¹Department of Intensive Care, Isala, Zwolle, The Netherlands

²Department of Cardiothoracic Surgery, Isala, Zwolle, The Netherlands

³Department of Cardiothoracic Anesthesiology, Isala, Zwolle, The Netherlands

Corresponding Author:

Hans Kieft, Department of Intensive Care, Isala, Postbus 10400, 8000 GK Zwolle, The Netherlands.

Email: h.kieft@isala.nl



Case description

A 50-year-old male patient was admitted to our hospital with progressive dyspnea, cough, and cold sweats. He mentioned night sweating for a year and 15 kilograms weight loss. His medical history stated a human immunodeficiency virus (HIV) infection since 2003, with a double-sided pneumonia with *Pneumocystis jirovecii* (among other pathogens) at admittance, therefore diagnosed as acquired immunodeficiency syndrome (AIDS). Patient was treated with antiretroviral therapy with an undetectable viral load in 2012, but had stopped taking medication 1 year ago. He lived in a homeless shelter with his wife (who was also HIV positive); his children were accommodated elsewhere. There was no (intravenous) drug or alcohol use, and he had quit smoking 15 years ago. Physical examination on admission showed a non-acutely ill patient, tachypneic with an oxygen saturation of 88% on room air. His blood pressure was 130/80 mmHg, heart rate 132 per minute, and temperature 38.2°C. Percussion of the lungs did not reveal any dullness, and at auscultation normal breath sounds were heard except for the left lower side. Other physical examination was unremarkable.

Relevant laboratory results on admission were hemoglobin 7.2 mmol/L, white blood cell count $6.6 \times 10^9/L$, platelets $214 \times 10^9/L$, and C-reactive protein (CRP) 64 mg/L. There was no renal or hepatic insufficiency. Immunology results were as follows: CD4: $0.039 \times 10^9/L$, CD8: $1.2 \times 10^9/L$, CD4/CD8 ratio: 0.033. A chest X-ray showed bilateral “cloudy” infiltrates.

The patient was treated according to the local sepsis protocol, with gentamicin 280 mg and amoxicillin/clavulanic acid 1200 mg intravenously in the emergency room. This was followed by cotrimoxazole (3×1920 mg) and prednisolone (2×40 mg) the next day for suspected PJP. Two days after admission, a bronchoscopy with bronchoalveolar lavage (BAL) was performed to confirm the diagnosis. Directly after this procedure, the patient became dyspneic, had low oxygen saturations (82%), and developed subcutaneous emphysema. Due to progressive respiratory insufficiency, endotracheal intubation and mechanical ventilation were necessary. Bronchoscopy-guided intubation was performed in the operating theater, which was uneventful. A computed tomography (CT) scan of the chest immediately after intubation showed subcutaneous and mediastinal emphysema without pneumothorax. Also, severe air bronchograms and bilateral infiltrations were seen. Patient was admitted to the intensive care unit (ICU) afterward.

During the (ventilatory) treatment on the ICU, the subcutaneous and mediastinal emphysema increased, resulting in swelling of the entire face, arms, and torso down to the scrotum (Figure 1). Several bronchoscopies were performed to exclude tracheal injury that could have occurred during the BAL, but no injury was visualized. Despite efforts to treat patient with lung protective ventilation, using low tidal volumes and low airway pressures, the emphysema continued to increase. A new CT scan was performed 1 week after

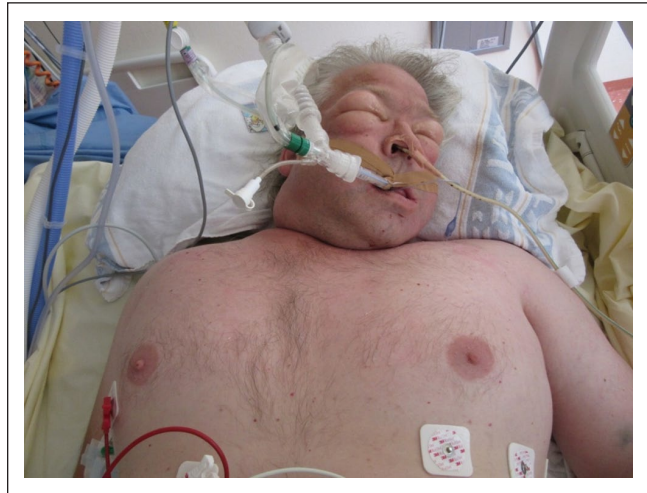

Figure 1. Photograph of subcutaneous emphysema prior to VAC therapy (with permission).

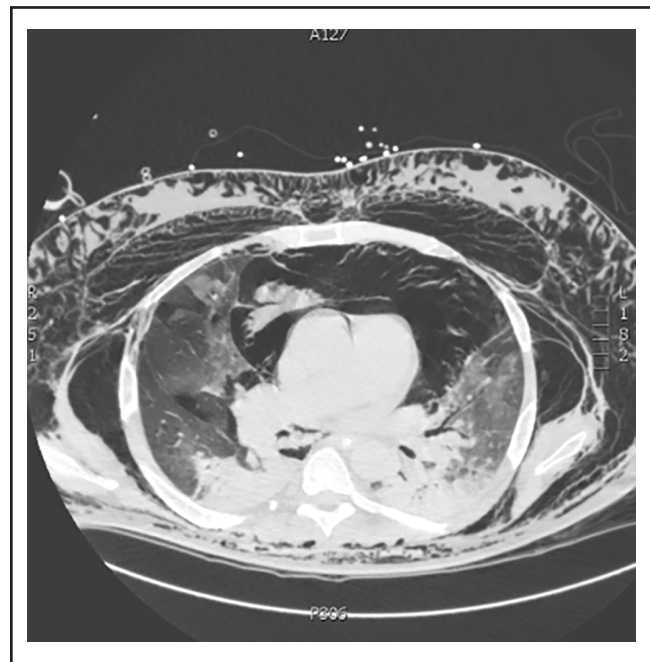


Figure 2. Chest CT scan 1 week after admission to the ICU (with permission).

admission to the ICU, showing severe subcutaneous and mediastinal emphysema (Figure 2). Treatment of the emphysema by skin incisions alone (“blow holes”) was considered but discarded due to the high HIV viral load (700,000 copies/mL) of the patient and the fear of viral spreading by blood spatters. Because of the severity and increase of the symptoms and no obvious tracheal injury (on subsequent bronchoscopies and CT scans), a search for other treatment options was performed. After elaborate consideration, it was decided to make two infraclavicular skin incisions and place VAC therapy on these incisions (ActiV.A.C., KCI Medical,

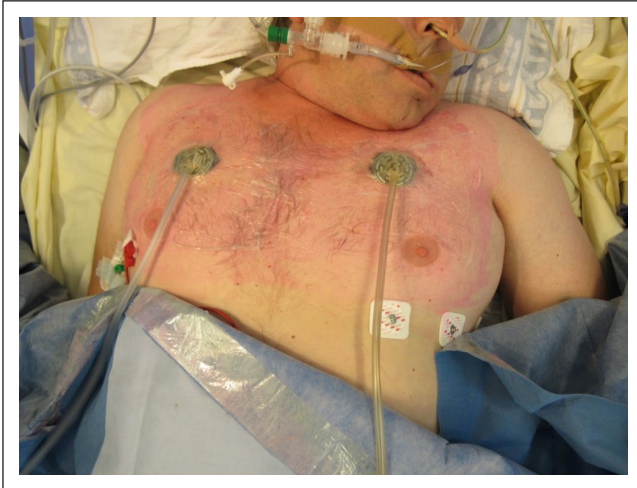

Figure 3. Photograph of VAC system in situ (with permission).

–125 mm Hg; Figure 3). While the subcutaneous emphysema started to improve significantly, a gradual clinical improvement was seen in the first week. VAC therapy was ended 9 days after initiation. The subcutaneous emphysema continued to decrease after removal of the VAC therapy system.

During his stay on the ICU, inflammatory markers decreased together with the pulmonary infiltrations on the chest X-ray, implying adequate treatment of the PJP. Patient was extubated after 17 days of mechanical ventilation, with a significant ICU-acquired weakness. Furthermore, dysphonia was reported, possibly caused by emphysema of the larynx. The patient was discharged to the general ward 25 days after admission to the ICU. Antiretroviral medicine was restarted, and patient was finally discharged to a medical rehabilitation center for further recovery.

Literature review

Research in three medical databases (PubMed, Embase, and Cochrane libraries) using the search (MeSH) terms “vacuum assisted closure therapy,” “negative pressure wound therapy,” “subcutaneous emphysema,” “mediastinal emphysema,” and “pneumothorax” in variable combinations revealed a total of 29 unique articles. After selecting on title, abstract, English language, and full text availability, six articles remained describing the use of VAC therapy in subcutaneous emphysema, pneumothorax, or pneumomediastinum.^{11,12,16–18} Byun et al.¹¹ described four patients with pneumothorax and thoracic subcutaneous emphysema after cardiothoracic surgery, who were successfully treated with VAC therapy adjacent to chest tube drainage with a mean therapy duration of 3 days. The main improvement was already seen after 24 h. Negative pressure wound therapy (NPWT) was also used in a case of severe subcutaneous emphysema in a trauma patient, described by Mihanovic et al.¹⁶ Sciortino et al.¹⁷ described a patient after upper lobe bullectomy with a tension pneumothorax and

severe subcutaneous emphysema, which drastically improved within 48 h after initiating NPWT, where chest tube drainage alone had failed. Son et al. described the use of NPWT in 10 patients on mechanical ventilation, expressing their concern of using “blow holes” alone in mechanical ventilation as this might not release enough air. The duration of NPWT in patients on mechanical ventilation was longer than described previously by Byun et al. with a mean of 7.5 days (± 5.1 days).¹¹ Towe et al.¹² reported a patient with persistent subcutaneous emphysema after a lobectomy, despite adequate chest tube drainage. They claim to be the first ones to describe bilateral skin incisions. The duration of their therapy was 8 days until full recovery. The last case series was described in a conference abstract by Hristova et al.¹⁴ where six patients underwent NPWT in addition to chest tube drainage, with either unilateral or bilateral “blow hole” incisions and always using unilateral NPWT. Most patients showed significant improvement of subcutaneous emphysema within 24 h.

Discussion

Severe subcutaneous emphysema is a condition that needs adequate treatment, because of the danger of impaired blood supply to the skin, muscles, and other tissues. Furthermore, mediastinal emphysema can lead to reduced expansion of the lungs leading to respiratory insufficiency, damage to compressed lungs, and an altered blood flow especially in tension pneumomediastinum.^{11,19} It can even lead to cardiac compression mimicking cardiac tamponade.¹⁹ When the emphysema is caused by a pneumothorax, this is usually treated by chest tube drainage. Literature search does reveal the use of VAC therapy in cases of subcutaneous emphysema but mainly used in addition to chest tube drainage in pneumothorax.^{12,14,15,17} It is questionable whether this therapy has an advantage to chest tube drainage alone, which is frequently used after thoracic surgery and is successful in most cases. A review into the use of other therapies for persistent subcutaneous emphysema does mention the use of “blow holes” or subcutaneous tube drainage, but they create a lot of work with frequent change of wound dressings and a risk of clotting the tubes.^{13,20} A disadvantage of VAC therapy can be discomfort of the patient when changing wound dressings, skin damage due to the suctioning, and scars due to the incisions.

Subcutaneous emphysema usually dissolves spontaneously in the course of several days to weeks, depending on its severity.⁶ It is possible that the improvement seen in our patient was the natural course of the illness and thus had been self-limiting. However, since the subcutaneous emphysema started to improve significantly after applying the VAC therapy, this improvement was more likely to be a result of the VAC therapy.

Further clinical research into the use of VAC therapy in severe subcutaneous emphysema (spontaneous or otherwise not caused by pneumothorax) is essential, but options are

limited due to the small number of eligible patients. This treatment option, however, should be considered in such cases.

Conclusion

Severe mediastinal and subcutaneous emphysema without pneumothorax in a ventilated HIV-positive patient with PJP can be treated using VAC therapy on (infraclavicular) skin incisions.

Author contributions

All authors have been involved in the procedure described in this article and have had a substantial contribution to the article.

Declaration of conflicting interests

The author(s) declared no potential conflicts of interest with respect to the research, authorship, and/or publication of this article.

Ethical approval

Our institution does not require ethical approval for reporting individual cases or case series.

Funding

The author(s) received no financial support for the research, authorship, and/or publication of this article.

Informed consent

Written informed consent was obtained from the patient(s) for their anonymized information to be published in this article.

ORCID iD

Noor H Bouwmeester  <https://orcid.org/0000-0002-2720-149X>

References

- Cheng W-L, Ko W-C, Lee N-Y, et al. Pneumomediastinum in patients with AIDS: a case report and literature review. *Int J Infect Dis* 2014; 22: 31–34.
- Kaji Y, Ohara G, Kagohashi K, et al. Pneumomediastinum in a patient with *Pneumocystis jirovecii* pneumonia. *Intern Med* 2012; 51(16): 2251.
- Mina NM and Soubani AO. Complication of *Pneumocystis jirovecii* pneumonia. *Respiration* 2011; 82(3): 288–289.
- Cho JY, Kim DM, Kwon YE, et al. Newly formed cystic lesions for the development of pneumomediastinum in *Pneumocystis jirovecii* pneumonia. *BMC Infect Dis* 2009; 9: 171.
- Lee JC, Bell DC, Guinness RM, et al. *Pneumocystis jirovecii* pneumonia and pneumomediastinum in an anti-TNF α naive patient with ulcerative colitis. *World J Gastroenterol* 2009; 15(15): 1897–1900.
- Park YK, Jung HC, Kim SY, et al. Spontaneous pneumomediastinum, pneumopericardium, and pneumothorax with respiratory failure in a patient with AIDS and *Pneumocystis jirovecii* pneumonia. *Infect Chemother* 2014; 46(3): 204–208.
- Goodman LF, Kingrey J and O'Brien JM. Pneumopericardium as presenting feature of HIV/AIDS with *P. jirovecii* pneumonia. *Am J Respir Crit Care Med* 2012; 185: A4614.
- Sakamoto A, Kogou Y, Matsumoto N, et al. Massive subcutaneous emphysema and pneumomediastinum following endotracheal intubation. *Intern Med* 2013; 52(15): 1759.
- She WH, Chok KSH, Li IWS, et al. *Pneumocystis jirovecii*-related spontaneous pneumothorax, pneumomediastinum and subcutaneous emphysema in a liver transplant recipient: a case report. *BMC Infect Dis* 2019; 19(1): 66.
- Clancy DJ, Lane AS, Flynn PW, et al. Tension pneumomediastinum: a literal form of chest tightness. *J Intensive Care Soc* 2017; 18(1): 52–56.
- Byun CS, Choi JH, Hwang JJ, et al. Vacuum-assisted closure therapy as an alternative treatment of subcutaneous emphysema. *Korean J Thorac Cardiovasc Surg* 2013; 46(5): 383–387.
- Towe C, Solomon B, Donington JS, et al. Treatment of recalcitrant subcutaneous emphysema using negative pressure wound therapy dressings. *BMJ Case Rep* 2014; 2014: bcr2014205577.
- Johnson CH, Lang SA, Bilal H, et al. In patients with extensive subcutaneous emphysema, which technique achieves maximal clinical resolution: infraclavicular incisions, subcutaneous drain insertion or suction on in situ chest drain? *Interact Cardiovasc Thorac Surg* 2014; 18(6): 825–829.
- Hristova R, Bogdan C, Kostopanagiotou K, et al. Negative pressure wound therapy. A novel adjunct in the treatment of postoperative severe surgical emphysema. *Interact Cardiovasc Thorac Surg* 2014; 18(Suppl. 1): S54.
- Herlan DB, Landreneau RD and Ferson PF. Massive spontaneous subcutaneous emphysema. Acute management with infraclavicular “blow holes.” *Chest* 1992; 102(2): 503–505.
- Mihanovic J, Bacic I and Sulen N. Negative-pressure in treatment of persistent post-traumatic subcutaneous emphysema with respiratory failure: case report and literature review. *Trauma Case Rep* 2018; 13: 42–45.
- Sciortino CM, Munding GS, Kuwayama DP, et al. Case report: treatment of severe subcutaneous emphysema with a negative pressure wound therapy dressing. *Eplasty* 2009; 9: e1.
- Son BS, Lee S, Cho WH, et al. Modified blowhole skin incision using negative pressure wound therapy in the treatment of ventilator-related severe subcutaneous emphysema. *Interact Cardiovasc Thorac Surg* 2014; 19(6): 904–907.
- Obeso Carillo GA, Barge Caballero G and Canizares Carretero MA. The Earth-Heart sign: a new diagnostic finding in a patient with tension pneumomediastinum. *Lancet* 2014; 383(9915): 486.
- Beck PL, Heitman SJ and Mody CH. Simple construction of a subcutaneous catheter for treatment of severe subcutaneous emphysema. *Chest* 2002; 121(2): 647–649.