

Buccal Fat Pad Flap, an Option for Surgical Reconstruction of Orbital Floor Defect: A Case Report

Abstract

Buccal fat pad (BFP) is widely used in oral and maxillofacial surgery, with paucity of literature describing its use in orbital reconstruction. We report a case of a 23-year-old female who had orbital floor defect surgically reconstructed with a pedicled buccal fat pad following maxillectomy.

Keywords: *Buccal fat pad, orbital floor, reconstruction*

Introduction

Buccal fat pad (BFP) was first introduced by Heisher *et al*^[1] in 1732, it was believed to be a glandular structure and named it “glandula molaris.” BFP appear three months in utero and continuously grows until birth.^[2] BFP is a trilobed mass of fatty tissue, distinct from subcutaneous fat, situated in the midface. It is located behind the zygomatic arch, medial to the masseter muscle and lateral to the buccinator muscle from which it derives its name.^[3] It consists of a body and four processes: the buccal, pterygoid, pterygopalatine, and deep temporal. The body lies behind the zygomatic arch and consists of three independent lobes: anterior, intermediate and posterior and while the processes extend from the body to their respective surrounding tissue spaces.^[3] BFP get its robust blood supply from maxillary artery (buccal and temporal branches), the superficial temporal artery (transverse facial branches) and facial artery.^[3] Its average weight is 9.3 grams with a volume of 9.6 ml and can provide a pedicled graft of up to 6 × 5 × 3 centimeter.^[4] Notably, the size of the pad remains relatively constant from childhood throughout adulthood, and it appears to be resistant to wasting even in the most cachectic patients.^[5] The physiological functions of BFP are to fill the masticatory space, acting as cushion for the masticatory muscles, to counteract negative pressure during suction in a newborn, and as a rich venous net, with valve-like structures, possibly involved in the exo-endocranial blood flow through the pterygoid plexus.^[6] Despite

these various physiological functions, the BFP can be safely sacrificed in the adult patient.^[7] Clinically, the BFP has been used for aesthetic and reconstructive applications.^[7] In cosmetic surgery, BFP lipectomy has been used to improve midface width in full-faced individuals.^[8,9] Similarly, BFP removal has been used alone and in conjunction with facelift surgery to modify facial contours and enhance the malar prominence.^[9] It has been described in rhytidectomy for improvement of the nasolabial fold.^[3] Adeyemo *et al.*^[10] describe its use in closure of oro-antral fistula. A number of other studies have further described the use of BFP flaps and grafts for the reconstruction of intraoral defects.^[11,12] The versatility of the buccal fat pad is evident from the variety of other novel reconstructive uses that have been described, including coverage of irregularities following bony trauma, closure of nasal defects, closure of palate cleft and use as vascularized filler material.^[11,12] However, there is paucity in literature describing its use in orbital reconstruction. We report a case of a 23-year-old female who had orbital floor defect reconstructed with a pedicled BFP following maxillectomy.

Case Report

A 23-year-old woman presented with a three-month history of a rapidly growing swelling on her right cheek. On extra-oral examination [Figure 1] a diffuse, painless and firm swelling was noted on the right maxilla with nasal and oral extension.

The overlying skin was normal. The right eye was proptosed and superiorly displaced, with vision in both eyes preserved. Intraorally, there

This is an open access journal, and articles are distributed under the terms of the Creative Commons Attribution-NonCommercial-ShareAlike 4.0 License, which allows others to remix, tweak, and build upon the work non-commercially, as long as appropriate credit is given and the new creations are licensed under the identical terms.

For reprints contact: reprints@medknow.com

How to cite this article: Ikekhuamen EA, Gambo A, Fomete B, Agbonifo D, Yusuf O. Buccal fat pad flap, an option for surgical reconstruction of orbital floor defect: A case report. *J West Afr Coll Surg* 2022;12:95-9.

**Ernest Ahamiojie
Ikekhuamen,
Aminu Gambo,
Benjamin
Fomete,
Desmond
Agbonifo,
Olalekan Yusuf**

*Department of Oral and
Maxillofacial Surgery,
Ahmadu Bello University
Teaching Hospital, Shika-
Zaria, Kaduna State,
Nigeria*

Received: 01-Apr-2022

Accepted: 30-Apr-2022

Published: 23-Aug-2022

Address for correspondence:

*Dr. Ernest Ahamiojie Ikekhuamen,
Department of Oral Maxillofacial
Surgery, Ahmadu Bello
University Teaching Hospital,
Shika-Zaria, Kaduna State,
Nigeria.*

E-mail: ernnyikesy@yahoo.com

Access this article online

Website:

www.jwacs-jcoac.com

DOI: 10.4103/jwas.jwas_89_22

Quick Response Code:



was protruding fungating mass which obliterated the buccal sulcus on the right with involvement of the palate. Computer tomogram scan revealed huge expansive hypodense mass from the right maxillary antrum with involvement of the palate and right unilateral proptosis [Figure 2].

An incisional biopsy was done with a result of myxofibrosarcoma. The tumor was excised completely using the Weber-Fergusson approach under general anesthesia via tracheostomy tube. After extensive resection of the right maxilla including fifty percent of the orbital floor and pterygoid plates, a large defect

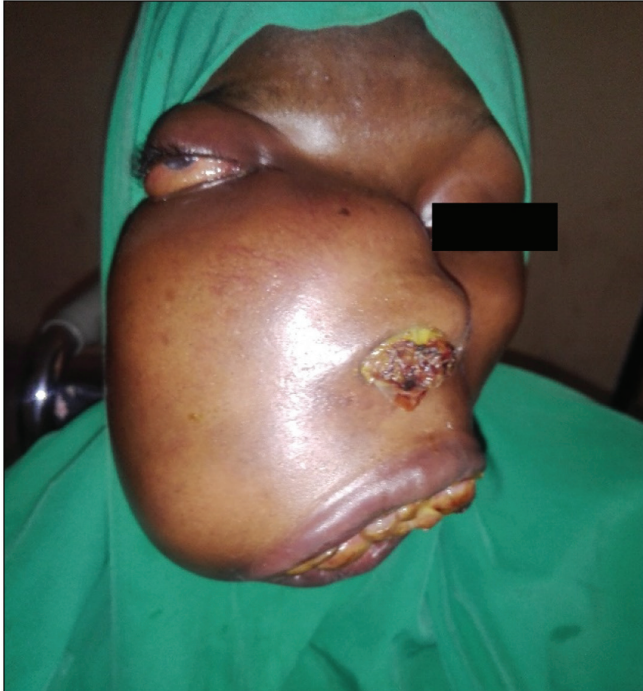

Figure 1: Extraoral clinical photograph of right facial swelling

resulted and the orbital floor reconstructed with a pedicled BFP flap [Figure 3].

The ipsilateral BFP was harvested by mobilizing the anterior attachments while preserving the posterior lobe and its vascular supply. The flap was advanced medially protecting its posterior vascular pedicle and inserted along the orbital floor [Figure 4].

The Weber-Ferguson skin flap returned and sutured with 3.0 vicryl [Figure 5] and the intraoral maxillary defect was obturated with a surgical palatal obturator.

At two weeks postoperatively [Figure 6] patient did well clinically with good eyeball projection, no diplopia, no limitation of ocular movement. Patient was discharged to another tertiary facility where she will benefit from chemo-radio oncology management and was lost to follow up.

Discussion

Maxillary defects after trauma or tumor resection can cause severe functional and cosmetic deformities. The orbital floor forms the roof of the maxillary antrum and is usually involved in extensive maxillectomy for midfacial tumors. The orbital floor is a very important bony structure in the midfacial region that is responsible for supporting the eye globe, midfacial projection, and facial symmetry. Orbital floor defects also result in various deformities and functional disturbances, such as diplopia, enophthalmos, ophthalmoplegia, a decrease in visual acuity, and depression of the infraorbital region.^[13] In this case, the maxillary defect was as a result of maxillectomy following histologically diagnosed maxillary myxofibrosarcoma. The reconstruction of post-traumatic orbital defects has been well documented in recent years.^[14-16] However, the reconstruction of orbital floor defects after extensive maxillectomy remains a challenge for surgeons. The goals of orbital floor reconstruction include restoration of the shape and framework of the orbit,

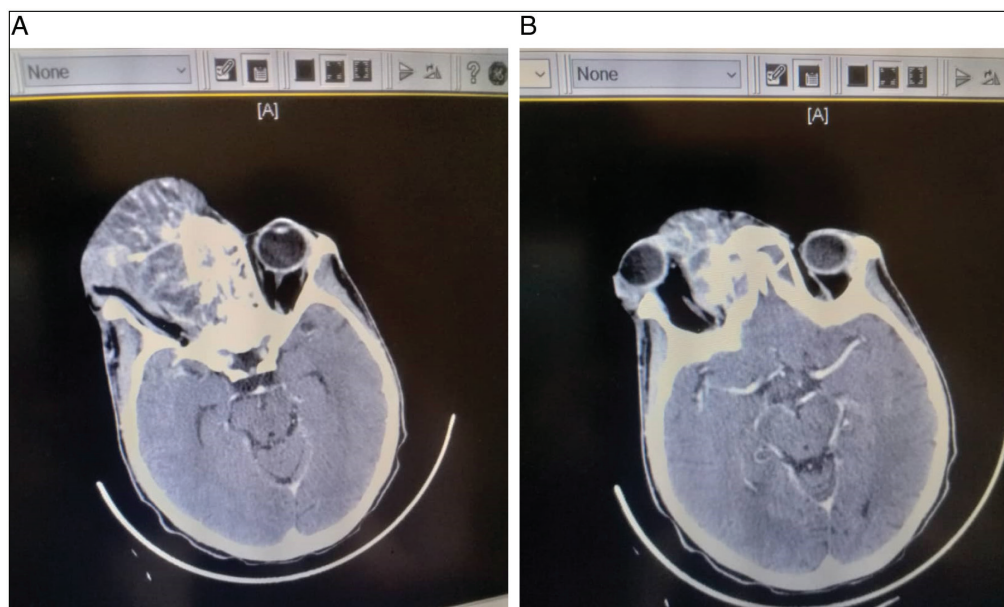


Figure 2: CT scan axial sections

provision of support and maintenance of the position of the eye globe, rehabilitation of the orbital volume, and restoration of facial esthetics. However, the thinness and irregular contour of the orbit make it difficult to find an appropriate material for precise reconstruction of orbital defects, and complications such as diplopia, enophthalmos, and restriction of ocular mobility, become inevitable in some cases.^[13] Minimal loss of the orbital floor in a standard maxillectomy may not result in loss of orbital support since the periorbita will support it. But, when the loss

is more, either in the medio-lateral direction or in the antero-posterior direction when entire floor of orbit is removed, support for the globe may be necessary.^[17] Iyar S and Thankappai K^[17] reported the study of Rao *et al.* indicating that the use of soft-tissue flaps alone in these situations may not be ideal. The number of cases with enophthalmos and hypophthalmos was higher when compared to bony reconstruction of the floor in the series reported by them. Several materials and methods have been used for orbital floor reconstruction, including autogenous bone grafts, alloplastic materials, and other manufactured materials.^[18-20] Previous studies have reported the use of non-vascularized autogenous bones, such as the iliac bone, ribs, and calvaria, as grafts for orbital floor reconstruction.^[21,22] However

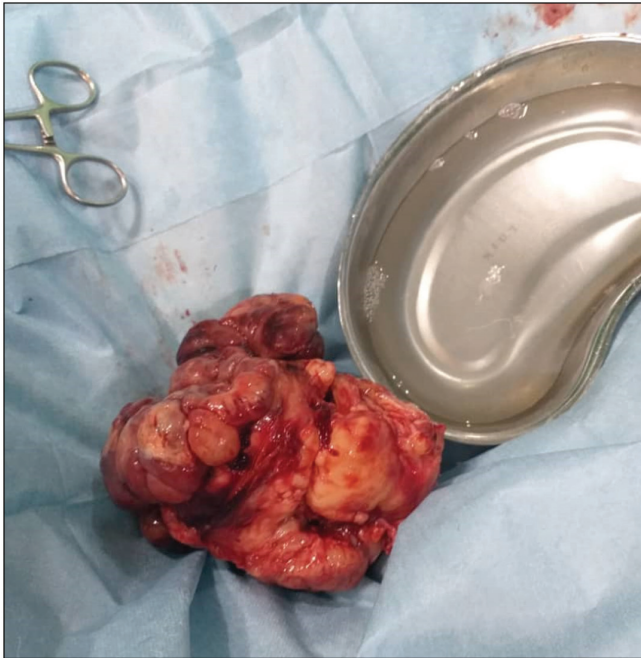


Figure 3: Intraoperative images showing: Tumor resected

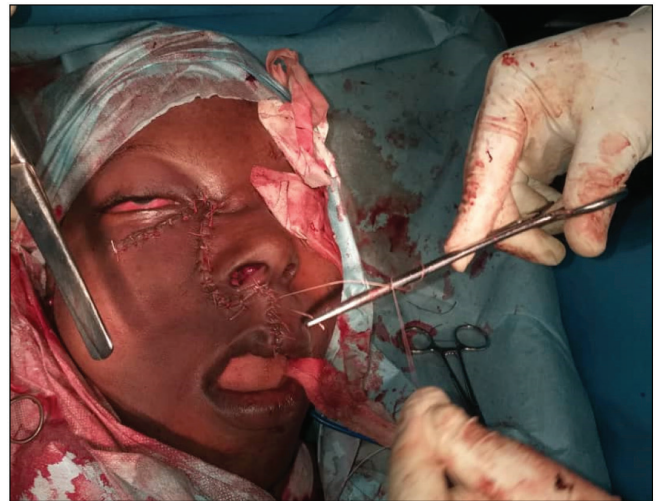

Figure 5: immediate postoperative clinical photograph

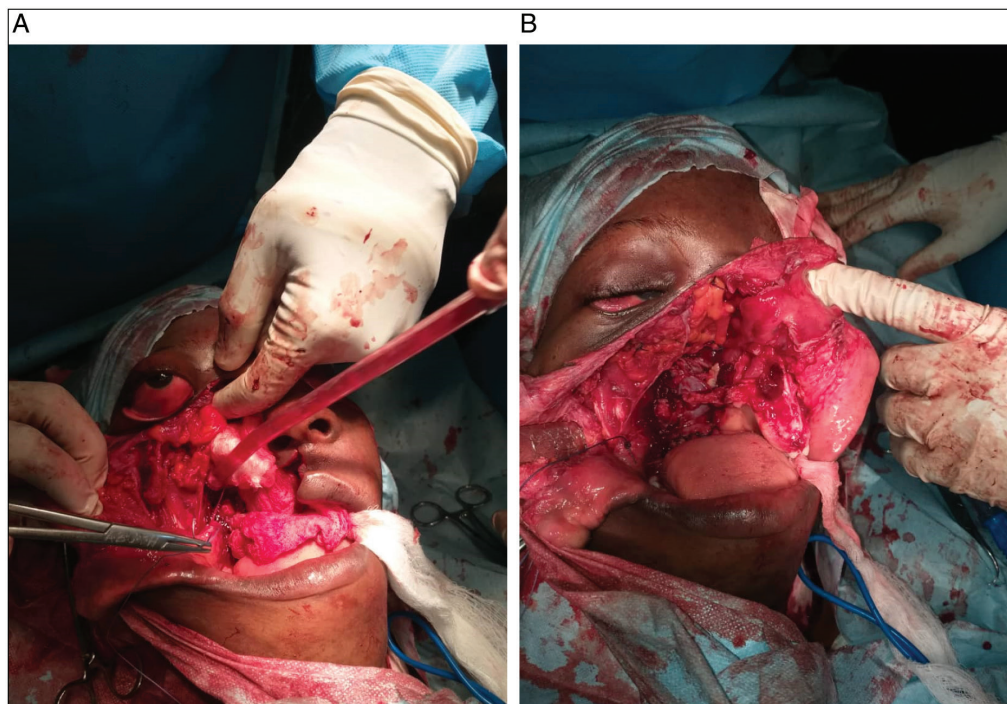


Figure 4: Intraoperative orbital floor reconstruction with pedicled buccal fat pad

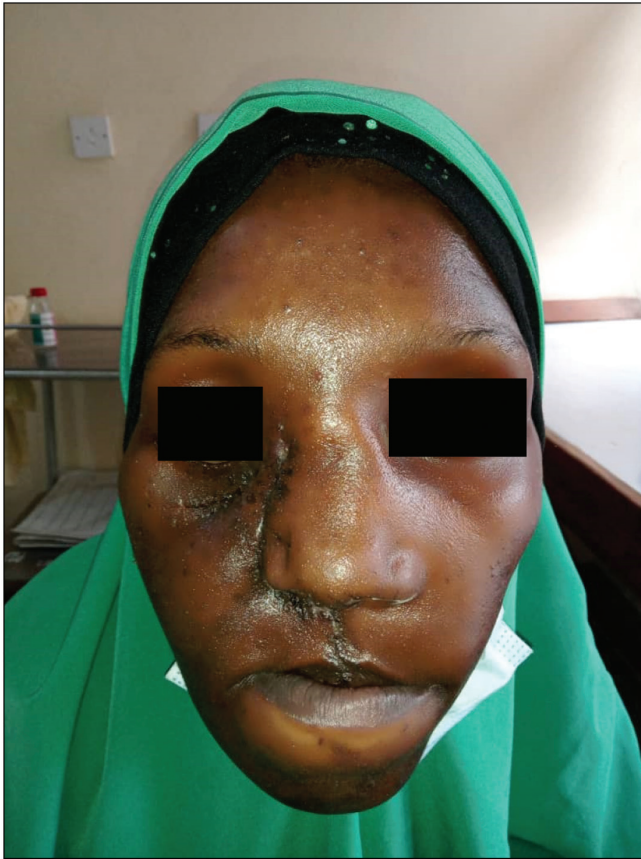

Figure 6: Two weeks postoperative clinical photograph

the rate of infection and resorption with these materials is high. In addition, donor-site morbidity is a potential disadvantage of these materials.^[13] Titanium meshes are commonly used for reconstruction of the orbital floor defect after ablative surgery and trauma, and they are currently the first choice of material for post-traumatic orbital reconstruction.^[23,24] The problem with using the mesh is its high extrusion rate, especially with the post-operative radiation therapy.^[17] In this case 50% of the orbital floor was lost following the excision of the tumor, and pedicled buccal fat pad was used for its reconstruction. The anatomical location of the buccal fat pad makes it an ideal source of tissue for orbital reconstruction. It is easily visualized and mobilized following the buccal vestibular incision for the Weber-Ferguson approach. This extended approach avoids injury to the facial nerve.^[7] The buccal fat pad is a structure that persists at a constant volume throughout life, even in patients with extreme wasting of other fat stores.^[5] Therefore, it can be utilized in nearly all patients, except in those who have had previous procedures that violated the fat pad.^[7] The buccal fat pad is a highly vascular structure that derives its arterial blood supply from a rich network, this robust vascularity obviously supports the viability of this structure in its reconstructive applications.^[7] Accordingly, the buccal fat pad can be expected to serve as a valuable source of vascular tissue when alloplastic or biologic implants are being used.^[7] Since the buccal fat pad is a highly vascular and fatty tissue, it is believed that it may improve the

tolerance to radiation therapy.^[7] Although the flap is robust and accessible, potential drawbacks exist. Mobilization of the fat pad may create diminished midface volume or asymmetry that can be aesthetically displeasing. In addition, this flap is limited by a relatively small volume of available tissue, which may not be adequate for massive orbital floor defect.^[7]

Conclusion

Reconstruction of orbital floor defect with pedicle BFP may be considered among the numerous aesthetic and reconstructive orofacial applications, given the ease of dissection, quality of vascularized tissue and consistent volume between patients.

Financial support and sponsorship

Nil.

Conflicts of interest

There are no conflicts of interest.

REFERENCES

1. Marzano UG. Lorenz Heister's "molar gland." *Plast Reconstr Surg* 2005;115:1389-93.
2. Arce K. Buccal fat pad in maxillary reconstruction. *Atlas Oral Maxillofac Surg Clin North Am* 2007;15:23-32.
3. Zhang HM, Yan YP, Qi KM, Wang JQ, Liu ZF. Anatomical structure of the buccal fat pad and its clinical adaptations. *Plast Reconstr Surg* 2002;109:2509-18; discussion 2519-20.
4. Abdel-Aziz M, Fawaz M, Kamel M, Kamel A, Aljerais T. Closure of oroantral fistula with buccal fat pad flap and endoscopic drainage of the maxillary sinus. *J Craniofac Surg* 2018;29:2153-5.
5. Xiao H, Bayramicli M, Jackson IT. Volumetric analysis of the buccal fat pad. *Eur J Plast Surg* 1999;22:177.
6. Rácz L, Maros TN, Seres-Sturm L. Structural characteristics and functional significance of the buccal fat pad (*Corpus adiposum buccae*). *Morphol Embryol (Bucur)* 1989;35:73-7.
7. Luthes H, Holton MD, Eduardo D, Rodriguez DDS, Ronald P, Silverman MD, et al. The buccal fat pad flap for periorbital reconstruction: A cadaver dissection and report of two cases. *Ideas and Innovations* 2004;104:1529-33.
8. Matarasso A. Buccal fat pad excision: Aesthetic improvement of the midface. *Ann Plast Surg* 1991;26:413-8.
9. Jackson IT. Anatomy of the buccal fat pad and its clinical significance. *Plast Reconstr Surg* 1999;103:2059-60; discussion 2061-3.
10. Adeyemo WL, Ogunlewe MO, Ladeinde AL, James O. Closure of oro-antral fistula with pedicled buccal fat pad: A case report and review of literature. *African J Oral Heal* 2004;1:42-6.
11. Neder A. Use of buccal fat pad for grafts. *Oral Surg Oral Med Oral Pathol* 1983;55:349-50.
12. Adeyemo WL, Ladeinde AL, Ogunlewe MO, Bamgbose BO. The use of buccal fat pad in oral reconstruction: A review. *Niger Postgr Med J* 2004;11:207-11.
13. Zhang WB, Mao C, Liu XJ, Guo CB, Yu GY, Peng X. Outcomes of orbital floor reconstruction after extensive maxillectomy using the computer-assisted fabricated individual titanium mesh technique. *J Oral Maxillofac Surg* 2015;73:2065-e1.
14. Fan X, Zhou H, Lin M, Fu Y, Li J. Late reconstruction of the complex orbital fractures with computer-aided design and computer-aided manufacturing technique. *J Craniofac Surg* 2007;18:665-73.

15. Lieger O, Richards R, Liu M, Lloyd T. Computer-assisted design and manufacture of implants in the late reconstruction of extensive orbital fractures. *Arch Faci Plast Surg* 2010;12:186-91.
16. Tabrizi R, Ozkan TB, Mohammadinejad C, Minaee N. Orbital floor reconstruction. *J Craniofac Surg* 2010;21:1142-6.
17. Iyer S, Thankappan K. Maxillary reconstruction: Current concepts and controversies. *Indian J Plast Surg* 2014;47:8-19.
18. Chowdhury K, Krause GE. Selection of materials for orbital floor reconstruction. *Arch Otolaryngol Head Neck Surg* 1998;124:1398-401.
19. Baino F. Biomaterials and implants for orbital floor repair. *Acta Biomater* 2011;7:3248-66.
20. Morrison AD, Sanderson RC, Moos KF. The use of silastic as an orbital implant for reconstruction of orbital wall defects: Review of 311 cases treated over 20 years. *J Oral Maxillofac Surg* 1995;53:412-7.
21. Ilankovan V, Jackson IT. Experience in the use of calvarial bone grafts in orbital reconstruction. *Br J Oral Maxillofac Surg* 1992;30:92-6.
22. Talesh KT, Babae S, Vahdati SA, Tabeshfar Sh. Effectiveness of a nasoseptal cartilaginous graft for repairing traumatic fractures of the inferior orbital wall. *Br J Oral Maxillofac Surg* 2009;47:10-3.
23. Rodriguez ED, Bluebond-Langner R, Park JE, Manson PN. Preservation of contour in periorbital and midfacial craniofacial microsurgery: Reconstruction of the soft-tissue elements and skeletal buttresses. *Plast Reconstr Surg* 2008;121:1738-47.
24. Zhang Y, He Y, Zhang ZY, An JG. Evaluation of the application of computer-aided shape-adapted fabricated titanium mesh for mirroring-reconstructing orbital walls in cases of late post-traumatic enophthalmos. *J Oral Maxillofac Surg* 2010;68:2070-5.