

Leukemoid reaction with severe thrombocytopenia in a dying patient: a case report and literature review

Journal of International Medical Research

49(1) 1–7

© The Author(s) 2021

Article reuse guidelines:

sagepub.com/journals-permissions

DOI: 10.1177/0300060520974257

journals.sagepub.com/home/imr**Huang Hongwei** 

Abstract

Leukemoid reaction complicated by thrombocytopenia is rare, usually seen in patients with malignant conditions, and is often associated with poor prognosis. Here, the case of a 28-year-old healthy female without exceptional past medical history, who suffered from severe vaginal infection, is reported. Although symptoms improved, the white blood cell (WBC) count continued to increase up to 78 460 cells/ μl , however, the patient continued to improve and the outcome was good. The case revealed that an increasing WBC count may not change in synchrony with clinical symptoms. When faced with this scenario, procalcitonin measurements may play an important role in differentiating diagnosis and guiding treatment.

Keywords

Leukemoid reaction, thrombocytopenia, sepsis, procalcitonin, case report

Date received: 7 July 2020; accepted: 12 October 2020

Introduction

Leukemoid reaction, or extreme leukocytosis, is defined as a white blood cell count that exceeds 40–50 000 cells/ μl and is not caused by haematologic malignancies.¹ Various cut-offs have been described in the literature, such as 25 000 cells/ μl or 30 000 cells/ μl , but most studies abide by the cut-off criterion of 40 000 cells/ μl .^{2,3}

Leukemoid reaction is a relatively rare situation, mostly reported in patients with solid tumours. Other non-tumour causes

include infection, side-effect of corticosteroids or haematopoietic growth factors, severe haemorrhage, or bone metastases

Intensive Care Unit, The People's Hospital of Guangxi Zhuang Autonomous Region, Nanning, China

Corresponding author:

Huang Hongwei, Intensive Care Unit, The People's Hospital of Guangxi Zhuang Autonomous Region, 6 Taoyuan Road, Qingxiu District, Nanning, Guangxi Province, 530020 China.

Email: daffodils0622@163.com



Creative Commons Non Commercial CC BY-NC: This article is distributed under the terms of the Creative

Commons Attribution-NonCommercial 4.0 License (<https://creativecommons.org/licenses/by-nc/4.0/>) which permits non-commercial use, reproduction and distribution of the work without further permission provided the original work is attributed as specified on the SAGE and Open Access pages (<https://us.sagepub.com/en-us/nam/open-access-at-sage>).

with necrosis. Most leukemoid reactions are seen in senior patients and are associated with a poor prognosis.⁴ Leukemoid reaction in combination with severe thrombocytopenia (defined as a blood platelet count lower than $20 \times 10^9/l$) remains even more rare. Here, the case of a young woman who had severe clinical symptoms, leukemoid reaction and severe thrombocytopenia, and who progressed to a good outcome in the end, is presented.

Case report

Written informed consent was obtained from the patient's next of kin for publication of this case report and accompanying images. A copy of the written consent is available for review by the Editor-in-Chief of this journal on request.

A 28-year-old, otherwise healthy Chinese female with no past medical, drug, psychosocial or family history, was brought into the intensive care unit of The People's Hospital of Guangxi Zhuang Autonomous Region, Nanning, China, by ambulance on 15 October 2017. She had willingly, according to the patient, received water-sac induced labour on 11 October 2017, during her fourth month of pregnancy, and two days later she started to experience the following symptoms: hyperpyrexia, chills, and continuous vaginal bleeding. Although treated with antibiotics (2 g ceftazidime, every 8 h) she still progressed to shock with a blood pressure (BP) of only 70/30 mmHg. The local hospital proceeded with emergency surgery to eliminate the foetus and placenta. During surgery, the patient sustained a vaginal injury and gradually fell into a coma. In order to proceed with rescuing the patient, she was admitted to the surgical intensive care unit of the People's Hospital of Guangxi Zhuang Autonomous Region. Her clinical condition at that time was as follows: hypothermia, on ventilator-assisted ventilation, undetected BP, coma, vaginal

bleeding, spreading shin cyanosis and anuria. The patient's haemoglobin (Hb) was 7.0 g/dl, platelet count was $6 \times 10^9/l$, and leucocyte count was 22 360 cells/ μl (normal range, 3 600–10 000 cells/ μl), segmented neutrophils were 87.8%, lymphocytes 5.37%, monocytes 1.31%, and eosinophils 0.3%. International normalization ratio (INR) and activated partial thromboplastin time (APTT) were 1.99 and 51 s, respectively. Procalcitonin (PCT) was 50 ng/ml (normal range, 0.01–0.1 ng/ml), lactic acid was 8.4 mmol/l, HCO_3^- was 12.8 mmol/l and creatinine was 200 $\mu mol/l$.

After treatment with fluid resuscitation, transfusion (fresh frozen plasma, platelets and suspended erythrocytes), antibiotics (1.0 g meropenem, intravenous drip over 3 h, every 8 h), human immunoglobulin intravenous injection, ventilator-assisted ventilation, continuous venous–venous haemopurification and high dose vasopressor (3.0 $\mu g/kg/min$ noradrenaline), she showed no signs of improvement (coma, anuria, continuous vaginal bleeding, Hb level decreased to 3.4 g/dl, and lactic acid increased to 12.4 mmol/l). Therefore, an acute hysterectomy was performed on 16 October 2017, by a gynaecologist of the Department of Gynaecology, The People's Hospital of Guangxi Zhuang Autonomous Region. Following surgery, the patient started to show signs of improvement: bleeding gradually stopped, she regained consciousness, shin cyanosis alleviated, and cycling stability could be maintained (1.0 $\mu g/kg/min$ noradrenaline; BP, 110/60 mmHg; lactic acid, 4.1 mmol/l; and increasing trend in urine volume). However, the white blood cell (WBC) count ascended swiftly, up to 78 000 cells/ μl (Figure 1), and the platelet count remained very low, fluctuating between 3 and $28 \times 10^9/l$ (Figure 2), despite the patient receiving intermittent platelet infusion.

The patient received a differential diagnosis as follows: First, her condition was

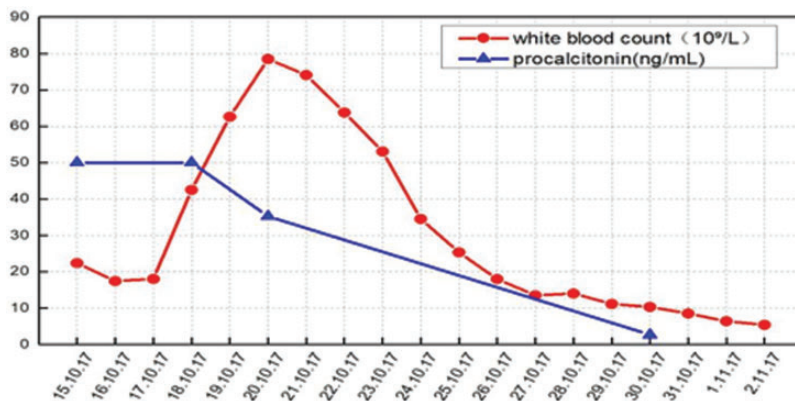


Figure 1. Changes in white blood cell count and procalcitonin levels over time (days).

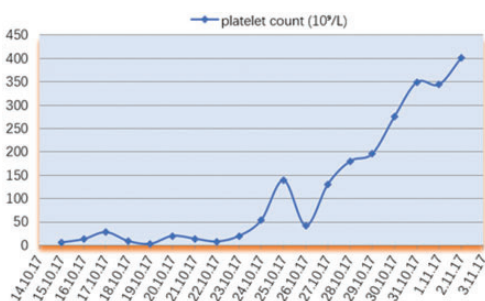


Figure 2. Changes in platelet count over time (days).

complicated with haematologic malignancies, such as granulocytic leukaemia. Second, she was still in severe infection.

Because the patient's clinical condition was improved (eating normally, no stomach ache, energised, had ceased vasopressor treatment, and lactic acid was staying within normal range) the patient and her family refused a bone marrow puncture and biopsy. So, a peripheral blood smear was performed, which showed prominent toxic particles and a lack of juvenile cells, and showed no evidence of schistocytes or spherocytes (Figure 3). The patient had no haemoglobinuria and the free haemoglobin level was normal. Meanwhile, the PCT level

was rechecked and found to still be at the highest level (50 ng/ml; Figure 1) whereas the C-reactive protein (CRP) level was low (50.5 mg/l). On the third day of hospital admission, the local hospital reported that the blood cluster (previously drawn by the local hospital) manifested *Escherichia coli*, whilst all tests investigating the presence of pathogen conducted at The People's Hospital of Guangxi Zhuang Autonomous Region were negative. Considering all the factors mentioned above, the conclusion was drawn that elevated WBCs were due to a leukemoid reaction, therefore treatment with 1.0 g meropenem (intravenous drip over 3 h, every 8 h) was continued.

Another encountered dilemma was the continuous severe thrombocytopenia, which fluctuated between low platelet counts despite intermittent platelet infusion (Figure 2). The following four hypotheses were presented, and were tested one-by-one: first, the existence of antiplatelet antibodies contributed to the low platelet levels despite valid platelet infusion. The result of a test for antiplatelet antibodies disproved this hypothesis. Secondly, thrombocytopenia was caused by decreasing pseudo-platelets, which accounts for 15% of thrombocytopenia in clinical settings. In order to exclude this hypothesis, the clinical

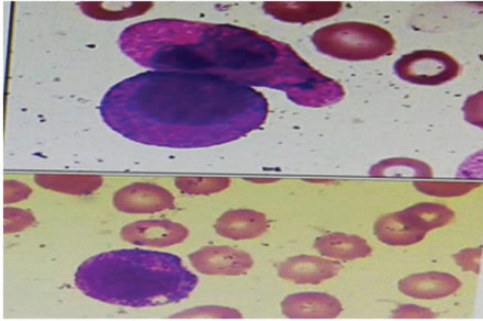


Figure 3. Representative peripheral blood smear. Myeloblasts and promyelocytes could not be detected; myelocytes, metamyelocytes, band neutrophils and segmented neutrophils accounted for 2%, 6%, 11% and 74%, respectively; a large number of white blood cells, neutrophilic metamyelocytes and in some granulocytes, toxic granules and vacuolar degeneration, could be observed; nucleated erythrocytes, erythrocytes of varying size, and dysmorphic erythrocytes could be seen; and a small quantity of scattered platelets could be seen.

laboratory was asked to check the platelet count in a different machine and the blood sample was sent to the Affiliated Hospital of Guangxi Medical University, Nanning, China. The laboratory test confirmed that the platelet count was very low, thus, the second hypothesis was rejected. Thirdly, the influence of anticoagulation was considered. The patient was transferred to the clinical laboratory where blood was drawn into a non-anticoagulation tube and tested within 1 minute following sample collection. The test result still showed severe thrombocytopenia. Fourthly, thrombocytopenia caused by acute bone marrow haematopoietic function stasis was considered. However, the manifestation of platelet particles rejected this hypothesis. Therefore, the final conclusion was drawn that the patient's severe thrombocytopenia was caused by sepsis, via a mechanism that is not well known, and although the sepsis had been controlled, the thrombocytopenia continued.

Since the patient's clinical condition improved, the same antibiotic regimen (meropenem) was continued, and platelet transfusion was stopped (due to lack of perceptible bleeding). On the fifth day of hospital admission, the PCT level decreased to 35.2 ng/ml. On the eighth day, the WBC count began to decline and on the ninth day, the platelets started to increase.

On 26 October 2017, although the platelet count was increasing ($145 \times 10^9/l$) and oral food intake was normal, the patient experienced upper gastrointestinal haemorrhage for 2 days. On 2 November 2017, she was discharged from the hospital. During a follow-up assessment on 2 February 2018, her blood cell count was as follows: WBC count was 4900 cells/ μl (segmented neutrophils 43.6%, lymphocytes 45.4%, monocytes 5.9%, and eosinophils 3.7%), platelet count was $269 \times 10^9/l$ and Hb was 114 g/l. The patient was followed-up after two years, and was found to be living a normal life, working as a nail technician.

Discussion

Leukemoid reaction was first defined around 70 years ago, however due to its rare incidence, investigating the pathogenesis of leukemoid reaction has remained difficult. Two retrospective studies have shown that most leukemoid reactions are caused by solid tumours,^{3,4} and the abnormal increase in WBC count may be caused by abnormal secretion by tumour cells.⁵ Other non-tumour causes include infection, a side-effect of corticosteroid treatment or haematopoietic growth factors, severe haemorrhage, and bone metastases with necrosis. In clinical settings, a common dilemma has been the differential diagnosis between tumour and infection. Conventional markers, such as CRP, have shown no statistical significance in previously published studies,^{6,7} but one study reported that looking for toxic particles in a peripheral blood

smear may be helpful in providing a differential diagnosis.³ The present author recommends PCT as a potential and more accurate marker of sepsis in critically ill patients. PCT is a 116-amino acid polypeptide precursor of calcitonin, produced by the C cells of the thyroid gland. Healthy individuals typically have serum PCT levels less than 0.05 ng/ml. In response to bacterial endotoxins or pro-inflammatory cytokines, such as interleukin (IL)-6 and tumour necrosis factor (TNF)- α , various cell types outside the thyroid gland produce PCT, resulting in up to a 1000-fold increase. Higher levels of PCT are associated with severe sepsis and declining PCT levels are associated with the resolution of infection. Previous studies have suggested that detecting serum PCT level may be superior to previously studied biomarkers for use in the diagnosis of sepsis, monitoring the sepsis course and severity, and guiding antimicrobial therapy.⁸⁻¹¹ As an important marker of infection, the elevation of WBCs is common in sepsis, but the count is usually lower than $40 \times 10^9/l$, and levels decrease as infection is brought under control. In the present patient, WBCs kept rising, even though her clinical symptoms improved (stabilizing haemoglobin, and withdrawal of mechanically-assisted ventilation and vasopressors), which the present author had never before observed during ten years of clinical practice. The patient rejected bone marrow aspiration, for reasons not currently understood, and there was a pressing need to be able to judge what should be done next. The assessment of PCT facilitated decision-making in this circumstance. When confronted with such a dilemma, the PCT level impacted the present differential diagnosis and guided treatment decisions, supporting the extensive use of antibiotic. At the same time, it seemed that the WBC increase did not change synchronously with the clinical symptoms. The patient's general health improved, while the

WBC count continued to increase. This may have been due to abnormal secretion of factors that induce a continuous impact on WBC generation, or WBC discharge from peripheral leucocyte cisterna, such as the spleen. The present case provides evidence that if clinical symptoms have improved and PCT levels have declined, although WBC count may have increased continuously, the clinician may still insist on initial antibiotic treatment.

Patients with a leukemoid reaction caused by bacteria are most commonly infected with the bacillus bacteria, typically seen in seniors with a tumour. Whereas in young females undergoing vaginal surgery, *Clostridium sordellii* is commonly found,¹² which usually causes necrotizing soft tissue infections and severe clinical symptoms, such as shock. The patient in the present case report underwent induced labour and gynaecological surgery, which was nearly fatal, but the bacteria causing her severe infection was determined to be *E. coli*. Vaginal infection complicated by leukemoid reaction is very rare. In two previously reported cases of vaginal infections complicated by leukemoid reaction,^{13,14} the WBC counts were 42 900 cells/ μl and 64 030 cells/ μl , respectively, and the associated pathogens were Gram positive and *C. sordellii*. Neither case report mentioned the platelet count. To the best of the present author's knowledge, this is the first case report regarding vaginal infection caused by *E. coli* complicated by a leukemoid reaction and severe thrombocytopenia.

Leukemoid reaction accompanied by severe thrombocytopenia is rare. Previous case reports have usually involved paediatric patients, such as children with Down's syndrome contracting a shigella infection, often erupting simultaneously with organ bleeding.^{15,16} Mild thrombocytopenia (platelet count $< 150 \times 10^9/l$) is common, with an incidence of approximately 14.5%, but

severe thrombocytopenia (platelet count $< 20 \times 10^9/l$) is rare.¹⁷ As an inflammation marker, thrombocytopenia is more common, especially in patients who have a mild-to-moderate infection. Although the pathogenesis of thrombocytopenia remains uncertain, immunological factors are widely accepted as the main contributor. In addition, severe thrombocytopenia, rather than thrombocytopenia, is commonly known to have a poor prognosis.^{18–20} Severe thrombocytopenia is associated with a high risk of organ bleeding. Normally, in patients who are not experiencing surgery, platelets higher than $20 \times 10^9/l$ without a tendency of bleeding is permissible, whilst in the department of surgery, a platelet count higher than $50 \times 10^9/l$ is required in order to avoid vital organ bleeding. Oddly, the present patient did not suffer organ bleeding during the period of severe thrombocytopenia, whereas upper gastrointestinal haemorrhage occurred when the platelet count was up to $145 \times 10^9/l$, with normal coagulation function and normal food intake. This phenomenon is difficult to explain, and perhaps only occurs occasionally. In the People's Hospital of Guangxi Zhuang Autonomous Region department of intensive care, platelets are usually not infused due to a shortage of platelet supply, even when a patient's platelet counts fall below $50 \times 10^9/l$, and most patients do not experience concurrent organ bleeding.

A leukemoid reaction usually means poor prognosis, with a previously reported mortality rate of 78%, median survival of 12 weeks, and one-year survival rate of 10%.⁴ However, due to an effective diagnosis and treatment, the present patient had a satisfying outcome. Two years of follow-up showed no sequelae. Following discharge from hospital, her complete blood count was checked three times, and the WBC and platelet counts were within a normal

range, excluding the possibility of leucocytopenia. The present case report has shown that the WBC count in patients with a leukemoid reaction can increase up to $80 \times 10^9/l$, and the increased WBC may still persist even after improvement of the clinical condition, therefore, it may be unnecessary to intensify antibiotic treatment. PCT is highly related to infection, particularly in Gram-negative bacterial infections. Thus, the present author suggests that if the PCT level begins to decrease, even if accompanied by an increased WBC count, clinicians may still continue the initial treatment. On the other hand, accompanying leucocytopenia during several days is rarely seen, and because patients with severe thrombocytopenia may have a tendency to bleed, they might not consent to a bone marrow puncture.

Conclusion

The present case report included a few diagnostic shortcomings: the case lacked bone marrow puncture and biopsy in order to exclude a haematological malignancy, and failed to test the levels of TNF- α and IL-8, which may have confirmed the pathogenesis. The author concludes that in patients who improve clinically, whilst facing rising WBC count and severe thrombocytopenia, which might not be a response to anti-infection, PCT may play an important role in differentiating diagnosis and guiding treatment.

Declaration of conflicting interest

The author declares that there is no conflict of interest.

Funding

This research received no specific grant from any funding agency in the public, commercial, or not-for-profit sectors.

ORCID iD

Huang Hongwei  <https://orcid.org/0000-0001-8697-1913>

References

1. McKee LC Jr. Excess leukocytosis (leukemoid reactions) associated with malignant diseases. *South Med J* 1985; 78: 1475–1482.
2. Reding MT, Hibbs JR, Morrison VA, et al. Diagnosis and outcome of 100 consecutive patients with extreme granulocytic leukocytosis. *Am J Med* 1998; 104: 12–16.
3. Karakonstantis S, Koulouridi M, Pitsillos K, et al. A prospective study of hospitalized patients with leukemoid reaction; causes, prognosis and value of manual peripheral smear review. *Rom J Intern Med* 2019; 57: 241–247.
4. Granger JM and Kontoyiannis DP. Etiology and outcome of extreme leukocytosis in 758 nonhematologic cancer patients: a retrospective, single-institution study. *Cancer* 2009; 115: 3919–3923.
5. Astrom M, Tajeddinn W, Karlsson MG, et al. Cytokine measurements for diagnosing and characterizing leukemoid reactions and immunohistochemical validation of a granulocyte colony-stimulating factor and CXCL8-producing renal cell carcinoma. *Biomark Insights* 2018; 13: 1177271918792246.
6. Rajkumari N, Mathur P, Sharma S, et al. Procalcitonin as a predictor of sepsis and outcome in severe trauma patients: a prospective study. *J Lab Physicians* 2013; 5: 100–108.
7. Castelli GP, Pognani C, Cita M, et al. Procalcitonin, C-reactive protein, white blood cells and SOFA score in ICU: diagnosis and monitoring of sepsis. *Minerva Anesthesiol* 2006; 72: 69–80.
8. Bouadma L, Luyt CE, Tubach F, et al. Use of procalcitonin to reduce patients' exposure to antibiotics in intensive care units (PRORATA trial): a multicentre randomised controlled trial. *Lancet* 2010; 375: 463–474.
9. Wolff M and Bouadma L. What procalcitonin brings to management of sepsis in the ICU. *Crit Care* 2010; 14: 1007.
10. Nobre V, Harbarth S, Graf JD, et al. Use of procalcitonin to shorten antibiotic treatment duration in septic patients: a randomized trial. *Am J Respir Crit Care Med* 2008; 177: 498–505.
11. Schroeder S, Hochreiter M, Koehler T, et al. Procalcitonin (PCT)-guided algorithm reduces length of antibiotic treatment in surgical intensive care patients with severe sepsis: results of a prospective randomized study. *Langenbecks Arch Surg* 2009; 394: 221–226.
12. Elkbuli A, Diaz B, Ehrhardt JD Jr, et al. Survival from Clostridium toxic shock syndrome: Case report and review of the literature. *Int J Surg Case Rep* 2018; 50: 64–67.
13. Agrawal P and Garg R. Fulminant leukemoid reaction due to postpartum Clostridium sor-dellii infection. *J Glob Infect Dis* 2012; 4: 209–211.
14. Soper DE, Lee SI, Kim JY, et al. Case records of the Massachusetts General Hospital. Case 35-2011: a 33-year-old woman with postpartum leukocytosis and Gram-positive bacteremia. *N Engl J Med* 2011; 365: 1916–1924.
15. Hasegawa D. Myeloid proliferations related to Down syndrome. *Rinsho Ketsueki* 2019; 60: 1299–1307 [In Japanese, English abstract].
16. Isik DU, Aydemir O, Kale Y, et al. Severe leukemoid reaction in a preterm infant with congenital cytomegalovirus infection. *J Pediatr Hematol Oncol* 2014; 36: e310–e312.
17. Martin CM, Priestap F, Fisher H, et al. A prospective, observational registry of patients with severe sepsis: the Canadian Sepsis Treatment and Response Registry. *Crit Care Med* 2009; 37: 81–88.
18. Azkarate I, Choperena G, Salas E, et al. Epidemiology and prognostic factors in severe sepsis/septic shock. Evolution over six years. *Med Intensiva* 2016; 40: 18–25.
19. Sharma B, Sharma M, Majumder M, et al. Thrombocytopenia in septic shock patients—a prospective observational study of incidence, risk factors and correlation with clinical outcome. *Anaesth Intensive Care* 2007; 35: 874–880.
20. Horino T, Chiba A, Kawano S, et al. Clinical characteristics and risk factors for mortality in patients with bacteremia caused by Pseudomonas aeruginosa. *Intern Med* 2012; 51: 59–64.