

Ultrasound-Guided Superior Cluneal Nerve Block: A Narrative Review

Xiaohui Luo, Yan Zhao

Department of Anesthesiology, The First Affiliated Hospital, Zhejiang University School of Medicine, Hangzhou, People's Republic of China

Correspondence: Yan Zhao, Department of Anesthesiology, The First Affiliated Hospital, Zhejiang University School of Medicine, Hangzhou, 310000, People's Republic of China, Tel +86 18346350883, Email 1152637095@qq.com

Abstract: Low back pain (LBP) is common and has a complex etiology. Superior cluneal nerve (SCN) entrapment has come to the attention of pain physicians as a cause of LBP. SCN block is the mainstay of treatment for LBP due to SCN entrapment. The aim of this narrative review is to summarize the approaches and techniques for ultrasound-guided SCN block. Meanwhile, the evidence for the clinical use of SCN block is reviewed, based on relevant and recent literature. The authors expect this article to provide a reference point for the diagnosis and treatment of LBP.

Keywords: superior cluneal nerve, ultrasound, low back pain

Introduction

Low back pain (LBP) is a disease named after a symptom. In clinical practice, symptoms such as pain and discomfort in the lower back are collectively referred to as LBP. In China, the annual prevalence of LBP is 20.88% - 29.88%, and the lifetime prevalence is 40% - 70%.¹ A variety of diseases have resulted in LBP, including but not limited to spinal diseases, neurological diseases, urological diseases, and gynaecological diseases.

One cause of LBP is the compression of the superior cluneal nerve (SCN). In 1957, Strong et al introduced the concept of "cluneal nerve compression syndrome" and utilized nerve blockage as a treatment for pain resulting from the compression of cluneal nerves.² Nevertheless, the efficacy of nerve blockage through blind probing for anatomical landmarks and paresthesia remains uncertain. Over the past few decades, extensive research on the etiology and treatment of cluneal nerve compression syndrome has stimulated the advancement of cluneal nerve block under the guidance of ultrasound.

A literature search was performed using PubMed, Embase, and Web of Science without any language and time restriction. The terms "superior cluneal nerve", "ultrasound", "low back pain" were used to search. Randomized controlled trials, case reports, retrospective studies were included. We performed a correlation analysis of the articles and summarized the data.

The objective of this narrative review was to comprehensively review the relevant anatomy, mechanisms, approaches, and techniques associated with the SCN block, as well as to summarize the clinical evidence supporting its application.

Anatomy

The spinal nerve divides into anterior and posterior branches after exiting the intervertebral foramen. The posterior branches are located on the outer side of the facet joints and travel posteriorly between adjacent transverse processes. Most posterior branches except C1 and S4-S5 further divide into medial and lateral branches to innervate the corresponding muscles and skin.

The SCN is typically composed of the lateral branches of the posterior branches of T11-L4,^{3,4} (Figure 1). They traverse through the multifidus, erector spinae, anterior layer of the thoracolumbar fascia, quadratus lumborum, middle layer of the thoracolumbar fascia, and latissimus dorsi at the level of the third and fourth lumbar spinous processes. Subsequently, they

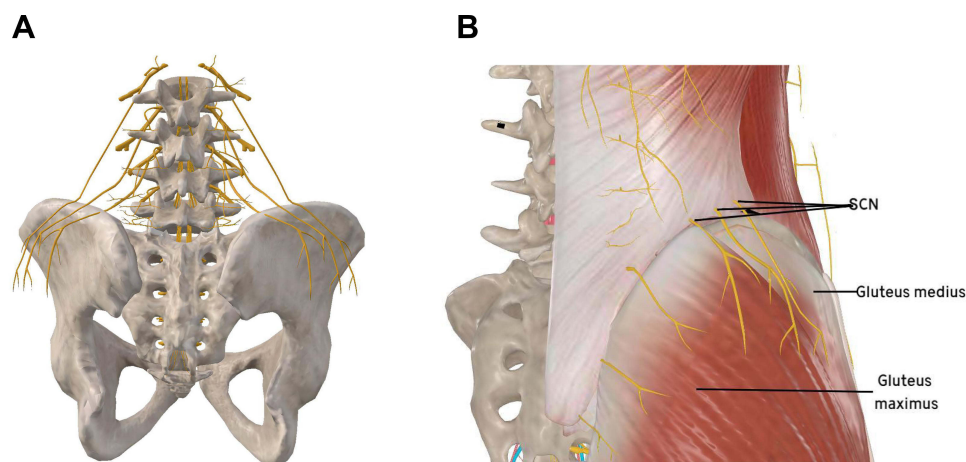


Figure 1 (A) Schematic diagram of SCN origin and anatomy. The figure is a modified excerpt from 3Dbody, with permission from 3Dbody (Shanghai) Digital Technology Co., Ltd (www.3Dbody.com). (B) Distribution and alignment of SCN. The figure is a modified excerpt from 3Dbody, with permission from 3Dbody (Shanghai) Digital Technology Co., Ltd (www.3Dbody.com).

pass through the osseofibrous tunnel attached to the superior border of the iliac crest and enter the subcutaneous tissue of the buttocks, providing innervation to the upper part of the gluteus maximus and gluteus medius muscles' skin.⁵

SCN can be classified into the medial, middle, and lateral branches. According to Twanaga et al, the diameter of the medial branch of the SCN ranged from 0.7 mm to 2.69 mm, the diameter of the middle branch ranged from 0.45 mm to 3.36 mm, and the diameter of the lateral branch ranged from 0.59 mm to 2.96 mm based on their examination of 10 cadaver specimens.⁶ The medial branch descends after traversing the iliac crest, which corresponds to the upper branch of the middle cluneal nerve.⁵ Among the three branches, the lateral branch is the longest and closest to the surface, extending to the level of the greater trochanter of the femur.⁵ The linear distance between the points where the SCN medial branch, middle branch, and lateral branch intersect with the iliac crest and the crest itself is 5.8 mm, 2.2 mm, and 12 mm, respectively.⁷ In a cadaver study by Kuniya et al, the average lengths of the medial branch, middle branch, and lateral branch within the bony fibrous canal were found to be 6.8 mm, 5.8 mm, and 6.4 mm, respectively. Additionally, the average distances to the superior iliac spine were 45 mm, 51 mm, and 56 mm, respectively, while the average distances to the midline posteriorly were 71 mm, 76 mm, and 82 mm, respectively.⁸

Approaches and Techniques of Ultrasound-Guided Injection

Four major approaches of ultrasound-guided SCN block will be described and compared here.

Position

When performing an SCN block, the selection of a lateral or prone position is generally necessary, taking into consideration the patient's mobility, needle insertion site, and puncture path.

Approaches

In the study by Bonder et al, to locate the SCN, a high-frequency linear array probe is typically placed transversely at the level of the posterior superior iliac spine and gradually advanced in the cephalad direction until the gluteus maximus disappears and the gluteus medius and iliac wing become visible. An echogenic oval-shaped structure with high reflectivity, representing the medial branch of the SCN, can be observed between the iliac crest and thoracolumbar fascia on the ultrasound image,⁹ (Figure 2). Meanwhile, the study conducted by Bonder et al demonstrated the effectiveness of local anesthetic injection at the superior aspect of the iliac crest, prior to its crossing the thoracolumbar fascia, in blocking the medial branch of the SCN.⁹

After identifying the nerve, as the probe is slid upwards until the SCN reaches the level of the erector spinae, the nerve pathway becomes steeper, presenting a wave-like pattern that is more challenging to differentiate in the short-axis

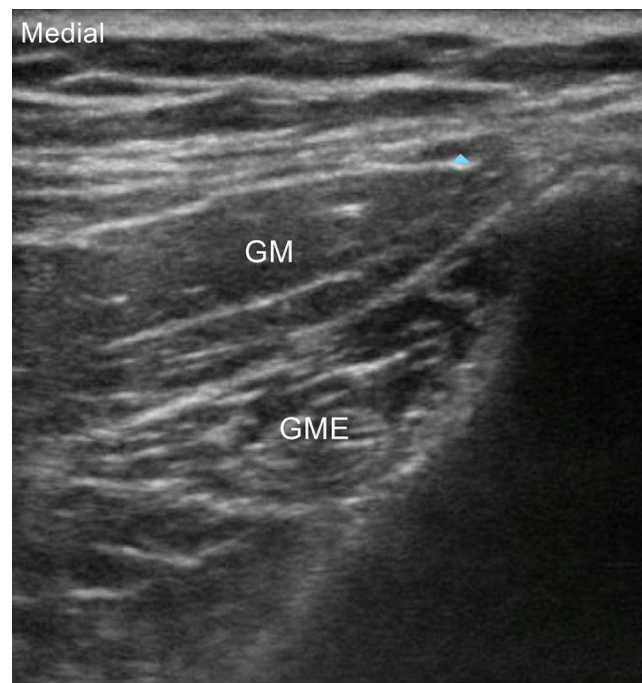

Figure 2 The short-axis views of the medial branch of the SCN. Blue arrow denotes medial branch of the SCN.
Abbreviations: GM, gluteus maximus; GME, gluteus medius.

view. Therefore, Chang et al recommended that once the SCN is identified, the probe is repositioned longitudinally and moved along the long axis to observe the course of the nerve,¹⁰ (Figure 3).

In a recent study by Nielsen et al, an ultrasound-guided SCN block was proposed at the lateral margin of the erector spinae muscle above the iliac crest, adjacent to the third lumbar vertebra, the researchers conducted both cadaveric dissection and randomized clinical trials, which demonstrated the comprehensive blockage of all branches of the SCN using this approach,¹¹ (Figure 4).

Fan et al speculated that direct injection of local anesthetic above the lateral aspect of the posterior superior iliac spine near the iliac crest, could effectively block the SCN without the requirement for nerve identification. During imaging, the ultrasound probe was positioned transversely at the midline of the sacrum, gradually moved towards the head until the spinous process of the fifth lumbar vertebra became visible, and then adjusted to the positions of the transverse process of the fifth lumbar vertebra, the iliac crest, the erector spinae muscle, and the gluteus maximus. Using the in-plane technique, the local anesthetic was then injected at the superior margin of the iliac crest, enabling diffusion along the crest's edge and resulting in a broad SCN block.¹²

Suggestions

According to clinical reports, it is reasonable to conclude that each of techniques has a definite effect. When it comes time to carefully identify the SCN, the technique by Bonder et al is more appropriate. But the longitudinal axis plane technique for SCN blockade by Chang et al is easier to use and visualize the nerve along the thoracolumbar fascia.¹³ To ensure the comprehensive blockage of all branches of the SCN, both the study by Nielsen et al and the research by Fan et al can be selected. As distinguishing the SCN from surrounding tissues in elderly and obese patients can be difficult, the technique for SCN blockade by Fan et al is more commonly used.

Local Anesthetic and Adjuvants

Opioid analgesics, dexmedetomidine, and corticosteroids are frequently utilized as adjuvants in the administration of regional nerve blocks. Nevertheless, there is a dearth of research on the concurrent use of these adjuvants with local anesthetics for SCN block. Merely a small number of case studies have uncovered that combining single or repeated

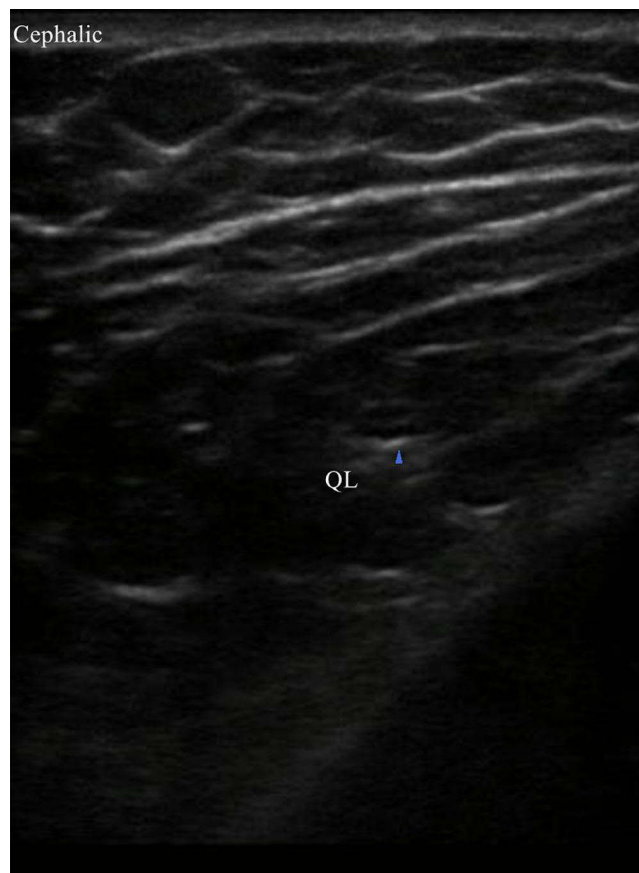


Figure 3 The long-axis views of the middle branch of the SCN. Blue arrow denotes medial branch of the SCN.
Abbreviation: QL, quadratus lumborum muscle.

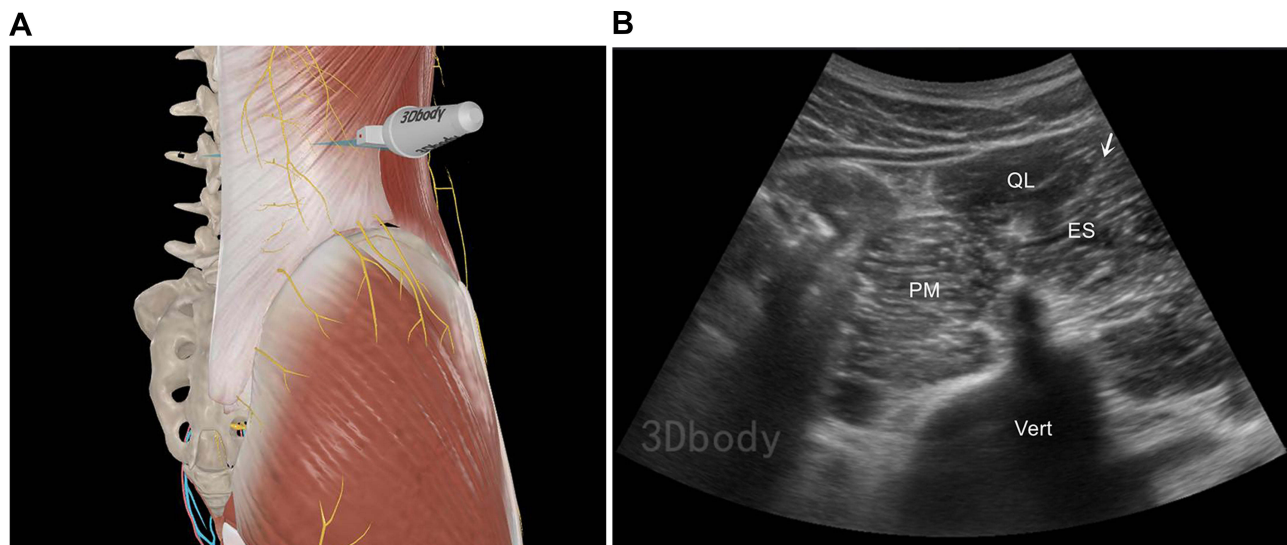


Figure 4 (A) Scanning position. The figure is a modified excerpt from 3Dbody, with permission from 3Dbody (Shanghai) Digital Technology Co., Ltd (www.3Dbody.com). (B) SCN block technique at the lateral margin of the erector spinae muscle. The figure is a modified excerpt from 3Dbody, with permission from 3Dbody (Shanghai) Digital Technology Co., Ltd (www.3Dbody.com). White arrow denotes injection site.
Abbreviations: QL, quadratus lumborum muscle; ES, erector spinae muscle; PM, psoas major muscle; Vert, vertebra of L3.

injections of local anesthetics with corticosteroids enhances the outcomes of SCN block.^{14,15} However, there is also evidence indicating that the utilization of corticosteroids around the nerves heightens the risk of sensory abnormalities and complications linked to nerves.¹⁶

The current evidence regarding the concentration, dosage, and various adjuvants of local anesthetics in SCN block is limited. Hence, practitioners must consider the available evidence and adjust the dosage of the local anesthetic during the implementation of the SCN block to prevent exceeding the toxic threshold. Additionally, obtaining more clinical data to substantiate the use of specific adjuvants is desirable. Future research is expected to standardize the application of local anesthetics and adjuvants in SCN block. Epinephrine can decrease the absorption rate of drugs in blood vessels. Irrespective of the addition of epinephrine, it is important to perform aspiration prior to injection and administer the drugs slowly and in fractional doses, with simultaneous monitoring for any signs of toxicity in the patient. Table 1 summarizes selected studies on the dosage and effects of local anesthetics in SCN block.

Indications and Clinical Relevance

Diagnosis and Treatment of LBP

Functional disorders of the SCN can result from various causes, including SCN compression or damage due to iliac bone transplantation. These disorders can manifest as pain in the lower back, buttocks, or legs.^{20,21} Additionally, conditions such as lumbar disc herniation, lumbar canal stenosis, and piriformis syndrome may contribute to lower back or leg pain. When the nature of the pain caused by SCN dysfunction cannot be distinguished from other diagnoses, a 2mL injection of 1% lidocaine can be administered around the SCN. If the patient experiences pain relief exceeding 75% within 2 hours following the injection, a diagnosis of SCN dysfunction can be confirmed.^{18,19} Notably, a case series study by Kuniya et al

Table 1 Studies on the Dosage and Effects of Local Anesthetics in SCN Block

| Articles | Article Type | Number of Patients | Objectives | Local Anesthetic | Outcomes |
|-----------------------------|------------------|-------------------------------|--|---------------------------------------|--|
| Mahli et al ¹⁷ | Case Series | 4 | Treatment for pain of SCN entrapment | 3 mL of 0.5% lidocaine | 100% pain reduction within 2 hours |
| Bodner et al ⁹ | Case Series | 9 | To determine whether visualization and assessment of the SCN with high-resolution ultrasound is feasible. | 1 mL of 2% lidocaine | All patients showed numbness and blockade within the presumed SCN territory |
| Chang et al ¹³ | Case Report | 1 | Treatment for pain of SCN entrapment | 4 mL of 5% dextrose plus 1% lidocaine | 80% pain relief 2 weeks after the second injection |
| Kokubo et al ¹⁸ | Case Series | 17 | Diagnostic treatment | 2 mL of 1% lidocaine | 75% pain reduction within 2 hours |
| Iwamoto et al ¹⁹ | Case Series | 8 | Diagnosis | 2 mL of 1% lidocaine | 75% pain reduction within 2 hours |
| Nielsen et al ¹¹ | Randomized Trial | Study 2:20 healthy volunteers | To describe a novel ultrasound-guided SCN block technique and to map the area of cutaneous anesthesia and its coverage of the hip surgery incisions. | Study 2:15 mL of 0.375% ropivacaine | Study 2:Successful anesthesia after the SCN block was achieved in 18 of 20 active sides (90%). |
| Fan et al ¹² | Case Report | 1 | To validate a new approach of SCN block | 15 mL of 0.5% ropivacaine | The acupuncture pain in the cutaneous region alleviated or disappeared |

demonstrated that repeated SCN blocks led to a 20 mm reduction in the visual analog scale (VAS) scores of 85% of patients suffering from SCN compression.²²

Postoperative Analgesia After Hip Surgery

The innervation of the skin in the hip joint region is intricate. Although the combined transversus abdominis plane block and lateral femoral cutaneous nerve block may encompass most incisions in hip procedures,²³ the commonly employed posterior and lateral approaches in hip arthroplasty often result in incomplete blockade of the incision and inadequate pain relief.²⁴ Nielsen et al conducted SCN blocks on 20 volunteers and illustrated the relationship between the anesthetic coverage of the skin and the areas affected by the transversus abdominis plane block, subcostal nerve block, and lateral femoral cutaneous nerve block.¹¹ The findings revealed a contiguous correlation between the regions innervated by the SCN and those innervated by the transversus abdominis plane block, intercostal nerves, and lateral femoral cutaneous nerve. This discovery implies that SCN block can expand the extent of anesthesia for surgical incisions in hip arthroplasty, thereby offering a novel avenue for postoperative pain management. However, further clinical research is warranted to substantiate its efficacy and feasibility.

Contraindications

Empirical contraindications for SCN block encompass various circumstances, including but not limited to injury or infection at the puncture site, pre-existing nerve damage, severe underlying medical conditions, systemic infection, diminished blood volume, coagulation disorders, and patient non-compliance or refusal to undergo nerve blockade.

Complications

Local Anesthetic-Related Complications

The risk of injecting local anesthetics into blood vessels during the process of SCN block is highly unlikely. Currently, no complications related to SCN block have been reported, however, it is essential to remain vigilant towards allergic and toxic reactions caused by local anesthetics. Individuals with a predisposition to allergies or with a history of local anesthetic allergies should exercise caution. Amide-type local anesthetics have a lower occurrence of allergic reactions compared to ester-type local anesthetics. It is crucial to administer a safe dosage of local anesthetics during the blockade procedure and monitor for potential prodromal symptoms of toxicity.

Needle Trauma

During the process of blockade, repeated punctures or inadvertent injection of local anesthetics into the nerve can lead to temporary or permanent nerve damage. Moreover, if the puncture needle penetrates a blood vessel, it can result in concomitant vascular injury. To mitigate the complications arising from needle puncture, a comprehensive comprehension of the anatomical structure and precise positioning should be acquired prior to the puncture. Multiple aspiration techniques should be employed before administering medication, ensuring the secure fixation of the puncture needle.

Limitations

In the first place, like other narrative reviews, this article included material was subject to selection and evaluation bias. Besides, although SCN block has shown positive outcomes in improving related pain, there are limited reports on ultrasound-guided SCN block. This paper is not a systematic review, thus it might not include all the available evidence. Many of the available evidence is case series and case reports. More randomized control studies are warranted in the future to validate these techniques.

Conclusions

A comprehensive understanding of the pertinent anatomy and techniques of SCN block is imperative for its efficient and safe implementation. Presently, the optimal injection dosage and diffusion range of local anesthetics concerning various SCN block approaches lack precise definition. Therefore, mastering the operational techniques with ultrasound guidance holds utmost importance in determining the distribution of local anesthetics, evaluating proper drug dosage, and

enhancing the efficacy and safety of the blockade. The indications for SCN block are primarily derived from a limited number of clinical randomized controlled trials and case reports, which offer restricted evidence. Future research endeavors should actively explore the utilization of ultrasound imaging and ultrasound-guided SCN block in disease management. Moreover, studies should incorporate outcome measures such as cost analysis and hospitalization duration to further enhance our understanding of this intervention.

Disclosure

The authors report no conflicts of interest in this work.

References

1. Gu R, Wang Y, Chen B. 中国非特异性腰痛临床诊疗指南 [Clinical guidelines for nonspecific low back pain in China]. *Chinese J Spine Spinal Cord*. 2022;32(03):258–268. Chinese.
2. Strong EK, Davila JC. The cluneal nerve syndrome; a distinct type of low back pain. *Ind Med Surg*. 1957;26(9):417–429.
3. Maigne JY, Lazareth JP, Guerin SH, Maigne R. The lateral cutaneous branches of the dorsal rami of the thoraco-lumbar junction. An anatomical study on 37 dissections. *Surg Radiol Anat*. 1989;11(4):289–293. doi:10.1007/BF02098698
4. Maigne JY, Maigne R. Trigger point of the posterior iliac crest: painful iliolumbar ligament insertion or cutaneous dorsal ramus pain? An anatomic study. *Arch Phys Med Rehabil*. 1991;72(10):734–737.
5. Tubbs RS, Levin MR, Loukas M, Potts EA, Cohen-Gadol AA. Anatomy and landmarks for the superior and middle cluneal nerves: application to posterior iliac crest harvest and entrapment syndromes. *J Neurosurg Spine*. 2010;13(3):356–359. doi:10.3171/2010.3.SPINE09747
6. Iwanaga J, Simonds E, Schumacher M, Oskouian RJ, Tubbs RS. Anatomical study of superior cluneal nerves: revisiting the contribution of the lumbar spinal nerves. *World Neurosurg*. 2019;128:e12–e15. doi:10.1016/j.wneu.2019.02.159
7. Lu J, Ebraheim NA, Huntoon M, Heck BE, Yeasting RA. anatomic considerations of superior cluneal nerve at posterior iliac crest region. *Clin Orthop Relat Res*. 1998;(347):224–228.
8. Kuniya H, Aota Y, Saito T, et al. Anatomical study of superior cluneal nerve entrapment. *J Neurosurg Spine*. 2013;19(1):76–80. doi:10.3171/2013.4.SPINE12683
9. Bodner G, Platzgummer H, Meng S, Brugger PC, Gruber GM, Lieba-Samal D. Successful identification and assessment of the superior cluneal nerves with high-resolution sonography. *Pain Physician*. 2016;19(3):197–202.
10. Chang KV, Wu WT. Is it possible to exactly visualize the superior cluneal nerve using ultrasound imaging? *Reg Anesth Pain Med*. 2019;rapm-2019-100731. doi:10.1136/rapm-2019-100731
11. Nielsen TD, Moriggl B, Barckman J, et al. Randomized trial of ultrasound-guided superior J cluneal nerve block. *Reg Anesth Pain Med Epub*. 2019;44(8):772–780. doi:10.1136/rapm-2018-100174
12. Fan K, Cheng C, Gong WY. A simple and novel ultrasound-guided approach for superior cluneal nerves block. *Anaesth Crit Care Pain Med*. 2021;40(2):100838. doi:10.1016/j.accpm.2021.100838
13. Chang KV, Hsu SH, Wu WT, Ozcakar L. Ultrasonographic Technique for Imaging and Injecting the Superior Cluneal Nerve. *Am J Phys Med Rehabil*. 2017;96(6):e117–e118. doi:10.1097/PHM.0000000000000642
14. Talu GK, Ozyalcin S, Talu U. Superior cluneal nerve entrapment. *Reg Anesth Pain Med*. 2000;25(6):648–650. doi:10.1053/rapm.2000.18189
15. Aly TA, Tanaka Y, Aizawa T, Ozawa H, Kokubun S. Medial superior cluneal nerve entrapment neuropathy in teenagers: a report of two cases. *Tohoku J Exp Med*. 2002;197(4):229–231. doi:10.1620/tjem.197.229
16. Gagne OJ, Cheema A, Abuhantash M, et al. Effect of dexamethasone in peripheral nerve blocks on recovery of nerve function. *Foot Ankle Int*. 2021;42(1):23–30. doi:10.1177/1071100720952075
17. Mahli A, Coskun D, Altun NS, Simsek A, Ocal E, Kostekci M. Alcohol neurolysis for persistent pain caused by superior cluneal nerves injury after iliac crest bone graft harvesting in orthopedic surgery: report of four cases and review of the literature. *Spine*. 2002;27(22):E478–E481. doi:10.1097/00007632-200211150-00018
18. Kokubo R, Kim K, Isu T, et al. Superior cluneal nerve entrapment neuropathy and gluteus medius muscle pain: their effect on very old patients with low back pain. *World Neurosurg*. 2017;98:132–139. doi:10.1016/j.wneu.2016.10.096
19. Iwamoto N, Isu T, Kim K, et al. Treatment of low back pain elicited by superior cluneal nerve entrapment neuropathy after lumbar fusion surgery. *Spine Surg Relat Res*. 2017;1(3):152–157. doi:10.22603/ssr.1.2016-0027
20. Konno T, Aota Y, Kuniya H, et al. Anatomical etiology of “pseudo-sciatica” from superior cluneal nerve entrapment: a laboratory investigation. *J Pain Res*. 2017;10:2539–2545. doi:10.2147/JPR.S142115
21. Isu T, Kim K, Morimoto D, Iwamoto N. Superior and middle cluneal nerve entrapment as a cause of low back pain. *Neurospine*. 2018;15(1):25–32. doi:10.14245/ns.1836024.012
22. Kuniya H, Aota Y, Kawai T, Kaneko K, Konno T, Saito T. Prospective study of superior cluneal nerve disorder as a potential cause of low back pain and leg symptoms. *J Orthop Surg Res*. 2014;9(1):139. doi:10.1186/s13018-014-0139-7
23. Nielsen TD, Moriggl B, Barckman J, et al. Cutaneous anaesthesia of hip surgery incisions with iliohypogastric and subcostal nerve blockade: a randomised trial. *Acta Anaesthesiol Scand*. 2019;63(1):101–110. doi:10.1111/aas.13221
24. Chechik O, Khashan M, Lador R, Salai M, Amar E. Surgical approach and prosthesis fixation in hip arthroplasty world wide. *Arch Orthop Trauma Surg*. 2013;133(11):1595–1600. doi:10.1007/s00402-013-1828-0

Journal of Pain Research

Dovepress

Publish your work in this journal

The Journal of Pain Research is an international, peer reviewed, open access, online journal that welcomes laboratory and clinical findings in the fields of pain research and the prevention and management of pain. Original research, reviews, symposium reports, hypothesis formation and commentaries are all considered for publication. The manuscript management system is completely online and includes a very quick and fair peer-review system, which is all easy to use. Visit <http://www.dovepress.com/testimonials.php> to read real quotes from published authors.

Submit your manuscript here: <https://www.dovepress.com/journal-of-pain-research-journal>