

# Dye-based chromoendoscopy following polypectomy reduces incomplete polyp resection



## Authors

Neil R. O'Morain<sup>1,2</sup>, Mohd I. Syafiq<sup>1,2</sup>, Ammar Shahin<sup>1</sup>, Barbara Ryan<sup>1,2</sup>, Stephen Crowther<sup>3</sup>, Deirdre McNamara<sup>1,2</sup>

## Institutions

- 1 Department of Gastroenterology and Clinical Medicine, Tallaght University Hospital, Trinity College Dublin
- 2 Trinity Academic Gastroenterology Group, Tallaght University Hospital, Trinity College Dublin
- 3 Department of Histopathology, Tallaght University Hospital, Trinity College Dublin, Ireland

submitted 3.10.2018

accepted after revision 29.7.2019

## Bibliography

DOI <https://doi.org/10.1055/a-1024-3759> |

Endoscopy International Open 2020; 08: E13–E19

© Georg Thieme Verlag KG Stuttgart · New York

eISSN 2196-9736

## Corresponding author

Dr. Neil O'Morain, Department of Gastroenterology & Clinical Medicine, Tallaght University Hospital, Dublin 24, Ireland

Fax: +353-1-4144114

neilmoran@gmail.com

## ABSTRACT

**Background and study aims** The completeness of a polyp resection is an important determinant of quality in colonoscopy, and may reduce incidence of interval cancers. Incomplete resection rates (IRR) vary widely and range from 6.5%

to 22.7%. Residual disease is more likely with larger polyps, for sessile serrated adenomas, and with more proximal lesions. Chromoendoscopy is increasingly employed in lesion detection. The aims of this study were to assess local IRR, and to determine whether chromoendoscopy could correctly identify residual disease post polypectomy.

**Patients and methods** This was a prospective study examining post polypectomy sites. Chromoendoscopy (0.13% indigo carmine) was applied to resection bases to identify residual disease. Targeted base biopsies were taken from identified residual disease (positive group) or random base biopsies were taken when a clear base was visualised (negative group). Overall rates of incomplete resection were documented. Reported rates post chromoendoscopy and actual histological rates were documented and compared.

**Results** A total of 102 polyps were identified for inclusion, of which 15% (n=16) were excluded. Resection quality was evaluated in 86 polyps of 61 patients (female n=33 54%; mean Age 62.3 years). Polyps were mainly removed by cold snare (n=71, 82.5%). Most polyps (n=58, 67%) measured between 5 to 10mm. Polyps were largely located in the right colon (n=57, 66%). Overall histological residual disease occurred in 17/86 (19.6%). Chromoendoscopy correctly identified residual disease in 13 of 17 bases (76.5%). Only four of /86 (4.6%) of polyp bases were misclassified post-chromoendoscopy (odds ratio 0.284 (95% CI 0.0857–0.9409), *P*=0.03).

**Conclusion** Indigo carmine chromoendoscopy improves early detection of residual disease post polypectomy, reducing incomplete resection rates.

## Introduction

Polyp identification and resection is an important and recognized quality indicator in colonoscopy. Removal of colonic polyps has been shown to clearly reduce incidence and mortality from colorectal cancer and forms the basis for all colorectal cancer screening programmes [1]. Consensus guidelines frequently demand a minimum adenoma detection rate (ADR) of between 15% and 30% in screening populations [2–4]. Lower ADRs have been associated with a higher risk of interval cancer, with an ADR greater than 20% significant for reducing interval

cancer rates [1, 5–6]. Appropriate surveillance intervals as well as ADR aim at reducing the rate of subsequent neoplasia. Patients with adenomatous polyps, large polyps or a large number of polyps are at greater risk of developing future malignancy and are therefore entered into surveillance programmes accordingly.

## Incomplete resection rate

Polyp detection is only one part of a successful colorectal cancer prevention strategy. Performing safe and complete polypectomy is also a specific goal for successful colonoscopy. An

increasingly recognized measure of efficient colonoscopy is the incomplete resection rate (IRR) of polyps, which may have significant implications for development of interval cancers. In practice, complete polyp resection is assumed if no residual polyp tissue is visible macroscopically following resection. Nonetheless, random biopsies of apparently clear polyp bases can demonstrate residual polyp tissue [7]. Rates of incomplete polyp resection vary widely in the literature but may be as high as 23% [5, 8, 9].

The morphology and histological subtype of a polyp may affect the completeness of resection, with sessile serrate lesions more difficult to fully demarcate and, therefore, completely resect [10]. Residual disease is more likely with larger polyps, for sessile serrated adenomas, and with more proximal lesions [11]. Endoscopists' training and experience are key factors in increasing lesion detection [12, 13] and reducing incomplete resection, with significant variability in IRR between endoscopists reported (ranging from 6.5% to 22.7%) in one study alone [11]. However, no consensus exists regarding what level of experience is required to ensure quality-assured polypectomy. It is estimated that up to 30% of interval cancers are due to incomplete resection of polyps and the 5-year interval cancer rate is reportedly as high as 8% [6, 14]. While the majority of interval cancers are thought to arise from missed lesions at the time of index colonoscopy, residual disease from incomplete polypectomy also accounts for a significant proportion [15]. Indeed, risk of interval cancers is higher for those with a previous history of polyps [16].

### What techniques are used to reduce IRR?

The method with which polyps are resected may affect the likelihood of residual disease. When compared to other polypectomy devices, cold forceps polypectomy is more likely to result in residual histological disease and is no longer recommended except for diminutive polyps [17–19]. Nonetheless, even with diminutive polyps, significant IRR have been reported for SSLs in particular. Cold snare polypectomy results in higher resection completion rates [20–22], particularly when employed by experienced endoscopists. Consensus guidelines recommend snare resection for polyps larger than 5 mm [17]. In fact, (piecemeal) cold snare resection has been shown to be safe and efficacious when employed for polyps larger than 1 cm, previously of hot snare polypectomy alone, and is increasingly employed in clinical practice [23].

Adherence to recommendations on polypectomy technique reduces IRR; however, compliance with these guidelines is inconsistent [24]. Recent evidence suggests that despite the application of appropriate techniques, residual disease remains a problem. Recently a Japanese group reported complete resection rates (R0) of only 32% and residual disease rates of 1% employing cold snare polypectomy [25]. Identification of residual disease can be challenging. In particular, differentiating between snare artefact (post-polypectomy protrusions) and residual tissue on white light inspection alone is difficult for post-cold snare polypectomy. The cautery effect of hot snare further complicates this inspection with a visible ring of cauterized tissue often remaining around the base post-resection. Currently,

close inspection of a polyp base with white light is advocated to identify residual dysplastic tissue.

### Chromoendoscopy

Dye-based chromoendoscopy is a diagnostic technique in which a chemical substance is sprayed or flushed onto the mucosal surface of the gastrointestinal tract to highlight specific areas. It is an established technique in demarcating and evaluating colorectal lesions and is increasingly employed in lesion detection [26, 27]. The stains used can be subdivided into “absorptive” or “vital” stains which are absorbed into certain tissue types (i. e. dysplastic) and “contrast” or “non-absorptive” stains which pool in mucosal grooves to delineate a lesion. The most commonly employed absorptive stains crystal violet, acetic acid and methylene blue, while indigo carmine is the non-absorptive stain most commonly used.

Chromoendoscopy is increasingly recommended in surveillance programs aimed at detecting dysplastic or neoplastic tissue (e. g. Barrett's esophagus (BO) or inflammatory bowel disease [IBD]). Improved ADRs have been reported following chromoendoscopy in a colorectal cancer screening cohort [28], as well as improved detection of flat and right-sided lesions [29]. Several studies have reported increased detection rates for dysplasia with chromoendoscopy compared to random quadrantic biopsies in inflammatory bowel disease surveillance [30–32]. More recently, meta-analyses have demonstrated an incremental yield of dysplasia detection between chromoendoscopy and white light endoscopy [33, 34]. Spraying catheters allow the most controlled and precise application of the dye as a fine mist onto the gastrointestinal surface. This is of particular use in IBD surveillance where the entire colon is inspected. Contrast stains may also be flushed onto smaller areas, including individual polyps.

### Study aims

The aims of this study were to assess local incomplete resection rates post snare polypectomy, and to determine whether dye-based chromoendoscopy could correctly identify residual disease at the time of snare polypectomy. We hypothesize that targeted dye-based chromoendoscopy post-polypectomy may be an easy and fast technique to implement and result in increased detection of residual tissue compared to close inspection alone. This could represent a strategy to reduce the rate of interval cancers.

## Patients and methods

### Patients

This was a prospective interventional study conducted at a university tertiary referral hospital between June 2017 and April 2018. Adult patients undergoing colonoscopy for colorectal cancer screening or non-specific gastrointestinal symptoms and those referred specifically for polypectomy were considered for the study. For 2 days prior to the scheduled colonoscopy, all participants were advised to consume a low-residue diet. Bowel preparation was with polyethylene glycol (PEG) solutions. Split dosing was advised for afternoon procedures.

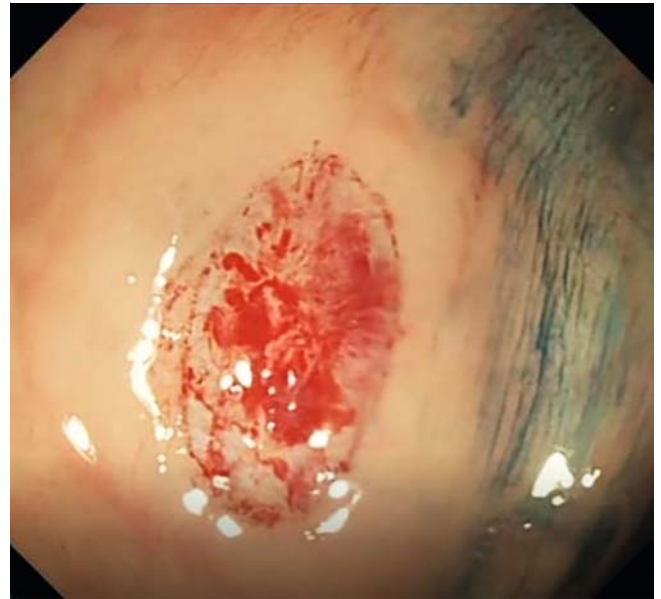
## Polypectomy and EMR protocol

Conventional high-definition colonoscopes (Olympus) were used for all procedures, which were performed under conscious sedation by either a consultant gastroenterologist or a specialist registrar in gastroenterology (minimum 3 years post-qualification). Patients who agreed to participate were enrolled if they were found to have at least one colonic polyp requiring snare resection,  $\geq 3$  mm in diameter. Polyps were resected en-bloc with or without an injection-assisted endoscopic mucosal resection (EMR) technique (ie “lift and cut”) with a saline-only lifting solution, depending on size and morphology. Polypectomy specimens were retrieved and sent for histological analysis. The polyp base was then flushed thoroughly with normal saline to allow direct inspection under white light (► **Fig. 1**). Polypectomy bases without visible residual disease on white light inspection were then flushed with 5 to 10 mL of 0.13% indigo carmine drawn up in a 5-mL syringe and injected down the working channel of the scope. Excess contrast was suctioned and the base re-examined (► **Fig. 2**). Residual disease identified post-indigo carmine application was documented and removed by targeted biopsy. In cases where no residual disease was identified post-application of indigo carmine, two random biopsies were taken from each side of the polyp base. All samples were processed as standard and examined by expert pathologists blinded to the endoscopy result.

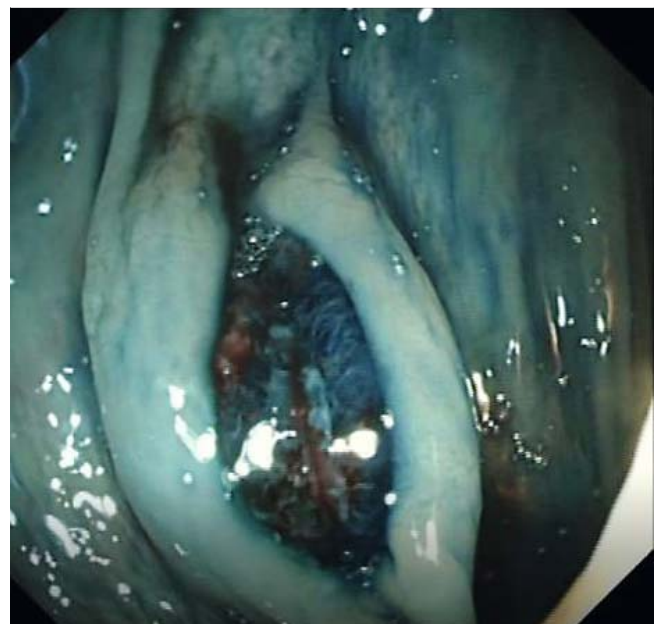
Exclusion criteria included the need for piecemeal resection, visible residual disease prior to chromoendoscopy, failure to retrieve the polyp post-polypectomy or significant post-polypectomy bleeding requiring treatment. Basic demographic data and endoscopy findings including polyp location, size, resection technique and complications were documented. The result of base examination under white light and chromoendoscopy was recorded in the endoscopy report for each excised polyp as either positive or negative. Subsequent polyp histology was documented. Residual disease was defined as presence of the same dysplastic tissue on samples from the polypectomy base as detected in the polyp sample itself, irrespective of histological type (Tubular adenoma, tubulovillous adenoma, hyperplastic or sessile serrated adenoma).

## Statistical analysis

Data are presented as means  $\pm$  standard deviations or medians and ranges. The overall and post-indigo carmine incomplete resection rates are presented as proportions with 95% confidence intervals (CIs). Histology assessment was used as a gold standard and the accuracy of chromoendoscopy prediction of residual disease; sensitivity, specificity, positive and negative predictive values (NPV) and number needed to treat was calculated. Odds ratios were calculated for chromoendoscopy versus white light inspection of polyp bases. Detection rates were compared using a Chi squared test.  $P < 0.05$  was considered significant. All statistical analyses were performed using SPSS Statistics, version 23 (SPSS Inc., IBM Corp. Armonk, New York, United States).



► **Fig. 1** Post-cold snare polypectomy margin and base as viewed with standard white light.



► **Fig. 2** Post-cold snare polypectomy margin and base as viewed following application of 0.13% indigo carmine.

## Results

A total of 102 polyps were identified for inclusion in this study, of which 15% ( $n = 16$ ) were excluded in total due to either piecemeal resection ( $n = 11$ ) or visible residual tissue post-polypectomy ( $n = 5$ ). Resection quality was therefore evaluated in 86 polyps from 61 patients (female  $n = 33$  54%, mean age 62.3 years). The majority of polyps were removed by cold snare polypectomy ( $n = 71$ , 83.5%), with cautery less commonly required ( $n = 15$ , 17.5%). Most polyps were small ( $n = 58$ , 67%) measuring between 5 to 10 mm, with larger polyps  $> 10$  mm (9.3%)

► **Table 1** Study population.

Parameter	Number	Percentage
Patients	62	N/A
Male gender	28	46
Age	62.3 years	N/A
Included polyps	86	85
Excluded Polyps	16	16
Polyps 5 mm-10 mm	58	68
Polyps >10 mm	8	9
Polyps 3 mm-5 mm	20	23
Right colon	57	66
Cold snare polypectomy	71	84
Hot snare polypectomy	15	16
Saline EMR	66	76

EMR, endoscopic mucosal resection.

and diminutive polyps <5 mm (23%) less frequent. All polyps larger than 5 mm (76.7% n = 66) were lifted with normal saline-only solution prior to snare resection. Polyps were predominantly located in the right colon (n = 57, 66%). Histopathological analysis confirmed the majority of polyps as tubular adenomas (n = 54, 63%), with tubulovillous adenoma (n = 25, 29%) and sessile serrated lesions (n = 7, 8%) also detected. There were no reported procedure related complications (► **Table 1**).

The overall incomplete resection rate (IRR) following polypectomy and conventional white light examination, based on histological examination of residual disease or whether targeted or random base biopsies was 19.7% (n = 17/86). In all, post-polypectomy indigo carmine chromoendoscopy (PPC) was deemed positive by the endoscopist in 22 resection bases (25.6%) and PCC accurately detected residual disease in 13 of these 17 incomplete resections (76.5%). Therefore, only four of 86 (4.6%) of all polyp bases were misclassified as negative on PPC, odds ratio of 0.284 (95% CI 0.0857–0.9409)  $P=0.03$  (► **Table 2**).


The sensitivity, specificity, positive predictive value and negative predictive value (NPV) of PCC for residual disease were 76%, 87%, 59%, 94% respectively. Overall PCC correlation with histology for presence of residual disease was moderate, Pearson's  $r=0.5789$ ,  $P<0.00001$ . Compared to close examination of the polypectomy base with white light alone, PCC significantly enhanced the endoscopist's ability to detect residual disease (15.1% v 4.9%) (► **Fig. 3**) with a number needed to treat (NNT) of 10, (95% CI 1.56–18.87, NNT range 5.3–64). There was no difference in IRR rate by polyp size, location or resection technique, although the overall population size in the study prevented effective subgroup analysis.

## Discussion

Despite the success of colorectal cancer screening programs, interval cancers do occur. Missed lesions at the time of index colonoscopy and inadequate excision account for a significant proportion of interval cancers. Better recognition and visualization of margins, improved excision techniques and identifica-

► **Table 2** Incomplete resection detection rate by technique for sessile colonic polyps.

Technique	Complete resection (n)	Incomplete resection (n)	Incomplete resection rate %
White light inspection	97	5	4.9
0.13% Indigo carmine post-polypectomy Chromoendoscopy	73	13	15.1
0.13% Indigo carmine post-polypectomy Chromoendoscopy and random polypectomy base biopsies	69	17	19.7



► **Fig. 3** The effect of indigo carmine on the detection of residual disease compared to white light endoscopy alone. ("Complete resection" and residual disease suspected refers to endoscopists' assessment post-polypectomy.)

tion and removal of residual polyp tissue have all been the subject of clinical investigation, with a view to reducing risk of early recurrence and interval cancers. Inclusion of appropriate polypectomy technique in the latest European Society of Gastrointestinal Endoscopy position statement on performance measures for lower gastrointestinal endoscopy as one of seven key indices highlights the importance of complete excision [35]. Overcoming incomplete excision, which accounts for approximately 20% of interval cancers, remains a challenge [36].

Previous studies have demonstrated the efficacy of magnification chromoendoscopy colonoscopy in detecting residual disease post-EMR [37, 38] and in differentiating between neoplastic and non-neoplastic lesions [39]. Its wider use, however, has been limited by cost, availability, and the additional training that is required for its use. To our knowledge ours is the first study to show that post-polypectomy dye-based chromoendoscopy (PCC) can effectively enhance detection of residual dysplastic tissue, thereby significantly reducing incomplete resection rates (OR 0.28, 95% CI 0.0857–0.9409  $P=0.03$ ). In this study, immediate post-polypectomy dye-based chromoendoscopy detected significantly more residual dysplastic tissue than was identified by conventional white light inspection alone, thereby enabling further targeted resection. In addition, PCC had a high NPV of 94%, suggesting it could be a simple, reliable means of ruling out residual disease. Overall PCC was significantly superior to simple close inspection of polypectomy bases with white light, with a NNT of 10, suggesting routine implementation would quickly improve detection of residual disease, enabling further excision at the time of index colonoscopy, thereby reducing the potential risk of incomplete resection and the development of interval disease.

The chromoendoscopy technique used was simple and easy to perform without the need for specific chromoendoscopy equipment or for magnification endoscopes. Three of the four endoscopists taking part in this study would not routinely perform chromoendoscopy as part of their practice. Post-polypectomy chromoendoscopy significantly enhanced detection of residual disease by 76%, with a significant NPV of 94%, suggesting it could be applied widely and used effectively by Endoscopists without significant prior chromoendoscopy experience.

In general, the additional time required for chromoendoscopy, which includes preparing the mucosal surface, diluting the contrast stain correctly, applying the contrast through specific catheters to the entire colonic mucosa, and performing slow phased withdrawal with thorough inspection and additional biopsy specimens, is a major factor preventing universal application of chromoendoscopy. The targeted application technique employed in this study was simple and fast, with less than 2 minutes required to apply, examine, and manage identified residual disease, suggesting the technique could be widely implemented without significant cost or time implications. In addition, the technique was safe with no reported complications either as a result of enhanced detection and targeted removal of residual disease or from random base biopsies.

The design of our study is not without inherent drawbacks. Endoscopists were not blinded to the white light inspection and as only polyps thought to be clear after initial inspection

were included, this could represent a source of bias or Hawthorne effect. It is not known what the actual histologically proven IRR and/or complete R0 resection rates were for excluded polyps after white light inspection. However, this excluded group were thought to have residual disease at the time of polypectomy and received additional treatment as required without the need for enhanced base inspection techniques. These lesions were not the subject of this research. In addition, four different experienced endoscopists undertook the study, all of whom were blinded to final histological findings.

Contrast stains are increasingly added to the injection solution during endoscopic mucosal resection (EMR) to assist in demarcating the borders of large flat lesions prior to resection. Whether the addition of contrast pre-polypectomy reduces risk of incomplete resection, or moreover enhances detection of residual disease, is unknown and beyond the scope of this study. However, as methylene blue rather than indigo carmine is more commonly used in injection solutions and the injected cushion tends to disappear after resection, it is unlikely that contrast included in lifting solutions will provide the same function.

Perhaps disappointingly, despite the application of appropriate polypectomy techniques, our IRR was high at just under 20%. Endoscopist experience may explain this relatively high IRR in part, as approximately half of the procedures were completed by a senior trainee rather than a Consultant, which would be expected to increase the IRR somewhat. While our IRR rates appear high, other studies have reported similar findings, which highlights the significant problem of residual disease despite apparent complete en-bloc resection at the time of polypectomy and adds support for the development of effective techniques to enhance early detection. Indeed, reported complete resection rates (R0) based on histological examination of excised polyps vary significantly in the published literature from as low as 33% to 97% [22, 36].

It is possible that our policy of taking two random biopsies from clear polypectomy bases has increased our detected IRR. Other studies employing similar polypectomy base biopsy regimens, however, have reported variable rates from 2% to as high as 24% [22, 23]. While our rate is among the higher rates reported, it appears not to be an outlier. In addition, all of the polyps included in our study were sessile and most were larger than 5 mm (68%) and eight (10%) were larger than 10 mm, which increases risk of IRR. A substantial proportion were located in the right colon 66% ( $n=57$ ), and 8% of all polyps were sessile serrated lesions, both recognized risk factors for incomplete resection. We also included all dysplastic tissue found on base biopsies consistent with the index polyp as positive residual disease. We did this as endoscopists endeavor to remove polyps entirely at the time of colonoscopy without having the fore knowledge of its histological diagnosis.

The small sample size in this study limited our ability to assess for size-specific IRRs which may be clinically relevant. Indeed, the technique of post-polypectomy dye-based chromoendoscopy may be more beneficial in lesions of a certain size or morphology over others. Use of cautery may limit its utility. As ever larger polyps are resected in a safe and efficacious man-



ner with cold snare polypectomy, our technique may increase in utility. This would benefit from further investigation.

Unfortunately, the small sample size in our study precluded further subgroup analysis of factors associated with risk of residual disease, which was not the primary purpose of our study and would require a future large prospective investigation. In addition, the precise role of PCC in certain populations and in conjunction with other enhanced identification and polypectomy techniques requires further study.

## Conclusion

Our prospective study suggests that immediate examination of a polypectomy base with the application of 0.13% indigo carmine is a simple and effective means to enhance detection of residual polyp tissue. This technique appears to be effective following cold snare polypectomy of small and larger sessile polyps throughout the colon. In this study, detection of residual disease was enhanced by 76%, thereby significantly reducing risk of incomplete resection (odds ratio of 0.284, 95% CI 0.0857–0.9409). The significant NPV of 94% suggests this technique could be employed as a simple and reliable method of ruling out residual disease at the time of polypectomy. Further protocol-driven studies are required to determine the role post-polypectomy dye-based chromoendoscopy might play, and in what setting its effects may be most marked.

## Competing interests

None

## References

- [1] Corley DA, Jensen CD, Marks AR et al. adenoma detection rate and risk of colorectal cancer and death. *N Engl J Med* 2014; 370: 1298–1306
- [2] European Commission. European guidelines for quality assurance in colorectal cancer screening and diagnosis. 2010. Available from: [http://eee.uegf.org/eu\\_news/CRC\\_guidelines\\_publications%20EU\\_2011.pdf](http://eee.uegf.org/eu_news/CRC_guidelines_publications%20EU_2011.pdf)
- [3] Carey F, Newbold M, Quirke P et al. Reporting lesions in the NHS Bowel Cancer Screening Programme. Sheffield: NHS Cancer Screening Programmes, 2007
- [4] McNamara D, Qasim A, Lee N et al. Round one of the Adelaide and Meath Hospital/Trinity College Colorectal Cancer Screening Programme: programme report and analysis based on established international key performance indices. *Irish J Med Sci* 2011; 180: 549–542
- [5] Kaminsky MF, Regula J, Kraszewska E et al. Quality indicators for colonoscopy and the risk of interval cancer. *N Engl J Med* 2010; 362: 1795–1803
- [6] Chiu SY, Chuang S, Chen SL et al. Faecal haemoglobin concentration influences risk prediction of interval cancers resulting from inadequate colonoscopy quality: analysis of the Taiwanese Nationwide Colorectal Cancer Screening Program. *Gut* 2017; 66: 293–300
- [7] Liu S, Ho SB, Krinsky ML. Quality of polyp resection during colonoscopy: are we achieving polyp clearance? *Dig Dis Sci* 2012; 57: 1786
- [8] Robertson DJ, Greenber ER, Beach M et al. Colorectal cancer in patients under close colonoscopic surveillance. *Gastroenterology* 2005; 129: 34–41
- [9] Farrar WD, Sawhney MS, Nelson DB et al. Colorectal cancers found after a complete colonoscopy. *Clin Gastroenterol Hepatol* 2006; 4: 1259–1264
- [10] Gomez V, Badillo RJ, Crook JE et al. Diminutive colorectal polyp resection comparing hot and cold snare and cold biopsy forceps polypectomy. Results of a pilot randomized, single-center study (with videos). *Endosc Int Open* 2015; 03: E76–E80
- [11] Pohl H, Srivastava A, Bensen SP et al. Incomplete polyp resection during colonoscopy – results of the complete adenoma resection (CARE) study. *Gastroenterology* 2013; 144: 74–80
- [12] Nicolas-Perez D, Parra-Blanco A, Gimeno-Garcia AZ et al. Risk factors associated with colorectal flat adenoma detection. *Eur J Gastroenterol Hepatol* 2013; 25: 302–308
- [13] Kaltenbach T, McGill SK, Kalidindi V et al. Proficiency in the diagnosis of nonpolypoid colorectal neoplasm yields high adenoma detection rates. *Dig Dis Dci* 2012; 57: 764–770
- [14] Zauber AG, Winawer SJ, O'Brien MJ et al. Colonoscopic polypectomy and long-term prevention of colorectal-cancer deaths. *N Engl J Med* 2012; 366: 687–696
- [15] le Clercq CMC, Bouwens MWE, Rondagh EJA et al. Postcolonoscopy colorectal cancers are preventable: a population-based study. *Gut* 2014; 63: 957–963
- [16] Samadder NJ, Curtin K, Tuohy TM et al. Characteristics of missed or interval colorectal cancer and patient survival: a population-based study. *Gastroenterology* 2014; 146: 950–960
- [17] Ferlitsch M, Moss A, Hassan C et al. Colorectal polypectomy and endoscopic mucosal resection (EMR): European Society of Gastrointestinal Endoscopy (ESGE). *Endoscopy* 2017; 49: 270–297
- [18] Lee CK, Shim JJ, Jang JY. Cold snare polypectomy vs. Cold forceps polypectomy using double-biopsy technique for removal of diminutive colorectal polyps: a prospective randomized study. *Am J Gastroenterol* 2013; 108: 1593–1600
- [19] Kim JS, Lee BI, Choi H et al. Cold snare polypectomy versus cold forceps polypectomy for diminutive and small colorectal polyps: A randomized controlled trial. *Gastrointest Endosc* 2015; 81: 741–747
- [20] Kawamura T, Takeuchi Y, Asai S et al. A comparison of the resection rate for cold and hot snare polypectomy for 4–9 mm colorectal polyps: a multicentre randomised controlled trial (CRESCENT study). *Gut* 2018; 67: 1950–1957
- [21] Robertson DJ, Lieberman DA, Winawer SJ et al. Interval cancer after total colonoscopy: results from a pooled analysis of eight studies. *Gastroenterology* 2008; 134: A-111–112
- [22] Efthymiou M, Taylor AC, Desmond PV et al. Biopsy forceps is inadequate for the resection of diminutive polyps. *Endoscopy* 2011; 43: 312–316
- [23] Piraka C, Saeed A, Waljee AK et al. Cold snare polypectomy for non-pedunculated colon polyps greater than 1 cm. *Endosc Int Open* 2017; 5: E184–E189
- [24] Parihar V, Falco J, Maheshwari P et al. Adherence to European polypectomy guidelines: retrospective experience from a tertiary Irish hospital. *Gastrointest Tumours* 2019; 5: 82–89
- [25] Maruoka D, Arai M, Akizue N et al. Residual adenoma after cold snare polypectomy for small colorectal adenomas: a prospective clinical study. *Endoscopy* 2018; 50: 693–700
- [26] Trivedi PJ, Braden B. Indications, stains and techniques in chromoendoscopy. *Q J Med* 2013; 106: 117–131
- [27] Omata F, Ohde S, Deshpande GA et al. Image-enhanced, chromo, and cap-assisted colonoscopy for improving adenoma/neoplasia detection rate: a systematic review and meta-analysis. *Scan J Gastroenterol* 2014; 49: 222–237

- [28] Kiesslich R, von Bergh M, Hahn M et al. Chromoendoscopy with indigo carmine improves the detection of adenomatous and nonadenomatous lesions in the colon. *Endoscopy* 2001; 33: 1001–1006
- [29] Hurlstone DP, Cross SS, Slater R et al. Detecting diminutive colorectal lesions at colonoscopy: a randomised controlled trial of pan-colonic versus targeted chromoscopy. *Gut* 2004; 53: 376–380
- [30] Laine L, Kaltenbach T, Barkun A et al. SCENIC International Consensus Statement on Surveillance and Management of Dysplasia in Inflammatory Bowel Disease. *Gastroenterology* 2015; 148: 639–651
- [31] Rutter MD, Saunders BP, Schofield G et al. Pancolonic indigo carmine dye spraying for the detection of dysplasia in ulcerative colitis. *Gut* 2004; 53: 256–260
- [32] Ratiu N, Gelbmann C, Rath HR et al. Chromoendoscopy with indigo carmine in flexible sigmoidoscopy screening: does it improve the detection of adenomas in the distal colon and rectum? *J Gastrointest Liver Dis* 2007; 16: 153–156
- [33] Subramanian V, Mannath J, Ragunath K et al. Meta-analysis: the diagnostic yield of chromoendoscopy for detecting dysplasia in patients with colonic inflammatory bowel disease. *Aliment Pharmacol Ther* 2011; 33: 304–312
- [34] Brown SR, Baraza W, Din S et al. Chromoscopy versus conventional endoscopy for the detection of polyps in the colon and rectum. *Cochrane Database Syst Rev* 2016; 4: Cd006439
- [35] Kaminski MF, Thomas-Gibson S, Bugajski M et al. Performance measures for lower gastrointestinal endoscopy: a European Society of Gastrointestinal Endoscopy (ESGE) Quality Improvement Initiative. *Endoscopy* 2017; 49: 378–397
- [36] Robertson DJ, Lieberman DA, Winawer SJ et al. Colorectal cancers soon after colonoscopy: a pooled multicohort analysis. *Gut* 2014; 63: 949–956
- [37] Hurlstone DP, Cross SS, Brown S et al. A prospective evaluation of high-magnification chromoscopic colonoscopy in predicting completeness of EMR. *Gastrointest Endosc* 2004; 59: 642–650
- [38] Hurlstone DP, Cross SS, Drew K et al. An evaluation of colorectal endoscopic mucosal resection using high-magnification chromoscopic colonoscopy: a prospective study of 1000 colonoscopies. *Endoscopy* 2004; 36: 491–498
- [39] Yanai S, Nakamura S, Matsumoto T. Role of magnifying colonoscopy for diagnosis of colorectal neoplasms: From the perspective of Japanese colonoscopists. *Digest Endosc* 2016; 28: 274–280