



## Primary gastric mucormycosis presenting with post-Coronavirus disease - 19 upper gastrointestinal bleed

Sayan Malakar<sup>1</sup> · Anshuman Elhence<sup>1</sup> · Pallavi Prasad<sup>2</sup> · Uday C. Ghoshal<sup>1</sup> · Gaurav Pandey<sup>1</sup> · Samir Mohindra<sup>1</sup> 

© Indian Society of Gastroenterology 2022

A man aged 82-year presented with a history of hematemesis and melena for five days. His hemoglobin was 5 g/dL. He required two units of packed red blood cell transfusion after initial resuscitation with intravenous saline. He suffered from moderate Coronavirus disease-19 (COVID-19) 2 months ago for which he received oral prednisolone (60 mg once a day) for 21 days. His recent nasal swab was negative for COVID-19 ribonucleic acid (RNA). His current high-resolution computed tomography of the chest was not suggestive of active infection. After resuscitation, he underwent an esophagogastroduodenoscopy.

His upper gastrointestinal (GI) endoscopy showed a large gastric ulcer (8 Cm) extending from the gastroesophageal junction (Fig. 1a). Biopsy revealed ulcerated stomach mucosa with necrotic debris containing periodic acid Schiff (PAS)-positive fungal hyphae (Fig. 1b). It was suggestive of gastric mucormycosis. He was managed conservatively with pantoprazole infusion and amphotericin B. After the initial 13 days, because of worsening renal function, amphotericin B was stopped. Posaconazole was administered, which was continued for 3 months. On follow-up endoscopy, his ulcer healed and subsequently resolved after 3 months (Fig. 2a), which was confirmed on biopsy (Fig. 2b).

Acute gastrointestinal bleeding (GIB) complicates 2% to 13% of patients hospitalized with COVID-19 [1]. During the second wave of this pandemic in India, nasopharyngeal mucormycosis was found to complicate the disease course; however, mucormycosis of the gut has been rarely reported as a cause of GIB in COVID-19 patients. The estimated prevalence of mucormycosis ranges from 0.12 to 0.20 per 10,000 patients [2]. Gastrointestinal manifestations can be presenting complaints in around 7% of patients mostly in immunocompromised hosts and the stomach is the most commonly affected organ in the GI tract. Though antifungal therapy is the mainstay of treatment in the majority of patients, gastrectomy and debridement may be required in extensive diseases [3], our patient was managed with anti-fungal drugs alone.

Mucorales are iron-dependent for their hyphal growth during the invasion of the host cells. Inflammation-associated hyperferritinemia in COVID-19 along with bleeding from a pre-existing peptic ulcer may contribute to the rapid proliferation of Mucorales leading to fatal GI bleeding [4].

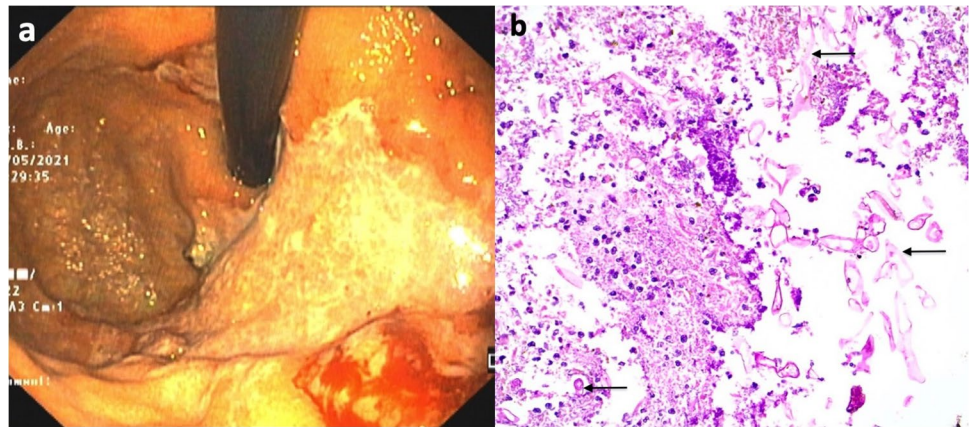
Our case highlights an unusual cause of GI bleeding in a patient who recovered from COVID-19. Despite an extensive disease, he was successfully managed with anti-fungal therapy alone without surgery.

✉ Samir Mohindra  
mohindrasamir@yahoo.com

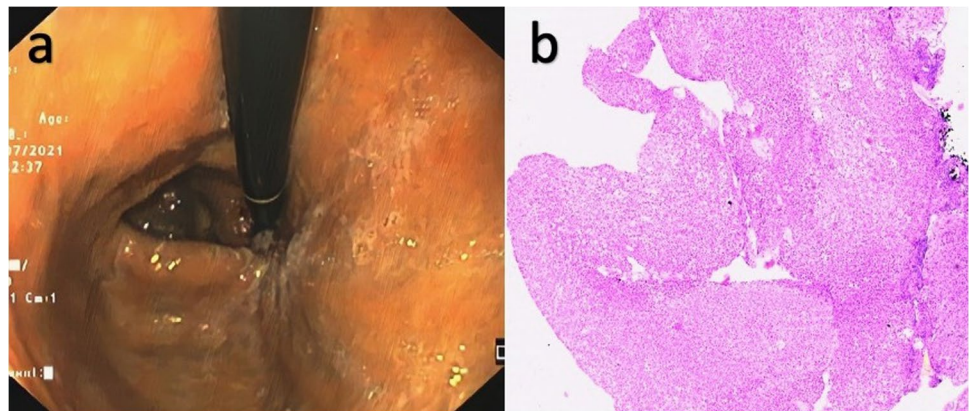
<sup>1</sup> Department of Gastroenterology, Sanjay Gandhi Post Graduate Institute of Medical Sciences, Lucknow 226 014, India

<sup>2</sup> Department of Pathology, Sanjay Gandhi Post Graduate Institute of Medical Sciences, Lucknow 226 014, India

**Fig. 1** Upper gastrointestinal endoscopy and biopsy. **a** Upper gastrointestinal endoscopy showing 8-Cm-large gastric ulcer extending from the gastroesophageal junction. **b** Gastric biopsies revealed periodic acid-Schiff (PAS)-positive broad aseptate fungal hyphae (black arrow) suggestive of Mucorales (PAS staining 40×)



**Fig. 2** Follow-up endoscopy and biopsy. Follow-up endoscopy shows healed ulcer (**a**) and biopsy revealed a normal mucosal pattern (**b**) of gastric tissue without any evidence of mucormycosis (H&E 10×)



## Declarations

**Conflict of interest** SM, AE, PP, UCG, GP, and SM declare no competing interests.

**Disclaimer** The authors are solely responsible for the findings and the content of the paper. In no way the Honorary Editor-in-Chief, Editorial Board Members, the Indian Society of Gastroenterology and the printer/publishers are responsible for the results/findings and the content of this article.

## References

1. Lin L, Jiang X, Zhang Z, et al. Gastrointestinal symptoms of 95 cases with SARS-CoV-2 infection. *Gut*. 2020;69:997–1001.
2. Kontoyiannis DP, Yang H, Song J, et al. Prevalence, clinical and economic burden of mucormycosis-related hospitalizations in the United States: a retrospective study. *BMC Infect Dis*. 2016;16:730.
3. Sharma D. Successful management of emphysematous gastritis with invasive gastric mucormycosis. *BMJ Case Rep*. 2020;13:e231297.
4. Baldin C, Ibrahim AS. Molecular mechanisms of mucormycosis—the bitter and the sweet. *PLoS Pathog*. 2017;13:e1006408.

**Publisher's note** Springer Nature remains neutral with regard to jurisdictional claims in published maps and institutional affiliations.