

FDG PET Appearance of “Cannonball” Pulmonary Metastases

Murali Meka, M.D., Srinivas Bommireddipalli, M.D., Jonathan Killam, M.D., Peeyush Bhargava, M.D., and E. Gordon Depuey, M.D.

We present the case of a 67-year-old woman with a recent tissue diagnosis of endometrial cancer whose FDG PET scan exhibited multiple hypermetabolic foci through out both the lungs. Contemporaneously acquired conventional radiographs showed parenchymal nodules that demonstrated the classic “cannon ball” appearance of pulmonary metastases. Pulmonary metastasis from an endometrial primary is a rare event, as are the presence of pulmonary findings at the time of initial staging. Thus, this case demonstrates rare, and yet, distinctive aspects of the disease presentation and image correlation across the various imaging modalities.

Introduction

Pulmonary metastasis from an endometrial primary is a rare event, as are the presence of pulmonary findings at the time of initial staging. In this report we present a post-menopausal female, with a recent tissue diagnosis of endometrial cancer, exhibiting multiple hypermetabolic foci throughout both the lungs on FDG PET. Furthermore, we intend to briefly review the relevant

literature with special emphasis on radiological imaging.

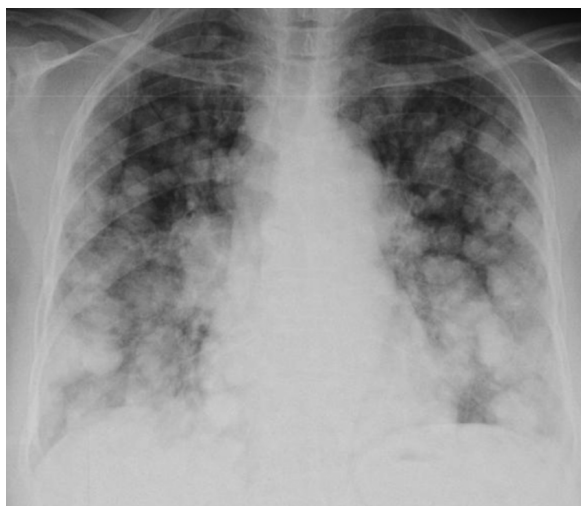

Figure 1. 67-year-old woman with endometrial cancer. Chest radiograph shows innumerable pulmonary nodules with “cannonball” morphology.

Citation: Meka M, Bommireddipalli S, Killam J, Bhargava P, Depuey EG. FDG PET Appearance of “Cannonball” Pulmonary Metastases. *Radiology Case Reports*. [Online] 2009;4:152.

Copyright: © 2009 The Authors. This is an open-access article distributed under the terms of the Creative Commons Attribution-NonCommercial-NoDerivs 2.5 License, which permits reproduction and distribution, provided the original work is properly cited. Commercial use and derivative works are not permitted.

Abbreviations: CT, computed tomography; FDG, fluorodeoxyglucose; PET, positron emission tomography

Murali Meka, M.D. (Email: MMeka@chpnet.org), Srinivas Bommireddipalli, M.D., Jonathan Killam, M.D., Peeyush Bhargava, M.D., and E. Gordon Depuey, M.D., are in the Division of Nuclear Medicine, St Luke’s Roosevelt Hospital Center, New York, NY, USA.

Published: July 17, 2009

DOI: 10.2484/rcr.v4i3.152

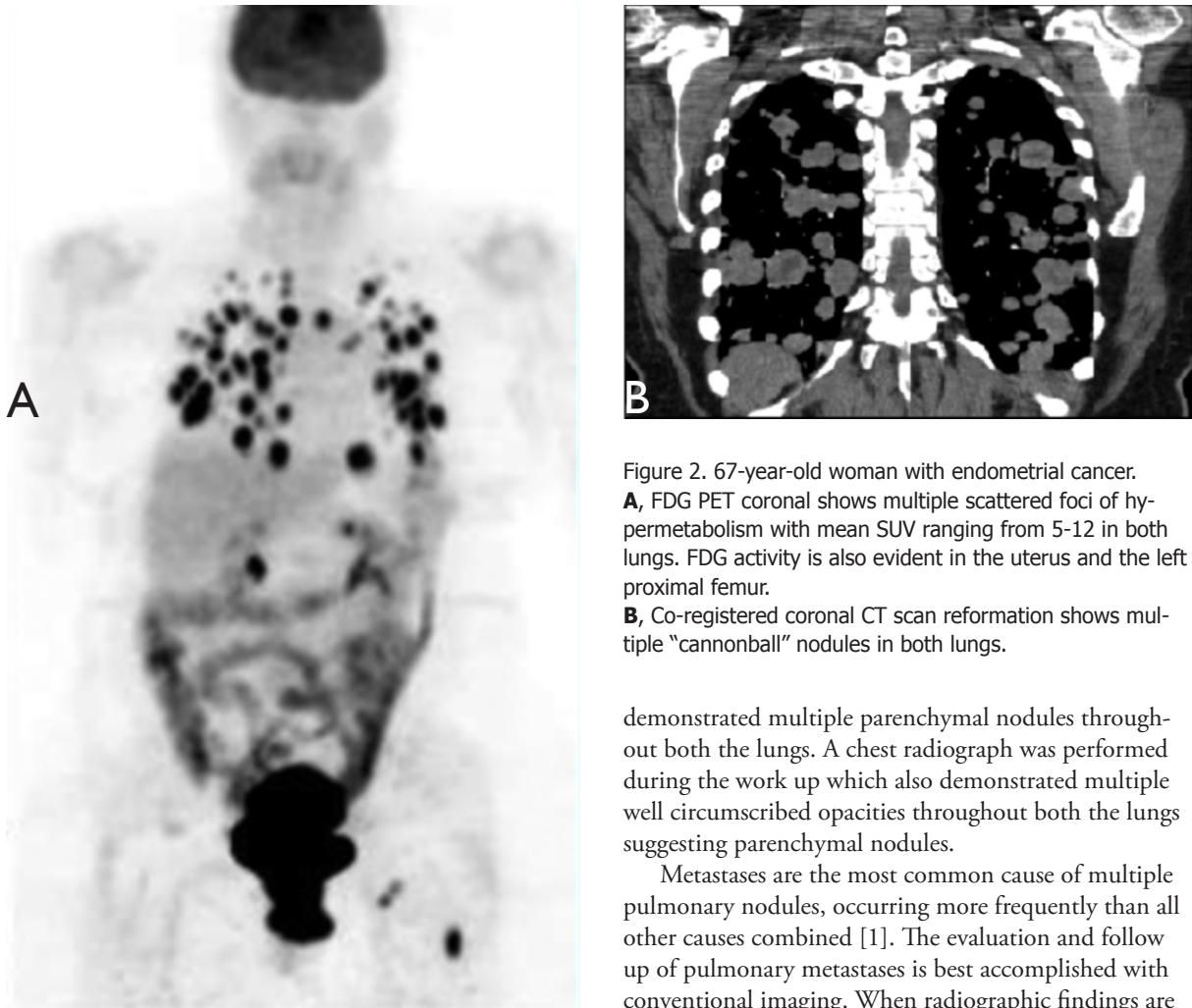


Figure 2. 67-year-old woman with endometrial cancer. **A**, FDG PET coronal shows multiple scattered foci of hypermetabolism with mean SUV ranging from 5-12 in both lungs. FDG activity is also evident in the uterus and the left proximal femur. **B**, Co-registered coronal CT scan reformation shows multiple “cannonball” nodules in both lungs.

demonstrated multiple parenchymal nodules throughout both the lungs. A chest radiograph was performed during the work up which also demonstrated multiple well circumscribed opacities throughout both the lungs suggesting parenchymal nodules.

Metastases are the most common cause of multiple pulmonary nodules, occurring more frequently than all other causes combined [1]. The evaluation and follow up of pulmonary metastases is best accomplished with conventional imaging. When radiographic findings are equivocal or negative in the setting of primary tumors that tend to metastasize to the lungs, CT is usually helpful [2]. The characteristic radiographic finding of “cannonball” metastases is multiple solid, well circumscribed parenchymal masses of variable size [3-5], resembling cannonballs (a heavy metal or stone ball fired from old-fashioned cannon).

FDG PET projection image was acquired 50 minutes after intravenous administration of 16.5mCi of FDG. Multiple scattered foci of hypermetabolism with mean SUV ranging from 5-12 are seen in both lungs, consistent with lung metastases. Additionally, FDG activity is also evident in the uterus and the left proximal femur. The Co-registered CT scan revealed multiple “cannonball” parenchymal nodules in both lungs consistent with lung metastases.

Case Report

A 67-year old multiparous Caucasian female presented with a history of intermittent post-menopausal bleed. Her past medical history was unremarkable. Physical examination and pelvic findings were unremarkable. Prior screenings by Pap smear, mammogram and colonoscopy were negative for any malignancy. An endometrial biopsy was performed which revealed endometrial adenocarcinoma. As part of the workup for staging a PET-CT was performed. PET images showed multiple scattered foci of hypermetabolism in both lungs. Additionally, FDG activity was also evident in the uterus and the left proximal femur. Co-registered CT

FDG PET Appearance of “Cannonball” Pulmonary Metastases

Discussion

Endometrial cancer is one of the most common female gynecological malignancies in United States with the majority of cases confined to the uterus at the time of diagnosis. Post menopausal bleeding is the most common presenting symptom and it can also occur from endometrial polyps, endometritis and hormone replacement therapy. It is imperative to investigate the post menopausal bleeding, as approximately 75% of woman diagnosed with endometrial cancer are postmenopausal. Multiple epidemiological risk factors & medical conditions have been found to be associated with endometrial cancer. These include obesity, nulliparity, and unopposed and/or prolonged exposure to estrogen, a positive family history for endometrial cancer, presence of breast, colon, and ovarian cancers [14]. In current practice, an out-patient endometrial biopsy is widely accepted for definitive diagnosis with a more invasive evaluation of the endometrial cavity reserved for biopsy negative symptomatic cases. Once diagnosis is confirmed, presurgical staging can be performed with conventional imaging and PET CT.

The overall incidence of pulmonary metastases from uterine cancer is low (2.3-4.7%) and its presence is crucial in the management of the patient [6]. Multiple pulmonary nodules are the most common manifestation of secondary neoplastic disease in the lungs, and are most frequent with tumors such as breast, colorectal, prostate, bronchial, head-and-neck, and renal cancers [11, 12]. The anatomical distribution and appearance of these lung nodules on radiological imaging are important in narrowing the differential diagnosis. Features associated more likely with metastases than with benign disease include the rate of growth of the lesion and lesions that are non-calcified, spherical or ovoid, adjacent to vessels, decreased distal attenuation, and reticular changes [2-5]. Chest x-ray was the standard technique to evaluate the lung lesions in the past. Lesions smaller than 7 mm, particularly those in the lung apices and bases or adjacent heart, mediastinum, and pleura, may be missed by this technique. Therefore, a faster and more sensitive imaging modality such as high resolution CT scan has become the technique of choice in detecting pulmonary metastases [2]. But this high sensitivity comes at the cost of specificity in that inflammatory and benign nodules are included into metastases. The introduction of FDG

PET CT has greatly enhanced the differentiation of benign and malignant nodules by complementing the structural information gained from the CT with the metabolic activity of these lesions [10,13].

The main stay of treatment for primary endometrial cancer with distant metastases (stage IVa/b) is chemotherapy with individualized surgery, where feasible. Although anecdotal cases of successful remission and disease free survival were reported with extensive surgery and combination chemotherapy with Taxol derivatives and cisplatin, the overall prognosis and survivability (approximately 37%) in this group remains poor. For most cases, the goal is palliation and progression free survival.

In conclusion, recently diagnosed uterine cancer may present rarely in advanced stage with multiple “cannon ball” like metastases to the lung. Initial staging with FDG PET CT can have a significant impact on patient’s management as in our case.

References

1. Lillington GA, Caskey CI. Evaluation and management of solitary and multiple pulmonary nodules. *Clinics in chest medicine*. 1993 Mar; 14(1):111-9. [PubMed]
2. Kagan AR, Steckel RJ. Radiologic contributions to cancer management. Lung metastases. *AJR. American journal of roentgenology*. 1986 Sep; 147(3):473-6. [PubMed]
3. D’Orsi CJ, Bruckman J, Mauch P, Smith EH. Lung metastases in cervical and endometrial carcinoma. *AJR. American journal of roentgenology*. 1979 Oct; 133(4):719-22. [PubMed]
4. Otsuka I, Ono I, Akamatsu H, Sunamori M, Aso T. Pulmonary metastasis from endometrial carcinoma. *International journal of gynecological cancer*. 2002 Mar-Apr; 12(2):208-13. [PubMed]
5. Crow J, Slavin G, Kreef L. Pulmonary metastasis: a pathologic and radiologic study. *Cancer*. 1981 Jun 1;47(11):2595-602. [PubMed]

FDG PET Appearance of “Cannonball” Pulmonary Metastases

6. Bouros D, Papadakis K, Siafakas N, Fuller AF Jr. Natural history of patients with pulmonary metastases from uterine cancer. *Cancer*. 1996 Aug 1;78(3):441-7. [PubMed]
7. Rohren EM, Turkington TG, Coleman RE. Clinical applications of PET in oncology. *Radiology*. 2004 May;231(2):305-32. Epub 2004 Mar 24. [PubMed]
8. Bakheet SM, Powe J, Ezzat A, Al Suhaibani H, Tulbah A, Rostom A. F-18 FDG whole-body positron emission tomography scan in primary breast sarcoma. *Clinical nuclear medicine*. 1998 Sep; 23(9):604-8. [PubMed]
9. Franzius C, Daldrup-Link HE, Wagner-Bohn A, Sciuk J, Heindel WL, Jürgens H, Schober O. FDG-PET for detection of recurrences from malignant primary bone tumors: comparison with conventional imaging. *Annals of oncology*. 2002 Jan; 13(1):157-60. [PubMed]
10. Hsu WH, Hsu NY, Shen YY, Yen RF, Kao CH. Differentiating solitary pulmonary metastases in patients with extrapulmonary neoplasms using FDG-PET. *Cancer investigation*. 2003; 21(1):47-52. [PubMed]
11. Khan N, Oriuchi N, Yoshizaki A, Kanuma T, Higuchi T, Endo K.. Diagnostic accuracy of FDG PET imaging for the detection of recurrent or metastatic gynecologic cancer. *Annals of nuclear medicine*, 2005 Apr; 19(2):137-45. [PubMed]
12. Nakahara T, Fujii H, Ide M, Mochizuki Y, Takahashi W, Yasuda S, Shohtsu A, Kubo A. F-18 FDG uptake in endometrial cancer. *Clinical nuclear medicine*. 2001 Jan; 26(1):82-3. [PubMed]
13. Bryant AS, Cerfolio RJ. The maximum standardized uptake values on integrated FDG-PET/CT are useful in differentiating benign from malignant pulmonary nodules. *The Annals of thoracic surgery*. 2006 Sep; 82(3):1016-20. [PubMed]
14. Grady D, Gebretsadik T, Kerlikowske K, Ernster V, Petitti D. Hormone replacement therapy and endometrial cancer risk: a meta-analysis. *Obstetrics and gynecology*. 1995 Feb;85(2):304-13. [PubMed]