

# Solitary intraosseous neurofibroma: Report of a unique case

SAGAR SATISH JANGAM, SNEHAL NILESH INGOLE, MOHAN DEVIDAS DESHPANDE, PALLAVI ADINATH RANADIVE

## Abstract

Neural tumors located centrally in jaw bones are relatively rare compared with soft tissue neurofibromas. Less than 50 cases have been reported in the literature with a predilection for mandible. This article aims to elucidate a unique case of intraosseous neurofibroma of mandible in a 62-year-old edentulous female patient associated with facial asymmetry due to the swelling extending from the right body of mandible to left body of mandible. The uniqueness of this case is related to the age and extensiveness of this lesion. A review of clinical, radiographic, histological, and immunohistochemical features, and the surgical management pertaining to this case are discussed along with a review of the literature.

**Keywords:** Intraosseous neurofibroma, mandible, unique

## Introduction

WHO defines neurofibroma as a benign tumor of peripheral nerve sheath phenotype with mixed cellular components, including Schwann cells, perineurial hybrid cells and intraneural fibroblasts. Neurofibroma is an unencapsulated neoplasm containing small nerve fascicles in an unstructured collagenous matrix and arises from Schwann cells. Neurofibroma is caused due to inactivation/mutation of NF-1 gene, which is located on the long arm of chromosome 17.<sup>[1]</sup> This gene encodes for a protein known as neurofibromin, which plays a role in cell signaling.<sup>[1]</sup>

Bruce in 1954 gave the first description of solitary neurofibroma of the oral cavity. Since then only a few (<50) cases have been documented in the literature.<sup>[2,3]</sup> Ellis *et al.* have published an excellent study covering a total 35 intraosseous benign nerve sheath tumors occurring in jaws, 23 of these cases were neurofibroma and 12 neurilemmomas.<sup>[4]</sup> In only 3 of the cases of neurofibroma was Von Recklinghausen's disease diagnosed and only 1 of these cases had multiple tumors affecting

both maxilla as well as mandible. Friedrich *et al.*, compared 22 patients with disseminated neurofibroma and 26 patients with plexiform neurofibroma affecting oral and maxillofacial region in NF-1 patients.<sup>[5,6]</sup> Das Gupta *et al.*, found that among 303 cases of benign nerve sheath tumors, about 45% involved the head and neck region, and approximately 9% occurred in the oral cavity.<sup>[7]</sup> Polak *et al.* have reported a case of solitary neurofibroma of the mandible. Their analysis of 66 cases of neurofibroma revealed the following distribution concerning the site of occurrence of neurofibroma in the head and neck area: Tongue, 12; palate, 12; mandibular ridge/vestibule, 15; maxillary ridge/vestibule, 9; buccal mucosa, 10; lip, 4; mandibular intrabony, 2; gingiva, 1; and floor of the mouth, 1.<sup>[8]</sup> Moreover, in the past literature, they found only 29 cases of solitary neurofibroma of the mandible. When solitary neurofibroma occurred in mandible there was definite female predilection (2:1) and was most frequently localized in the posterior section of the mandible.<sup>[9]</sup> The average age of occurrence is 27.5 years ranging between 14 and 45 years old.<sup>[10]</sup>

## Case Report

A 62-year-old edentulous female patient was referred with facial asymmetry and remarkable swelling extending from the right body of mandible to the left body of mandible since 7-8 months. Pain associated with the lesion was occasional and sharp in nature. Tenderness was present over the lesion along with neural deficit (paresthesia) over the lower lip. She had a history of total extraction 14 months ago because of poor periodontal health. There was no history of trauma or dental pain, and the total extraction procedure was uneventful. The patient then got her complete dentures made, which were found to be ill-fitting at the time of reporting to our institution.

Skin over the swelling was apparently not involved and showed no evidence of scars, sinus or any discharge. There was no evidence of crepitus or egg shell crackling in relation to the lesion. Notably lymphadenopathy was absent in

*Departments of Oral and Maxillofacial Surgery, Nair Hospital Dental College, Mumbai, Maharashtra, India*

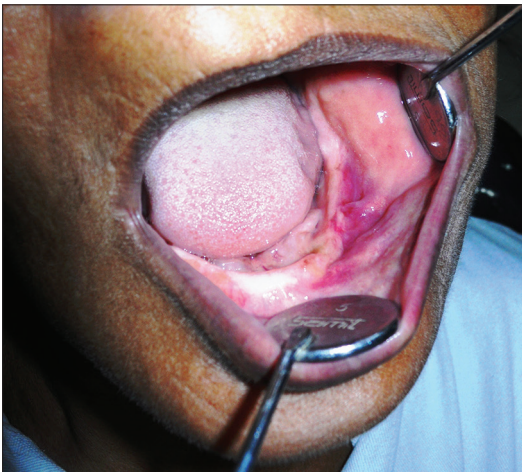**Correspondence:** Dr. Sagar Satish Jangam,  
Department of Oral and Maxillofacial Surgery, Nair  
Hospital Dental College, Dr. A. L. Nair Road, 107/1<sup>st</sup> Floor,  
Mumbai Central, Mumbai - 400 008, Maharashtra, India.  
E-mail: sagarjangam19@gmail.com

Access this article online	
Quick Response Code:	Website: <a href="http://www.contemplindent.org">www.contemplindent.org</a>
	DOI: 10.4103/0976-237X.142833

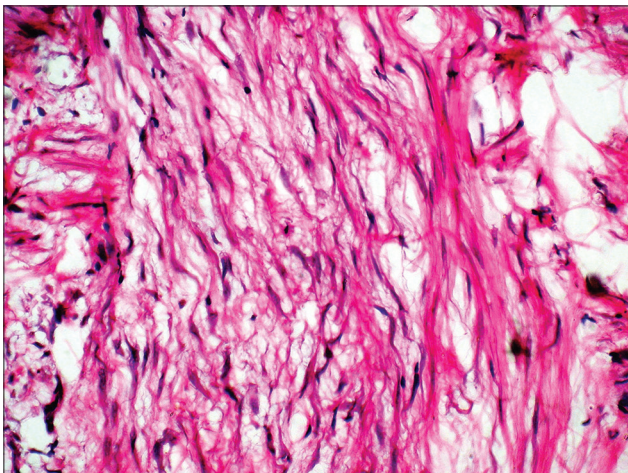
relation with the lesion. Intraorally the buccal plate was found to be expanded in anterior and left mandibular body region, which resulted in the obliteration of left buccal vestibule [Figure 1]. Floor of the mouth appeared to be raised.

The past medical history did not reveal any major illness however she was anemic and was under medication (injection vitcofol) for the same. There were no café au lait spots or subcutaneous nodules on the patient's trunk, and no evident axillary freckling noted.

Orthopantomographic findings showed well-defined radiolucency extending from right body region to left body region of the mandible [Figure 2]. Three-dimensional computed tomography revealed thinning of lower border and pathological fracture in left body region of the mandible. Ultrasonography of the local part showed a heterogeneous predominantly hypoechoic soft tissue lesion involving the right and left half of the mandible and no evidence of any vascularity was noted within it.



**Figure 1:** Intraoral view



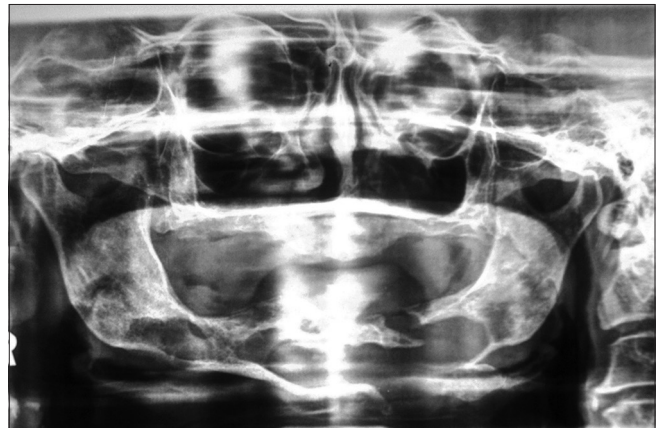
**Figure 3:** Histopathology (admixture of nerve fibres)

Aspiration of the lesion was negative and hence it was decided to perform an incision biopsy under local anesthesia. Fine needle aspiration cytology of the submandibular gland was inconclusive. Histopathology of the incisional biopsy revealed admixture of nerve fibers (mostly inferior alveolar nerve) and fibrous tissue [Figure 3]. There was no evidence of any malignancy. Immunohistochemistry of the lesion revealed positivity for anti S-100 protein antibody. Hence, the neural origin of the lesion was confirmed.

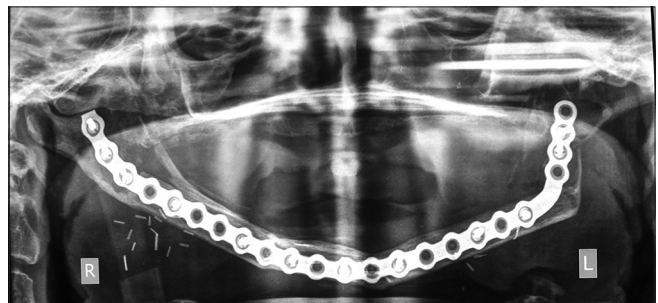
The resection of the mandible was carried out from left ramus to the right ramus region since the lesion was too extensive. A 25 hole reconstruction plate was used to stabilize the defect. Four months later the patient was taken up for secondary reconstruction using the free fibula graft (single barrel). The blood circulation was satisfactory after the operation, and the graft survived completely. Postsurgical follow-up after 2 years revealed no recurrence and no functional discrepancies were encountered [Figure 4]. The patient is now planned to be taken up for rehabilitation by placement of dental implants.

## Discussion

About 90% of the neurofibromas are associated with neurofibromatosis type 1, and hence the presence of a solitary case requires physical examination and familial history to



**Figure 2:** Preoperative radiograph (orthopantomography)



**Figure 4:** Follow-up radiograph (orthopantomography) (showing well taken up free fibula graft)

exclude Von Recklinghausens disease.<sup>[10]</sup> Our patient did not have café au lait spots on the trunk nor any other common clinical features suggestive of Von Recklinghausen's disease. Solitary neurofibroma is a benign, slow growing neoplasm, relatively circumscribed but not encapsulated, originating within a nerve and composed of Schwann cells, perineural cells and mature collagen. In our case bilateral inferior alveolar nerve involvement in the central part of the tumor and deep invasion of the tumor cells into the surrounding bone was observed on histological examination. This may be a typical finding suggesting that the tumor arises from the inferior alveolar nerve. Therefore, resection from left mandibular ramus to right mandibular ramus along with removal of the overlying mucosa because of the potentiality of the tumor invasion into the surrounding tissue was carried out. The defect so created was secondarily reconstructed with free fibula graft.

The absence of encapsulation makes complete surgical removal of a solitary neurofibroma difficult which probably accounts for some cases of recurrences.<sup>[11]</sup> Hence a more radical treatment of resection should be preferred. Also, it is necessary to rule out the differential diagnosis schwannoma and perineuroma as proposed by Ide *et al.*<sup>[12,13]</sup>

Our literature search has not revealed such extensive lesions at this specific age as mentioned in our case. Hence, this case may be considered as a unique entity.

## Conclusion

It is always important to consider solitary intraosseous neurofibroma as the first manifestation of neurofibromatosis, and a thorough clinical and radiographic follow-up is necessary since recurrence and malignant changes have been reported.<sup>[14]</sup>

## References

1. Seizinger BR, Rouleau GA, Ozelius LJ, Lane AH, Faryniarz AG, Chao MV, *et al.* Genetic linkage of von Recklinghausen neurofibromatosis to the nerve growth factor receptor gene. *Cell* 1987;49:589-94.
2. Bruce KW. Solitary neurofibroma (neurilemmoma, schwannoma) of the oral cavity. *Oral Surg Oral Med Oral Pathol* 1954;7:1150-9.
3. Dalili Z, Adham G. Intraosseous neurofibroma and concurrent involvement of the mandible, maxilla and orbit: Report of a case. *Iran J Radiol* 2012;9:45-9.
4. Ellis GL, Abrams AM, Melrose RJ. Intraosseous benign neural sheath neoplasms of the jaws. Report of seven new cases and review of the literature. *Oral Surg Oral Med Oral Pathol* 1977;44:731-43.
5. Friedrich RE, Giese M, Schmelzle R, Mautner VF, Scheuer HA. Jaw malformations plus displacement and numerical aberrations of teeth in neurofibromatosis type 1: A descriptive analysis of 48 patients based on panoramic radiographs and oral findings. *J Craniomaxillofac Surg* 2003;31:1-9.
6. Komerik N, Kirzioğlu Z, Ulu G, Kapucuoglu N. Neurofibroma of the mandible in a child with neurofibromatosis type 1. *Arch Oral Sci Res AOSR* 2011;1:95-9.
7. Das Gupta TK, Brasfield RD, Strong EW, Hajdu SI. Benign solitary schwannomas (neurilemmomas). *Cancer* 1969;24:355-66.
8. Polak M, Polak G, Brocheriou C, Vigneul J. Solitary neurofibroma of the mandible: Case report and review of the literature. *J Oral Maxillofac Surg* 1989;47:65-8.
9. Vivek N, Manikandhan R, James PC, Rajeev R. Solitary intraosseous neurofibroma of mandible. *Indian J Dent Res* 2006;17:135-8.
10. Deichler J, Martínez R, Niklander S, Seguel H, Marshall M, Esguep A. Solitary intraosseous neurofibroma of the mandible. Apropos of a case. *Med Oral Patol Oral Cir Bucal* 2011;16:e704-7.
11. Misra S, Gogri P, Misra N, Bhandari A. Recurrent neurofibroma of the orbit. *Australas Med J* 2013;6:189-91.
12. Brady GL, Schaffner DL, Joy ED Jr, Morris RL, Given KS. Solitary neurofibroma of the maxilla. *J Oral Maxillofac Surg* 1982;40:453-6.
13. Ide F, Shimoyama T, Horie N, Kusama K. Comparative ultrastructural and immunohistochemical study of perineurioma and neurofibroma of the oral mucosa. *Oral Oncol* 2004;40:948-53.
14. Cheng SF, Chen YI, Chang CY, Peng Y, Liao SL. Malignant peripheral nerve sheath tumor of the orbit: Malignant transformation from neurofibroma without neurofibromatosis. *Ophthal Plast Reconstr Surg* 2008;24:413-5.

**How to cite this article:** Jangam SS, Ingole SN, Deshpande MD, Ranadive PA. Solitary intraosseous neurofibroma: Report of a unique case. *Contemp Clin Dent* 2014;5:561-3.

**Source of Support:** Nil. **Conflict of Interest:** None declared.