

# Target Selection of Directional Lead in Patients with Parkinson's Disease

Ayaka SASAGAWA,<sup>1</sup> Rei ENATSU,<sup>1</sup> Mayumi KITAGAWA,<sup>2</sup> Takeshi MIKAMI,<sup>1</sup>  
Chie NAKAYAMA-KAMADA,<sup>1</sup> Tomoyoshi KURIBARA,<sup>1</sup> Tsukasa HIRANO,<sup>1</sup>  
Masayasu ARIHARA,<sup>1</sup> and Nobuhiro MIKUNI<sup>1</sup>

<sup>1</sup>*Department of Neurosurgery, Sapporo Medical University School of Medicine, Sapporo, Hokkaido, Japan*

<sup>2</sup>*Department of Neurology, Sapporo Teishinkai Hospital, Sapporo, Hokkaido, Japan*

## Abstract

Several structures including subthalamic nucleus (STN), the caudal zona incerta (cZI), the premidline radiation (Raprl), and the thalamic ventral intermediate nucleus (Vim) have been reported to be useful for improving symptoms of Parkinson's disease (PD). However, the effect of each target is still unclear. Therefore, we investigated each structure's effects and adverse effects using a directional lead implanted in the posterior STN adjacent to the cZI and Raprl in two patients with tremor-dominant PD. In Case 1, maximal reduction of tremor was obtained by stimulation toward the Vim, and stimulation toward the thalamic reticular nucleus (TRN) reduced verbal fluency, but did not induce dysarthria. In Case 2, maximal reduction of tremor was obtained by stimulation toward the dorsal STN and Raprl. Maximal reduction of rigidity was achieved by stimulation toward the dorsal STN, Raprl, and cZI. Bradykinesia was improved by stimulation in all directions, but dyskinesia and dysarthria were evoked by stimulation toward the dorsal STN and cZI. The directional lead may elucidate the stimulation effect of each structure and broaden target selection depending on patients' symptoms and adverse effects.

Keywords: deep brain stimulation, directional lead, Parkinson's disease, subthalamic nucleus, posterior subthalamic area

## Introduction

Deep brain stimulation (DBS) targeting the subthalamic nucleus (STN), caudal zona incerta (cZI), premidline radiation (Raprl), posterior subthalamic area (PSA), and the ventral intermediate nucleus (Vim) of the thalamus has been reported to be effective for Parkinson's disease (PD).<sup>1–5)</sup> Plaha et al.<sup>3)</sup> reported that cZI-DBS was more effective for tremor and bradykinesia than STN-DBS, whereas Mostofi et al.<sup>6)</sup> found no significant difference between cZI-DBS and STN-DBS in improvement in parkinsonian motor symptoms. In these studies, DBS leads were implanted using an image-verified implantable guide tube/stylette technique; however, the efficacy

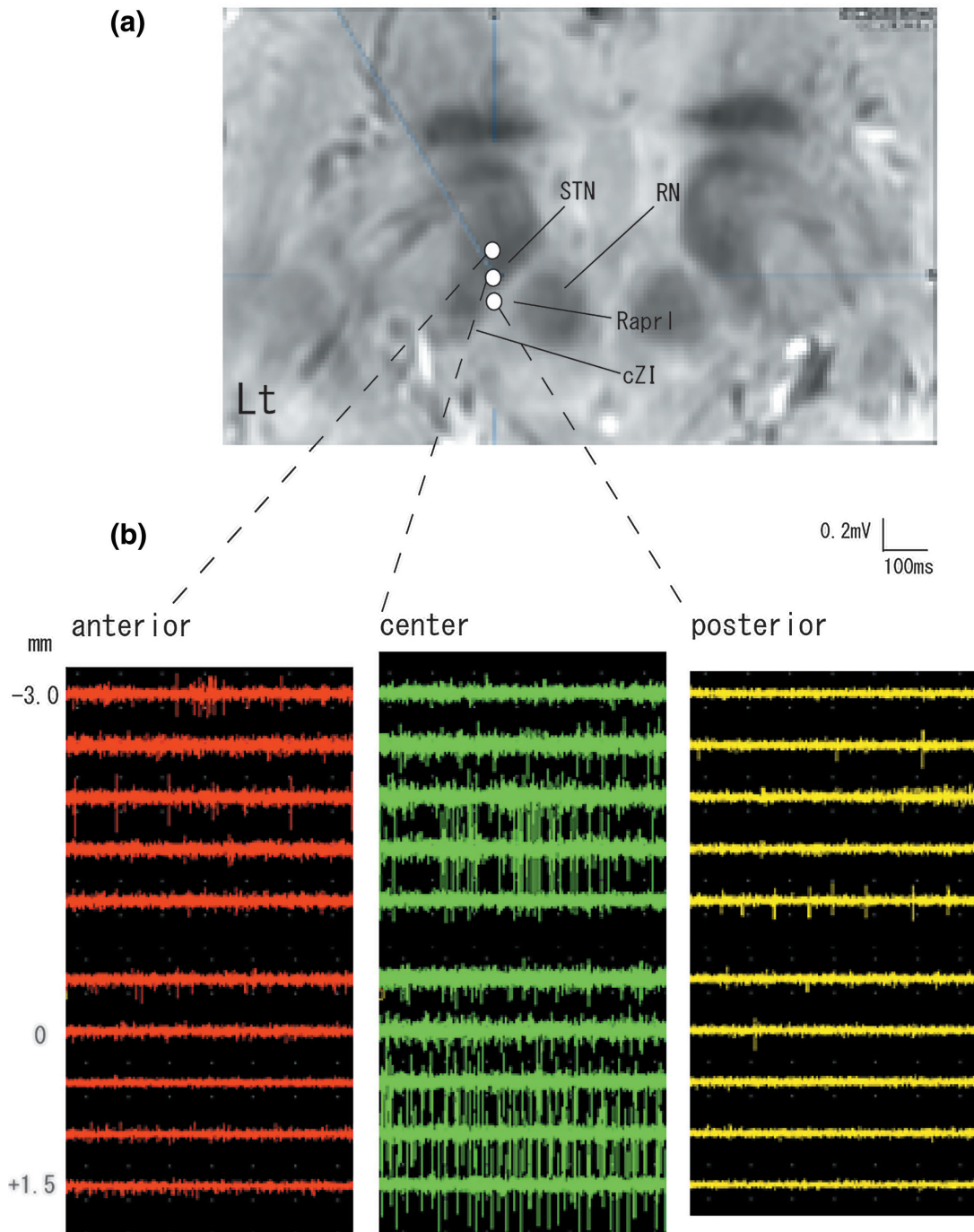
of cZI-DBS was not compared with STN-DBS in individual patients. Recently, directional leads have been developed to precisely control the volume of tissue activated (VTA) during DBS, and allow stimulation to be directed toward the functional target and away from side-effect structures. Therefore, we investigated direction-related improvement in parkinsonian symptoms (tremor, rigidity, and bradykinesia) and adverse effects using a directional lead implanted in the posterior STN adjacent to the cZI and Raprl in two patients with tremor-dominant PD.

## Case Reports

Posterior STN/cZI/Raprl-DBS (13 mm lateral, 6 mm posterior, and 4 mm inferior to the mid-commissure point, 30° relative to the midline plane, 60° relative to the AC-PC plane) was planned using the magnetic resonance imaging/computed tomography (MRI/CT) imaging fusion software BrainLAB system (Brainlab, Feldkirchen, Germany) (Fig. 1a). Three microelectrodes

Received June 29, 2020; Accepted September 2, 2020

Copyright© 2020 by The Japan Neurosurgical Society This work is licensed under a Creative Commons Attribution-NonCommercial-NoDerivatives International License.



**Fig. 1** (a) The planning and (b) microrecording of posterior STN/cZI/Raprl-DBS. The target was set to the border of posterior STN and the PSA. Three microelectrodes were simultaneously placed in an array with central, anterior, and posterior positions placed 2 mm apart to delineate STN and PSA. cZI: caudal zona incerta, PSA: posterior subthalamic area, Raprl: prelemniscal radiation, RN: red nucleus, STN: subthalamic nucleus.

were simultaneously placed in an array with central, anterior, and posterior positions placed 2 mm apart to delineate STN and PSA (Fig. 1b). After microrecording through the tracts, intraoperative stimulation was performed to confirm the therapeutic effects and check for adverse responses. Thereafter, a Vercise™

DBS Directional Lead (Boston Scientific, Marlborough, MA, USA) was implanted in the posterior STN. The marker of electrode position was checked with intraoperative fluoroscopy to confirm the direction of electrodes. One month after surgery, high-resolution volumetric CT was performed and

coordinated with pre-surgical MRI to provide a correlation each contact and the corresponding structure. The locational relationship between each contact and dentato-ruburo-thalamic tract (DRT) was also assessed using a pre-surgical diffusion tensor image of DRT.<sup>7)</sup> Thereafter, the threshold for complete disappearance of parkinsonian motor symptoms (tremor, rigidity, and bradykinesia) and the threshold for appearance of adverse effects (dyskinesia, paresthesia, dysarthria, and reduced verbal fluency) were assessed at each electrode separately with steps in stimulation amplitude of 1–3 mA. Pulse width was set to 60  $\mu$ s and stimulation frequency to 130 Hz. Electrode impedances were ensured to be below 2000 Ohms.

### Case 1

A 59-year-old man with PD presented with resting tremor of right hand for 2 years. He was referred to our department to receive surgical treatment because of the worsening and lack of control of his postural tremor. His preoperative medication was levodopa (equivalent daily dose 300 mg). His preoperative Movement Disorder Society-unified Parkinson's Disease Rating Scale (MDS-UPDRS) part 3 score was 11 at medication off. A left posterior STN/cZI/Raprl-DBS (13 mm lateral, 4 mm posterior, and 4 mm inferior to the mid-commissure point, 23° relative to the midline plane, 65° relative to the AC-PC plane) was planned using the MRI/CT imaging fusion software BrainLAB system (Brainlab, Feldkirchen, Germany). Three microelectrodes were simultaneously placed in an array with central, anterior, and posterior positions placed 2 mm apart. After microrecording through the tracts, intraoperative stimulation was performed to confirm the therapeutic effects and to check for adverse responses. Thereafter, a Vercise™ DBS Directional Lead was implanted in the posterior STN. Postoperatively, his right-sided tremor disappeared. One month after surgery, the maximal reduction of tremor was obtained by stimulation toward Vim (directions 5 and 6 in Fig. 2a, threshold: 1–2 mA). Stimulation toward the thalamic reticular nucleus (TRN) reduced verbal fluency, but did not induce dysarthria (directions 4 and 5 in Fig. 2b, threshold: 1–2 mA). The postoperative MDS-UPDRS part 3 score at DBS on was 2 (stimulation conditions: ring mode [directions 1–2–3], 60  $\mu$ s, 130 Hz, 2.0 mA).


### Case 2

A 59-year-old woman with PD presented right-side akinesia and resting tremor of right hand for 6 years. She had received medical control, but she reported wearing-off and early-morning dystonia. She was referred to our department to receive surgical

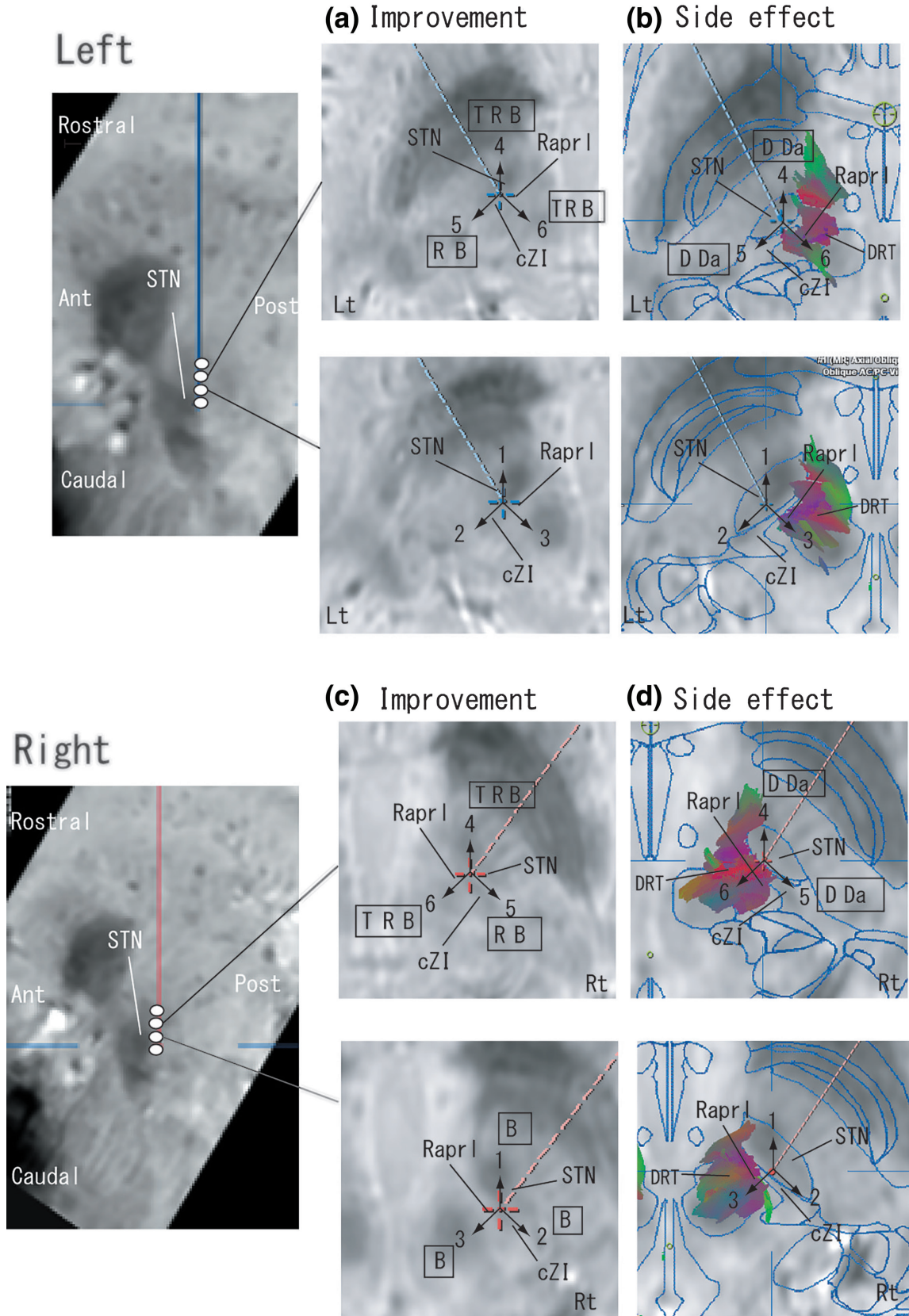
treatment because of worsening of tremors and freezing of gait symptoms. Her preoperative medications were as follows: L-dopa/carbidopa 400 mg, entacapone, cabergoline, istradefylline, rasegiline, and trihexyphenidyl. Her preoperative MDS-UPDRS part 3 score was 11/22 (on/off). Right posterior STN/cZI/Raprl-DBS (12 mm lateral, 3 mm posterior, and 5 mm inferior to the mid-commissure point, 30° relative to the midline plane, 55° relative to the AC-PC plane) and left posterior STN/cZI/Raprl-DBS (12 mm lateral, 3 mm posterior, and 5 mm inferior to the mid-commissure point, 22° relative to the midline plane, 56° relative to the AC-PC plane) were planned. In both sides, three microelectrodes were simultaneously placed in an array with central, anterior, and posterior positions placed 2 mm apart. After microrecording through the tract, intraoperative stimulation was performed to confirm the therapeutic effects and to check for adverse responses. Thereafter, a Vercise™ DBS Directional Lead was implanted in the posterior STN. One month after surgery, maximal reduction of tremor was obtained by stimulation toward the dorsal STN and Raprl (directions 4 and 6 in Figs. 3a and 3c, threshold: <1 mA). Maximal reduction of rigidity was achieved by stimulation toward the dorsal STN, Raprl and cZI (directions 4, 5, and 6 in Figs. 3a and 3c, threshold: <1 mA). Bradykinesia was improved by stimulation in all directions (directions 1–6 in Figs. 3a and 3c, threshold: <1 mA), but dyskinesia was evoked by stimulation toward the dorsal STN and cZI (directions 4 and 5 in Figs. 3b and 3d, threshold: 1–2 mA). Dysarthria occurred with stimulation toward the dorsal STN and cZI (directions 4 and 5 in Figs. 3b and 3d, threshold: 1–2 mA). The postoperative MDS-UPDRS part 3 score at DBS on was 1 (stimulation conditions: ring mode [directions 4–5–6] at the left side, ring mode [directions 4–5–6] at the right side, and stimulus intensity was 60  $\mu$ s, 130 Hz, 1.5 mA both sides).

## Discussion

In our results, the superior part of STN improved parkinsonian symptoms and each direction had a specific improvement and adverse effects. There have been several studies evaluating the relationship between clinical outcomes and anatomical location of contacts of DBS electrodes. According to these studies, maximal reduction of tremor is related to the posterolateral STN,<sup>8,9)</sup> the pallidothalamic fibers (Forel H1/ZI),<sup>10)</sup> and the dentatorubrothalamic fibers. Improvement in rigidity is associated with the superior STN and pallidothalamic fibers.<sup>9,10)</sup> Improvement in bradykinesia has been obtained by stimulation within the dorsolateral motor region of the STN but



**Fig. 2** Postoperative electrode location, stimulation effects (a) and side effect (b) of each direction in Case 1 (Numbers 1–6 indicate each direction). Sagittal (left column) and axial images (middle and right column) are shown. Left side images are fused with the atlases and tractographies of DRT. DRT: dentato-ruburo-thalamic tract, TRN: the thalamic reticular nucleus, Vim: the ventral intermediate nucleus of the thalamus.



**Fig. 3** Postoperative electrode location, stimulation effects (left side: [a], right side: [c]) and side effect (left side: [b], right side: [d]) of each direction in Case 2.

not with stimulation beyond the STN border.<sup>9,10</sup> Stimulation of the adjacent internal capsule may be related to aggravation of bradykinesia.<sup>11</sup> cZI-DBS<sup>3</sup> and PSA-DBS<sup>2,5</sup> can improve bradykinesia. cZI is anatomically located behind STN and Raprl is located medial to cZI. Raprl includes the cerebello-thalamic cortical fibers through Vim<sup>5</sup> and cZI has connections with the various brainstem nuclei, the basal ganglia, and the thalamus.<sup>2</sup> The stimulation of these fibers is thought to play an important role in improvement of parkinsonian symptoms.

Bouthour et al. reported that dyskinesia-inducing contacts were located ventrally within the dorso-lateral motor STN.<sup>12</sup> Lalys et al.<sup>13</sup> reported the deterioration of categorical fluency after stimulation in the postero-superior STN, whereas Mikos et al.<sup>14</sup> reported that activation in the ventral associative region resulted in negative effects on verbal fluency performance. Previous reports suggest that DRT relate not only to dysarthria but also reduced verbal fluency during STN-DBS,<sup>15</sup> cZI-DBS,<sup>16</sup> or Vim-DBS.<sup>17</sup> However, the present results that the stimulation toward the opposite side of DRT induced verbal fluency decline seem to be inconsistent with previous results, and indicate the influence of TRN, which might play a role of hub in the thalamus to modulates information flow from the thalamus to the cortex.<sup>18</sup> We could not achieve a conclusion due to the small sample size.

Some groups have developed a methodology to predict the VTA by DBS on a patient-specific basis,<sup>19</sup> but could not efficiently explain the variability of the effects of DBS on a per-patient basis.<sup>20</sup> Our method enables the stimulation of the STN, cZI, Raprl, and Vim, and selects the best target for the individual patient. Further investigations are needed to accumulate data to confirm the stimulation effect of each anatomical structure.

## Conflict of Interest Disclosure

No disclosures to declare.

## References

- 1) Koller WC, Pahwa R, Lyons KE, Albanese A: Surgical treatment of Parkinson's disease. *J Neurol Sci* 167: 1–10, 1999
- 2) Kitagawa M, Murata J, Uesugi H, et al.: Two-year follow-up of chronic stimulation of the posterior subthalamic white matter for tremor-dominant Parkinson's disease. *Neurosurgery* 56: 281–289, 2005
- 3) Plaha P, Ben-Shlomo Y, Patel NK, Gill SS: Stimulation of the caudal zona incerta is superior to stimulation of the subthalamic nucleus in improving contralateral parkinsonism. *Brain* 129: 1732–1747, 2006
- 4) Blomstedt P, Fytagoridis A, Åström M, Linder J, Forsgren L, Hariz MI: Unilateral caudal zona incerta deep brain stimulation for Parkinsonian tremor. *Parkinsonism Relat Disord* 18: 1062–1066, 2012
- 5) Velasco F, Carrillo-Ruiz JD, Salcido V, Castro G, Soto J, Velasco AL: Unilateral stimulation of prelemniscal radiations for the treatment of acral symptoms of Parkinson's disease: long-term results. *Neuromodulation* 19: 357–364, 2016
- 6) Mostofi A, Evans JM, Partington-Smith L, Yu K, Chen C, Silverdale MA: Outcomes from deep brain stimulation targeting subthalamic nucleus and caudal zona incerta for Parkinson's disease. *NPJ Parkinsons Dis* 5: 17, 2019
- 7) Morishita T, Higuchi MA, Kobayashi H, Abe H, Higashi T, Inoue T: A retrospective evaluation of thalamic targeting for tremor deep brain stimulation using high-resolution anatomical imaging with supplementary fiber tractography. *J Neurol Sci* 398: 148–156, 2019
- 8) Eisenstein SA, Koller JM, Black KD, et al.: Functional anatomy of subthalamic nucleus stimulation in Parkinson disease. *Ann Neurol* 76: 279–295, 2014
- 9) Akram H, Sotiropoulos SN, Jbabdi S, et al.: Subthalamic deep brain stimulation sweet spots and hyperdirect cortical connectivity in Parkinson's disease. *Neuroimage* 158: 332–345, 2017
- 10) Hilliard JD, Frysinger RC, Elias WJ: Effective subthalamic nucleus deep brain stimulation sites may differ for tremor, bradykinesia and gait disturbances in Parkinson's disease. *Stereotact Funct Neurosurg* 89: 357–364, 2011
- 11) Xu W, Miocinovic S, Zhang J, Baker KB, McIntyre CC, Vitek JL: Dissociation of motor symptoms during deep brain stimulation of the subthalamic nucleus in the region of the internal capsule. *Exp Neurol* 228: 294–297, 2011
- 12) Bouthour W, Béreau M, Kibleur A, et al.: Dyskinesia-inducing lead contacts optimize outcome of subthalamic stimulation in Parkinson's disease. *Mov Disord* 34: 1728–1734, 2019
- 13) Lalys F, Haegelen C, Mehri M, Drapier S, Vérin M, Jannin P.: Anatomical atlases correlate clinical data and electrode contact coordinates: application to subthalamic deep brain stimulation. *J Neurosci Methods* 212: 297–307, 2013
- 14) Mikos A, Bowers D, Noecker AM, et al.: Patient-specific analysis of the relationship between the volume of tissue activated during DBS and verbal fluency. *Neuroimage* 54: S238–246, 2011
- 15) Fenoy AJ, McHenry MA, Schiess MC: Speech changes induced by deep brain stimulation of the subthalamic nucleus in Parkinson disease: involvement of the dentatorubrothalamic tract. *J Neurosurg* 126: 2017–2027, 2017
- 16) Fytagoridis A, Sjöberg RL, Åström M, Fredricks A, Nyberg L, Blomstedt P: Effects of deep brain stimulation in the caudal zona incerta on verbal fluency. *Stereotact Funct Neurosurg* 91: 24–29, 2013

- 17) Ehlen F, Vonberg I, Tiedt HO, et al: Thalamic deep brain stimulation decelerates automatic lexical activation. *Brain Cogn* 111: 34–43, 2017
- 18) Takata N: Thalamic reticular nucleus in the thalamo-cortical loop. *Neurosci Res* 156: 32–40, 2020
- 19) Butson CR, Cooper SE, Henderson JM, McIntyre CC: Patient-specific analysis of the volume of tissue activated during deep brain stimulation. *Neuroimage* 34: 661–670, 2007
- 20) Moks CB, Butson CR, Walter BL, Vitek JL, McIntyre CC: Deep brain stimulation activation volumes and their association with neurophysiological mapping and therapeutic outcomes. *J Neurol Neurosurg Psychiatry* 80: 659–666, 2009

---

Corresponding author: Rei Enatsu, MD, PhD  
Department of Neurosurgery, Sapporo Medical University, South 1 West 16, Chuo-ku, Sapporo, Hokkaido 060-8543, Japan.  
*e-mail*: enatsur@sapmed.ac.jp