


Standard cross-linking versus photorefractive keratectomy combined with accelerated cross-linking for keratoconus management: a comparative study

Mohammed Iqbal,¹  Ahmed Elmassry,² Ahmed Tawfik,³ Mervat Elgharieb,⁴ Khaled Nagy,⁵ Ashraf Soliman,⁶ Hisham Saad,⁵ Tarek Tawfik,⁷ Osama Ali,¹ Ahmed Gad,¹ Islam El Saman,¹ Alaa Radwan,⁸ Hosam Elzembely,⁹ Amin Abou Ali¹ and Omar Fawzy¹⁰

¹Department of Ophthalmology, Faculty of Medicine, Sohag University, Sohag, Egypt

²Department of Ophthalmology, Faculty of Medicine, Alexandria University, Alexandria, Egypt

³Department of Ophthalmology, Faculty of Medicine, Zagazig University, Zagazig, Egypt

⁴Department of Ophthalmology, Faculty of Medicine, Suez Canal University, Suez, Egypt

⁵Department of Ophthalmology, Faculty of Medicine, Tanta University, Tanta, Egypt

⁶Department of Ophthalmology, Faculty of Medicine, Ain Shams University, Cairo, Egypt

⁷Department of Ophthalmology, Faculty of Medicine, Benha University, Benha, Egypt

⁸Department of Ophthalmology, International Eye Clinic, Cotoba EYE Center, Cairo, Egypt

⁹Department of Ophthalmology, Faculty of Medicine, Minia University, Minia, Egypt

¹⁰Department of Ophthalmology, Sohag Eye Hospital, Sohag, Egypt

ABSTRACT.

Purpose: To compare the safety and efficacy of standard 30 min epithelium-off cross-linking (CXL) versus photorefractive keratectomy (PRK) combined with accelerated epithelium-off cross-linking (AXL) for the treatment of progressive keratoconus (CXL-Plus).

Methods: This study was a prospective multicentre comparative clinical study. A total of 125 eyes of 75 patients with grade 1 keratoconus and documented progression were divided into two groups. Group A included 58 eyes treated with standard CXL. Group B included 67 eyes treated with combined PRK and AXL. The recorded data included UDVA, CDVA, subjective and objective refraction, keratometry and pachymetry using corneal topographies preoperatively and postoperatively at 3, 6, 12 and 24 months of follow-up.

Results: In group A, at 24 months of UDVA and CDVA were improved from 1.12 ± 0.38 and 0.58 ± 0.42 to 0.66 ± 0.20 and 0.20 ± 0.12 (LogMAR \pm SD). The spherical equivalent was reduced from 4.03 ± 1.18 to 1.78 ± 1.04 D. The cylinder reduction was 0.32 ± 0.19 D. In group B, at 24 months of UDVA and CDVA were improved from 1.26 ± 0.52 and 0.68 ± 0.36 to 0.58 ± 0.28 and 0.20 ± 0.16 (LogMAR \pm SD). The spherical equivalent was reduced from 4.23 ± 0.95 to 1.92 ± 0.74 D. The cylinder reduction was ± 1.76 D.

Conclusion: Surprisingly, standard CXL showed close results to CXL-Plus at the 24th follow-up month. Standard CXL acted as a stabilizing procedure associated with a late myopic component reduction. CXL-Plus acted as a refractive and stabilizing procedure with an early effect on both the myopic and the astigmatic component but no later improvements. Standard CXL seems to be more powerful than AXL in its long-term effect. Therefore, in the future, we want to test the combination of PRK with standard CXL.

Key words: CXL-Plus – ectasia – epithelium-off CXL – keratoconus – PRK – standard CXL

Acta Ophthalmol. 2019; 97: e623–e631

© 2018 The Authors. Acta Ophthalmologica published by John Wiley & Sons Ltd on behalf of Acta Ophthalmologica Scandinavica Foundation.

This is an open access article under the terms of the Creative Commons Attribution-NonCommercial-NoDerivs License, which permits use and distribution in any medium, provided the original work is properly cited, the use is non-commercial and no modifications or adaptations are made.

doi: 10.1111/aos.13986

Introduction

Fifteen years ago, standard corneal cross-linking (CXL) was introduced as a successful treatment for the stop of corneal ectasia in progressive keratoconus by Wollensak et al. (2003) in Dresden, Germany. In the meantime, accelerated epithelium-off cross-linking (AXL) to reduce the treatment time has been developed and its combination with refractive procedures such as PRK and intracorneal ring segments (ICRS) to also reduce the refractive error of keratoconus has been promoted (Kanellopoulos & Binder 2007; Kanellopoulos 2009; Kanellopoulos & Asimellis 2014; Kymionis et al. 2014; Saleem et al. 2018). This combination is sometimes called cross-linking plus (CXL-Plus).

Over the last decade, the so-called Athens Protocol was used by many authors and surgeons as a documented protocol to treat progressive keratoconus. The Athens Protocol includes the use of both wavefront topography-guided PRK with epithelium-off AXL in the same session as a both therapeutic and refractive treatment of keratoconus. The protocol allows a maximum ablation of 50 μ m of the stromal

corneal tissue to correct up to 2.5 D of the spherical equivalent. Furthermore, it was designed for the correction of anterior surface irregularities thus improving the overall postoperative refractive and topographic status. Cross-linking plus (CXL-Plus) describes the combination of CXL and a refractive procedure promoted (Kanellopoulos & Binder 2007; Kanellopoulos 2009; Kanellopoulos & Asimellis 2014).

The main purpose of the present study was to compare the efficacy in terms of refractive and visual outcomes of the standard CXL treatment of progressive keratoconus versus photorefractive keratectomy (PRK) combined with accelerated epithelium-off cross-linking (AXL).

Patients and methods

Patients

This study was designed as a prospective comparative multicenter clinical study. This study was carried out in five universities in Egypt including Sohag, Alexandria, Zagazig, Suez Canal and Ain Shams universities. This study gained the approval of the high ethical committee in Sohag University Hospital and followed the rules of the Declaration of Helsinki. The nature of the KC disease, the proposed surgical treatment and the possible postoperative complications were fully explained to all patients preoperatively. Furthermore, all patients signed written consents before surgery approving the surgical procedures and approving the use of their medical data in scientific research work. Only cases with documented keratoconus progression were treated (Galvis et al. 2017).

This study included 125 eyes of 75 patients (32 males and 43 females). All eyes included in this study had fulfilled the following inclusion criteria: all eyes with grade 1 (early KC) according to Amsler–Krumeich classification (the central corneal thickness at the thinnest location $>400 \mu\text{m}$, the spherical equivalent including both myopic and astigmatic KC components $<5 \text{ D}$ while the mean k readings $<48 \text{ D}$), all eyes had documented active pathological progression of KC (by documenting 2 or more specific parameters including increase in the k_{max} more than 1 D,

increase in the SE more than 0.5 D, decrease in the corneal thickness more than 2% and increase in the k readings on posterior corneal surface), all eyes were operated by one of the authors (M.I.) and completed 24 months of follow-up period.

Preoperative and postoperative assessment

The eyes included in this study were divided into two groups. Group A included 58 eyes of 33 patients (46.4% of the study eyes), and they were subjected to standard 30 min epithelium-off CXL (Wollensak et al. 2003). The age of the patients in group A ranged from 14 years to 27 years old with a mean age of 20.65 ± 6.24 (mean \pm SD).

Group B included 67 eyes of 42 patients (53.6% of the study eyes), and they were subjected to CXL-Plus combining standard PRK with accelerated epithelium-off CXL (AXL). The age of the patients in group B ranged from 14 years to 28 years old with a mean age of 21.37 ± 6.92 (mean \pm SD).

The main objectives of this study were to compare between the results of the standard CXL alone ('Standard Dresden Protocol') versus the results of combined standard PRK with AXL ('Athens Protocol'). All keratoconic eyes were examined preoperatively and postoperatively to collect the preoperative data that recorded the visual status including both uncorrected distance visual acuity (UDVA) and corrected distance visual acuity (CDVA), refractive status mainly the subjective refraction including both myopic and astigmatic components and spherical equivalent, topographic status including central corneal thickness at the thinnest location, k readings on the anterior and posterior corneal surfaces and back surface elevation. The investigative device for the topographic and tomographic parameters was a CSO SIRIUS Topographer (CSO, Firenze, Italy).

Surgical procedure

The surgical devices used in this study included the Opto XLink-corneal cross-linking System (Opto Global Pty Ltd., Adelaide, Australia), the KXL Crosslinking System (Avedro Inc., Burlington, MA, USA) and the

excimer laser VISX STAR S4 IR™ (Abbott Laboratories, Lake Bluff, IL, USA).

Group A

The surgical procedure in this group was performed according to the Standard Dresden Protocol (Wollensak et al. 2003) using the Opto XLink-Corneal Crosslinking System (Opto Global Pty Ltd.) with continuous irradiation mode. The first step in this procedure was to use an 8 mm zone marker to mark the corneal area to be de-epithelialized. Then, a blunt tip spatula was used to remove the corneal epithelium within the 8 mm marked zone. 0.1% riboflavin with dextran solution (RICROLIN®, Sooft Italia S.p.A., Montegiorgio FM, Italy) was applied every 3 min for 30 min thus allowing corneal saturation with the photosensitizer riboflavin before UVA irradiation. Adjustment of the parameters of the Opto XLink-corneal crosslinking system was performed including the following parameters: power 1.50 mW, UVA irradiance 2.984 mW/cm^2 , UVA dose 5.371 J/cm^2 and the duration 30 min. The next step was the irradiation of the riboflavin-saturated cornea with UVA for 30 min with continued riboflavin installation every 3 min during the UV irradiation time. At the end of the procedure, a bandage contact lens (CooperVision, The Cooper Companies, Inc., Pleasanton, CA, USA) was placed onto the cornea. Finally, installation of topical antibiotic eye drops (Zymar, gatifloxacin 0.3%, Allergan, Inc, Jersey City, NJ, USA) and topical steroid eye drops (Pred Forte, prednisolone acetate 1%, Allergan, Inc.) was performed.

Group B

All eyes in group B were treated with CXL-Plus that included non-topography-guided PRK followed immediately by AXL in the same session. The Standard Nomogram (Maloney Vision Institute VISX S4) was used to perform PRK with a maximum tissue ablation of $50 \mu\text{m}$. Figure 1 shows the steps of CXL-Plus in the right eye of one patient in group B: Centration of the reticle onto the pupil was performed and followed by epithelial removal of the central 6 mm zone via the trans-epithelial treatment mode (Fig. 1A). A hockey knife was used to remove additional corneal epithelium

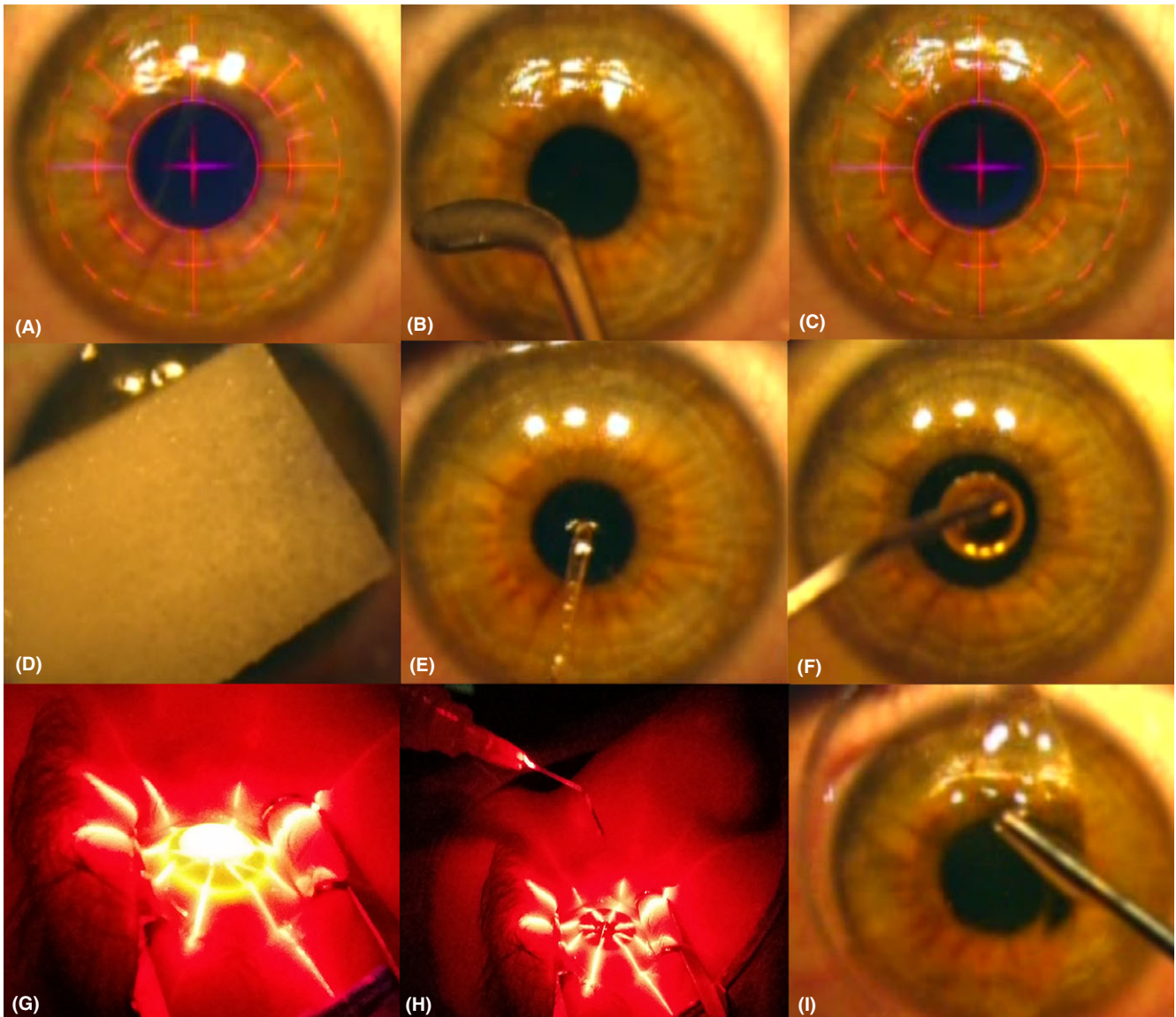


Fig. 1. The CXL-Plus steps (Group B); A: The reticle was centred over the pupillary entrance to be followed immediately by epithelial treatment that included epithelial removal within a 6 mm zone using the trans-epithelial ablation mode, B: Using a hockey knife to widen the de-epithelialized corneal zone to 8 mm, C: Standard PRK for ablation of the corneal stromal tissues, D: A K-Sponge triangular spear saturated with 0.02% MMC solution was applied onto the cornea, e: washing the corneal surface with careful MMC solution removal, F: Installation of 0.1% of riboflavin onto the cornea, G: Pulsed mode of the accelerated epithelium of CXL, H: Washing the corneal surface with BSS in between the UVA pulses, I: Applying of the bandage contact lens onto the cornea.

to achieve an 8 mm de-epithelialized corneal zone (Fig. 1B). Corneal ablation of the stromal tissue via standard PRK was performed (Fig. 1C). After PRK, a disposable K-Sponge triangular spear (hydrocellulose sponge, Katena Products, New Jersey, USA) was soaked with 0.02% Mitomycin C solution (MMC, Cadila Healthcare Pharmaceutical, Mumbai, India) was placed onto the de-epithelialized corneal surface for 20 seconds (Fig. 1D). Balanced salt solution (BSS® Sterile Irrigating isotonic Solution, Alcon Laboratories, Inc., Fort Worth, TX,

USA) was used to irrigate the de-epithelialized corneal surface to remove any remaining MMC solution from the corneal surface (Fig. 1E). Installation of 0.1% riboflavin, saline, hydroxypropyl methylcellulose HPMC (VibeX Rapid™, Avedro Inc.) onto the de-epithelialized 8 mm corneal zone was performed as the first step in the consecutive AXL (Fig. 1F). The frequency of the riboflavin installation was every 2 min with a total soaking time of 10 min. Pulsed UVA irradiation of the cornea was performed along 8 min so that the total treatment

time including both the soaking time and the corneal irradiation time was 18 min. The pulsed mode of UVA irradiation included one second on one second off UVA as 4 min of UV irradiation time was the actual target of corneal irradiation. The AXL was performed using the Avedro Nomogram which included the use of a power of 30 mW/cm² to deliver a total energy of 7.2 J/cm². (Fig. 1G). Irrigation of the corneal surface with BSS was performed between the UVA pulses (Fig. 1H). At the end of procedure, a bandage

contact lens was applied onto the cornea (Fig. 1I) followed by installation of topical antibiotic and steroid eye drops (gatifloxacin 0.3% and prednisolone acetate 1%).

Postoperative treatment and follow-up

Both groups received the same postoperative treatment that continued till the end of the 4th postoperative week. Topical therapy included three types of eye drops, gatifloxacin 0.3%, prednisolone acetate 1% and sodium hyaluronate 0.15% eye drops (Hyabak, THEA laboratories, Clermont-Ferrand, France). The topical prednisolone acetate 1% and sodium hyaluronate 0.15% were installed five times daily in the first postoperative week and then tapered gradually.

All patients were examined at the second and fourth postoperative days to check for complete regeneration of the corneal epithelium after which the bandage contact lens was removed. Then the patient was followed up at the end of the first, second, third and fourth postoperative weeks. During the follow-up period, all patients were examined at 3, 6, 12 and 24 months postoperatively.

Regarding corneal haze, it was graded according to a scale from 0–4. Scale 0 means clear cornea, scale 0.5 means faint haze, scale 1 means mild haze seen only with tangential illumination, scale 2 means faint opacity seen with direct illumination, scale 3 means opacity obscuring iris details while scale 4 means opacity seen without slit-lamp (Kim et al. 2004).

Statistical analysis

The statistical package for social sciences software (SPSS version 22 for Windows, SPSS Inc., Chicago, IL, USA) was used for the analysis of the study data. Median, mean and standard deviation were used to describe the quantitative data. Qualitative data were presented as number and percentage. For non-normally distributed data, Wilcoxon test was used. For a normally distributed data, paired sample T-test was used. The postoperative data results were considered statistically significant if p value was <0.05 .

Results

This study included surgical intervention in 125 keratoconic eyes of 75 patients.

The study patients included 32 males and 43 females (ratio 1:1.34). Fifty eight eyes (46.4%) of 33 patients represented group A while 67 eyes (53.6%) of 42 patients represented group B.

Central corneal thickness

Regarding the corneal thickness at the thinnest location (CCT), both groups had different postoperative courses of corneal pachymetry pathway (Table 1). In group A, CCT showed a slowly progressive slight thinning from the preoperative CCT of $459.5 \pm 29.7 \mu\text{m}$ to $407.4 \pm 26.0 \mu\text{m}$ at 24 months. In group B, the CCT had a different postoperative pathway as it showed an immediate reduction in the CCT by the action of the PRK-induced stromal ablation effect after which CCT remained stable along the 2 years of follow-up period with only minor changes. The immediate postoperative reduction by PRK ablation was from $486.2 \pm 33.5 \mu\text{m}$ preoperatively (range 437–503) to reach $421.2 \pm 27.1 \mu\text{m}$ (range 392–481) at the end of the 1st postoperative month.

Topographic outcome analysis

Regarding the keratometry readings (k readings) on the anterior corneal surface, both groups showed different pathways in the postoperative reduction in the k readings (Tables 1 and 2, Fig. 2). The major difference between the postoperative courses in both groups was the nature of the postoperative improvement in relation to time. In group A, the improvement in the k readings was both slow and progressive while in group B, the improvement in the k readings was immediate and approximately stable over time in most cases.

In group A, the preoperative $k1$, $k2$, k average and k reading at the apex (k_{max}) were 46.43 ± 0.78 , 48.43 ± 1.37 , 47.27 ± 1.13 and 48.64 ± 1.34 D (mean \pm SD), respectively. At the end of the 24-month follow-up period, the postoperative $k1$, $k2$, k average and k_{max} readings were significantly reduced to 44.43 ± 0.75 , 46.01 ± 0.76 , 45.15 ± 0.73 and 46.61 ± 1.11 D (mean \pm SD), respectively (p value <0.001). The preoperative $k2$ and k_{max} ranges were 44.23–50.11 and 44.50–50.21 D, respectively, while the postoperative $k2$ and k_{max} ranges were 42.51–48.20 and

43.53–48.62 D, respectively, at the end of the 24 follow-up months.

In group B, the preoperative $k1$, $k2$, k average and k_{max} readings were 45.65 ± 1.16 , 49.22 ± 0.39 , 47.51 ± 0.78 and 49.30 ± 0.49 D (mean \pm SD), respectively. At the end of the 24 months of follow-up period, the preoperative $k1$, $k2$, k average and k_{max} readings were reduced to 44.80 ± 0.52 , 47.05 ± 0.41 , 46.07 ± 0.59 and 47.07 ± 0.56 D (mean \pm SD), respectively (p value <0.001). The preoperative $k2$ and k_{max} ranges were 47.91–50.24 and 46.31–50.25 D, respectively, while the postoperative $k2$ and k_{max} ranges were 46.15–48.72 and 45.13–48.32 D, respectively, at the end of the 24 follow-up months.

While in group B the reduction in k_{max} was present from the first month, it started at 6 months and continued to 24 months in group A (Fig. 2).

Refractive outcomes analysis

In group A, there was a statistically highly significant reduction in the myopic component that was reduced from 3.21 ± 1.09 to 1.17 ± 0.73 D (mean \pm SD) postoperatively at the end of the 24th month of follow-up period (p value <0.001) (Tables 3 and 4). This excellent improvement in the myopic component in the keratoconic eyes in group A was attributed to the remarkable sphere reduction achieved by the standard CXL that was 1.97 ± 0.62 D at the 24th postoperative month (p value <0.001). The slight postoperative cylinder reduction of 0.32 ± 0.19 D at the end of the 24th postoperative month was statistically insignificant (p value <0.1). The postoperative spherical equivalent reduction in group A was by 2.15 ± 0.67 D at the end of the 24th postoperative month (p value <0.001).

In group B, both myopic and astigmatic components in group B showed a remarkable early postoperative improvement. The preoperative myopic component was reduced from 2.89 ± 1.05 to 1.38 ± 0.57 D postoperatively (p value <0.05). The preoperative astigmatic component showed a postoperative statistically highly significant reduction from 3.07 ± 1.26 to 1.43 ± 0.62 D (p value <0.001). Remarkably there was a great reduction in the astigmatic component of KC more than the reduction in the

Table 1. Summary of the preoperative and postoperative corneal topographic parameters in Group A

Parameters	Group A						p value
	Preoperative Mean ± SD	1st month Mean ± SD	6th month Mean ± SD	12th month Mean ± SD	18th month Mean ± SD	24th month Mean ± SD	
Pachymetry							
CCT (µm)	459.5 ± 29.7	451.3 ± 32.6	442.9 ± 37.1	429.0 ± 32.5	416.3 ± 28.8	407.4 ± 26.0	<0.001
Anterior corneal surface							
k1 (D)	46.43 ± 0.78	46.27 ± 0.61	45.90 ± 0.55	45.16 ± 0.91	44.92 ± 0.83	44.43 ± 0.75	<0.001
k2 (D)	48.43 ± 1.37	48.27 ± 0.93	47.31 ± 0.82	46.79 ± 0.68	46.35 ± 0.59	46.01 ± 0.76	<0.001
k average (D)	47.27 ± 1.13	47.09 ± 0.89	46.72 ± 0.64	45.84 ± 0.69	45.73 ± 0.62	45.15 ± 0.73	<0.001
k at the apex (k _{max}) (D)	48.64 ± 1.34	48.57 ± 1.28	47.43 ± 1.09	47.02 ± 1.08	46.75 ± 1.15	46.61 ± 1.11	<0.001
Posterior corneal surface							
k1 (D)	-5.65 ± 0.76	-5.64 ± 0.59	-5.53 ± 0.68	-5.42 ± 0.65	-5.38 ± 0.46	-5.31 ± 0.46	<0.05
k2 (D)	-7.07 ± 0.56	-7.00 ± 0.61	-6.74 ± 0.66	-6.60 ± 0.71	-6.57 ± 0.49	-6.49 ± 0.34	<0.05
k average (D)	-6.42 ± 0.61	-6.33 ± 0.76	-6.02 ± 0.70	-5.92 ± 0.68	-5.85 ± 0.50	-5.80 ± 0.52	<0.05

Table 2. Summary of the preoperative and postoperative corneal topographic parameters in Group B

Parameters	Group B						p value
	Preoperative Mean ± SD	1st month Mean ± SD	6th month Mean ± SD	12th month Mean ± SD	18th month Mean ± SD	24th month Mean ± SD	
Pachymetry							
CCT (µm)	486.2 ± 33.5	421.2 ± 27.1	436.7 ± 27.8	439.0 ± 30.1	433.4 ± 23.0	430.9 ± 25.2	<0.05
Anterior corneal surface							
k1 (D)	45.65 ± 1.16	44.01 ± 0.64	44.29 ± 0.82	44.69 ± 0.71	44.85 ± 0.66	44.80 ± 0.52	<0.05
k2 (D)	49.22 ± 0.39	46.29 ± 0.52	46.65 ± 0.71	46.87 ± 0.80	47.11 ± 0.65	47.05 ± 0.41	<0.001
k average (D)	47.51 ± 0.78	45.36 ± 0.57	45.67 ± 0.88	45.94 ± 0.63	46.00 ± 0.47	46.07 ± 0.59	<0.001
k at the apex (k _{max}) (D)	49.30 ± 0.49	46.37 ± 0.68	46.71 ± 0.43	46.90 ± 0.69	47.05 ± 0.52	47.07 ± 0.56	<0.001
Posterior corneal surface							
k1 (D)	-5.57 ± 0.83	-5.59 ± 0.75	-5.62 ± 0.71	-5.64 ± 0.55	-5.59 ± 0.62	-5.60 ± 0.58	< 0.1
k2 (D)	-7.47 ± 0.62	-7.46 ± 0.53	-7.33 ± 0.48	-7.31 ± 0.54	-7.37 ± 0.41	-7.42 ± 0.45	< 0.1
k average (D)	-6.63 ± 0.72	-6.61 ± 0.65	-6.55 ± 0.58	-6.59 ± 0.61	-6.57 ± 0.49	-6.52 ± 0.64	< 0.1

myopic component. The postoperative sphere reduction at 24 months was 1.31 ± 0.43 D (p value < 0. 05) while the postoperative cylinder reduction was 1.65 ± 0.55 D (p value < 0. 001). Also, there was a highly significant postoperative spherical equivalent reduction that reached 2.23 ± 0.49 D at 24 months (p value < 0. 001).

The differences in spherical equivalent, myopic component, astigmatic component and k_{max} were statistically significant at 1, 6 (p = 0.0001) and 12 (p = 0.003) months for the spherical equivalent, at 1, 6 (p = 0.0001) and 12 (p = 0.002) months for the myopic component, at zero, 1, 6, 12, 18 (p = 0.0001) and 24 (p = 0.002) months for the astigmatic component and at zero (p = 0.0003), 1, 6 (p < 0.0001) and 24 (p = 0.003) months for k_{max} (Fig. 2).

Visual outcomes analysis

This study showed improvement in both postoperative UDVA and CDVA

in both A and B groups (Tables 3 and 4). In group A, preoperative UDVA and CDVA improved from 1.12 ± 0.38 and 0.58 ± 0.42 LogMAR (mean ± SD) to 0.66 ± 0.20 (p value < 0. 05) and 0.20 ± 0.12 (p value < 0. 001) at 24 months.

In group B, preoperative UDVA and CDVA improved from 1.26 ± 0.52 and 0.68 ± 0.36 LogMAR (mean ± SD) to 0.58 ± 0.28 (p value < 0. 05) and 0.20 ± 0.16 (p value < 0. 001) at 24 months.

Complications

Thirty-seven eyes (63.8%) in group A and 51 eyes (76.1%) in group B complained about early postoperative photophobia, pain, foreign body sensation, irritation and watery eyes (Table 5). All patients were reassured that most of these complaints will disappear within 48 hr postoperatively. Topical anaesthetic Benoxinate hydrochloride 0.4% eye drops (Benox, Pharmaceutical

Industries Company, E.I.P.I.CO., Egypt) was prescribed for all patients to be installed 4 times in the 1st postoperative days then stopped. All patients were instructed to start immediately the postoperative topical therapy on an hourly basis in the first postoperative 8 hr than then 5 times daily. Most eyes showed relief of these complains within the first 2–3 days postoperatively.

Delayed epithelial healing was recorded in 9 eyes (15.5%) in group A and 8 eyes (11.9%) in group B. All these eyes were instructed to stop installation of the steroid eye drops. Instead, non-steroidal anti-inflammatory Nepafenac 0.1% eye drops (Nepafenac, Alcon Laboratories, Inc.) were prescribed four times daily. In addition, carboxymethylcellulose sodium solution 0.5% lubricant eye drops (Refresh Plus, Allergan, Inc, Jersey city, USA) was added twice daily. All eyes showed complete epithelial healing within 7–10 postoperative days.

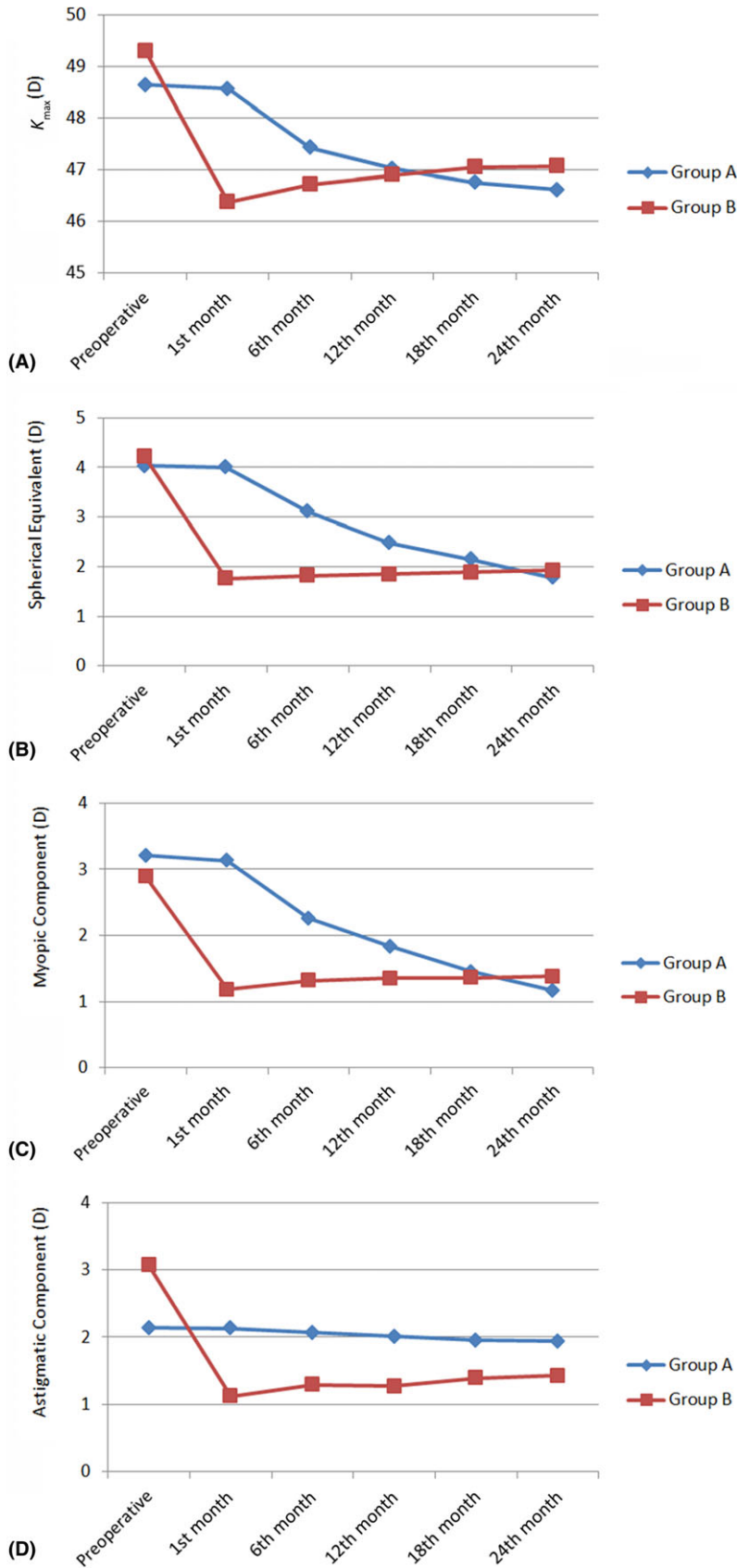


Fig. 2. Analysis of k_{max} and the refractive outcomes; A: k_{max} , B: spherical equivalent, C: Myopic component, D: Astigmatic component pathways in group A and group B along the 24-month follow-up period. The differences in spherical equivalent, myopic component, astigmatic component and k_{max} were statistically significant at 1, 6 ($p = 0.0001$) and 12 ($p = 0.003$) months for the spherical equivalent, at 1, 6 ($p = 0.0001$) and 12 ($p = 0.002$) months for the myopic component, at zero, 1, 6, 12, 18 ($p = 0.0001$) and 24 ($p = 0.002$) months for the astigmatic component and at zero ($p = 0.0003$), 1, 6 ($p < 0.0001$) and 24 ($p = 0.003$) months for k_{max} .

had a dust-like appearance in the corneal stroma most probably resulting from lacunar oedema of the keratocytes (Wollensak & Herbst 2010). This haze was considered as a good and normal sign of effective CXL. All these patients received Pred Forte eye drops, Hyabak and Sodium chloride 5% eye drops (Optic Saline, Advanced Pharmaceutical Industries Co., APIC, Cairo, Egypt) five times daily and tapered gradually. The corneal haze was transitory and disappeared within the first six postoperative months.

In group B, corneal haze was recorded in four eyes (5.9%). Corneal haze was recorded as scale 1 in two eyes (2.9%), scale 2 in one eye (1.5%) and scale 3 in one eye (1.5%). The corneal haze was subepithelial in nature with a reticulated appearance mostly resulted from PRK. All these patients were instructed to instil the Pred Forte and Hyabak eye drops on an hourly basis to be reduced to 5 times daily once the signs of improvement were observed. All patients showed recovery from the corneal haze within 2–4 weeks postoperatively.

In group A, a persistent epithelial defect (PED) was recorded only in one eye (1.7%). The patient was instructed to stop using the steroid eye drops. Supportive therapy was used for this patient. Frequent eye lubricants and artificial tears were prescribed. Carboxymethylcellulose sodium solution 0.5% lubricant eye drops were prescribed five times daily. The supportive care continued for 8 weeks until the epithelial defect showed complete healing leaving a very faint paracentral corneal opacity that did not affect the overall postoperative visual outcome.

In group A, anterior corneal haze was recorded in seven eyes (12.1%). Corneal haze was recorded as scale 1 in

three eyes (5.1%), scale 2 in 2 eyes (3.5%) and scale 3 in two eyes (3.5%). This corneal haze after standard CXL

Table 3. Summary of the preoperative and postoperative visual and refractive parameters in Group A

Parameters	Group A						p value
	Preoperative Mean ± SD	1st month Mean ± SD	6th month Mean ± SD	12th month Mean ± SD	18th month Mean ± SD	24th month Mean ± SD	
Visual acuity							
UDVA (LogMAR)	1.12 ± 0.38	1.00 ± 0.43	0.92 ± 0.54	0.74 ± 0.28	0.68 ± 0.22	0.66 ± 0.20	<0.05
CDVA (LogMAR)	0.58 ± 0.42	0.54 ± 0.46	0.32 ± 0.34	0.27 ± 0.26	0.22 ± 0.18	0.20 ± 0.12	<0.001
Subjective refraction							
Myopic component (D)	3.21 ± 1.09	3.13 ± 1.02	2.26 ± 0.86	1.83 ± 0.67	1.45 ± 0.50	1.17 ± 0.73	<0.001
Astigmatic component (D)	2.14 ± 1.31	2.13 ± 1.35	2.07 ± 1.21	2.01 ± 1.05	1.95 ± 0.92	1.94 ± 0.86	<0.1
Spherical equivalent (D)	4.03 ± 1.18	4.00 ± 1.07	3.11 ± 0.95	2.48 ± 1.12	2.15 ± 0.89	1.78 ± 1.04	<0.001

Table 4. Summary of the preoperative and postoperative visual and refractive parameters in Group B.

Parameters	Group B						p value
	Preoperative Mean ± SD	1st month Mean ± SD	6th month Mean ± SD	12th month Mean ± SD	18th month Mean ± SD	24th month Mean ± SD	
Visual acuity							
UDVA (LogMAR)	1.26 ± 0.52	0.48 ± 0.32	0.50 ± 0.34	0.53 ± 0.38	0.51 ± 0.44	0.58 ± 0.28	<0.05
CDVA (LogMAR)	0.68 ± 0.36	0.18 ± 0.12	0.22 ± 0.18	0.22 ± 0.25	0.23 ± 0.17	0.20 ± 0.16	<0.001
Subjective refraction							
Myopic component (D)	2.89 ± 1.05	1.18 ± 0.72	1.32 ± 0.83	1.35 ± 0.76	1.36 ± 0.71	1.38 ± 0.57	<0.05
Astigmatic component (D)	3.07 ± 1.26	1.12 ± 0.87	1.29 ± 0.72	1.27 ± 0.85	1.39 ± 0.52	1.43 ± 0.62	<0.001
Spherical equivalent (D)	4.23 ± 0.95	1.76 ± 1.14	1.82 ± 0.84	1.85 ± 0.93	1.89 ± 0.68	1.92 ± 0.74	<0.001

Table 5. The summary of the postoperative complications.

List of complications	Group A (58 eyes)		Group B (67 eyes)	
	No. of eyes	%	No. of eyes	%
Early				
Corneal haze	7	12.1	4	5.9
Pain and photophobia	37	63.8	51	76.1
Delayed epithelial healing	9	15.5	8	11.9
Late				
Persistent epithelial defect (PED)	1	1.7	1	1.3
Irreversible stromal scarring	–	–	1	1.3

In group B, one eye (1.3%) had postoperative localized stromal scarring (Fig. 3). The patient received the previously mentioned supportive therapy. The condition ended in a permanent localized corneal opacity.

There were no recorded cases of treatment failure with postoperative keratoconus progression in either group.

Discussion

This study has proven that PRK combined with AXL can significantly reduce the astigmatic and myopic errors of keratoconus at an early postoperative time-point with a stable long-term effect. Remarkably, standard CXL alone also induced a remarkable

corneal flattening effect with a significant reduction in the myopic refractive component at a later time-point one to two years postoperatively. This seems to be a unique effect of CXL which was not observed with AXL.

These outcomes in group A could be attributed to the fact that the standard CXL affects all corneal meridians symmetrically so that it had a great influence in the postoperative sphere reduction and almost insignificant influence in the postoperative cylinder reduction. The outcomes in group B could be attributed to the fact that PRK is effective in the postoperative cylinder reduction while AXL had almost no refractive gain to add to the myopic component improvement in the way that standard CXL managed

to reduce the postoperative sphere in group A.

Kymionis et al. reported the use of a modified accelerated CXL protocol including 14 min irradiance of 9mW/cm² or 7 min irradiance with 18mW/cm². They concluded that accelerated CXL protocols seem to be a valid alternative to the standard CXL protocol (Kymionis et al. 2017). Schumacher et al. compared corneal stiffness induced by standard (30 min using UVA 3 mW/cm²) versus accelerated CXL (9 min using UVA 10 mW/cm²) using uniaxial biomechanical measurements of porcine corneal strips. They reported that there was no statistical difference between both cross-linking procedures regarding the biomechanical changes and corneal stiffness (Schumacher et al. 2011). In contrast, using inflation experiments Bao et al. recently evaluated the biomechanical changes and corneal stiffening induced by different UVA irradiances ranging from 3 mW/cm² for 30 min to 90 mW/cm² for 1 min in seven different groups of white rabbits. They showed that the higher the UVA irradiance and the shorter the corneal irradiation duration, the lower the corneal stiffening effect. In other words, corneal stiffening proved to be

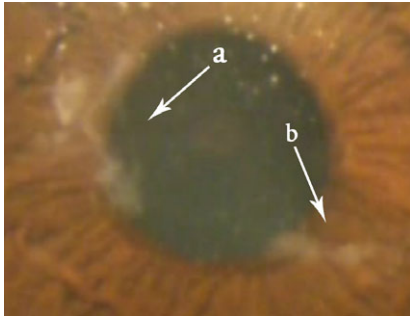


Fig. 3. One eye in group B with PED (arrow a) and localized irreversible stromal scarring (arrow b).

lower when the UVA irradiation time was shortened. This would suggest that standard CXL is more powerful than accelerated CXL in inducing corneal stiffening. Moreover, the Bunsen-Roscoe law of reciprocity may not be fully applicable for corneal tissue cross-linking (Bao et al. 2018).

The results of our study suggest that standard CXL may be more powerful in flattening the anterior corneal surface than AXL in the long run. Similarly, many authors have reported the good and lasting effect of standard CXL in comparison with AXL. In fact, it has been observed that AXL had a limited corneal flattening influence in topography while standard CXL had an excellent topographic corneal flattening outcome that led to keratoconus stability and postoperative visual improvement (Choi et al. 2017; Kymionis et al. 2017; Santhiago 2017). Brittingham et al. (2014) stated that AXL has negative effect on the demarcation line at 12 months after cross-linking with increased steepening of the anterior corneal surface. Spadea et al. (2016) reported that the depth of the stromal demarcation line after standard CXL ranged from 300 to 500 μm while in pulsed AXL about 210 μm and only about 150 μm in continuous mode AXL. Mazzotta et al. evaluated the qualitative micro-morphological postoperative outcomes of the cornea following AXL using confocal microscopy. They evaluated four different protocols of epithelium-off AXL and concluded that AXL shortens the duration of standard CXL by 20 min average and has a corneal stiffening outcome that affects only the anterior 160 μm of corneal stroma on average with a range from 140 to 200 μm (Mazzotta et al. 2013).

Vastardis et al. reported that pulsed CXL was effective in halting KC progression and stiffening of the cornea (Vastardis et al. 2017). Moramarco et al. reported the results of the depth of the demarcation line of the corneal stroma and compared two techniques of accelerated CXL. In their study group A, the cornea was irradiated with 30 mW/cm^2 UVA using the continuous mode for 4 min to deliver a total energy of 7.2 J/cm^2 while group B received the same treatment except that the UVA mode was pulsed mode for 8 min (Moramarco et al. 2015). They finally concluded that the postoperative demarcation line of the cornea stroma, scanned with anterior segment optical coherence tomography, was at a deeper level when pulsed mode was used rather than the continuous mode (149.32 ± 36.03 and 213 ± 47.38 μm , respectively). Furthermore, Mazzotta et al. compared continuous versus pulsed epithelium-off AXL for one year in both groups. Surprisingly enough, they reported that pulsed AXL had better results than continuous AXL with no recorded endothelial damage in either group (Mazzotta et al. 2014). On the contrary, this study has shown that continuous standard CXL was more powerful than pulsed AXL in the long-term perspective.

Kanellopoulos and colleagues described the use of simultaneous AXL combined with PRK aimed to reduce the spherical equivalent up to 3 dioptres. This procedure was known as Athens Protocol that included ablation of 50 μm of the anterior cornea to provide a therapeutic tool in advanced KC followed by accelerated CXL to irradiate the cornea with 370 nm UVA and an irradiance of 3 mW/cm^2 . However, our study tried to follow the Athens Protocol in group B with the main difference that the study eyes included only grade 1 keratoconus. In addition, they used wavefront-guided WFG-PRK (Allegrito Wave Eye-Q 400-Hz) to do CXL-Plus (Kanellopoulos & Binder 2007; Kanellopoulos 2009; Kanellopoulos & Asimellis 2014) while group B in this study used the standard PRK (VISX STAR S4 IR™, Abbott Laboratories). Both studies were restricted to ablation of 50 μm of the corneal stromal tissue. Other authors reported similar results and concluded that AXL-Plus was a good therapeutic and a safe procedure to treat KC (Ghanem et al.

2014; Knezović et al. 2015; Sakla et al. 2016; Kymionis et al. 2017).

Kontadakis et al. compared the outcomes of two groups. The first group had CXL alone while the second group had topography-guided PRK combined with CXL (tPRK-CXL). Each group included 30 eyes that were followed up for 3 years. They used a solid state laser to achieve 50 μm ablation of the corneal stromal tissue (Kontadakis et al. 2016). Our study had almost the same idea of their study; however, we used AXL instead CXL and included 125 eyes with only grade 1 keratoconus however. Both studies used the same 50 μm ablation depth as a maximum value but our PRK was not topography-guided. Their study concluded that CXL-Plus had more significantly improved visual outcomes in comparison with the CXL group. They also stated that both groups showed the same postoperative stability. However, in our study standard CXL proved to be equally effective in corneal flattening with sphere reduction and visual outcomes when compared with AXL-Plus.

Regarding corneal haze, Raiskup et al. (2009) reported clinical significant corneal haze in 8.6% of eyes with grade 1, 2 and 3 KC and they concluded that advanced KC was at more risk to develop corneal haze and localized stromal scarring. Greenstein et al. (2010) and Gutiérrez et al. (2012) reported corneal haze in the first month that decrease gradually to finally disappear from 3 to 12 months postoperatively. Moreover, Dhawan et al. reported that the corneal haze after CXL is different from the corneal haze after PRK. The haze following CXL may extend to 60% of the corneal thickness and is associated with honeycomb-like or dust-like appearance resulting from lacunar hydration and oedema of keratocytes which is usually a transient self-limiting phenomenon that disappears within few months postoperatively (Wollensak & Herbst 2010). On the other hand, the haze following PRK has a subepithelial reticulated pattern which is more superficial than the haze induced by CXL (Dhawan et al. 2011). Our study showed both types of corneal haze as 12.1% of eyes in group A had haze after CXL that disappeared within the first six postoperative months while 5.9% of eyes in group B had haze after

PRK despite the use of MMC, however the haze disappeared within the first postoperative month. Koller et al. (2009) reported many complications of CXL which included a 7.6% failure rate of CXL, central stromal scars complicated 2.8% while sterile infiltrates were recorded in 6.7% of cases. Our study recorded paracentral irreversible stromal scarring in one eye (1.3%) following CXL-Plus. In view of possible CXL-related complications corneal cross-linking can only be recommended in grade 1 KC if an active progression of ectasia or corneal thinning has been documented.

In conclusion, standard CXL showed close results to AXL-Plus at the 24th follow-up month. Standard CXL was acting as a stabilizing procedure that was associated with a significant improvement of the myopic refractive component after one to two years. AXL-Plus achieved a reduction in both the astigmatic and myopic refractive component shortly after the treatment due to the PRK-induced tissue ablation. However, there was no further improvement of the refractive and topographic parameter in the long term due to AXL. In the future, we plan to perform a study combining PRK and standard CXL thereby also combining the advantages of the early refractive corrections by PRK and the late improvements due to standard CXL.

References

- Bao F, Zheng Y, Liu C, Zheng X et al. (2018): Changes in corneal biomechanical properties with different corneal cross-linking irradiances. *J Refract Surg* **34**: 51–58.
- Brittingham S, Tappeiner C & Beatrice E (2014): Corneal cross-linking in keratoconus using the standard and rapid treatment protocol: differences in demarcation line and 12-month outcomes. *Invest Ophthalmol Vis Sci* **55**: 8371–8376.
- Choi M, Kim J, Kim E et al. (2017): Comparison of the conventional Dresden protocol and accelerated protocol with higher ultraviolet intensity in corneal collagen cross-linking for keratoconus. *Cornea* **36**: 523–529.
- Dhawan S, Rao K & Natrajan S (2011). Complications of corneal collagen cross-linking. *J Ophthalmol*; Article ID 869015.
- Galvis V, Tello A, Ortiz AI, Escaf L et al. (2017): Patient selection for corneal collagen crosslinking: an updated review. *Clin Ophthalmol* **11**: 657–668.
- Ghanem C, Santhiago R, Berti T et al. (2014): Topographic, corneal wavefront, and refractive outcomes 2 years after collagen crosslinking for progressive keratoconus. *Cornea* **33**: 43–48.
- Greenstein SA, Fry KL, Bhatt J & Hersh PS. (2010): Natural history of corneal haze after collagen crosslinking for keratoconus and corneal ectasia: Scheimpflug and biomicroscopic analysis. *J Cataract Refract Surg* **36**: 2105–2114.
- Gutiérrez R, Lopez I, Villa-Collar C & González-Méijome JM (2012): Corneal transparency after crosslinking for keratoconus: 1-year follow-up. *J Refract Surg* **28**: 781–786.
- Kanellopoulos J (2009): Comparison of sequential vs same-day simultaneous collagen cross-linking and topography-guided PRK for treatment of keratoconus. *J Refract Surg* **25**: S812–S818.
- Kanellopoulos J & Asimellis G (2014): Keratoconus management: long-term stability of topography guided normalization combined with high-fluence CXL stabilization (The Athens Protocol). *J Refract Surg* **30**: 88–93.
- Kanellopoulos A & Binder PS (2007): Collagen cross-linking (CCL) with sequential topography-guided PRK: a temporizing alternative for keratoconus to penetrating keratoplasty. *Cornea* **26**: 891–895.
- Kim M, Kim C, Park C et al. (2004): Effect of thermal preconditioning before excimer laser photoablation. *J Korean Med Sci* **19**: 437–446.
- Knezović I, Višnjić M & Raguž H (2015): Partial topography-guided photorefractive keratectomy followed by corneal cross linking in the management of progressive keratoconus: our initial ten month results. *Acta Clinica Croatica* **54**: 193–200.
- Koller T, Mrochen M & Seiler T (2009): Complication and failure rates after corneal crosslinking. *J Cataract Refract Surg* **35**: 1358–1362.
- Kontadakis G, Kankariya V, Tsoulnaras K et al. (2016): Long-term comparison of simultaneous topography-guided photorefractive keratectomy followed by corneal crosslinking versus corneal cross-linking alone. *Ophthalmology* **123**: 974–983.
- Kymionis GD, Grentzelos MA, Portaliou DM et al. (2014): Corneal collagen cross-linking (CXL) combined with refractive procedures for the treatment of corneal ectatic disorders: CXL-Plus. *J Refract Surg* **30**: 566–576.
- Kymionis G, Kontadakis G & Hashemi K (2017): Accelerated versus conventional corneal crosslinking for refractive instability: an update. *Curr Opin Ophthalmol* **28**: 343–347.
- Mazzotta C, Paradiso A, Baiocchi S, Caragiuli S et al. (2013): Qualitative investigation of corneal changes after accelerated corneal collagen cross-linking (A-CXL) by in vivo confocal microscopy and corneal OCT. *J Clin Exp Ophthalmol* **4**: 6.
- Mazzotta C, Traversi C, Paradiso AL, Latronico ME & Rechichi M (2014): Pulsed light accelerated crosslinking versus continuous light accelerated crosslinking. One-year results. *J Ophthalmol* **2014**, Article ID 604731, 6 pages.
- Moramarco A, Iovieno A, Sartori A & Fontana L (2015): Corneal stromal demarcation line after accelerated crosslinking using continuous and pulsed light. *J Cataract Refract Surg* **41**: 2546–2551.
- Raiskup F, Hoyer A & Spoerl E (2009): Permanent corneal haze after riboflavin-UVA-induced crosslinking in keratoconus. *J Refract Surg* **25**: 824–828.
- Sakla H, Altroudi W, Munoz G et al. (2016): Simultaneous topography-guided photorefractive keratectomy and accelerated corneal collagen cross-linking for keratoconus. *Cornea* **35**: 941–945.
- Saleem M, Elzembely H, AboZaid M et al. (2018): Three-year outcomes of cross-linking PLUS (combined cross-linking with femtosecond laser intracorneal ring segments implantation) for management of keratoconus. *J Ophthalmol* **2018**: 6907573.
- Santhiago M (2017): Corneal crosslinking: The standard protocol. *Revista Brasileira de Oftalmologia* **76**: 43–49.
- Schumacher S, Oeftiger L & Mrochen M (2011): Equivalence of biomechanical changes induced by rapid and standard cross-linking, using riboflavin and ultraviolet radiation. *Invest Ophthalmol Vis Sci* **52**: 9048–9052.
- Spadea L, Tonti E & Vingolo E (2016): Corneal stromal demarcation line after collagen crosslinking in corneal ectatic diseases: a review of the literature. *Clin Ophthalmol* **10**: 1803–1810.
- Vastardis I, Pajic-Eggspuehler B, Nichorlis C et al. (2017): Recent innovations in collagen corneal cross-linking; a mini review. *Open Ophthalmol J* **11**: 217–224.
- Wollensak G & Herbst H (2010): Significance of the lacunar hydration pattern after corneal cross-linking. *Cornea* **29**: 899–903.
- Wollensak G, Spoerl E & Seiler T (2003): Riboflavin/ultraviolet-A-induced collagen crosslinking for the treatment of keratoconus. *Am J Ophthalmol* **135**: 620–627.

Correspondence:

Mohammed Iqbal, MD
Department of Ophthalmology
Faculty of Medicine
Sohag University
Sohag
Egypt
Tel: +00201068559840
Fax: +0020932330733
Email: dr_m_iqbal@yahoo.com

The authors are grateful for the help and support of Dr Islam Awany, Dr. Adham Saro, Dr. Mohammed Salah, Mr. Tamer Badawy, Mr. Esmael El-Etriby, Mr. Ahmed Saber, Mr. Mostafa Saber, Mr. El Khominy Omar, Mr. Mohammed Mahmoud, Mr. Amr Hamed, Mr. Mohammed Eid and Mr. Waleed Hatour. Registry Number: PACTR201801002951377.