

Optimizing Chemotherapy of Pancreatic Acinar Cell Carcinoma: Our Experiences and Pooled Analysis of Literature

Clinical Medicine Insights: Oncology
Volume 16: 1–10
© The Author(s) 2022
Article reuse guidelines:
sagepub.com/journals-permissions
DOI: 10.1177/11795549221090186



Jian-Ying Xu^{1*}, Wen-Long Guan^{1*}, Shi-Xun Lu², Xiao-Li Wei¹,
Wen-Jie Shi³, Chao Ren¹, Yu-Hong Li¹, Sheng-Ping Li⁴,
Miao-Zhen Qiu¹ and Feng-Hua Wang¹

¹Department of Medical Oncology, State Key Laboratory of Oncology in South China, Collaborative Innovation Center for Cancer Medicine, Sun Yat-sen University Cancer Center, Guangzhou, China. ²Department of Pathology, State Key Laboratory of Oncology in South China, Collaborative Innovation Center for Cancer Medicine, Sun Yat-sen University Cancer Center, Guangzhou, China. ³University Hospital for Gynecology, Pius-Hospital, University Medicine Oldenburg, Oldenburg, Germany. ⁴Department of Hepatobiliary and Pancreatic Surgery, State Key Laboratory of Oncology in South China, Collaborative Innovation Center for Cancer Medicine, Sun Yat-sen University Cancer Center, Guangzhou, China.

ABSTRACT

BACKGROUND: Pancreatic acinar cell carcinoma (PACC) is rare, and its appropriate treatment remains unknown. We aim to explore the characteristics and optimal treatment of it.

METHODS: The data on clinicopathologic characteristics, molecular alteration, treatment, and survival of patients diagnosed with PACC at the Sun Yat-sen University Cancer Center from 2005 to 2020 were collected. The optimal treatment was explored by co-analyzing our results and published literatures.

RESULTS: Twenty-two PACC patients were enrolled. Eight of 17 non-metastatic patients received adjuvant chemotherapy. The patients receiving fluoropyrimidine-based regimen ($n=3$) had a better median disease-free survival (mDFS) than those with gemcitabine-based regimen ($n=5$) (unreached vs 27 months). Eight metastatic patients received first-line chemotherapy. Four patients received second-line chemotherapy. The objective response rate (ORR) of the fluoropyrimidine-based regimen was 85.7% (6/7), much better than that of the gemcitabine-based regimen (0/5). One patient who had responded to the first-line FOLFIRINOX (5-fluorouracil + oxaliplatin + leucovorin + irinotecan) regimen received olaparib as maintenance treatment for 5 months with good tolerance. Thirty-one published literatures, with a total of 86 cases, were included in the co-analysis. The ORR of the first-line fluoropyrimidine-based regimen ($n=47$) was higher than that of gemcitabine-based regimen ($n=39$) (59.6% vs 15.3%, $P<.001$). Eight of 11 patients treated with the FOLFIRINOX regimen achieved partial response (PR).

CONCLUSIONS: For patients with metastasis, a fluorouracil-based regimen such as FOLFIRINOX may be preferred, and maintenance treatment of poly ADP-ribose polymerase (PARP) inhibitors after effective platinum-containing treatment for breast cancer susceptibility gene (BRCA) mutation patients must be assessed.

KEYWORDS: Pancreatic acinar cell carcinoma, chemotherapy, fluorouracil, gemcitabine, olaparib

RECEIVED: October 25, 2021. **ACCEPTED:** March 9, 2022.

TYPE: Original Research Article

FUNDING: The author(s) received no financial support for the research, authorship, and/or publication of this article.

DECLARATION OF CONFLICTING INTERESTS: The author(s) declared no potential conflicts of interest with respect to the research, authorship, and/or publication of this article. The manuscript has received preprint service on Research Square—<https://www.researchsquare.com/article/rs-177880/v1>.

CORRESPONDING AUTHORS: Miao-Zhen Qiu, Department of Medical Oncology, State Key Laboratory of Oncology in South China, Collaborative Innovation Center for Cancer Medicine, Sun Yat-sen University Cancer Center, 651 Dong Feng Road East, Guangzhou 510060, Guangdong Province, China. Email: qiumzh@sysucc.org.cn

Feng-Hua Wang, Department of Medical Oncology, State Key Laboratory of Oncology in South China, Collaborative Innovation Center for Cancer Medicine, Sun Yat-sen University Cancer Center, 651 Dong Feng Road East, Guangzhou 510060, Guangdong Province, China. Email: wangfh@sysucc.org.cn

Introduction

Acinar cells are present in more than 80% of the pancreas, yet pancreatic acinar cell carcinoma (PACC) is rare, accounting for approximately 1% of all primary pancreatic neoplasms.¹ Recent studies have demonstrated that PACC was quite different from pancreatic ductal cell carcinoma (PDCC) in clinical, pathological, and molecular features and was associated with a significantly better survival.^{2–4}

* Jian-Ying Xu and Wen-Long Guan contributed equally to this study.

The therapeutic strategy of PACC should be distinguished from that of PDCC.^{1,5,6}

Radical surgery is recommended for non-metastatic PACC with a 5-year survival rate of 36.6% to 3.9%.^{7,8} Pancreatic acinar cell carcinoma was considered aggressive with a high recurrence rate and frequent metastasis after surgery.^{1,9,10} Systemic chemotherapy may play an essential role in improving prognosis. However, no prospective studies or meta-analyses documenting this fact have been reported. Retrospective studies comprising small case series or case reports resulted in the lack of high-quality evidence. Limited and selection-biased data



Creative Commons Non Commercial CC BY-NC: This article is distributed under the terms of the Creative Commons Attribution-NonCommercial 4.0 License (<https://creativecommons.org/licenses/by-nc/4.0/>) which permits non-commercial use, reproduction and distribution of the work without further permission provided the original work is attributed as specified on the SAGE and Open Access pages (<https://us.sagepub.com/en-us/nam/open-access-at-sage>).

make treatment decisions difficult. The authors collected data for 22 PACC patients in Sun Yat-sen University Cancer Center, based on clinicopathologic characteristics, molecular alteration, treatment, and survival. The role of chemotherapy and targeted therapy was explored. The study further compares fluoropyrimidine-based regimen with gemcitabine-based regimen by co-analyzing the results obtained herein and published literature. The authors aim to understand rare diseases better and optimize their treatment.

Material and Methods

Informed consent was obtained from all the patients in a written format. The institutional ethics committees approved this study to be conducted at Sun Yat-sen University Cancer Center, in accordance with the Declaration of Helsinki. The medical database at the center was scrutinized for patients treated between January 2005 and April 2020. Patients diagnosed with PACC who had all treatment and follow-up records were included in the study. If the patients have liver metastasis, liver biopsy was used to obtain a specimen. If it is difficult to obtain specimens from metastatic sites, the ultrasound-guided puncture was used to obtain specimens from primary lesions. At least 2 pathologists reviewed all the tumor specimens. Immunohistochemical staining was used to confirm acinar differentiation and to distinguish between acinar cell carcinomas and ductal adenocarcinomas. The standard for morphology is abundant with acinar cell pathological differentiation (unlike rich ductal adenocarcinoma). The expression of SYN and CgA (for the identification of neuroendocrine tumor), and partial response (PR) and CD10 (for the identification of solid pseudopapilloma) was negative. Meanwhile, the specific expression of trypsin is detected in these cases, and the cases with controversial diagnosis of atypical morphology and histochemistry were excluded. Data on the clinicopathologic characteristics, molecular alteration, treatment, and survival were collected. The authors also searched the literature, including case reports or meeting abstracts describing therapeutic approaches for PACC in PubMed, Embase, and Cochrane library until August 25th, 2020. All literature involving systemic therapy containing gemcitabine or fluorouracil was included. An analysis based on the searched data and published data was conducted to improve the understanding of this rare disease and seek effective treatment. Cases receiving gemcitabine plus fluorouracil were categorized into a fluoropyrimidine-based regimen group.

Computed tomographic scans or magnetic resonance imaging were used for tumor assessment. Revised Response Evaluation Criteria In Solid Tumours (RECIST) guideline (version 1.1) was adopted for tumor response evaluation.

Tumor specimens and matched blood samples were used for next-generation sequences (NGS). High-depth sequencing and 4 types of tumor variation (including point mutation, insertion loss of small fragments, copy number variation, and currently known fusion genes) were detected through the 1021

gene panel platform (including somatic mutation, germline mutation, and tumor mutational burden [TMB]).

All quantitative data were analyzed using the R version 3.6.2. Kaplan–Meier methods estimated survival. Log-rank tests were performed for the estimation of differences in survival. The objective response rate (ORR) was calculated using the chi-square test. A 2-tailed P value $<.05$ was considered statistically significant.

Results

Clinicopathological characteristics

A total of 27 PACC patients were identified from 4508 patients diagnosed with pancreatic neoplasms in the Sun Yat-sen University Cancer Center. Five patients without treatment were excluded, and 22 patients were enrolled in the study. There were 17 non-metastatic patients and 5 metastatic patients at initial diagnosis. All patients without metastasis had radical surgery and 9 of them developed metastasis. Table 1 shows the patients' baseline characteristics. Most patients had bulky primary disease with a median size of 9.2 cm (range from 3 to 17 cm). Main metastatic sites were the liver ($n=10$), distant lymph node ($n=6$), and peritoneum ($n=5$). One patient was diagnosed as mixed acinar-endocrine carcinoma and 2 patients as mixed acinar-ductal carcinoma. All of them had a predominantly acinar differentiation. Serum CA-199 level (43.46–123.32 U/ml) was found in 7 patients. Elevated alpha-fetoprotein (AFP) level (50.43–23778.56 ng/ml) was detected in 3 patients who developed liver metastasis. Three patients with elevated serum lipase levels suffered subcutaneous fat necrosis and developed distant metastasis.

Gene alteration

Next-generation sequences on tumor samples were performed in 4 PACC patients. All patients showed microsatellite stability (MSS) and wild-type rat sarcoma (RAS)/v-raf murine sarcoma viral oncogene homolog B1 (BRAF) and low TMB (ranging from 6.72 to 8.16 mutations/mb). Two patients with breast cancer susceptibility gene 2 (BRCA2) germline mutation were identified, including 1 male patient with somatic mutation of IGF1R, FAT3, SMAD4, APC, SPEN, and MLH1 whose mother and sister were diagnosed with breast cancer. One female patient had a somatic mutation of TP53, CRTCL1, SMAD4, ROS1, NTRK1, ATM, and KIF5B, whose grandmother was suspected of pancreatic tumor. One male patient showed mutation of TP53, PML, ATM, ENDR, and ZNF703, whose father and grandfather were diagnosed with rectal cancer. No gene mutation was observed in the last patient.

Treatment for non-metastatic PACC

Seventeen non-metastatic patients underwent radical surgery with an median disease-free survival (mDFS) of 57 months. Eight of 17 (47.1%) patients received adjuvant chemotherapy. Nine of 17 (52.9%) patients developed metastasis after radical

Table 1. Patient demographics and clinicopathological characteristics (n=22).

CHARACTERISTICS	NO. OF PATIENTS
Sex	
Male	15 (68.2%)
Female	7 (31.8%)
Age, years	
Median (range)	51 (7-79)
ECOG performance status	
0	4 (18.2%)
1	18 (81.8%)
Size of primary disease, cm	
Median (range)	9.2 (3.0-17.0)
Location of primary lesions	
Head	9 (40.9%)
Body/tail	13 (59.1%)
Histology	
PACC	19 (86.4%)
Mixed PACC	3 (13.6%)
Common symptom	
Abdominal pain	11 (50.0%)
Weight loss	5 (28.6%)
Abdominal mass	5 (28.6%)
Subcutaneous fat necrosis	3 (13.6%)
Metastases at initial diagnosis	
Yes	5 (22.7%)
No	17 (77.3%)
Main metastatic site	
Liver	10 (45.5%)
Distant lymph node	6 (27.3%)
Peritoneum	5 (22.7%)
Serum CA-199	
Elevated	7 (31.8%)
Normal	15 (68.2%)
Serum AFP	
Elevated	3 (13.6%)
Normal	14 (63.6%)
Not available	5 (22.7%)

(continued)

Table 1. (Continued)

CHARACTERISTICS	NO. OF PATIENTS
Tumor family history	4 (18.2%)
Non-metastases cases	n= 17
Radical surgery	17 (100%)
Adjuvant chemotherapy	8 (47.1%)
Regional lymph node metastasis	3 (17.6%)
High Ki-67 index ($\geq 30\%$)	4 (23.5%)
Lymph-vascular invasion	6 (35.3%)
Treatment for metastases cases	n= 14
First palliative chemotherapy	8 (57.1%)
Second palliative chemotherapy	4 (28.6%)

Abbreviations: AFP, alpha-fetoprotein; CA-199, carbohydrate antigen 199; ECOG, Eastern Cooperative Oncology Group; PACC, pancreatic acinar cell carcinoma.

surgery. All 6 patients with pathological lymph-vascular invasion developed metastasis, and 3 of 11 patients without lymph-vascular invasion also developed metastasis. Ki-67 expression on the tumor was positive in 9 patients. By a cutoff of 30%, 4 patients with a high index of Ki-67 ($\geq 30\%$) developed metastasis, while 5 patients with a low index of Ki-67 ($<30\%$) remained disease-free. Five of 8 (62.5%) patients in the adjuvant therapy group had lymph-vascular invasion or Ki-67 high index, while 2 of 9 (22.2%) patients in the non-adjuvant therapy group had these risk factors.

Most patients received adjuvant therapy of 2 to 4 cycles, and only 2 patients received more than 6 cycles with disease-free survival (DFS) over 4 years. Table 2 lists the specific information on adjuvant chemotherapy. In all, 5 of 8 patients with adjuvant therapy and 4 of 9 patients without adjuvant therapy developed metastasis. Median disease-free survival of 9 patients without adjuvant chemotherapy seemed numerically better than that of the 8 patients with adjuvant chemotherapy (69 vs 42 months). Median disease-free survival of 5 patients receiving gemcitabine-based adjuvant chemotherapy was 27 months, while that of 3 patients receiving fluoropyrimidine-based adjuvant chemotherapy was not reached.

Treatment for metastatic PACC patients

Eight metastatic PACC patients received first-line chemotherapy, including 5 patients at initial diagnosis and 3 patients after radical surgery. Four patients received second-line chemotherapy after failing to first-line chemotherapy. The chemotherapy regimens and results have been shown in Table 3. The ORR of the fluoropyrimidine-based regimen was 85.7% (6/7), much better than the gemcitabine-based regimen (0/5, 4 patients got progressive disease [PD]). Two patients who received the second-line

Table 2. Adjuvant chemotherapy for non-metastatic patients and outcome.

PATIENT NUMBER, AGE	REGIMES	CYCLES	DFS (MONTHS)	LV INVASION	KI-67 INDEX	METASTASIS
1 60-69 years	GEM	4	5	Yes	70%	Yes
1 50-59 years	GEM	4	5	Yes	Unknown	Yes
1 50-59 years	S1	2	26	Yes	Unknown	Yes
2 50-59 years	GEMOX	2	27	Yes	30%	Yes
1 50-59 years	GEM	10	57	No	30%	Yes
2 40-49 years	S1	12	51	No	15%	No
1 50-59 years	SOX	5	62	No	20%	No
1 10-19 years	GEM	4	141	No	10%	No

Abbreviations: DFS, disease-free survival; GEM, gemcitabine; GEMOX, gemcitabine + oxaliplatin; LV, lymph-vascular; S1, tegafur/gimeracil/potassium; SOX, S1 + oxaliplatin. 1/2 in Column 1 refers to sex (male or female).

FOLFIRINOX (5-fluorouracil + oxaliplatin + leucovorin + irinotecan) regimen achieved PR after failing to first-line AG (albumin-bound paclitaxel + gemcitabine) regimen. One patient developed PD with the second-line AG regimen, and 1 patient with RAS wide-type achieved stable disease (SD) to second-line AG plus nimotuzumab with the condition controlled for 2 months.

Two patients with BRCA2 germline mutation had a good response to the FOLFIRINOX regimen and received olaparib treatment. One patient achieved PR to second-line FOLFIRINOX regimen and then received the maintenance olaparib treatment for 5 months with good tolerance. Another patient achieved PR to first-line FOLFIRINOX regimen with PFS (progression-free survival) of 18 months and developed PD to second-line AG regimen and third-line olaparib.

Review of published literature on chemotherapy of metastatic PACC

The study involved 32 studies; a total of 86 cases were included. The selection procedure has been shown in Figure 1, and treatment details are given in Table 4. Eighty-six cases received first-line treatment, and 33 out of 86 cases failed to first-line treatment and received second-line therapy. All the enrolled patients were divided into 2 groups: fluoropyrimidine-based regimen group and gemcitabine-based regimen group. The patients receiving gemcitabine plus fluorouracil were classified into the fluoropyrimidine-based regimen group.

For first-line chemotherapy, the ORR of 86 patients was 39.5%. There were 39 cases in the gemcitabine-based regimen group and 47 subjects in the fluoropyrimidine-based regimen group. The ORR of the fluoropyrimidine-based group (59.6%, 28/47) was higher than that of the gemcitabine-based group (15.4%, 6/39) ($P < .001$). Eight patients received FOLFIRINOX as first-line chemotherapy, and 6 of them achieved PR. The survival data were available for 74 cases, including 42 patients in the fluoropyrimidine-based group and

32 patients in the gemcitabine-based group. The median PFS and median overall survival (OS) of 74 cases were 8 and 25.4 months, respectively. Median PFS in the fluoropyrimidine-based group were significantly better than the gemcitabine-based group (12 vs 6 months, $P < .001$; Figure 2).

For second-line chemotherapy, the ORR of 29 patients was 37.9%. There were 10 cases in the gemcitabine-based regimen group and 19 cases in the fluoropyrimidine-based regimen group. ORR of the fluoropyrimidine-based group (52.6%, 10/19) was much higher than the gemcitabine-based group (10%, 1/10) ($P < .05$). The comparison of response between fluoropyrimidine-based regimen and gemcitabine-based regimen for metastatic PACC has been shown in Table 5.

Discussion

As PACC is rare, limited information is available. There is no consensus on PACC treatment strategy. More clinical data are needed to improve our understanding of this disease and seek appropriate treatments. The authors collected the data of 22 PACC patients at the cancer center. The authors combined the study results with the published literature to explore the role of adjuvant chemotherapy for non-metastatic disease. They optimized the selection of palliative chemotherapy or targeted therapy for metastatic disease. Compared with gemcitabine-based regimens, fluorouracil-based regimens may be the preferred choice for PACC. Furthermore, the value of olaparib for BRCA germline mutation patients and the role of epidermal growth factor receptor (EGFR) monoclonal antibody combined with chemotherapy for RAS wild-type patients were preliminarily explored.

Pancreatic acinar cell carcinoma may need more aggressive surgical resection because it was considered a more favorable prognosis than PDCA.⁹ In the study, 17 non-metastatic patients receiving radical surgery achieved an mDFS of 57 months, similar to that in other clinical reports.^{1,41} Eight of 9 patients with lymph-vascular invasion or high Ki-67 index ($\geq 30\%$) developed metastasis, consistent with other studies.⁴²

Table 3. The systemic chemotherapy and response for metastasis patients in our center.

FIRST LINE	RESPONSE	PFS ^a (MONTHS)	SECOND LINE	RESPONSE	PFS ^b (MONTHS)	THIRD LINE	RESPONSE	PFS ^c (MONTHS)	PFS ^d (MONTHS)	OS (MONTHS)
CAPOX	PR	16	-	-	-	-	-	-	-	24
GEMOX	PD	2	-	-	-	-	-	-	-	57
FOLFIRINOX	PD	2	GP/nimotuzumab	SD	2	-	-	-	-	61
S1	PR	23	-	-	-	-	-	-	-	66
AG	PD	3	FOLFIRINOX	PR	6	S1/PD-1 inhibitor	PD	2	2	16
GP ^e	PD	2	FOLFIRINOX	PR	9	Lenvatinib/PD-1 inhibitor	SD	4	-	17
FOLFIRINOX	PR	9	-	-	-	-	-	-	-	32
FOLFIRINOX ^e	PR	18	GP	PD	1.5	Olaparib	PD	2	1	39

Abbreviations: AG, albumin-bound paclitaxel + gemcitabine; CAPOX, oxaliplatin + capecitabine; FOLFIRINOX, 5-FU + oxaliplatin + irinotecan; GEMOX, gemcitabine + oxaliplatin; GP, gemcitabine + cisplatin; OS, overall survival; PD, progressive disease; PFS, progression-free survival; PR, partial response; SD, stable disease; S1, tegafur/gimeracil/potassium.
^aPFS for first-line chemotherapy.
^bPFS for second-line chemotherapy.
^cPFS for the third-line chemotherapy.
^dPFS for the fourth-line chemotherapy.
^ePatients were detected with BRCA2 mutation.

Ki-67 and invasion of lymph-vascular invasion may be prognostic indicators for PACC.

The role of adjuvant chemotherapy or chemoradiotherapy for PACC remains controversial or is considered to be underpowered. Schmidt et al⁷ included 865 resected PACC patients from 1985 to 2005 in National Cancer Database (NCDB) to identify the prognostic factors. The results showed that adjuvant therapy was not associated with better outcomes on multivariable analysis and that T classification, tumor size, and nodal status remained non-significant predictors of survival. Pate et al⁴³ carried out a more contemporary cohort of 298 patients with resectable PACC between 2004 and 2015 from NCDB. The results showed that adjuvant systemic therapy was associated with a significant improvement in OS (hazard ratio [HR]: 0.54, 95% confidence interval [CI]: 0.33-0.89) compared with surgery alone and supported that adjuvant systemic therapy should be given due consideration in patients undergoing resection, mainly when there is evidence of lymph node involvement. Wang et al⁴⁴ reported that 14 patients who received radical resection followed by adjuvant chemoradiotherapy had a better outcome than surgery alone. In our study, no DFS benefit of adjuvant chemotherapy was shown. It was speculated that the negative result might be related to the higher proportion of patients with poor prognostic factors such as lymph-vascular invasion or high Ki-67 index in the adjuvant chemotherapy group (62.5% vs 22.2%), inadequate cycles of adjuvant chemotherapy (median cycles of 4), and selection of chemotherapeutic regimen. So far, the literature does not report any study exploring the efficacy of different adjuvant chemotherapy regimens. In this study, the patients receiving fluoropyrimidine-based adjuvant chemotherapy achieved better mDFS than those receiving gemcitabine-based adjuvant chemotherapy (unreached vs 27 months). The value of fluoropyrimidine-based adjuvant chemotherapy may be noteworthy.

Palliative chemotherapy is the primary treatment for metastatic PACC. However, the appreciative chemotherapy regimen remains unclear because the published retrospective and small sample studies or various case reports had significant heterogeneity and a lack of high-quality evidence. Referring to the treatment of PDCC, many physicians were inclined to choose gemcitabine-based regimes with unsatisfied outcomes. A possible underlying mechanism for fluoropyrimidine-based regimen that could be an effective treatment of PACC is the similarity to colon cancer. Research has shown that PACC has none of the gene abnormalities commonly found in PDCC and has gene mutations in the APC gene/ β -catenin pathway and genetic progression similar to colon cancer.¹⁷ In the preclinical PACC patient-derived tumor xenograft model, oxaliplatin produced a prolonged durable growth response associated with increased apoptosis, decreased serum lipase level, and increased healthy acinar cells.⁴⁵ Yoo et al⁴⁶ reported that oxaliplatin-containing chemotherapy against PACC has improved activity compared with gemcitabine. It was indicated that

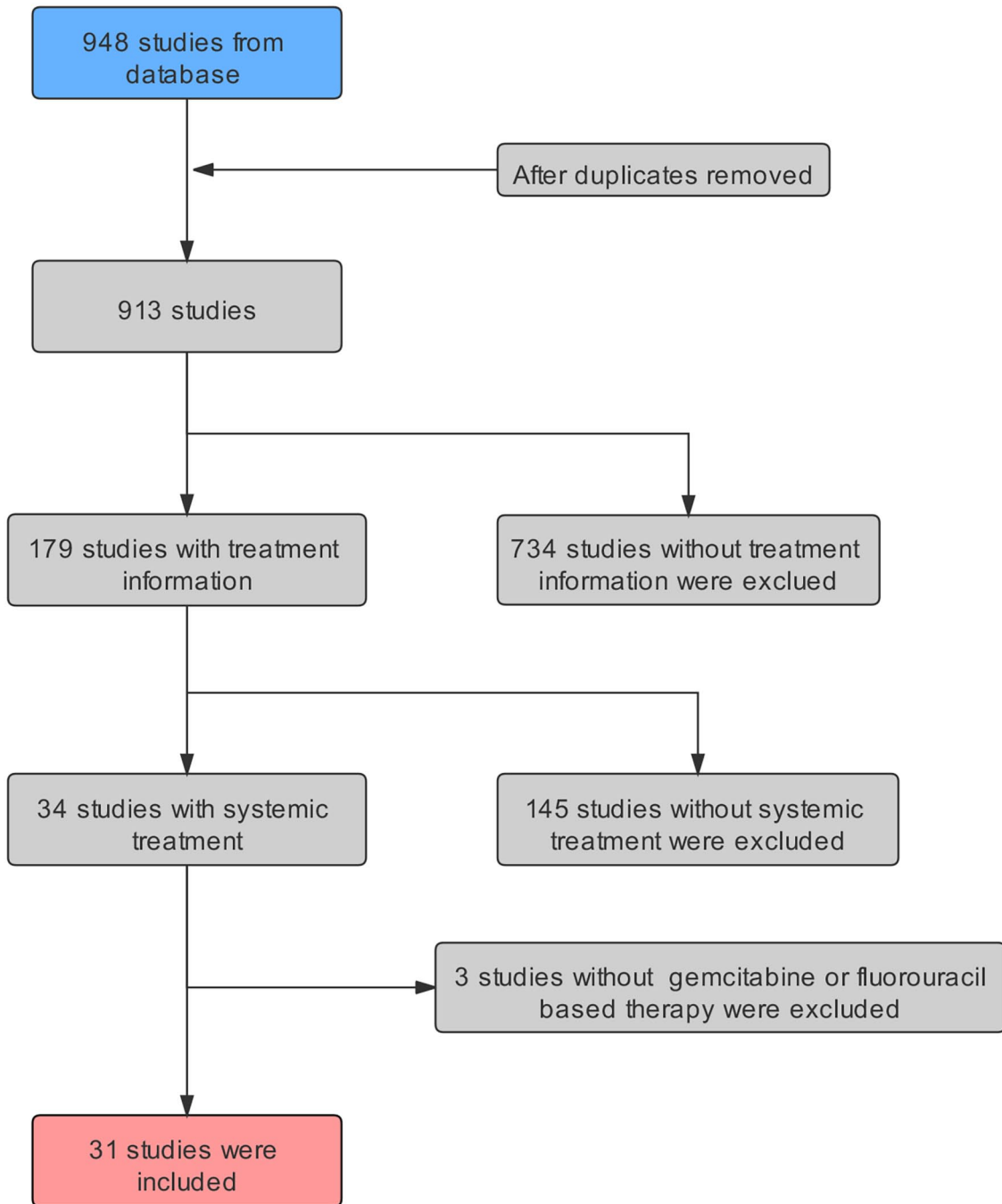


Figure 1. Schematic representation of literature selected.

chemotherapeutic agents used in treating colorectal cancer might be effective in ACC of the pancreas. Six out of 7 patients with the FOLFIRINOX regimen achieved PR, while 5 patients with the AG regimen had no response. To further understand the preferred chemotherapy regimen for metastatic PACC, the efficacy of fluoropyrimidine-based regimen and gemcitabine-based regimen were compared after reviewing published literature. The results based on the analysis of 44 patients further supported that fluorouracil-based chemotherapy with higher ORR and improved survival was superior to gemcitabine-based chemotherapy. FOLFIRINOX regimen may be the preferred one for PACC.

The molecular feature of PACC is different from other pancreatic cancers.¹⁷ Typical genetic alterations observed in PDAC usually are not detected or rarely occur in ACC, that is, mutations in KRAS, TP53, CDKN2A, and SMAD4. In our study, 4 patients underwent NGS and showed MSS, wild-type RAS/BRAF, and low TMB. Due to their pivotal role in maintaining genome integrity, BRCA1/2-deficient tumors are susceptible to therapies introducing cross-linking and DNA damage, namely, platinum-based chemotherapies and PARP inhibitors.^{17,47,48} Olaparib, an oral PARP inhibitor, has been approved for the maintenance treatment of adult patients with germline or BRCA-mutated advanced ovarian cancer,⁴⁹ breast

Table 4. Palliative chemotherapy for metastatic patients: data from literature.

REGIMEN	RESPONSE	AUTHOR	PUBLICATION (YEAR)
First-line regimen			
Gemcitabine-based			
AG	1SD/2PD	Brunetti et al ¹¹	2018
GEM	1PR/10SD/11PD	Fujii et al ¹² /Yokode et al ¹³ /Seki et al ¹⁴ /Brunetti et al ¹¹ /Lowery et al ¹⁵ /Simon et al ¹⁶ /Yoo et al ¹⁷ /Kuji et al ¹⁸ /Kruger et al ¹⁹ /Toda et al ²⁰	2009-2012 2016-2018
GEMOX/GEM + CDDP	4PR/2SD/2PD	Brunetti et al ¹¹ /Kruger et al ¹⁹ /Lowery et al ¹⁵	2011/2016/2018
GEM + irinotecan	2SD	Lowery et al ¹⁵	2011
GEM + erlotinib	1PR/3PD	Lowery et al ¹⁵ /Kruger et al ¹⁹	2016
Fluoropyrimidine-based			
5-FU/S1/CAP	7PR	Yamamoto et al ²¹ /Morishima et al ²² /Kanemasa et al ²³ /Sumiyoshi et al ²⁴ /Yoo et al ¹⁷ /Kruger et al ¹⁹	2010/2012 2013/2015
GEM + 5FU/GEM + S1	2CR/4PR/1SD	Nishimizu et al ²⁵ /Fukui et al ²⁶ /Hatata et al ²⁷ /Miyagawa et al ²⁸ /Toda et al ²⁰ /Brunetti et al ¹¹	2010/2011 2016/2018
FOLFOX/CAPOX	4PR/3SD/1PD	Yoo et al ¹⁷ /Fontenot et al ²⁹ /Morales et al ³⁰ /Brunetti et al ¹¹ /Kruger et al ¹⁹ /Jordan et al ³¹	2013/2016-2018 2020
5FU + CDDP	3PR/2SD	Brunetti et al ¹¹ /Butturini et al ⁵	1999/2011
		Ukei et al ³² /Jauch et al ³³	2016/2018
GEM + CAP	1PR/2SD/1PD	Yoo et al ¹⁷ /Lowery et al ¹⁵ /Sorscher ³⁴	2011/2017
PEXG	5SD	Brunetti et al ¹¹	2011
GTX	1PR/1SD	Lowery et al ¹⁵	2011
CAPE/temozolomide	1PD	Callata-Carhuapoma et al ³⁵	2015
FOLFIRINOX	6PR/2SD	Li et al ³⁶ /Yoshihiro et al ³⁷ /Kryklyva et al ³⁸ /Schempf et al ³⁹ /Kruger et al ¹⁹ /Pfrommer et al ⁴⁰	2013/2014 2016-2019
Second-line regimen			
Gemcitabine-based			
AG/GEMOX	1PR/1SD/2PD	Brunetti et al ¹¹ /Lowery et al ¹⁵ /Kruger et al ¹⁹	2011/2016 2018
GEM	2SD/4PD	Brunetti et al ¹¹ /Yoo et al ¹⁷ /Kanemasa et al ²³	2013/2017/2018
Fluoropyrimidine-based			
S1	2PR/3PD	Fujii et al ¹² /Yokode et al ¹³ /Seki et al ¹⁴	2009/2010/2017
GEM + CAP/GEM + S1	1PR/1SD/1PD	Brunetti et al ¹¹ /Lowery et al ¹⁵ /Kuji et al ¹⁸	2011/2018
FOLFIRI	1PR/2PD	Lowery et al ¹⁵ /Morales et al ³⁰	2011/2013
FOLFOX	4PR/1SD	Yoo et al ¹⁷ /Brunetti et al ¹¹ /Kruger et al ¹⁹ /Simon et al ¹⁶	2016-2018
FOLFIRINOX	2PR/1SD	Brunetti et al ¹¹ /Kruger et al ¹⁹ /Callata-Carhuapoma et al ³⁵	2015/2016/2018

Abbreviations: 5FU, 5-fluorouracil; AG, albumin paclitaxel + gemcitabine; CAPE, capecitabine; CAPOX, oxaliplatin + capecitabine; CDDP, cisplatin; FOLFIRI, 5-fluorouracil + leucovorin + irinotecan; FOLFIRINOX, 5-fluorouracil + oxaliplatin + leucovorin + irinotecan; FOLFOX, 5-FU + oxaliplatin + leucovorin; GEM, gemcitabine; GEM + CAP, gemcitabine + capecitabine; GEM + S1, gemcitabine + tegafur/gimeracil/potassium; GEMOX, gemcitabine oxaliplatin; PEXG, cisplatin + eprubicin + capecitabine + gemcitabine; GTX, gemcitabine + T axotere + capecitabine; PD, progressive disease; PR, partial response; S1, tegafur/gimeracil/potassium; SD, stable disease.

cancer,⁵⁰ and pancreatic cancer.⁵¹ In our study, molecular analysis revealed germline BRCA2 in 2 patients with a familial history of breast and pancreatic cancer and achieved PR to

first-line FOLFIRINOX regimen. The authors preliminarily explored the value of olaparib maintenance treatment for 1 patient who had responded to the first-line FOLFIRINOX

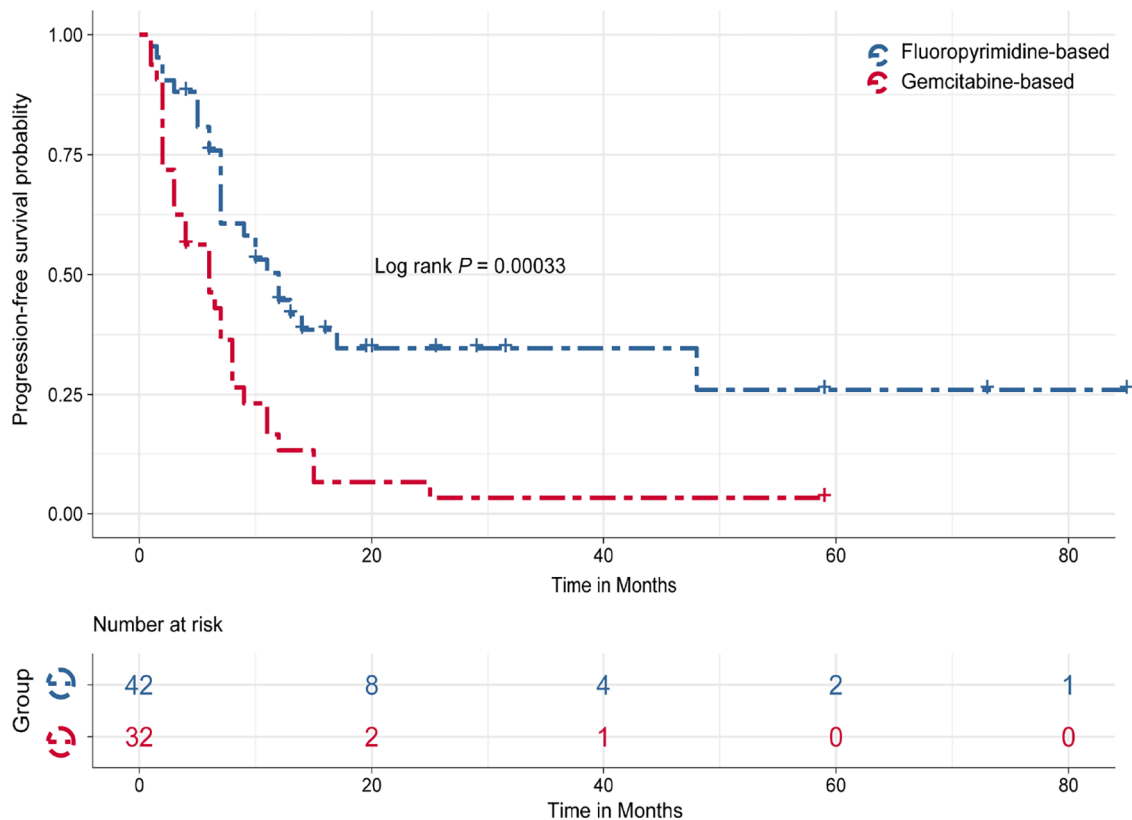


Figure 2. Kaplan–Meier plots of progression-free survival stratified by fluorouracil-based therapy and gemcitabine-based therapy for advanced PACC. PACC indicates pancreatic acinar cell carcinoma.

Table 5. Comparison of response between fluoropyrimidine-based regimen and gemcitabine-based regimen for metastatic PACC.

		GEMCITABINE-BASED		FLUOROPYRIMIDINE-BASED		P VALUE
		CASES	ORR (%)	CASES	ORR (%)	
Our study	First line (n=8)	3	0 (0)	5	4 (80)	>.05
	Second line (n=4)	2	0 (0)	2	2 (100)	>.05
Literatures	First line (n=86)	39	6 (15.3)	47	28 (59.6)	<.001
	Second line (n=29)	10	1 (10.0)	19	10 (52.6)	<.05

Abbreviations: ORR, objective response rate; PACC, pancreatic acinar cell carcinoma.

regimen and then received olaparib for 5 months with good tolerance. It may be crucial to establish the link between ACC and BRCA1/2 mutations, given the importance of recognizing potentially hereditary tumors and identifying patients who may benefit from platinum-based chemotherapy and targeted therapy.

The study has some limitations. First, it is a retrospective study from a single institution which resulted in an inherent selective bias. Second, the relatively small sample size and the imbalance in subgroups resulted in the deviation of analyses. Last, the meta-analysis lacks genomics and there were no criteria for the search engine to check the literature.

Conclusion

It was further confirmed that PACC is different from PDCC in clinicopathological and molecular characteristics and should have different management strategies and chemotherapy choices. Ki-67 and invasion of lymph-vascular invasion may be prognostic indicators for PACC. Although the benefit of adjuvant chemotherapy remained unclear, the value of fluoropyrimidine-based chemotherapy deserves attention. For patients with metastasis, fluorouracil-based chemotherapy such as FOLFIRINOX could be a preferred treatment, but more studies are needed for small sample size in this study. The maintenance treatment of PARP inhibitors after effective

platinum-containing treatment for BRAC mutation patients should be explored further.

Acknowledgements

We would like to thank all the subjects who participated in this study.

Author Contributions

F.-H.W. designed the study; J.-Y.X. and W.-L.G. performed data analysis and wrote the manuscript; X.-L.W., W.-J.S., C.R., S.-X.L., S.-P.L., and Y.-H.L. collected and interpreted data; and F.-H.W. and M.-Z.Q. reviewed and revised.

Availability of Data and Materials

Main data are shown in this article and additional data about this study could be obtained from the corresponding author on reasonable request.

Ethical Approval and Consent to Participate

The study protocol was approved by the institutional ethics committee of Sun Yat-sen University Cancer Center (approval number: B2022-050-01, approval date: July 19, 2021), and was carried out in full compliance with the principles of the “Declaration of Helsinki” (current revision) and “Good Clinical Practice” guideline. Written informed consent was obtained from all participants before the start of treatment or any study-related procedures.

ORCID iDs

Jian-Ying Xu  <https://orcid.org/0000-0003-3409-9873>

Wen-Jie Shi  <https://orcid.org/0000-0002-4588-4044>

REFERENCES

- Holen KD, Klimstra DS, Hummer A, et al. Clinical characteristics and outcomes from an institutional series of acinar cell carcinoma of the pancreas and related tumors. *J Clin Oncol*. 2002;20:4673-4678.
- Thompson ED, Wood LD. Pancreatic neoplasms with acinar differentiation: a review of pathologic and molecular features. *Arch Pathol Lab Med*. 2020;144:808-815.
- Mortenson MM, Katz MH, Tamm EP, et al. Current diagnosis and management of unusual pancreatic tumors. *Am J Surg*. 2008;196:100-113.
- Al-Hader A, Al-Rohil RN, Han H, Von Hoff D. Pancreatic acinar cell carcinoma: a review on molecular profiling of patient tumors. *World J Gastroenterol*. 2017;23:7945-7951.
- Butturini G, Pisano M, Scarpa A, D’Onofrio M, Auriemma A, Bassi C. Aggressive approach to acinar cell carcinoma of the pancreas: a single-institution experience and a literature review. *Langenbecks Arch Surg*. 2011;396:363-369.
- Wisnoski NC, Townsend CM Jr, Nealon WH, Freeman JL, Riall TS. 672 patients with acinar cell carcinoma of the pancreas: a population-based comparison to pancreatic adenocarcinoma. *Surgery*. 2008;144:141-148.
- Schmidt CM, Matos JM, Bentrem DJ, Talamonti MS, Lillemoe KD, Bilimoria KY. Acinar cell carcinoma of the pancreas in the United States: prognostic factors and comparison to ductal adenocarcinoma. *J Gastrointest Surg*. 2008;12:2078-2086.
- Kitagami H, Kondo S, Hirano S, Kawakami H, Egawa S, Tanaka M. Acinar cell carcinoma of the pancreas: clinical analysis of 115 patients from pancreatic cancer registry of Japan pancreas society. *Pancreas*. 2007;35:42-46.
- Matos JM, Schmidt CM, Turrini O, et al. Pancreatic acinar cell carcinoma: a multi-institutional study. *J Gastrointest Surg*. 2009;13:1495-1502.
- Klimstra DS, Heffess CS, Oertel JE, Rosai J. Acinar cell carcinoma of the pancreas. A clinicopathologic study of 28 cases. *Am J Surg Pathol*. 1992;16:815-837.
- Brunetti O, Aprile G, Marchetti P, et al. Systemic chemotherapy for advanced rare pancreatic histotype tumors: a retrospective multicenter analysis. *Pancreas*. 2018;47:759-771.
- Fujii M, Sato H, Ogasawara T, et al. [A case of liver metastasis of pancreatic acinar cell carcinoma treated with S-1 and intra-arterial CDDP combination therapy]. *Gan To Kagaku Ryobo*. 2010;37:1987-1990.
- Yokode M, Itai R, Yamashita Y, Zen Y. A case report of mixed acinar-endocrine carcinoma of the pancreas treated with S-1 chemotherapy: does it work or induce endocrine differentiation? *Medicine*. 2017;96:e8534.
- Seki Y, Okusaka T, Ikeda M, Morizane C, Ueno H. Four cases of pancreatic acinar cell carcinoma treated with gemcitabine or s-1 as a single agent. *Jpn J Clin Oncol*. 2009;39:751-755.
- Lowery MA, Klimstra DS, Shia J, et al. Acinar cell carcinoma of the pancreas: new genetic and treatment insights into a rare malignancy. *Oncologist*. 2011;16:1714-1720.
- Simon M, Bioulac-Sage P, Trillaud H, Blanc JF. Folfox regimen in pancreatic acinar cell carcinoma: case report and review of the literature. *Acta Oncol*. 2012;51:403-405.
- Abraham SC, Wu TT, Hruban RH, et al. Genetic and immunohistochemical analysis of pancreatic acinar cell carcinoma: frequent allelic loss on chromosome 11p and alterations in the APC/beta-catenin pathway. *Am J Pathol*. 2002;160:953-962.
- Kuji M, Yamamoto Y, Tani C, Kenno S, Kobayashi T. [A case of advanced pancreatic cancer responding well to s-1/gemcitabine combination therapy after gemcitabine therapy]. *Gan To Kagaku Ryobo*. 2011;38:853-855.
- Kruger S, Haas M, Burger PJ, et al. Acinar cell carcinoma of the pancreas: a rare disease with different diagnostic and therapeutic implications than ductal adenocarcinoma. *J Cancer Res Clin Oncol*. 2016;142:2585-2591.
- Toda H, Kurahara H, Maemura K, et al. [A case of curative resection for advanced pancreatic acinar cell carcinoma with liver metastasis and involvement of the superior mesenteric artery after chemoradiotherapy following systemic chemotherapy]. *Gan To Kagaku Ryobo*. 2016;43:2071-2073.
- Yamamoto T, Ohzato H, Fukunaga M, Imamura H, Furukawa H. Acinar cell carcinoma of the pancreas: a possible role of S-1 as chemotherapy for acinar cell carcinoma. A case report. *JOP*. 2012;13:87-90.
- Morishima K, Hyodo M, Nihei Y, Sata N, Yasuda Y. [A case of acinar cell carcinoma of pancreas with liver metastases treated effectively by s-1]. *Gan To Kagaku Ryobo*. 2010;37:127-129.
- Kanemasa Y, Kamisawa T, Tabata T, et al. Mixed acinar-endocrine carcinoma of the pancreas treated with S-1. *Clin J Gastroenterol*. 2013;6:459-464.
- Sumiyoshi T, Shima Y, Okabayashi T, et al. Long-term survival following pancreatotomy and s-1 chemotherapy for pancreatic acinar cell carcinoma with peritoneal dissemination: a case report and literature review. *Medicine (Baltimore)*. 2015;94:e378.
- Nishimizu T, Minemura M, Kajjura S, et al. [A case of pancreatic acinar cell carcinoma with a giant liver metastasis successfully treated with combination of gemcitabine and peroral S-1]. *Gan To Kagaku Ryobo*. 2011;38:309-312.
- Fukui H, Kou C, Matsumoto T, Matsumoto M. [S-1+gemcitabine (GEM) therapy effective in a case of pancreatic body cancer with multiple liver metastasis]. *Gan To Kagaku Ryobo*. 2010;37:1775-1778.
- Hatata T, Takaya S, Taniguchi K, Naka T, Kondo A, Ikeguchi M. [A case of complete response of gemcitabine (GEM) monotherapy-refractive liver metastatic pancreatic cancer treated with GEM+S-1 combined chemotherapy]. *Gan To Kagaku Ryobo*. 2011;38:109-112.
- Miyagawa K, Yata Y, Yamaoka N, Sagara Y. [A case of complete response (CR) to combination therapy of S-1 and gemcitabine (GEM) for unresectable pancreatic cancer]. *Gan To Kagaku Ryobo*. 2010;37:1145-1147.
- Fontenot J, Spieler B, Hudson C, Boulmay B. Pancreatic acinar cell carcinoma—literature review and case report of a 56-year-old man presenting with abdominal pain. *Radiol Case Rep*. 2020;15:39-43.
- Morales M, Cabrera MA, Maeso MD, Ferrer-López N. Use of panitumumab in the treatment of acinar cell carcinoma of the pancreas: a case report. *Oncol Lett*. 2013;5:969-971.
- Jordan EJ, Basturk O, Shia J, et al. Case report: primary acinar cell carcinoma of the liver treated with multimodality therapy. *J Gastrointest Oncol*. 2017;8:E65-E72.
- Ueki T, Okagawa K, Uemura Y, et al. Effective intra-arterial chemotherapy for acinar cell carcinoma of the pancreas. *Dig Surg*. 1999;16:76-79.
- Jauch SF, Morris VK, Jensen CT, Kaseb AO. Multimodal approach and long-term survival in a patient with recurrent metastatic acinar cell carcinoma of the pancreas: a case report. *Pancreatol*. 2016;16:153-156.
- Sorscher SM. Acinar cell carcinoma responding to carboplatin/etoposide chemotherapy. *J Gastrointest Cancer*. 2012;43:S2-S3.
- Callata-Carhuapoma HR, Pato Cour E, Garcia-Paredes B, et al. Pancreatic acinar cell carcinoma with bilateral ovarian metastases, panniculitis and polyarthritis treated with folfox chemotherapy regimen. A case report and review of the literature. *Pancreatol*. 2015;15:440-444.

36. Li M, Mou Y, Hou S, Cao D, Li A. Response of germline BRCA2-mutated advanced pancreatic acinar cell carcinoma to olaparib: a case report. *Medicine (Baltimore)*. 2018;97:e13113.
37. Yoshihiro T, Nio K, Tsuchihashi K, et al. Pancreatic acinar cell carcinoma presenting with panniculitis, successfully treated with folfinirox: a case report. *Mol Clin Oncol*. 2017;6:866-870.
38. Kryklyva V, Haj Mohammad N, Morsink FHM, et al. Pancreatic acinar cell carcinoma is associated with BRCA2 germline mutations: a case report and literature review. *Cancer Biol Ther*. 2019;20:949-955.
39. Schempf U, Sipos B, König C, Malek NP, Bitzer M, Plentz RR. Folfinirox as first-line treatment for unresectable acinar cell carcinoma of the pancreas: a case report. *Z Gastroenterol*. 2014;52:200-203.
40. Pfrommer S, Weber A, Dutkowski P, et al. Successful salvage chemotherapy with folfinirox for recurrent mixed acinar cell carcinoma and ductal adenocarcinoma of the pancreas in an adolescent patient. *Case Rep Oncol*. 2013;6:497-503.
41. Seth AK, Argani P, Campbell KA, et al. Acinar cell carcinoma of the pancreas: an institutional series of resected patients and review of the current literature. *J Gastrointest Surg*. 2008;12:1061-1067.
42. La Rosa S, Adsay V, Albarello L, et al. Clinicopathologic study of 62 acinar cell carcinomas of the pancreas: insights into the morphology and immunophenotype and search for prognostic markers. *Am J Surg Pathol*. 2012;36:1782-1795.
43. Patel DJ, Lutfi W, Sweigert P, et al. Clinically resectable acinar cell carcinoma of the pancreas: is there a benefit to adjuvant systemic therapy? *Am J Surg*. 2020;219:522-526.
44. Wang Y, Wang S, Zhou X, et al. Acinar cell carcinoma: a report of 19 cases with a brief review of the literature. *World J Surg Oncol*. 2016;14:172.
45. Hall JC, Marlow LA, Mathias AC, et al. Novel patient-derived xenograft mouse model for pancreatic acinar cell carcinoma demonstrates single agent activity of oxaliplatin. *J Transl Med*. 2016;14:129.
46. Yoo C, Kim BJ, Kim KP, et al. Efficacy of chemotherapy in patients with unresectable or metastatic pancreatic acinar cell carcinoma: potentially improved efficacy with oxaliplatin-containing regimen. *Cancer Res Treat*. 2017;49:759-765.
47. Wattenberg MM, Asch D, Yu S, et al. Platinum response characteristics of patients with pancreatic ductal adenocarcinoma and a germline BRCA1, BRCA2 or PALB2 mutation. *Br J Cancer*. 2020;122:333-339.
48. Chmielecki J, Hutchinson KE, Frampton GM, et al. Comprehensive genomic profiling of pancreatic acinar cell carcinomas identifies recurrent RAF fusions and frequent inactivation of DNA repair genes. *Cancer Discov*. 2014;4:1398-1405.
49. Moore K, Colombo N, Scambia G, et al. Maintenance olaparib in patients with newly diagnosed advanced ovarian cancer. *N Engl J Med*. 2018;379:2495-2505.
50. Olaparib for metastatic breast cancer in patients with a germline BRCA mutation. *N Engl J Med*. 2017;377:1700.
51. Golan T, Hammel P, Reni M, et al. Maintenance olaparib for germline BRCA-mutated metastatic pancreatic cancer. *N Engl J Med*. 2019;381:317-327.