

# Intravenous piperacillin/tazobactam plus fluoroquinolone prophylaxis prior to prostate ultrasound biopsy reduces serious infectious complications and is cost effective

Louis C Remyse III  
Patrick J Sweeney  
Kevin A Brewton  
Jay M Lonsway

Urology Associates of Battle Creek,  
PC, Battle Creek, MI, USA

**Abstract:** Infectious complications related to prostate ultrasound and biopsy have increased in the past decade with the emergence of increasing fluoroquinolone bacterial resistance. We investigated the addition of intravenous (iv) piperacillin/tazobactam immediately prior to prostate ultrasound and biopsy with standard fluoroquinolone prophylaxis to determine if it would decrease the incidence of serious infectious complications after prostate ultrasound and biopsy. Group 1 patients were a historic control of 197 patients who underwent prostate ultrasound and biopsy with standard fluoroquinolone prophylaxis. Group 2 patients, 104 patients, received standard fluoroquinolone prophylaxis and the addition of a single dose of iv piperacillin/tazobactam 30 minutes prior to prostate ultrasound and biopsy. There were ten serious bacterial infectious complications in group 1 patients. No patients in group 2 developed serious bacterial infections after prostate ultrasound and biopsy. There was approximately a 5% incidence of serious bacterial infection in group 1 patients. Subgroup analysis revealed an almost 2.5 times increased risk of infection in diabetes patients undergoing prostate ultrasound and biopsy. There was a 10% risk of serious bacterial infection in diabetics compared with a 3.8% risk group 1 nondiabetes patients. The addition of a single dose of iv piperacillin/tazobactam along with standard fluoroquinolone prophylaxis substantially reduces the risk of serious bacterial infection after prostate ultrasound and biopsy ( $P < 0.02$ ).

**Keywords:** piperacillin/tazobactam, fluoroquinolone, prostate biopsy, infectious complications

## Introduction

The incidence of infectious complications after transrectal ultrasound and biopsy of the prostate has increased over the past several years.<sup>1-3</sup> Most patients receive an oral fluoroquinolone prior to biopsy as previously recommended in the best practice policy statement on urologic surgery antimicrobial prophylaxis.<sup>4</sup> There is concern that with increasing fluoroquinolone resistance a change or modification in antibiotic prophylaxis prior to transrectal ultrasound biopsy of the prostate may be necessary to minimize serious infectious complications. We have noted a gradual increase in the frequency of serious infectious complications after transrectal ultrasound-guided prostate biopsy in our patients; this has prompted us to look at alternative forms of antibiotic prophylaxis prior to prostate biopsy. Previous studies have reported decreased risk of infection with the use of piperacillin/tazobactam prior to prostate ultrasound and biopsy.<sup>5-7</sup>

Correspondence: Louis C Remyse III  
Urology Associates of Battle Creek,  
PC, 4441 Capital Avenue SW,  
Battle Creek, MI 49015, USA  
Tel +1 269 788 6888  
Fax +1 269 788 6889  
Email [runtosail@aol.com](mailto:runtosail@aol.com)

In our community the 2011 AntibioGram<sup>8</sup> indicates *Escherichia coli* sensitivity to levofloxacin 77%, piperacillin/tazobactam 98%, and imipenem 99%; amikacin not evaluated. Previous patients who were admitted for infectious complications after undergoing prostate ultrasound and biopsy were placed on piperacillin/tazobactam by our infectious disease consultants. We have noted that uniformly the bacteria isolated in blood cultures and urine cultures in our patients were uniformly sensitive to this antibiotic.

## Materials and methods

Patient charts were reviewed from Urology Associates of Battle Creek, PC. One hundred ninety-seven patients underwent prostate ultrasound and biopsy between January and November 2010 (group 1). All patients had documented negative urinalysis prior to biopsy, or if there was any concern about the possibility of infection were documented negative urine culture prior to biopsy. All patients received standard double sextant biopsies, and occasionally one or two additional biopsies if there was a specific abnormality noted at the time of ultrasound.

All ten patients in group 1 with infections after biopsy received standard double sextant biopsy only.

All patients received fluoroquinolone prophylaxis prior to biopsy; 196 patients were started on either ciprofloxacin or levofloxacin 24 hours prior to biopsy, fluoroquinolone on the day of biopsy and the day following biopsy. Most patients also received intramuscular (im) gentamicin 80 mg 1 hour prior to procedure. One patient with a fluoroquinolone allergy received trimethoprim/sulfamethoxazole double strength orally beginning the day prior to biopsy, the day of biopsy, and the day following biopsy.

After review of the complications which occurred in group 1 following prostate ultrasound and biopsy, we subsequently changed our antibiotic prophylaxis beginning in December 2010. Group 2 patients included 104 patients who continued to receive oral fluoroquinolone prophylaxis with either ciprofloxacin or levofloxacin beginning the day before biopsy, the day of biopsy and for 1 or 2 days after biopsy depending upon physician preference. Patients also received intravenous iv piperacillin/tazobactam 3.375 g administered within 60 minutes prior to undergoing biopsy procedure by a registered nurse in our office. All patients were informed of the addition of the iv antibiotic infusion to standard fluoroquinolone prophylaxis in the attempt to decrease serious infectious complications following the procedure. All biopsies were subsequently performed within 30 minutes after completion of iv antibiotic infusion.

All biopsies were performed by one of the authors (LCD), a urologist.

One patient in group 2 received iv amikacin 500 mg prior to prostate ultrasound guided biopsy. This patient had a penicillin allergy and is not included in our results analysis. All patients were then seen in the office within 10 days after biopsy for follow-up, including urinalysis. All patients who presented to the office with fever or other signs of infection were evaluated with complete blood count, blood, and urine cultures prior to antibiotic therapy.

There were 40 patients in group 1 with adult onset diabetes mellitus, and 21 patients in group 2 with adult onset diabetes mellitus.

Hospital records were subsequently reviewed for the patients requiring admission after prostate ultrasound and biopsy. Rather than looking at hospital charges, insurance reimbursement was evaluated in determining the actual cost of treatment for complications after prostate ultrasound and biopsy. Average hospital reimbursement was US\$5410 for group 1 patients who required hospitalization. A total of six patients were hospitalized with infectious complications after biopsy.

## Results

Ten patients from group 1 developed symptoms of infection after biopsy. Six patients required hospitalization after biopsy because of symptoms of infection. Three patients had positive blood and urine cultures for *E. coli* resistant to fluoroquinolones, one of whom had positive blood cultures and negative urine culture for *E. coli* resistant to fluoroquinolones. Two of the patients with positive blood cultures were subsequently treated with placement of a PICC line and outpatient iv antibiotics. The remaining two patients with positive blood and urine cultures were treated as outpatients with oral antibiotic. One patient with positive blood and urine culture required intensive care unit admission with less than 24 hours of iv norepinephrine for blood pressure support. The two patients admitted with positive urine culture and negative blood cultures were subsequently treated as outpatients with oral antibiotics. The remaining four patients were not hospitalized and had positive urine cultures and negative blood cultures for *E. coli*-resistant to fluoroquinolones and were subsequently treated with oral antibiotics as outpatients. Patients treated as outpatients were not included in our cost analysis.

No patients in group 2 who have received a combination of standard fluoroquinolone prophylaxis and iv piperacillin/tazobactam prior to undergoing prostate ultrasound and biopsy developed significant complications

after biopsy requiring hospitalization. No patients have developed fever, chills, or other symptoms after this procedure that would be considered symptomatic for potential bacteremia.

The one patient in group 2 who received iv amikacin prior to PUS/Bx developed fever and leukocytosis 36 hours after biopsy. The patient had a post biopsy urine culture positive for *E. coli* which was resistant to levofloxacin and sensitive to gentamicin. The blood culture was negative. The patient was treated as an outpatient with trimethoprim/sulfamethoxazole double strength.

One patient who received standard fluoroquinolone prophylaxis and iv piperacillin/tazobactam prior to ultrasound and biopsy developed a urinary tract infection with *E. coli* resistant to fluoroquinolones after the biopsy procedure. This patient presented with symptoms of lower urinary tract infection with no fever, leukocytosis, or other symptoms of bacteremia. This patient was treated as an outpatient with oral antibiotic, and not included in analysis.

Within group 1, four of the ten infectious complications occurred in patients with adult onset diabetes. This represents approximately 10% risk of serious infection and patients with diabetes undergoing prostate ultrasound and biopsy, compared with a 3.8% risk of serious bacterial infection in group 1 patients without a diagnosis of diabetes.

No patients developed allergic reactions or other side effects with iv piperacillin/tazobactam. Because only a single dose was infused, there is no dose adjustment for renal insufficiency.

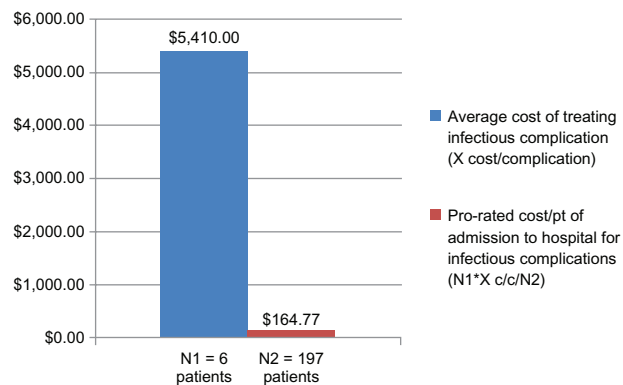
Chi square analysis revealed that the addition of a single dose of iv piperacillin/tazobactam plus standard fluoroquinolone prophylaxis reduced the risk of infection ( $P < 0.02$ ; Table 1).

### Cost of supplies and reimbursement

For group 2 patients Medicare reimbursement (US\$) was \$68.57 for infusion reimbursement, \$16.64 reimbursement for piperacillin/tazobactam, and total reimbursement was \$85.21 (Figure 2).

**Table 1** Chi square analysis chart ( $P \leq 0.02$ )

	Positive infection	Negative infection	Total
Piperacillin/tazobactam and fluoroquinolone	0	104	104
Fluoroquinolone	10	187	197
Total	10	291	301



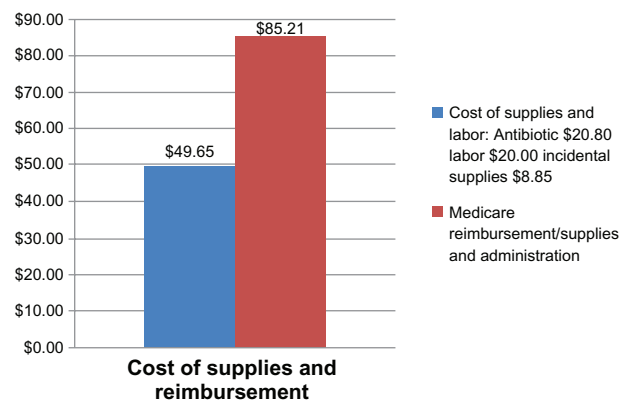
**Figure 1** Cost (US\$) of treating complications in group 1 compared with the cost of administering prophylactic intravenous piperacillin/tazobactam.

The pro-rated cost for treating an expected or future complication per patient undergoing this procedure would be calculated at \$164.77 per anticipated hospitalization.

Figure 1 illustrates the cost of treating complications in group 1 compared with the cost of administering prophylactic iv piperacillin/tazobactam prior to prostate ultrasound and biopsy. Figure 2 demonstrates the cost versus reimbursement for the individual physician practice of administering piperacillin/tazobactam. Table 2 demonstrates a potential cost-savings of approximately \$80 per patient undergoing this procedure.

### Discussion

Transrectal ultrasound and biopsy for diagnosis of prostate cancer is a very common procedure in urologic practice. Approximately 800,000 biopsies are performed annually in the United States. The majority of patients receive fluoroquinolone prophylaxis as recommended by the American Urological Association best practice statement.<sup>4</sup> However, there appears to be increasing incidence of serious infectious complications after this procedure with *E. coli* resistant to



**Figure 2** Cost (US\$) vs reimbursement.

**Table 2** Cost effectiveness of administering additional antibiotics

(Pro-rated cost/patient of additional hospitalization for infectious complications \$164.77) – reimbursement/supplies and administration \$85.21 = \$79.56 the potential cost savings per/patient of iv piperacillin/tazobactam

fluoroquinolones. Our individual group practice has noticed this over the past few years, and others have reported this trend. Our local Antibiogram also demonstrates the increasing prevalence of *E. coli* resistant to fluoroquinolones in the community setting. Recently a new technique for potentially screening for fluoroquinolone resistance prior to biopsy has been published. This group noted a 22% overall fluoroquinolone resistance rate and bacteria in patients prior to undergoing biopsy. However, this may have been a highly selective group of patients given that the average patient had already undergone more than one prior prostate ultrasound and biopsy.<sup>9</sup> It would be interesting to know if the reported *E. coli* antibiotic resistance patterns correspond with local Antibiograms, or whether there is a selection bias, since the majority of the patients in this study had undergone prior PUS/Bx procedures. Also, further study needs to be performed to determine if this type of screening mechanism predicts the appropriate choice of antibiotic to minimize infectious complications after prostate ultrasound and biopsy.

The choice of piperacillin/tazobactam was determined by review of our local Antibiogram, and consultation with local infectious disease specialist prior to proceeding. Over the preceding 2 years all patients admitted to our local hospitals with febrile infections after PUS/Bx were started on piperacillin/tazobactam while urine and blood culture results were pending. From review of all our local antibiogram, imipenem, 99%, and piperacillin/tazobactam provided the highest coverage for *E. coli*, 98%. There is a theoretical potential benefit of ceftriaxone with a longer half-life compared with piperacillin/tazobactam. Of the ten group 1 patients who developed serious infections after prostate ultrasound and biopsy we noticed that three had *E. coli* resistant to ceftriaxone. For this reason, we choose iv infusion, rather than im injection, to reliably achieve peak plasma concentrations immediately prior to performing PUS/Bx. Our hypothesis was that many of the serious infectious complications occurring after prostate ultrasound and biopsy results from the iv access of bacteria to the bloodstream at the time of biopsy. This was our rationale for iv infusion of piperacillin/tazobactam rather than im to reliably achieve peak serum levels at the time of prostate ultrasound and biopsy.

Intravenous piperacillin/tazobactam was infused by a registered nurse in our office. This nurse had no previous iv infusion experience. On average, this nurse is able to perform the infusion in less than 30 minutes.

No patients in the piperacillin/tazobactam plus fluoroquinolone group developed febrile infectious complications after PUS/Bx. No patients required hospitalization. One patient developed symptomatic dysuria without associated fever or other constitutional symptoms and was treated as an outpatient. The purpose of this study was to determine if iv piperacillin/tazobactam decreased the incidence of serious febrile complications requiring hospitalization after prostate ultrasound and biopsy.

The addition of piperacillin/tazobactam to fluoroquinolone prophylaxis prior to PUS/Bx is cost effective for the physician office. Medicare reimbursement for the medication and infusion is cost effective (see Table 2). For the Medicare/Private Payers it also appears cost effective. The cost of administering the additional antibiotic is more than offset by the health care dollar savings in reduced hospitalizations secondary to infectious complications after PUS/Bx (see Table 2).

## Summary

It is agonizing for a community urologist to perform a prostate ultrasound and biopsy for diagnosis of prostate cancer and then subsequently have patients develop serious complications requiring hospitalization for what otherwise appears to be such a minimally invasive procedure. When these patients present to the office with fever and other signs of bacteremia after the procedure, they truly are ill.

The addition of 3.375 g iv piperacillin/tazobactam 30 minutes prior to PUS/Bx plus standard fluoroquinolone prophylaxis substantially reduced the risk of potentially life-threatening infectious complications after PUS/Bx in our study. Our patients had previously received im gentamicin 1 hour prior to PUS/Bx; therefore, the additional time for iv infusion was not particularly disruptive to our practice's patient flow. This regimen has also been shown to be cost effective for insurance carriers and for physician practices.

Our study indicates a serious complication rate of approximately 3%. Serious complication rate is defined by admission for hospitalization secondary to symptoms of bacteremia after prostate ultrasound and biopsy. The addition of iv piperacillin/tazobactam prior to prostate ultrasound and biopsy substantially reduced the serious complication rate ( $P \leq 0.02$ ). Our study also suggests a significantly increased

risk of infectious complications in patients with adult onset diabetes mellitus undergoing prostate ultrasound and biopsy. This may be a subgroup of patients in whom iv prophylaxis with piperacillin/tazobactam and standard fluoroquinolone administration may be especially beneficial. There is the potential concern that with widespread adoption of a single dose of iv piperacillin/tazobactam antibiotic resistance in *E. coli* may increase. However, this needs to be balanced against the already significant emergency of fluoroquinolone-resistant *E. coli* and the continuing increase incidence of serious complications after prostate ultrasound and biopsy. With nearly 800,000 prostate ultrasound biopsies performed annually in the United States, there is a potential cost savings of approximately \$64 million if severe infectious complication after biopsy requiring hospitalization can be eliminated.

## Disclosure

The authors report no conflicts of interest in this work.

## References

1. Patel U, Kirby R. Infections after prostate biopsy and antibiotic resistance. *BJU Int.* 2008;101:1201–1202.
2. Feliciano J, Teper E, Ferrandino M, et al. The incidence of fluoroquinolone resistant infections after prostate biopsy – are fluoroquinolones still effective prophylaxis? *J Urol.* 2008;179:952–955.
3. Uddin MM, Ho HSS, Ng LG, et al. Transrectal prostate biopsy sepsis: trends in its bacteriology and antibiotic prophylaxis in a single center over 8 years. *J Urol.* 2010;183 Suppl e315:abstract 807.
4. Wolf JS Jr, Bennett CJ, Dmochowski RR, et al. Best practice policy statement on urologic surgery antimicrobial prophylaxis. *J Urol.* 2008;179:1379–1390.
5. Brewster S, MacGowan A, Gingell J. Antimicrobial prophylaxis for transrectal prostatic biopsy: a prospective randomized trial of cefuroxime versus piperacillin/tazobactam. *Br J Urol.* 1995;76:351–354.
6. Cormio L, Berardi B, Callea A, et al. Antimicrobial prophylaxis for transrectal prostatic biopsy: a prospective study of ciprofloxacin vs piperacillin/tazobactam. *BJU Int.* 2002;90:700–702.
7. Shigemura K, Yasufufu T, Matsumoto M, et al. Can penicillin including beta-lactamase inhibitor overcome febrile complications after transrectal prostate biopsy? *J Urol.* 2010;183 Suppl e316:abstract 809.
8. Clemmens-Funke L, Bittner S, Harrington G. Antibiogram: Regional Medical Laboratory, Battle Creek, MI; 2011.
9. Liss MA, Chang A, Santos R, et al. Prevalence and significance of fluoroquinolone resistant *Escherichia coli* in patients undergoing transrectal ultrasound guided prostate needle biopsy. *J Urol.* 2011;185:1283–1288.

Open Access Journal of Urology

Publish your work in this journal

The Open Access Journal of Urology is an international, peer-reviewed, open access journal publishing original research, reports, editorials, reviews and commentaries on all aspects of adult and pediatric urology in the clinic and laboratory including the following topics: Pathology, pathophysiology of urological disease; Investigation and treatment of

Submit your manuscript here: <http://www.dovepress.com/open-access-journal-of-urology-journal>

Dovepress

urological disease; Pharmacology of drugs used for the treatment of urological disease. The manuscript management system is completely online and includes a very quick and fair peer-review system, which is all easy to use. Visit <http://www.dovepress.com/testimonials.php> to read real quotes from published authors.