

# Evaluation of the Effect of Combined Low Energy Laser Application and Micro-Osteoperforations versus the Effect of Application of Each Technique Separately On the Rate of Orthodontic Tooth Movement

Ahmed Nasef Abdelhameed<sup>1\*</sup>, Wael Mohamed Mubarak Refai<sup>2</sup>

<sup>1</sup>Faculty of Dentistry, Minya University, Minya, Egypt; <sup>2</sup>Orthodontic Department, Faculty of Dentistry, Minya University, Minya, Egypt

## Abstract

**Citation:** Abdelhameed AN, Refai WMM. Evaluation of the Effect of Combined Low Energy Laser Application and Micro-Osteoperforations versus the Effect of Application of Each Technique Separately On the Rate of Orthodontic Tooth Movement. Open Access Maced J Med Sci. 2018 Nov 25; 6(11):2180-2185. <https://doi.org/10.3889/oamjms.2018.386>

**Keywords:** LLLT; Micro-osteoperforations; OTM; Orthodontic mini-screws

**\*Correspondence:** Ahmed Nasef Abdelhameed, Faculty of Dentistry, Minya University, Minya, Egypt. E-mail: [ahmed.nasef@mu.edu.eg](mailto:ahmed.nasef@mu.edu.eg)

**Received:** 12-Sep-2018; **Revised:** 16-Oct-2018; **Accepted:** 17-Oct-2018; **Online first:** 15-Nov-2018

**Copyright:** © 2018 Ahmed Nasef Abdelhameed, Wael Mohamed Mubarak Refai. This is an open-access article distributed under the terms of the Creative Commons Attribution-NonCommercial 4.0 International License (CC BY-NC 4.0)

**Funding:** This research did not receive any financial support

**Competing Interests:** The authors have declared that no competing interests exist

**AIM:** The study was conducted to evaluate the effect of combined low energy laser application and Micro-Osteoperforations versus the effect of the application of each technique separately on the rate of orthodontic tooth movement.

**PATIENTS AND METHODS:** Three parallel groups (each group contained 10 patients) were performed; Group A: In which one side was controlled side, and the other side received micro-osteoperforations (MOPs), Group B: In which one side was controlled side, and the other side received low-level laser therapy (LLLTL), Group C: In which one side was controlled side, and the other side received both MOPs and LLLTL.

**RESULTS:** Significant statistical differences were obvious in the rate of canine retraction between each intervention and the control sides as following; the MOPs increased the rate of canine retraction by 1.6 fold more than the control side, LLLTL increased the rate of canine retraction by 1.3 fold than the control side, and combination of both techniques resulted in an increase in the rate of canine retraction by 1.8 fold more than the control side.

**CONCLUSION:** Combination of MOPs and LLLTL proved to be more efficient regarding increasing the rate of canine retraction than the application of each technique separately.

## Introduction

Orthodontic treatment usually requires a long duration of about 2-3 years [1], which poses a high risk of caries [2], external root resorption [3], and decreased patient compliance [4]. Several methods are used to accelerate orthodontic tooth movement and shorten the duration of orthodontic treatment. Varieties of Surgical (corticotomy and micro-osteoperforation) and physical (electric current and LASER) methods were proposed based on our understanding of the biology of OTM [5].

Surgical corticotomy is one of the popular and widely used techniques to accelerate OTM, manipulation of anchorage, facilitating molar intrusion and molar distalization [6]. Although different surgical corticotomy techniques were attempted by many investigators [7] [8] [9], a Regional acceleratory phenomenon (RAP) is the main basic effect of corticotomy in accelerating OTM [10] [11].

In spite of all these facts, corticotomy is still an invasive surgical treatment which may cause some side effects such as, post-operative bleeding, pain, and negative impact on patient quality of life [12]. So, many other surgical less invasive techniques appeared to minimize these side effects. One of these

less invasive surgical techniques is micro-osteoperforation (MOP) [13].

Micro-osteoperforation is a surgical less invasive technique which can accelerate OTM creating predictable results. MOP can be completed chairside in a minute and does not require any advanced training [14].

Since the development of the first LASER by Maiman in 1960 [15], dental interest in lasers has been high, and research has been continuing into ways to improve dental treatment through laser application. The convenient and versatile nature of laser device has encouraged orthodontists to use it in several applications as, in diagnostic procedures, prevention of white spot lesions, bracket debonding and minor surgical procedures like gingivectomy and frenectomy.

Also, Soft laser therapy is a special category of laser application in orthodontic treatment. It is known as Low-Level energy Laser Therapy (LLLT) or as cold laser therapy. The discovery of the bio-stimulatory effect of LLLT in 1967 paved its way to be used in many indications especially in the acceleration of OTM [16], retention protocols [17], and in pain reduction [18].

From all of the previously mentioned, it was beneficial to compare between micro-osteoperforation as a less invasive surgical technique and LLLT as a non-invasive technique for acceleration of OTM. It was also a point of worthy investigation to combine both techniques aiming that there is a synergistic effect resulting from this combination.

## Patients and Methods

30 patients were recruited from the Outpatient Clinic at the Department of Orthodontics, Faculty of Dentistry, Minia University with the following inclusion criteria; Age ranged from 15 to 25 years, from both sex, Healthy general medical condition, Healthy periodontal condition, Malocclusion that requires extraction of the maxillary first premolars, followed by canine retraction (dental full unit class II canine relationship or bi-maxillary protrusion), Normal shape and structure of maxillary canine, with no history of filling or root canal treatment and Normal shape and structure of maxillary first molar.

Full explanation to the patients and or parents was performed regarding the study, interventions, and possible side effects. Informed consent was submitted either by the patients and or parents. All safety precautions were followed during laser application.

At first, all patients were referred to an oral surgeon to perform extraction for the first premolars and wait for 6 weeks as a healing period followed by

the beginning of orthodontic treatment till finishing the phase of levelling and alignment. Mini-screws were inserted between 1st molar and 2nd premolar which was used directly for canine retraction. Ligaturing of the upper incisors together by a ligature wire was taken into consideration.

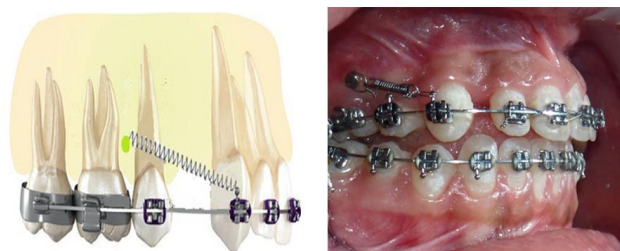

Figure 1: Lateral view of coil spring attached to canine hook and mini-screw

Group (A) contained a split-mouth study design in which one side was controlled side, and the other side received micro-osteoperforations (MOPs). Group (B) contained a split-mouth study design in which one side was controlled side, and the other side received low-level laser therapy (LLLT). Group (C) contained split-mouth study design in which one side was controlled side, and the other side received both MOPs and LLLT.

Assignment of patients and the sides of interventions were performed as following; Computer-generated random numbers was done using Microsoft Office Excel 2013 sheet. All of the 30 patients were firstly randomly assigned to one of the three groups. Then, the right sides of every 10 patients of each group were randomly assigned to be either the intervention side or control side while the left sides were automatically assigned to the choice.

Standardised canine retraction directly on the mini-screw using closing coil spring giving standard force (150 g) assured by usage of force gauge (Figure 1).

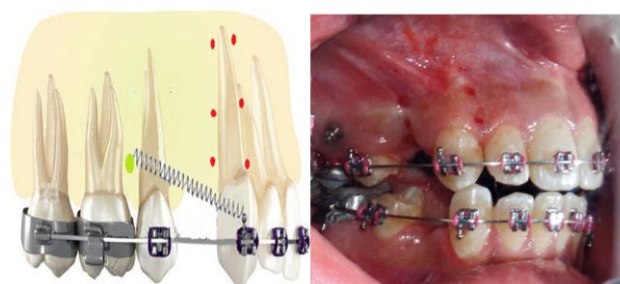


Figure 2: Lateral view showing micro-osteoperforations performed along the root of the canine

In this study, 12 MOPs were applied with a depth of 6 mm and were distributed as follows; Three MOPs were done buccally between the canine and lateral incisor roots. Three MOPs buccally were done between the canine root and the socket of the

extracted premolar. Three MOPs were done palatally between the canine and lateral incisor roots. Three MOPs were done palatally between the canine root and the socket of the extracted premolar. The technique was repeated every two weeks, so MOPs were performed 6 times as the study extended over 3 months (Figure 2).

**Micro-osteoperforation tool:** The aim was to create multiple pores with a certain depth (range from 3:7mm) in the alveolar bone. So, Mini-screws were used with a 1.6mm diameter and 8mm length to perform the intended perforations. That when the length of mini-screw is 8mm, and the gingival thickness is 2mm, the efficient depth of perforation in the alveolar bone will equal 6mm (Figure 3).

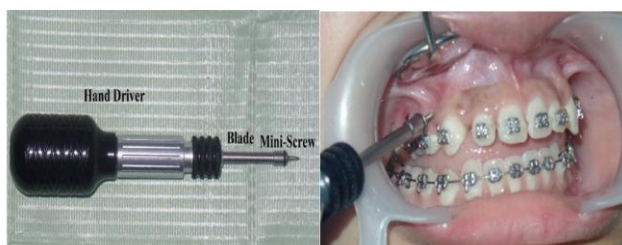

Figure 3: The used MOPs tool

The soft laser was applied using a laser machine (*DenLase-810/7*) (Figure 4) with the following specifications; Dimensions (W x H x D): 130 x 190 x 180 mm, Weight: approx. 1.5 kg, Display: LCD Touch Screen, Cooling: air-cooling, Wavelength:  $810 \pm 10$  nm, Output power:  $0.5 \text{ W/cm}^2$ , Operation modes: continuous wave (CW).

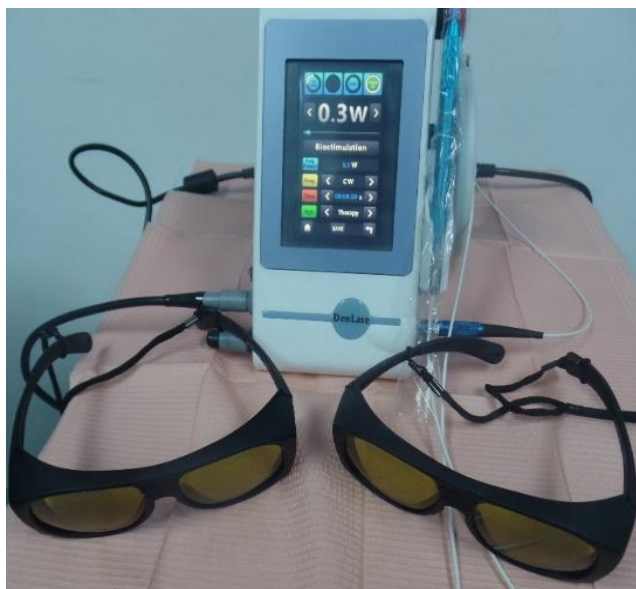

Figure 4: Laser device and the protective eyeglasses

The 1<sup>st</sup> application was at the beginning of a canine retraction, the 2<sup>nd</sup> application was after three days from the beginning of a canine retraction, the 3<sup>rd</sup> application was after one week from the beginning of

a canine retraction, the 4<sup>th</sup> application was after two weeks from beginning of canine retraction, then every two weeks along three months period of the intervention.

Application of laser was carried out from buccal and palatal surfaces along the root of the canine through lens specific for low-level laser therapy and biostimulation (Figure 5).

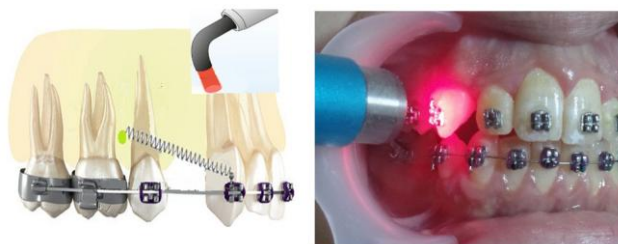


Figure 5: Lateral view showing laser application

Application of both techniques (MOPs and LLLT) was performed following the same protocols mentioned previously.

Data for the evaluation of each intervention were collected by direct intra-oral measurements. The measurement was taken from the canine cusp tip to the mesiobuccal cusp tip of the maxillary 1st molar using digital intra-oral calliper (Figure 6). Measurements were taken immediately before the beginning of canine retraction and every two weeks along three months following.

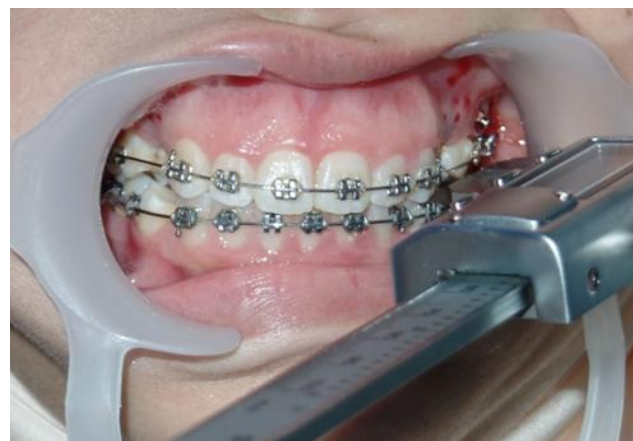

Figure 6: Intra-oral usage of a digital calliper

## Results

During the study, there was one dropout patient in (Group C). Also, there was some missing appointments which were all recorded as follow; Group (A), two missing patient appointments at the 4<sup>th</sup> and 10<sup>th</sup> weeks. Group (B), one missing patient appointment at the 10<sup>th</sup> week. Group (C), no missing



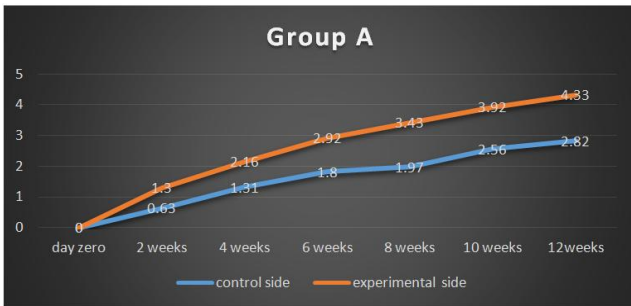patient appointments but there was one dropout patient as mentioned previously.

Measurements were taken every two weeks for three months follow up duration in all groups of the study. The measurements were taken from the canine cusp tip to the 1<sup>st</sup> molar mesiobuccal cusp tip. Outcomes of the rate of canine retraction showed a normal distribution of data. Consequently, parametric tests were chosen to evaluate the statistical significance of each group (independent sample t-test).

**Table 1: Results of independent sample t-test for the mean distance (mm) travelled by the maxillary canine on both control side and MOPs side**

Duration	No. of patients	Control side		Experimental side		Independent sample t-test		
		Mean	SD	Mean	SD	Mean Diff.	Std. Error Mean	P- value
2 weeks	10	0.63 ± 0.62		1.3 ± 0.12		0.67	.00422	0.000
4 weeks	9	1.31 ± 0.23		2.16 ± 0.27		0.85	.00314	0.000
6 weeks	10	1.8 ± 0.66		2.92 ± 0.73		1.12	.00133	0.000
8 weeks	10	1.97 ± 0.76		3.43 ± 0.66		1.46	.00149	0.001
10 weeks	9	2.56 ± 0.83		3.92 ± 0.88		1.36	.00258	0.001
12 weeks	10	2.82 ± 0.39		4.33 ± 0.64		1.51	.09784	0.001

Table 1 and Figure 7 show the independent sample t-test for the mean distance travelled by the maxillary canine on both the control and the experimental (MOPs) sides indicating the highly significant difference.

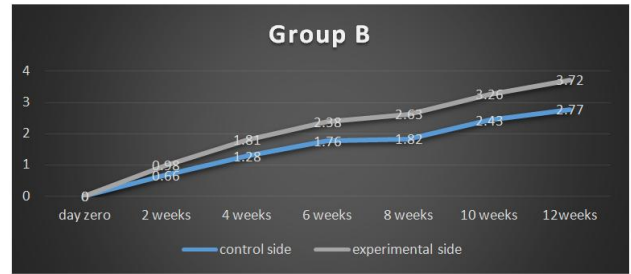

**Figure 7: Graphic representation of the mean distance travelled by the maxillary canine about the baseline in group A**

Table 2 and Figure 8 show the independent sample t-test for the mean distance travelled by the maxillary canine on both the control and the experimental (MOPs) sides indicating the highly significant difference.

**Table 2: Results of independent sample t-test for the mean distance (mm) travelled by the maxillary canine on both control side and LLLT side**

Duration	No. of patients	Control side		Experimental side		Independent sample t test		
		Mean	SD	Mean	SD	Mean Diff.	Std. Error	P- value
2 weeks	9	0.66 ± 0.55		0.98 ± 0.27		0.32	.00432	0.001
4 weeks	10	1.28 ± 0.48		1.81 ± 0.39		0.53	.003125	0.001
6 weeks	10	1.76 ± 0.83		2.38 ± 0.27		0.62	.00149	0.001
8 weeks	10	1.82 ± 0.63		2.63 ± 0.87		0.81	.02353	0.001
10 weeks	9	2.43 ± 0.23		3.26 ± 0.89		0.83	.06232	0.001
12 weeks	10	2.77 ± 0.37		3.72 ± 0.71		0.95	0.0432	0.001



**Figure 8: Graphic representation of the mean distance travelled by the maxillary canine about the baseline in group B**

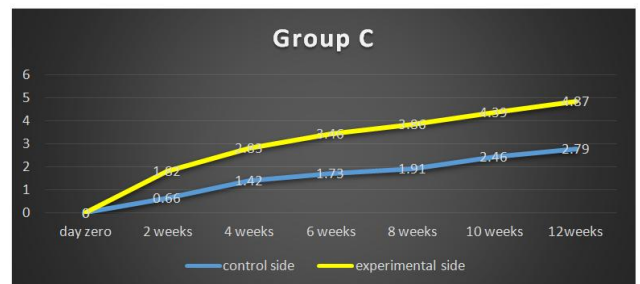Table 3 and Figure 9 show the independent sample t-test for the mean distance travelled by the maxillary canine on both the control and the experimental (MOPs) sides indicating the highly significant difference.

**Table 3: Results of independent sample t-test for the mean distance (mm) travelled by the maxillary canine on both control side and combined MOPs & LLLT side**

Duration	No. of patients	Control side		Experimental side		Independent sample t test		
		Mean	SD	Mean	SD	Mean Diff.	Std. Error	P- value
2 weeks	10	0.66 ± 0.76		1.82 ± 0.19		1.16	.01562	0.000
4 weeks	10	1.42 ± 0.66		2.83 ± 0.12		1.41	.00223	0.000
6 weeks	10	1.73 ± 0.39		3.46 ± 0.64		1.73	.02295	0.000
8 weeks	10	1.91 ± 0.83		3.86 ± 0.27		1.95	.03549	0.000
10 weeks	9	2.46 ± 0.62		4.39 ± 0.73		1.93	.08654	0.00
12 weeks	9	2.79 ± 0.23		4.87 ± 0.88		2.08	.09853	0.000

## Discussion

According to Thiruvengkatachari et al. (19) and Aboul-Ela et al., [7], titanium mini-screws provided a simple, efficient anchorage for canine retraction. Direct anchorage during canine retraction using mini-screw placed between 2<sup>nd</sup> premolar and 1<sup>st</sup> permanent molar was chosen to eliminate any molar anchorage loss which may give misleading results during measurements.



**Figure 9: Graphic representation of the mean distance travelled by the maxillary canine in reference to the baseline in group C**

Many techniques [20] [21] [22] are available to perform retraction of the canine in the extraction space regarding anchorage preparation and the force

used of retraction (amount, direction, and force decay). Standardization of the technique of canine retraction was a must so, the use of mini-screws was decided as a direct anchor for retraction of the canine as well as closing coil spring was used providing continuous 150 g of force for canine retraction. This force magnitude was advocated by Barlow and Kula [23], who in a systematic review, concluded that 200 g did not offer any benefit in the rate of canine retraction compared to 150 g.

Direct intra-oral measurements statistical analysis from Group A illustrated that the rate of canine retraction in the MOPs side was higher by nearly 1.6 fold in comparison to standard canine retraction in three months period.

The highest rate was observed during the 1<sup>st</sup> four weeks measuring nearly 0.9 mm every two weeks which was agreed by other clinical trials [10] [11] [12] and was explained by the accelerator effect of the MOPs procedure which is at its maximum in the 1<sup>st</sup> month. Wilcko et al., [24], theorised that the rapid orthodontic canine retraction and minimal apical root resorption that accompanied AOO/PAOO were attributable to increased regional bone turn over (the regional acceleratory phenomenon) and the associated osteopenia, i.e. calcium depletion and diminished bone density, precipitated by selective decortication. They further explained that the dynamics of the physiologic tooth movement in these patients might be more appropriately described as bone matrix transportation.

The rate of tooth movement is controlled by osteoclast recruitment and activation [6]. Therefore, regardless of the shape or the extent of the cut, bone resorption will not occur unless osteoclasts are activated. This means that similar to micro-osteoperforations, the effectiveness of corticotomy [8] or piezocision [9] can be related to the activation of cytokines that are released in response to the trauma induced during the cuts. The release of cytokines is expected to be significantly higher in corticotomy and piezocision in comparison with micro-osteoperforations due to the more invasive nature of these procedures and the extensive trauma to the bone.

Direct intra-oral measurements statistical analysis from Group B illustrated that the rate of canine retraction in the LLLT side was higher by nearly 1.3 fold in comparison to standard canine retraction in three months period. The ability of LLLT to accelerate canine retraction can be explained by the effect of LLLT on the receptor activator of the nuclear factor- $\kappa$ B (RANK)/RANK ligand (RANKL)/osteoprotegerin (OPG) system which is essential for osteoclastogenesis in animals and humans [16] [17] [18].

Reviewing the literature, vast heterogeneity was found in the protocol of LLLT application to accelerate OTM. Although some authors used higher

energy density ranging 5:8 J/cm<sup>2</sup>. e.g. Cruz et al. [25] and Youssef et al., [26]. All previously mentioned investigators used multiple point applications which were on average five on buccal and five on palatal sides, each was applied for 10 seconds.

Regarding the frequency of laser application, Youssef et al., [26] and Cruz et al., [25] used LLLT at 0, 3,7,14 days and they repeated the same frequency of application either after 21 days or 30 days. Genc et al., [27] added two applications to the previous protocol performing 6 applications applied once before the start of anterior teeth retraction as follows: 0, 3, 7, 14, 21, and 28 days. Doshi-Mehta [17] used 4 applications in the 1<sup>st</sup> month followed by 2 applications per month until complete canine retraction.

Direct intra-oral measurements statistical analysis from Group C illustrated that the rate of canine retraction in the combined MOPs& LLLT side was higher by nearly 1.8 fold in comparison to standard canine retraction in three months period. The increased rate of canine retraction in the combined MOPs & LLLT side more than the application of each technique separately in comparison to the control side can explain the synergistic effect occurring when the two techniques were combined.

In conclusion, both MOPs and LLLT techniques are proved to accelerate the rate of canine retraction during orthodontic treatment. MOPs technique can accelerate the rate of canine retraction more than the application of LLLT as compared to the standard canine retraction technique. Combination of MOPs and LLLT proved to be more efficient regarding increasing the rate of canine retraction than the application of each technique separately.

## References

1. Fisher MA, Wenger RM, Hans MG. pretreatment characteristics associated with orthodontic treatment duration. *Am J Orthod Dentofac Orthop.* 2010; 137:178-82. <https://doi.org/10.1016/j.ajodo.2008.09.028> PMID:20152672
2. Bishara SE, Ostby AW. White spot lesions: formation, prevention and treatment. *Semin Orthod.* 2008; 14:174-82. <https://doi.org/10.1053/j.sodo.2008.03.002>
3. Pandis N, Nasika M, Polychronopoulou A, Eliades T. External apical root resorption in patients treated with conventional and self-ligating brackets. *Am J Orthod Dentofac Orthop.* 2008; 134:646-51. <https://doi.org/10.1016/j.ajodo.2007.01.032> PMID:18984396
4. Royka A, Denes Z, Razouk G. The relationship between the length of orthodontic treatment and patient compliance. *Fogorv Sz.* 1999; 92:79-86.
5. Ghada Nimeri, Chung H Kau, Nadia S Abou-Kheir, and Rachel Corona. Acceleration of tooth movement during orthodontic treatment - a frontier in Orthodontics. *Prog Orthod.* 2013; 14:42. <https://doi.org/10.1186/2196-1042-14-42> PMID:24326040 PMCid:PMC4384959
6. Cano J, Campo J, Bonilla E, Colmenero C. Corticotomy assisted orthodontics. *J Clin Exp Dent.* 2012; 4(1):e54-9.

- <https://doi.org/10.4317/jced.50642> PMID:24558526  
PMCID:PMC3908811
7. Aboul-Ela SM, El-Bialy AR, El-Sayed KMF, Selim EMN, El-Mangoury NH, Mostafa YA. Miniscrew implant-supported maxillary canine retraction with and without corticotomy-facilitated orthodontics. *Am J Orthod Dentofac Orthop.* 2011; 139(2):252-9. <https://doi.org/10.1016/j.ajodo.2009.04.028> PMID:21300255
  8. Al-Naoum F, Hajeer MY, Al-Jundi A. Does alveolar corticotomy accelerate orthodontic tooth movement when retracting upper canines? A split mouth design randomized controlled trial. *J Oral Maxillofac Surg.* 2014; 72(10):1880-9. <https://doi.org/10.1016/j.joms.2014.05.003> PMID:25128922
  9. Abed S, Al Bustani A. Corticotomy assisted orthodontic canine retraction. *J Bagh Coll Dentistry.* 2013; 25(1):160-6. <https://doi.org/10.12816/0015134>
  10. Mostafa YA, Mohamed Salah Fayed M, Mehanni S, El Bokle NN, Heider AM. Comparison of corticotomy-facilitated vs standard tooth-movement techniques in dogs with miniscrews as anchor units. *Am J Orthod Dentofac Orthop.* 2009; 136(4):570-7. <https://doi.org/10.1016/j.ajodo.2007.10.052> PMID:19815161
  11. Wang L, Lee W, Lei D-L, Liu Y-P, Yamashita D-D, Yen SL-K. Tissue responses in corticotomy and osteotomy assisted tooth movement in rats: Histology and immunostaining. *Am J Orthod Dentofac Orthop.* 2009; 136(6): 770.el-11; discussion 770-1.
  12. Cassetta M, Di Carlo S, Giansanti M, Pompa G, Barbato E. The impact of osteotomy technique for corticotomy assisted orthodontic treatment (CAOT) on oral health related quality life. *Eur Rev Med Pharmacol Sci.* 2012; 16(12):35-40.
  13. Sangsuwon C, Alansari S, Nervina J, Teixeira CC, Alikhani M. Micro-osteoperforations in accelerated orthodontics. *Clin Dent Rev.* 2018 (s4)1894-017-0013-1.
  14. Aksakalli S, Balaban A, Nazaroğlu K, Sağlam E. Accelerated Tooth Movement with Orthodontic Mini-Screws. *Case Rep Dent.* 2017; 23(2):75-91. <https://doi.org/10.1155/2017/2327591>
  15. Maiman T. Stimulated optical radiation in ruby lasers. *Nature.* 1960; 187:493-4. <https://doi.org/10.1038/187493a0>
  16. Doshi-Mehta G, Bhad-Patil W. Efficacy of low intensity laser therapy in reducing treatment time and orthodontic pain: a clinical investigation. *Am J Orthod Dentofac Orthop.* 2012; 141(3): 289-97. <https://doi.org/10.1016/j.ajodo.2011.09.009> PMID:22381489
  17. Cepera F, Torres FC, Scanavini M, Paranhos L, Capelozza Filho L, Cardoso M. Effect low level laser on bone regeneration after rapid maxillary expansion. *Am J Orthod Dentofac Orthop.* American Association of Orthodontics. 2012; 141(4): 444-50.
  18. Ge MK, He WL, Chen J, Wen C, Yin X, Hu Z. Efficacy of low laser therapy for accelerating tooth movement during orthodontic treatment: a systematic review and meta-analysis. *Lasers Med Sci.* 2014.
  19. Thiruvengkatachari B, Ammayappan P, Kandaswamy R. comparison of rate of canine retraction with conventional molar anchorage and titanium implant anchorage. *Am J Orthod Dentofacial Orthop.* 2008; 134(1)30:5.
  20. Keng FY, Quick AN, Swain MV, Herbison P. A comparison of space closure rates between preactivated nickel-titanium and titanium-molybdenum alloy T-loops: a randomized controlled clinical trial. *Eur J Orthod.* 2012; 34(1):33-8. <https://doi.org/10.1093/ejo/cjq156> PMID:21415288
  21. Rohit S Kulshrestha, Ragni Tandon, and Pratik Chandra. Canine retraction: A systematic review of different methods used. *J Orthod Sci.* 2015; 4(1):1-8. <https://doi.org/10.4103/2278-0203.149608> PMID:25657985 PMCID:PMC4314834
  22. Mohammed H1, Rizk MZ, Wafaie K, Almuzian M. Effectiveness of nickel-titanium springs vs elastomeric chains in orthodontic space closure: A systematic review and meta-analysis. *Orthod Craniofac Res.* 2018; 21(1):12-19. <https://doi.org/10.1111/ocr.12210> PMID:29265578
  23. Barlow M, Kula K. Factor's influencing efficiency of sliding mechanics to close extraction space: a systematic review. *Orthod Craniofac Res.* 2008; 11(2):65-73. <https://doi.org/10.1111/j.1601-6343.2008.00421.x> PMID:18416747
  24. Wilcko WM, Wilcko MT. Accelerating tooth movement: the case for corticotomy-induced orthodontics. *Am J Orthod Dentofacial Ortop.* 2013; 144(1):4-12. <https://doi.org/10.1016/j.ajodo.2013.04.009> PMID:23810038
  25. Cruz DR, Kohara EK, Ribeiro MS, Wetter NU. Effects of low intensity laser therapy on the orthodontic movement velocity of human teeth: a preliminary study. *Lasers Surg Med.* 2004; 35(2):117-20. <https://doi.org/10.1002/lsm.20076> PMID:15334614
  26. Youssef M, Ashkar S, Hamade E, Gutknecht N, Lampert F, Mir M. The effect of low level laser therapy during orthodontic movement: preliminary study. *Lasers Med Sci.* 2008; 23(1):27-33. <https://doi.org/10.1007/s10103-007-0449-7> PMID:17361391
  27. Gence G, Kocadereli I, Tasar F, Kilinc K, El S, Sarkarati B. Effect of low level laser therapy (LLL) on orthodontic tooth movement. *Lasers Med Sci.* 2013; 28(1):41-7. <https://doi.org/10.1007/s10103-012-1059-6> PMID:22350425