



Fabrication of a metal-ceramic crown to fit an existing partial removable dental prosthesis using ceramic pressed to metal technique: a clinical report

Jae-Min Seo, Seung-Geun Ahn*

Department of Prosthodontics, School of Dentistry and Institute of Oral Bio-Science and Research Institute of Clinical Medicine, Chonbuk National University, Jeonju, Republic of Korea

Fabricating a crown to retrofit an existing abutment tooth for a partial removable dental prosthesis (PRDP) is one of the most time-consuming and labor-intensive clinical procedures. In particular, when the patient is concerned with esthetic aspects of restoration, the task of fabricating becomes more daunting. Many techniques for the fabrication of all-metallic or metal-ceramic crowns have been discussed in the literature. This article was aimed to describe a simple fabrication method in which a retrofitting crown was fabricated for a precise fit using a ceramic-pressed-to-metal system. [*J Adv Prosthodont 2014;6:241-4*]

KEY WORDS: Partial removable dental prosthesis; Metal ceramic crown; Ceramic press-on metal technique

INTRODUCTION

An abutment tooth on partial removable dental prosthesis (PRDP) can be carious as much as it requires additional restoration. In such cases, the existing PRDP can be replaced. However, if the PRDP is still clinically acceptable, abutment crown remake is a common solution. Regardless of the cause of tooth structure loss, the restoration procedure is usually complex. The literature has described many methods for making retrofitting surveyed crowns for such cases.¹⁻¹⁰ Some have suggested cast metal restorations while others have chosen ceramic restorations for esthetic reasons although the latter is more complicated. However,

many methods have turned out to be ineffective, causing inconvenience to patients as they could not use their PRDP while their crowns are being made and their fabricated crowns did not fit perfectly, which required considerable chairside time for adjustments.

In this article, a metal-ceramic crown was fabricated using the press-on metal (POM) technique to fit under an existing PRDP. The new generation of ceramics that are used as veneer materials for metallic and non-metallic cores have recently been introduced. This method has evolved from the idea of a pressable all-ceramic system. Crown fabrication started with wax-ups and casting for the metal substructure. After opaque porcelain was applied to the surface of the metal substructure, a full contour wax pattern was crafted and burned-out. The ceramic was then heat-pressed onto the substructure. Because the ceramic is pressed directly into the space made by burnout to the full extent of the wax pattern, this technique is simpler and quicker than multiple porcelain build-up used in conventional sintering method. The thermal expansion of the investment material is matched to that of the ceramic material. So, many of the problems associated with sintering shrinkage, such as dimensional inaccuracy and marginal opening may be avoided by using press-on-metal technique.^{11,12}

The POM technique reportedly has desirable properties.¹³ This method particularly benefits crown restorations

Corresponding author:

Seung-Geun Ahn

Department of Prosthodontics, School of Dentistry and Institute of Oral Bio-Science and Research Institute of Clinical Medicine, Chonbuk National University, 567 Baekje-daero, Deokjin-gu, Jeonju, 561-756, Jeonju, Republic of Korea

Tel. 82632502118; e-mail, sgahn@jbnu.ac.kr

Received September 30, 2013 / Last Revision January 2, 2014 / Accepted January 14, 2014

© 2014 The Korean Academy of Prosthodontics

This is an Open Access article distributed under the terms of the Creative Commons Attribution Non-Commercial License (<http://creativecommons.org/licenses/by-nc/3.0>) which permits unrestricted non-commercial use, distribution, and reproduction in any medium, provided the original work is properly cited.

under an existing PRDP because it is simpler but more accurate for fitting, compared to the conventional veneering technique.

CASE REPORT

A 75-year old man visited the Department of Prosthodontics, Chonbuk National University Dental Hospital with caries in the upper right canine and a dislodged filling material. The patient was using PRDP made by our hospital four years ago. His PRDP was still functional, and the patient was satisfied with his denture. Based on his clinical examination, a cingulum rest seat was located on the palatal surface, and this tooth served as the primary abutment for the PRDP. Resin filling was found on the distal surface with secondary caries being developed around the surface, and the filling became dislodged accordingly. The patient did not have pain or other symptoms. Very deep caries were revealed on a periapical radiograph, and the tooth did not respond to cold and heat tests, calling for root canal therapy. The resin filling and decayed tooth structure were removed, and root canal treatment was completed. However, the remaining tooth structure was not sufficient to support the PRDP. The damaged portion was restored

with resin filling (Filtek Z350; 3M ESPE, St. Paul, MN, USA). The patient was told about the need for a metal-ceramic crown to restore the tooth. Upon his agreement, abutment preparation was undertaken (Fig. 1).

After tooth preparation, PRDP was placed to ensure adequate clearance. The occlusal clearance should be no less than 2.0 mm. Also, a minimum clearance of 1.5 mm between the prepared tooth and all parts of the PRDP framework is essential. After the retraction cord (SURE-Cord; Suredent Co, Seoul, Korea) was inserted, the final impression was taken using a silicon impression material (Imprint 3; 3M ESPE, St. Paul, MN, USA). The PRDP was repositioned, and then an analog impression of the clasp assembly was generated with a monophasic impression material (Aquasil Ultra Monophasic; Dentsply Caulk, Milford, DE)(Fig. 2).

A temporary restoration was made directly on the prepared tooth with composite resin (Luxatemp; DMG, Hamburg, Germany), and the existing PRDP was fitted to the provisional crown. Working cast with a removable die system based on the conventional method was fabricated using an improved dental stone (Fuji-Rock; GC Co, Tokyo, Japan). The indentation made on the surface of the analog impression was filled with resin (TokusoCurefast; Tokuyama

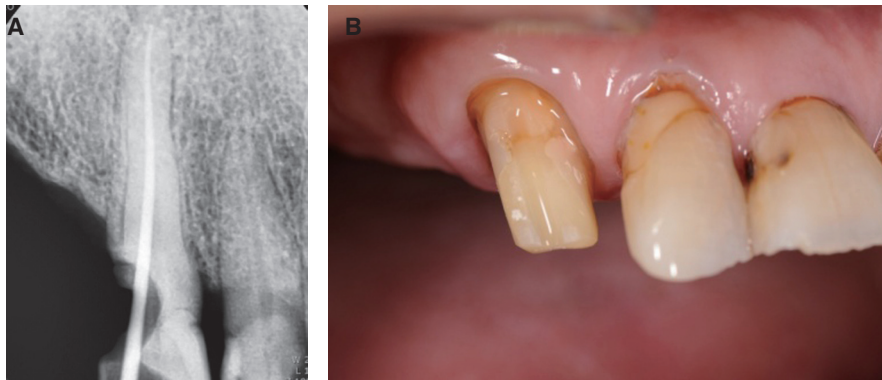


Fig. 1. (A) A periapical radiograph showing the upper right maxillary canine with a dislodged filling accelerated by secondary caries, calling for root canal treatment, (B) Abutment preparation for a metal-ceramic crown restoration.

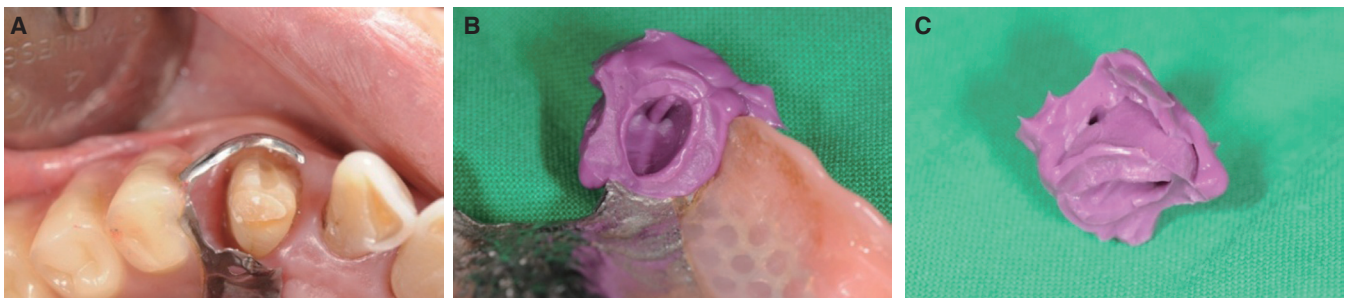


Fig. 2. (A) After the preparation process, PRDP was positioned to check stabilization, (B) Following polymerization of the impression material, the analog impression was removed along with PRDP, (C) Analog impression being separated from PRDP contained all records of the abutment and the clasp assembly.

dental Co, Tokyo, Japan) to make the clasp assembly analog. A full contour wax-up was fabricated to fit under the prepared clasp assembly analog, and a subsequent cut-back of the wax-up was performed. Next, phosphate bonded investment (Ticonium CB-30 investment; Ticonium Co, NY) was used to invest the wax pattern. Nonprecious metal alloy (NoBel; Kuwotech Co, Kwangju, Korea) was used to cast a metal substructure. The paste opaque (Vintage MP; Shofu Co, Kyoto, Japan) was applied over the surface of the metal substructure and fired in porcelain furnace (Austromat D4, DEKEMA GmbH, Germany). Another full contour wax-up (S-U-Esthetic Wax-O; Schuler-Dental GmbH & Co, Ulm, Germany) to fit under the clasp assembly analog was created on the opaque layer (Fig. 3).

This metal wax-up complex was then invested using an exclusive investment material (IPSPressVest Speed; IvoclarVivadent AG, Schaan, Liechtenstein) and burned out at 850°C for an hour in a furnace (Burnout Furnace: Model-104; JM-Tech Co, Seoul, Korea). Following burn-out, A3 shade porcelain ingot (IPS InLinePoM; Ivoclar Vivadent) was heat pressed onto the metal substructure in a pressing furnace (EP 600; IvoclarVivadent). The sprue was then cut off, and the definitive crown was contoured to fit under the clasp assembly analog. Contouring was followed

by staining (IPS InLine System Stains; IvoclarVivadent) and glazing (IPS e.max Ceram Glaze Paste; IvoclarVivadent) to complete the crown. The completed crown was tried in on the abutment tooth to check for fit with the existing PRDP. Necessary adjustments were also made to the crown. The adjusted crown was polished as a final touch using a polishing kit (Diagen-turbo-grinder; Bredent AG, Senden, Germany). Once the patient agreed to the shade and shape of the restoration, the crown was cemented with resin modified glass ionomer cement (Fuji-Cem; GC Co, Tokyo, Japan). In the recall check-ups, no complications were observed, and the patient was satisfied with the function of the crown and PRDP (Fig. 4).

DISCUSSION

The crown fabrication technique discussed in this article used a clasp assembly analog. This means that the patient can keep using their denture while a crown is being made. Other advantages include more accurate fit of metal-ceramic crowns created using the POM technique and a simpler fabrication method compared to conventional techniques. Metal -ceramic crowns made with the conventional porcelain build-up and firing method makes it impossible to pre-

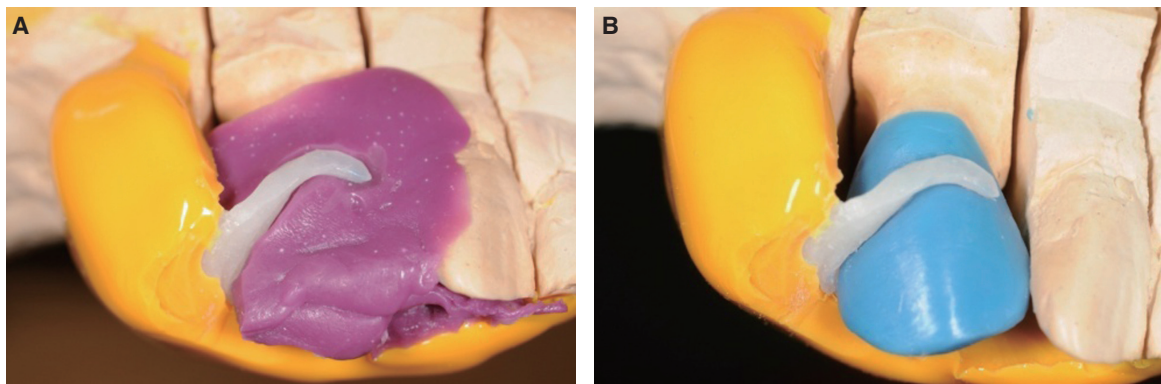


Fig. 3. (A) Resin injected into the pre-formed clasp hole, proximal plate and a cingulum rest to make a clasp assembly analog, (B) A full contour wax-up was created on a metal substructure to fit under the resin analog.

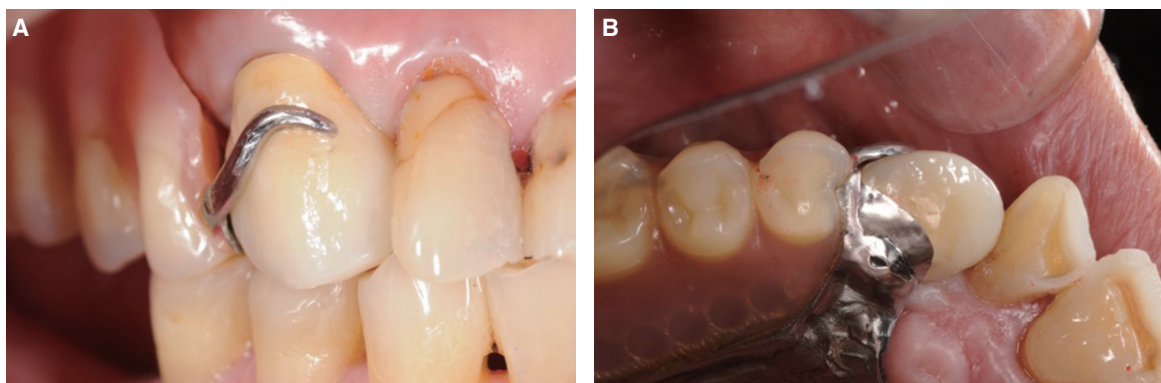


Fig. 4. A metal-ceramic crown fits well under the PRDP and meets the esthetic criteria. (A) Buccal view, (B) Occlusal view.

dict the shrinking rate precisely. As a result, the number of firing may rise and the chairside time for adjustments of the crown can be lengthened.

Many procedural approaches have been used to fabricate retrofitting surveyed crowns.^{3-5,7} Recently, computer-aided design/computer-assisted manufacturing (CAD/CAM) techniques have become available. However, limited software and the high price of equipment prevent the widespread use of digital techniques. The use of an analog of the clasp assembly and the POM technique allows not only a simple and accurate fabrication, but is also esthetically beneficial without the need for new equipment.^{11,12} However, the additional processes ranging from taking an analog impression in addition to the final impression, creating a clasp assembly analog and proper seating of the analog on the abutment die are the limitations of this technique. A long-term follow-up study is necessary to verify how effectively the metal-ceramic crown restorations reported in this article can remain without fracture or chipping.

The present clinical report described a retrofitting crown fabrication technique using a clasp assembly analog and the POM technique. The final impression was followed by an analog impression using a monophasic material, and an analog of the clasp assembly was created with resin. A full contour wax-up was fabricated to make a metal substructure, and porcelain was heat pressed on the metal substructure on the basis of the POM method. As a result, an esthetic retrofitting surveyed metal-ceramic crown was completed. The completed crown fitted well under the existing PRDP, and the chairside time for adjustments was minimized.

REFERENCES

1. Yoon TH, Chang WG. The fabrication of a CAD/CAM ceramic crown to fit an existing partial removable dental prosthesis: a clinical report. *J Prosthet Dent* 2012;108:143-6.
2. Burt D. Copy existing tooth form to retrofit to an RPD accurately: an ideal CAD/CAM application. *Dent Today* 2009;28:140-1.
3. Helvey GA. Retrofitting crowns to an existing removable partial denture clasp: a simple technique. *J Prosthet Dent* 2002;87:399-402.
4. Livaditis GJ. Fabricating abutment crowns for existing removable partial dentures using custom resin clasp analogs. *J Prosthet Dent* 1998;80:619-29.
5. Tran CD, Sherraden DR, Curtis TA. A review of techniques of crown fabrication for existing removable partial dentures. *J Prosthet Dent* 1986;55:671-3.
6. Hill GM. Construction of a crown to fit a removable partial denture clasp. *J Prosthet Dent* 1977;38:226-8.
7. Macpherson JR, Evans DB. Fabricating crowns to fit existing removable partial dentures: an illustration of two techniques. *J Prosthodont* 1993;2:199-205.
8. Silberman DM. An indirect procedure for making a crown under an existing partial denture. *J Prosthet Dent* 1993;69:631-3.
9. Schneider RL. Adapting ceramometal restorations to existing removable partial dentures. *J Prosthet Dent* 1983;49:279-81.
10. Raskin ER. An indirect technique for fabricating a crown under an existing clasp. *J Prosthet Dent* 1983;50:580-1.
11. Fahmy NZ, Salah E. An in vitro assessment of a ceramic-pressed-to-metal system as an alternative to conventional metal ceramic systems. *J Prosthodont* 2011;20:621-7.
12. Goldin EB, Boyd NW 3rd, Goldstein GR, Hittelman EL, Thompson VP. Marginal fit of leucite-glass pressable ceramic restorations and ceramic-pressed-to-metal restorations. *J Prosthet Dent* 2005;93:143-7.
13. Venkatachalam B, Goldstein GR, Pines MS, Hittelman EL. Ceramic pressed to metal versus feldspathic porcelain fused to metal: a comparative study of bond strength. *Int J Prosthodont* 2009;22:94-100.