

Investigation of the values of CT perfusion imaging and ultrasound elastography in the diagnosis of liver fibrosis

YANSONG LI^{1*}, QING PAN^{1*} and HONG ZHAO²

¹Department of Ultrasound, Qingdao Municipal Hospital; ²Department of Radiology, Eastern Hospital, Qingdao Municipal Hospital, Qingdao, Shandong 266071, P.R. China

Received December 25, 2017; Accepted June 1, 2018

DOI: 10.3892/etm.2018.6269

Abstract. This study intended to investigate the clinical application values of computed tomography (CT) perfusion imaging and ultrasound elastography in the diagnosis of liver fibrosis, and to analyze the characteristics and diagnostic values of the two methods in liver fibrosis. A total of 320 patients diagnosed with suspected liver fibrosis in Qingdao Municipal Hospital from April 2014 to May 2016 were selected. The patients were diagnosed by ultrasound elastography and CT perfusion imaging, respectively, and the influencing characteristics and diagnostic accuracies of the two methods were compared. Among 320 patients, there were 315 definitely diagnosed with liver fibrosis through liver biopsy. The accuracy of CT perfusion imaging was 95.63% (306/325), while that of ultrasound elastography was 91.88% (294/320); there was a significant difference in accuracy between the two methods ($P>0.05$). CT perfusion imaging was superior to ultrasound elastography in the degree of liver fibrosis ($P<0.05$). Receiver operating characteristic (ROC) curve analysis showed that the areas under the curve (AUC) of patients were 0.841 and 0.865 in S1 ($P>0.05$), 0.830 and 0.887 in S2 ($P>0.05$), 0.851 and 0.931 in S3 ($P>0.05$), and 0.951 and 0.970 in S4, respectively ($P>0.05$). AUC values of ROC curves of CT perfusion imaging and ultrasound elastography in diagnosing liver fibrosis were 0.833 and 0.857, respectively ($P>0.05$). Both CT perfusion imaging and ultrasound elastography have relatively high accuracies in the clinical diagnosis of liver fibrosis, and they are worth promoting and applying. However, the best imaging method needs to be selected according to the actual situation of patients and research purpose.

Introduction

China is one of the countries with a high incidence rate of chronic viral hepatitis B (CHB). The infection of its hepatitis B virus (HBV) can lead to the occurrence of a variety of liver diseases, including liver fibrosis, severe hepatitis and hepatocellular carcinoma developed from lesions in the terminal stage (1-3). The main cause of liver fibrosis is that the degradation of the extracellular matrix in the liver leads to inadequate or excessive collagen synthesis, resulting in a large number of collagen deposition near the hepatic lobule and finally hindering the exchange of liver cells and blood substances, which will lead to the liver cell necrosis and degeneration, followed by liver fibrosis and connective tissue hyperplasia (4). Currently, CHB in about 25% of the patients develops into cirrhosis that is the terminal stage of the disease, and patients will not survive from it unless they receive liver transplantation (5). Therefore, it is hoped to accurately detect the occurrence of liver fibrosis in the early stage and make corresponding treatment and intervention, which can effectively reduce the patients' pain and financial pressure. Now, liver biopsy still serves as the gold standard for liver fibrosis; however, it is relatively difficult to popularize and apply it in clinical practice.

Previous studies have shown that Fibroscan and computer tomography (CT) perfusion imaging can accurately assess and grade liver fibrosis (6,7). Fibroscan is a diagnostic tool for liver fibrosis with no invasiveness, whose principle is to diagnose the human body through low-frequency ultrasounds, and it is mainly used to detect the degree of liver cirrhosis and give feedbacks through the instantaneous elastic spectrums of the liver; when liver fibrosis occurs in liver tissues, Fibroscan can be used for quantitative grading for liver fibrosis at different degrees (8). The main method of CT perfusion imaging is to directly perfuse the human body so as to achieve semi-quantitative or quantitative analysis of the human body perfusion directly through CT imaging methods; CT perfusion is characterized by short scanning time, high recognition rate and simple technique, and changes in human blood flows can be observed through it while the analysis is conducted (9,10). However, there are few reports on the comparison between the two methods. Therefore, values of the two methods in the diagnosis of liver fibrosis were studied and explored, and the results of the two methods were compared.

Correspondence to: Dr Hong Zhao, Department of Radiology, Eastern Hospital, Qingdao Municipal Hospital, 5 Donghai Middle Road, Qingdao, Shandong 266071, P.R. China
E-mail: zq6q8e@163.com

*Contributed equally

Key words: computed tomography, perfusion imaging, ultrasound elastography, liver fibrosis, diagnostic value

Materials and methods

Data of patients. In the present study, the clinical data of 320 patients with chronic liver disease examined and treated in Qingdao Municipal Hospital (Qingdao, China) from April 2014 to May 2016 were retrospectively analyzed. Among them, there were 266 cases of HBV, including 147 males and 119 females aged 29-60 years, with an average of 47.4 ± 12.5 years; there were 54 cases of hepatitis C virus (HCV), including 27 males and 27 females aged 33-57 years, with an average age of 44.4 ± 10.2 years. Guidelines for prevention, Care and Treatment of Persons with CHB (Version 2009) (11) and Guidelines for Prevention, Care and Treatment of Persons with Hepatitis C (Version 2015) (12) were taken as the diagnostic criteria. Clinical data of patients are shown in Table I. The relevant study was carried out under the approval of the Ethics Committee of Qingdao Municipal Hospital, and all patients were informed and signed a formal written authorization.

Inclusion and exclusion criteria. Inclusion criteria: Patients with the course of disease of six months; receiving no drug treatment recently; with no other genetic diseases; receiving no radiotherapy and chemotherapy; and patients with autism, memory disorders and hearing disorders. Exclusion criteria: Patients with respiratory diseases; with hypertension or diabetes mellitus; with blood relationship with other patients; receiving no blood transfusion recently; and patients who did not cooperate with the follow-up or had incomplete clinical data.

Detection methods

Tissue biopsy. All patients underwent liver tissue puncture operation. Before the operation, blood routine examination and blood clotting time detection were conducted for patients. Patients were placed in the supine position, and the operation was conducted under the guidance of ultrasounds. The size of liver tissues taken by biopsy should not be less than 15 mm. Liver fibrosis staging: In S1, the portal area of fibrosis in patients was enlarged; in S2, fibrosis occurred around the portal area; in S3, the fibrous septum was accompanied by lobular disorders with no liver cirrhosis; and in S4, liver parenchyma was damaged with diffuse fibrosis and lobular structure disorders.

Fibroscan detection method. Instantaneous elastic ultrasonic instrument is a product of Echosens (Paris, France), and the testing method was operated in strict accordance with Fibroscan instructions. Subjects were placed in the supine position with right arms lifted behind 1/4 of the right brain, and the intercostal space in the lobe area of patients was detected. The probe was dipped in a little ultrasound coupling agent, which was applied perpendicularly to the human skin; the probe was put closely near the skin and was used for detection for conservative 10 times, and the median was taken as the result.

CT perfusion detection. Under the state of solid and liquid fasting as required, patients should sit quietly and keep eupnea at half an hour before examination. In the experiment, a 16-slice spiral CT scanner was used to scan patients. Patients underwent the first abdominal plain scan at the voltage of 120 kV, the current of 260 mA and the scan thickness of

Table I. Clinical data of patients.

Groups	Clinical data n (%)
Sex	
Male	174 (54.38)
Female	146 (45.62)
Age	
>50	166 (51.87)
≤50	154 (48.13)
Place of residence	
City	284 (88.75)
Countryside	36 (11.25)
Educational level	
< Junior college	230 (71.85)
≥ Junior college	90 (28.15)
Eating habit	
A spicy diet	66 (20.63)
A light diet	254 (79.37)
PT	11.40±1.14 sec
WBC	5.33±1.38×10 ⁹ /l
PLT	169.5±56.1×10 ⁹ /l

PT, prothrombin time; WBC, white blood cell; PLT, platelet.

10 mm for 0.8 sec in total. The left and right lobes of the liver and main portal veins were developed. The scanning bed was then adjusted for enhanced scanning of the selected area. The scan parameters were set at 0.8 sec/360°, voltage (120 kV), current (260 mA), thickness (5.4 mm) and field of view (360 mm). In this experiment, a total of 40 ml Omnipaque (350 mg/ml) was used as a contrast reagent, its flow rate was 3 ml/sec, the duration was 5 sec, and the scanning time was 60 sec in total. All the data obtained after scanning were uploaded to the workstation. In the experiment, GEAW 4.2 was applied to analyze the uploaded data.

Statistical methods. SPSS 22.0 (IBM Corp., Armonk, NY, USA) software package was used in this experiment for statistical analyses of the collected data of all patients. Receiver operating characteristic (ROC) curves of patients detected by the two methods were plotted using ROC and pROC packages. Normality test was performed for the experimental data. Comparison between groups was done using one-way ANOVA test followed by post hoc test (Least Significant Difference). Chi-square test was conducted for the non-normally distributed data. The data in this experiment were expressed as mean ± standard deviation (mean ± SD). $P < 0.05$ was considered to indicate a statistically significant difference.

Results

Biopsy results. All the patients received liver biopsy in this experiment, and the results showed that 320 patients suffered

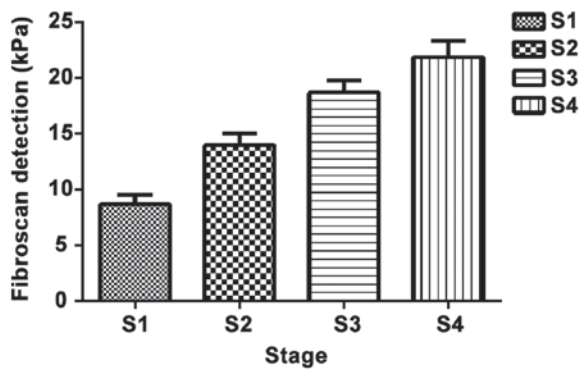


Figure 1. Fibroscan detection results. Fibroscan detection for fibrosis in patients in different stages shows that there are differences among stages: There are statistically significant differences between S1-S4 ($P < 0.05$); between S2-S4 ($P < 0.05$); and between S3-S4 ($P < 0.05$).

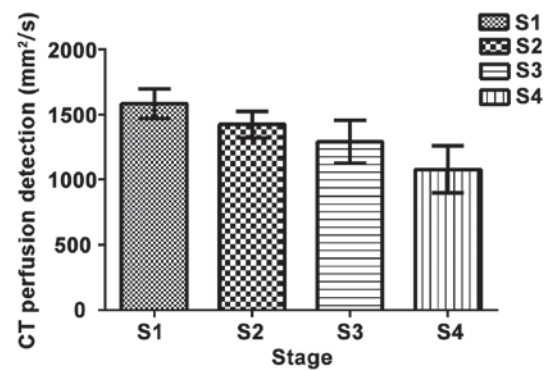


Figure 2. CT perfusion detection results. CT perfusion detection for fibrosis in patients shows that there are differences among various stages: There are statistically significant differences between S1-S4 ($P < 0.05$); between S2-S4 ($P < 0.05$); and between S3-S4 ($P < 0.05$). CT, computed tomography.

from liver fibrosis at different degrees. There were 85 cases (26.5%) in S1, 98 (30.6%) in S2, 76 (23.7%) in S3 and 61 (19.1%) in S4.

Fibroscan detection results of patients. The detection results of liver cirrhosis for 320 patients: The average detection value of liver cirrhosis in patients was (14.11±9.37) kPa, and there were 63 cases (8.67±6.67) kPa in S1, 98 cases (13.97±10.41) kPa in S2, 74 cases (18.67±9.61) kPa in S3 and 59 cases (21.84±11.67) pKa in S4. Liver cirrhosis was detected in a total of 294 patients with a detection rate of 91.88% (294/320) (Fig. 1).

CT perfusion detection. The apparent diffusion coefficient value in each group was detected via CT perfusion in 320 patients, which showed that there were 72 cases (1,584.80±115.00) mm²/sec in S1, 98 (1,421.80±103.00) mm²/sec in S2, 75 (1,288.60±162.80) mm²/sec in S3 and (1,079.00±179.30) mm²/sec in S4. Liver fibrosis was detected in a total of 306 patients with a detection rate of 95.63% (306/320) (Fig. 2).

Comparison of the detection rate between the two methods and ROC analyses. The detection rates of Fibroscan and CT perfusion in patients were 91.88 and 95.63%, respectively, and there was no statistically significant difference between the two methods ($P > 0.05$). ROC curves of the two methods in different stages were plotted, respectively. It was found that the areas under the curve (AUC) of ROC detected by CT perfusion imaging and ultrasound elastography in the diagnosis of liver fibrosis were 0.833 and 0.857, respectively ($P > 0.05$). The AUC values of patients detected by the two methods were 0.841 and 0.865 in S1, ($P > 0.05$), 0.830 and 0.887 in S2, ($P > 0.05$), 0.851 and 0.931 in S3, ($P > 0.05$), and 0.951 and 0.970 in S4, respectively ($P > 0.05$) (Fig. 3).

Discussion

According to the statistics of the World Health Organization (WHO), about 1/4 of the people in the world have ever had HBV infection, 350 million people are diagnosed with chronic HBV infection, and about 0.9-1 million people die of liver cirrhosis or liver cancer due to HBV infection each year (13). CHB is a

chronic liver disease caused by persistent HBV infection; liver fibrosis is a function repairing liver injury caused by CHB, and it is also an unavoidable process of pathological changes of liver cirrhosis and liver cancer in patients with CHB. Therefore, accurate judgment and assessment of liver fibrosis can be very effective in the customization and judgement of the prognosis of patients with liver fibrosis. As a dynamic process of liver tissue injury repair, liver fibrosis needs continuous testing and observation. At present, liver biopsy is one of the gold standards of liver fibrosis, but it will produce wounds to patients with shortcomings such as poor repeatability, so it is not suitable to be widely promoted in clinical practice. Non-invasive diagnosis of liver fibrosis has been a hot topic in recent years, and the accuracies of serum protein electrophoresis, fibrosis-4 (FIB-4) and other serum diagnostic methods are not ideal compared with that of biopsy (14).

Clinically, CT measurement mainly focuses on cirrhosis and liver cancer; CT perfusion directly reflects the structure of tissues through the detection of the water molecular flow within human tissues and blood flow perfusion, and it can also be used to diagnose and identify liver lesions by observation of the molecular level and provide information of clinical value (7). At present, there are few studies on CT perfusion of liver fibrosis. It has been reported (15) that after the treatment by multislice CT (MSCT) perfusion technique, the portal vein perfusion volume of cirrhosis < that of chronic hepatitis < that of normal control group, which proves that in the hepatitis-cirrhosis process, blood perfusion is gradually varied. Fibroscan, as a new type of noninvasive *in vitro* diagnostic instrument, is an instrument for liver diseases, which can be used for real-time monitoring of liver hardness through low-frequency pulses, so as to determine the degree of liver cirrhosis. Many studies in China and other countries have shown that Fibroscan can be used as a relatively good diagnostic method for chronic liver fibrosis in hepatitis C patients, and it has high diagnostic values in patients with HBV, fatty liver and alcoholic liver disease (16,17). The article of Roulot *et al* (18) mentioned that the detection for 1,358 healthy people by Fibroscan shows that the specificity and positive detection rate of Fibroscan in the diagnosis of liver cirrhosis in people over 45-years-old are up to 100%. This well illustrates that liver fibrosis can be predicted by Fibroscan.

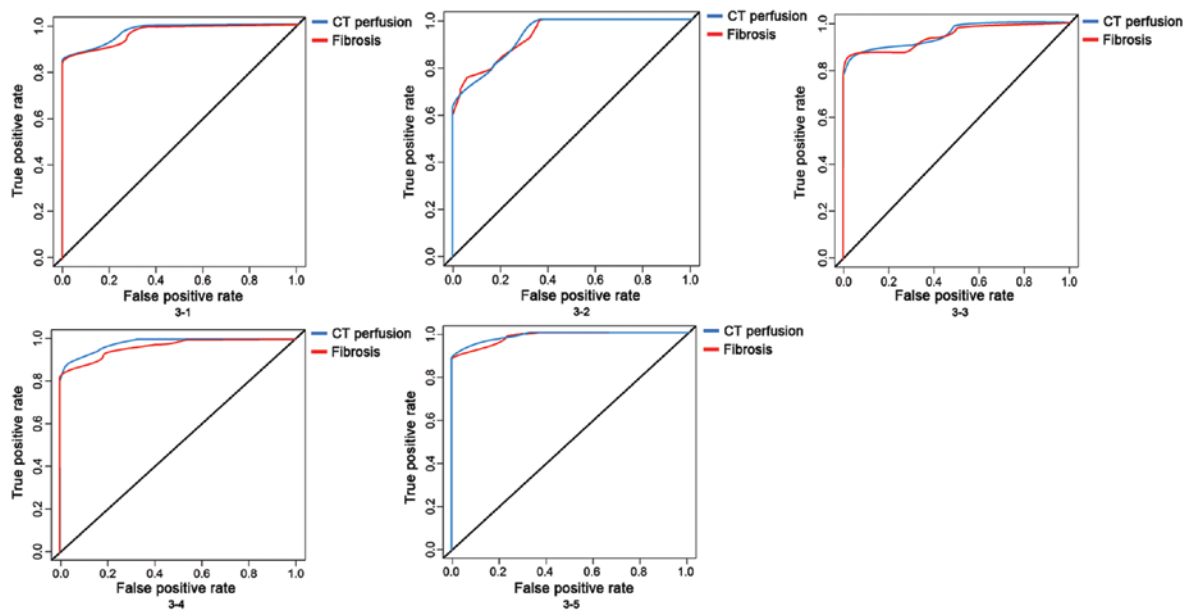


Figure 3. ROC curves of Fibrosan detection and CT perfusion detection. ROC curves are used to analyze the detection results by two methods, which shows that there is no difference between the two methods ($P>0.05$), but there is a good specificity and sensitivity, and there are also no differences in ROC curves among different analyses ($P>0.05$). 3-1: The detection rates of Fibrosis and CT perfusion in patients were 0.919 and 0.956, ($P>0.05$). 3-2: The AUC values of patients detected by the two methods were 0.841 and 0.865 in S1, ($P>0.05$); 3-3, were 0.830 and 0.887 in S2, ($P>0.05$); 3-4, were 0.851 and 0.931 in S3, ($P>0.05$); and 3-5, were 0.951 and 0.970 in S4, respectively ($P>0.05$). CT, computed tomography; ROC receiver operating characteristic; AUC, areas under the curve.

In the present study, it was confirmed through liver biopsy that 320 patients suffered from liver fibrosis at varying degrees; besides, CT perfusion and Fibrosan were used for diagnostic research in 320 patients so as to explore the accuracy rate of the two methods in the diagnosis of liver fibrosis. The results revealed that both methods had high accuracy rate (95.63 and 91.88%) in the diagnosis of liver fibrosis, and there was no statistical difference between them. Studies (19,20) have shown that CT perfusion technique and Fibrosan produce good diagnostic results in liver fibrosis. Wang *et al* (6) applied Fibrosan to detect the degree of liver fibrosis in patients with chronic hepatitis, and the results showed that the positive diagnostic rate reaches 90%, which is basically the same as the rate in this experiment, thus well proving the accuracy of the experiment. The article of Hashimoto *et al* (21) indicated that CT perfusion detection can be used to effectively detect the degree of liver fibrosis and has great significance in prognosis evaluation and diagnosis in patients. The clinical value of CT perfusion in the diagnosis of liver fibrosis was further testified. Therewith, ROC curve analysis was conducted for patients with liver fibrosis at different degrees, and it was found that there were no differences in AUC values measured by the two different methods. However, compared with CT perfusion, Fibrosan is characterized by high repeatability, simple operation and relatively low cost. Both the two methods have disadvantages since they radiate the human body; for example, they will affect the growth of the baby in pregnant and lying-in women. Therefore, the treatment method needs to be selected according to the actual situation of patients.

There are still shortcomings in this study. Lack of subjects led to biased experimental results in the retrospective analysis, so the sample size needs to be expanded; the two methods were simply compared in the experiment, and randomized

controlled experiments can be conducted in the future to better prove the experimental results. Besides, Fibrosan is popular in foreign countries, and a certain degree of biases may be caused if Chinese population is graded according to the reference range for foreign populations. Chinese people are generally short in stature, and their intercostal spaces are relatively narrow, which may affect the experimental results, so there is a need to improve the accuracy of the experimental results according to better standards set for Chinese people.

In conclusion, patients with liver fibrosis were diagnosed by two different methods in this study, both of which have significantly relatively high accuracies and are worthy of promotion.

Acknowledgements

Not applicable.

Funding

This work was supported by Qingdao Municipal Hospital, (Shandong, China).

Availability of data and materials

All data generated or analyzed during this study are included in this published article.

Authors' contributions

YL and QP designed the study, QP and HZ collected the data, HZ and YL analyzed the data. YL was for preparation of manuscript. All authors read and approved the final manuscript.

Ethics approval and consent to participate

The relevant study was carried out under the approval of the Ethics Committee of Qingdao Municipal Hospital (Qingdao, China) and all patients were informed and signed a formal written authorization. Research protocols were assessed and accepted by the institutional.

Patient consent for publication

Not applicable.

Competing interests

All authors have no conflict of interest to declare.

References

- Rehermann B: Pathogenesis of chronic viral hepatitis: Differential roles of T cells and NK cells. *Nat Med* 19: 859-868, 2013.
- Schweitzer A, Horn J, Mikolajczyk RT, Krause G and Ott JJ: Estimations of worldwide prevalence of chronic hepatitis B virus infection: A systematic review of data published between 1965 and 2013. *Lancet* 386: 1546-1555, 2015.
- Trépo C, Chan HLY and Lok A: Hepatitis B virus infection. *Lancet* 384: 2053-2063, 2014.
- Trautwein C, Friedman SL, Schuppan D and Pinzani M: Hepatic fibrosis: Concept to treatment. *J Hepatol* 62: 15-24, 2015.
- Gordon SC, Lamerato LE, Rupp LB, Li J, Holmberg SD, Moorman AC, Spradling PR, Teshale EH, Vijayadeva V, Boscarino JA, *et al*; CHeCS Investigators: Antiviral therapy for chronic hepatitis B virus infection and development of hepatocellular carcinoma in a US population. *Clin Gastroenterol Hepatol* 12: 885-893, 2014.
- Wang JH, Changchien CS, Hung CH, Eng HL, Tung WC, Kee KM, Chen CH, Hu TH, Lee CM and Lu SN: FibroScan and ultrasonography in the prediction of hepatic fibrosis in patients with chronic viral hepatitis. *J Gastroenterol* 44: 439-446, 2009.
- Ronot M, Asselah T, Paradis V, Michoux N, Dorvillius M, Baron G, Marcellin P, Van Beers BE and Vilgrain V: Liver fibrosis in chronic hepatitis C virus infection: Differentiating minimal from intermediate fibrosis with perfusion CT. *Radiology* 256: 135-142, 2010.
- Xu M, Wang X, Zou Y and Zhong Y: Key role of liver sinusoidal endothelial cells in liver fibrosis. *Biosci Trends* 11: 163-168, 2017.
- Kim SH, Kamaya A and Willmann JK: CT perfusion of the liver: Principles and applications in oncology. *Radiology* 272: 322-344, 2014.
- Lv WF, Han JK, Cheng DL, Zhou CZ, Ni M and Lu D: CT perfusion imaging can predict patients' survival and early response to transarterial chemo-lipiodol infusion for liver metastases from colorectal cancers. *Korean J Radiol* 16: 810-820, 2015.
- Lok ASF and McMahon BJ: Chronic hepatitis B: Update 2009. *Hepatology* 50: 661-662, 2009.
- Chen HS, Dou XG, Duan ZP, *et al*: Guidelines for the prevention and treatment of hepatitis C (Updated 2015). *Zhongguo Bingdubing Zazhi* 2015: 425-447, 2015 (In Chinese).
- Liaw YF and Chu CM: Hepatitis B virus infection. *Lancet* 373: 582-592, 2009.
- Forlenza GP and Stewart MW: Diabetic retinopathy in children. *Pediatr Endocrinol Rev* 10: 217-226, 2012.
- Nakashige A, Horiguchi J, Tamura A, Asahara T, Shimamoto F and Ito K: Quantitative measurement of hepatic portal perfusion by multidetector row CT with compensation for respiratory misregistration. *Br J Radiol* 77: 728-734, 2004.
- Zayed BEM, Elsharkawy A, Abdou M, Abd Al Fatah DS and El-Shabony TH: Assessment of hepatic fibrosis by fibroscan in egyptian chronic hemodialysis patients with chronic Hepatitis C (genotype 4): A single-center study. *Saudi J Kidney Dis Transpl* 28: 764-773, 2017.
- Liu CH, Liu CJ, Su TH, Yang HC, Kao JH, Chen DS and Chen PJ: THU-478-Noninvasive diagnosis of hepatic fibrosis by biofibroscan in patients with chronic hepatitis C virus infection. *J Hepatol* 66: S233-S234, 2017.
- Roulot D, Costes JL, Buyck JF, Warzocha U, Gambier N, Czernichow S, Le Clesiau H and Beaugrand M: Transient elastography as a screening tool for liver fibrosis and cirrhosis in a community-based population aged over 45 years. *Gut* 60: 977-984, 2011.
- Lamb P, Sahani DV, Fuentes-Orrego JM, Patino M, Ghosh A and Mendonça PR: Stratification of patients with liver fibrosis using dual-energy CT. *IEEE Trans Med Imaging* 34: 807-815, 2015.
- Cassinotto C, Lapuyade B, Mouries A, Hiriart JB, Vergniol J, Gaye D, Castain C, Le Bail B, Chermak F, Foucher J, *et al*: Non-invasive assessment of liver fibrosis with impulse elastography: Comparison of Supersonic Shear Imaging with ARFI and FibroScan®. *J Hepatol* 61: 550-557, 2014.
- Hashimoto K, Murakami T, Dono K, Hori M, Kim T, Kudo M, Marubashi S, Miyamoto A, Takeda Y, Nagano H, *et al*: Assessment of the severity of liver disease and fibrotic change: The usefulness of hepatic CT perfusion imaging. *Oncol Rep* 16: 677-683, 2006.



This work is licensed under a Creative Commons Attribution-NonCommercial-NoDerivatives 4.0 International (CC BY-NC-ND 4.0) License.