



Case Report

Impaired visual acuity as an only symptom of shunt malfunction, long time after initial cyst-peritoneal shunting for arachnoid cyst: A case report

Kotaro Ono¹, Nobutaka Mukae², Ataru Nishimura², Koichi Arimura², Masahiro Mizoguchi², Koji Yoshimoto², Koji Iihara³

¹Department of Neurosurgery, Japan Community Health care Organization Kyushu Hospital, Kitakyushu, ²Department of Neurosurgery, Graduate School of Medical Sciences, Kyushu University, Fukuoka, ³Director General, National Cerebral and Cardiovascular Center Hospital, Suita, Osaka, Japan.

E-mail: Kotaro Ono - k_ono0920@yahoo.co.jp; *Nobutaka Mukae - mukae.nobutaka.882@m.kyushu-u.ac.jp; Ataru Nishimura - atarunishimura@icloud.com; Koichi Arimura - arimura.koichi.001@m.kyushu-u.ac.jp; Masahiro Mizoguchi - mizoguchi.masahiro.950@m.kyushu-u.ac.jp; Koji Yoshimoto - yoshimoto.koji.315@m.kyushu-u.ac.jp; Koji Iihara - kiihara1122@gmail.com



*Corresponding author:

Nobutaka Mukae,
Department of Neurosurgery,
Graduate School of Medical
Sciences, Kyushu University,
Fukuoka, Japan.

mukae.nobutaka.882@m.
kyushu-u.ac.jp

Received : 26 October 2021
Accepted : 02 February 2022
Published : 25 February 2022

DOI

10.25259/SNI_1077_2021

Quick Response Code:



ABSTRACT

Background: Long-term outcomes after surgical treatment of arachnoid cysts (ACs) have not been reported adequately. Impaired visual acuity is not a common symptom of shunt dependency syndrome due to cyst-peritoneal (CP) shunt malfunction for ACs. We report a case of CP shunt malfunction, who presented only impaired visual acuity as a symptom, long after the initial surgical treatment.

Case Description: A 16-year-old boy was surgically treated for the left frontal AC with CP shunting at 2 years of age. Extension of the peritoneal shunt catheter was performed at 15 years of age. A year later, he started experiencing impairment of visual acuity without headaches, which worsened to bilateral light perception. The presence of bilateral optic atrophy was confirmed. The AC in the left frontal lobe had enlarged very slightly, with shortening of the intracystic catheter, and the cerebrospinal fluid pressure was elevated to 30 cmH₂O. He was treated with lumboperitoneal shunting. The visual acuity showed limited improvement.

Conclusion: The possibility of CP shunt malfunction and shunt dependency syndrome should be considered, even if the patient presented only impaired visual acuity and no significant changes in the size of the ACs are observed.

Keywords: Cyst-peritoneal shunt, Impaired visual acuity, Increased intracranial pressure

INTRODUCTION

Arachnoid cysts (ACs) are common cystic malformations, frequently occurring at various intracranial locations.^[1] In many cases, they are asymptomatic and are diagnosed incidentally.^[1,17] Intracranial ACs often lead to elevated intracranial pressure (ICP) and present as headache, dizziness, seizures, and developmental delay.^[10,16] Surgical treatment modalities are frequently considered, when ACs are symptomatic.^[3,4,10] The common surgical procedures for treating ACs are microsurgical or endoscopic fenestration of the cyst wall and cyst-peritoneal (CP) shunting.^[4,10] Recently, a rare but serious complication after shunting of ACs has become known as shunt dependency syndrome.^[12,14] In the shunt dependency syndrome, there is often no sign

This is an open-access article distributed under the terms of the Creative Commons Attribution-Non Commercial-Share Alike 4.0 License, which allows others to remix, transform, and build upon the work non-commercially, as long as the author is credited and the new creations are licensed under the identical terms.

©2022 Published by Scientific Scholar on behalf of Surgical Neurology International

of intracranial hypertension (enlarging of AC or ventricles), but elevation of ICP occurring and presents headache or vomiting.^[12,14] Only a few cases present impaired visual acuity as a symptom of shunt dependency syndrome.

Herein, we report a case of CP shunt malfunction for AC who presented only impaired visual acuity, as a shunt-dependent syndrome.

CASE REPORT

The patient was a 16-year-old male. At the age of 1 year, his parents noticed the enlarging of his head, and following investigations revealed an AC in the left frontal lobe and hydrocephalus. He was treated with CP shunting at 2 years of age [Figure 1a]. Normal development followed and he underwent extension of the peritoneal shunt catheter in another hospital at 15 years of age. Computed tomography (CT) scan performed immediately after the catheter extension surgery [Figure 1b] demonstrated a decrease in size of the AC and of the cerebrospinal fluid (CSF) space in bilateral middle cranial fossa and lateral ventricles. However, the tip of the intracranial shunt catheter was found to be shorter compared to catheter used in the initial surgery, as observed on the CT scan. At the age of 16 years, he started experiencing impaired visual acuity without headaches. He visited an ophthalmologist and was treated for optic neuritis of unknown etiology, but the treatment was ineffective. Nine months later, his visual acuity worsened to limited to light perception and he was admitted to our hospital.

Except impaired visual acuity, he did not show any neurological problems. Fundus examination revealed bilateral optic atrophy [Figure 2a]. CT scan demonstrated slight increase in the size of the AC, lateral ventricles, and dilated CSF spaces in bilateral middle cranial fossa compared to the CT scan performed 9 months previously [Figure 2b]. Magnetic resonance imaging (MRI) demonstrated distention of the CSF space surrounding the optic nerve sheath [Figure 2c]. CSF pressure with lumbar puncture was elevated to 30 cmH₂O. These findings suggest that malfunction of a CP shunt could cause recurrence of an AC and increased ICP. Cisternography with iotrolan revealed a communication between the left frontal AC, CSF spaces in the middle cranial fossa, and basal cisterns [Figure 2d]. We treated the patient with lumboperitoneal shunting. The size of the CSF space in bilateral middle cranial fossa and that of the AC decreased gradually [Figure 3]. The visual acuity improved to a manual value at 10 cm, 6 days after the surgery, but did not recover completely.

DISCUSSION

The patient we have reported here is thought to have caused elevation of ICP triggered by catheter deviation from AC.

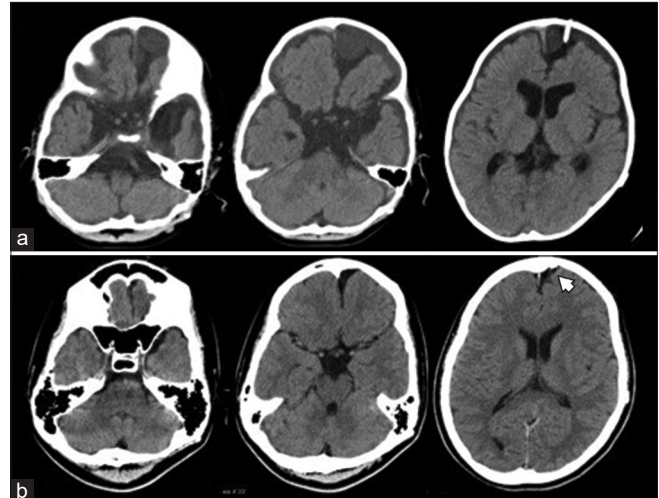


Figure 1: (a) Postoperative computed tomography (CT) scan after cyst-peritoneal (CP) shunting at 2 years of age showing left frontal arachnoid cyst (AC), dilation of cerebrospinal (CSF) space in bilateral middle cranial fossa, basal cisterns, and lateral ventricles. A CP shunt catheter is inserted in the left frontal AC. (b) CT after surgery for extension of the peritoneal shunt catheter at 15 years of age showing reduced size of the left frontal AC and CSF space in bilateral middle cranial fossa and lateral ventricles, compared to that seen at the age of 2 years. However, the shunt catheter in the left frontal AC is shortened (white arrowhead).

We think that this is a very rare case report in that the only symptom was impaired visual acuity. Impaired visual acuity as a symptom of ACs is originally relatively rare, accounting for 1.6–4% of ACs in the literature.^[8,16] Only a few case reports have documented the association between visual symptoms and ACs.^[9,13,20] Zhang *et al.* reported the 6.5-year follow-up of ACs treated with shunting, and shunt malfunction was reported in 26% of patients but without the symptom of visual impairment.^[21] Galarza *et al.* reported follow-ups of ACs treated with open craniotomy after a mean duration of 6 years and reported no recurrence.^[5] Only a few cases of visual impairment after CP shunt placement have been reported.^[2,11,14] Hence, it seems that visual impairment seems to be a rare symptom. It is universally accepted that clinicians should exercise caution when ascribing any nonspecific symptoms such as headaches, behavioral disturbances, or epilepsy to the presence of an AC.^[6] In the cases of CP shunt-related complications, many cases appear to present with symptoms of headaches and vomiting,^[2,11,14] and these symptoms were ordinary complicated in the patient who showed the visual impairment. It is not clear why there were no symptoms of headache or vomiting in this case, but it should be noted that shunt dependency syndrome might only present visual impairment.

Increased ICP is a possible mechanism of for the development of impaired visual acuity in this case. In idiopathic intracranial hypertension, impaired visual acuity is quite common.^[19] It is well-known that patients with increased

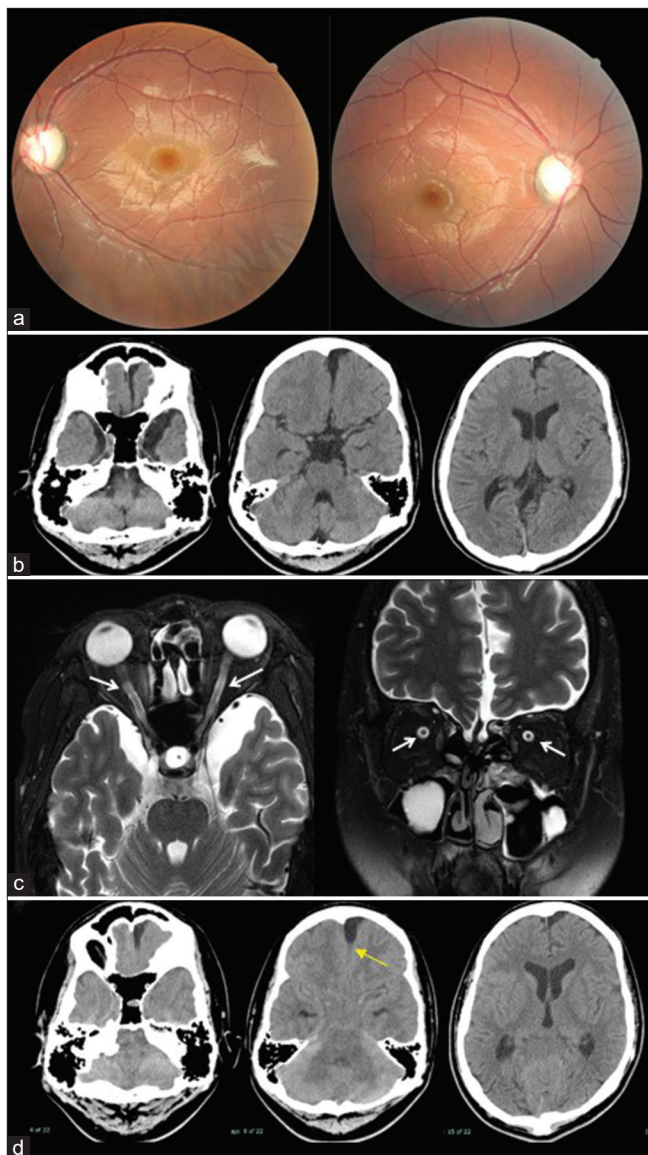


Figure 2: (a) Fundus examination at 16 years of age showing bilateral optic atrophy. (b) Computed tomography after 9 months since the initiation of visual symptoms. Slight enlargement of the left frontal arachnoid cysts (AC) and dilated cerebrospinal fluid (CSF) spaces in bilateral middle cranial fossa and lateral ventricles compared to Figure 1b. (c) Magnetic resonance imaging at 16 years of age demonstrates distention of the CSF space around the optic nerve sheath (white arrows). (d) Cisternography with iotrolan. There is a slight influx of contrast agent in the AC (yellow arrow). Communication between the left frontal AC, CSF spaces in the middle cranial fossa, and basal cisterns is confirmed.

ICP often show distention of the CSF space around the optic nerve sheath,^[7] which was observed in our case. It is also well-known that chronic papilledema caused by increased ICP can lead to secondary optic nerve atrophy.^[15] Hence, we speculate that in our case, first, the shunt catheter in the AC shortened, and CSF flow through the CP shunt reduced.

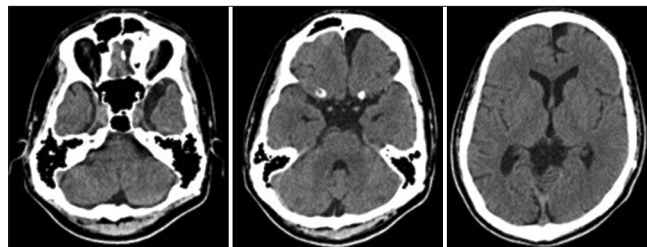


Figure 3: Computed tomography 1 year after lumboperitoneal shunting showing shrinkage of the left frontal arachnoid cysts and cerebrospinal fluid spaces in the middle cranial fossa and lateral ventricles.

The excess CSF from the left frontal AC flowed to the basal cisterns and middle fossa ACs and ICP gradually increased, which could have led to impaired visual acuity.

Regarding the CT and MRI findings in our case, the changes were modest. Aoki *et al.* and Sunami *et al.* reported similar cases of increased ICP as a result of CP shunt malfunction without enlargement of cyst and ventricles, as a slit ventricle syndrome,^[2,18] and recently, these cases have been described as shunt dependency syndrome.^[12,14] Considering these knowledge, the diagnosis of shunt failure cannot be reliably excluded on the basis of normal cyst or ventricular size. The mechanism by which the ventricular size remains unchanged has not been completely elucidated, but could be attributed to low brain compliance because of the regression of absorption mechanism of CSF.^[14] We believe that this phenomenon can be seen in this case. Our case was referred to our hospital after a relatively long time (9 months). The stable size of the AC could be the reason for this delay. Unfortunately, the patient's visual acuity did not recover well, probably because the damage to the optic nerve lasted for a long time. The importance of recognizing the symptoms of increased ICP, regardless of the imaginary result, is highlighted by the findings of our case.

CONCLUSION

Caution should be exercised while treating AC patients with CP shunt developing impaired visual acuity. The possibility of CP shunt malfunction and shunt dependency syndrome should be considered even if the patient presented only impaired visual acuity, and no significant changes in the size of the ACs are observed.

Acknowledgment

We would like to thank Editage (www.editage.com) for English language editing.

Declaration of patient consent

The authors certify that they have obtained all appropriate patient consent.

Financial support and sponsorship

Nil.

Conflicts of interest

There are no conflicts of interest.

REFERENCES

- Al-Holou WN, Yew AY, Boomsaad ZE, Garton HJ, Muraszko KM, Maher CO. Prevalence and natural history of arachnoid cysts in children. *J Neurosurg Pediatr* 2010;5:578-85.
- Aoki N, Sakai T, Umezawa Y. Slit ventricle syndrome after cyst-peritoneal shunting for the treatment of intracranial arachnoid cyst. *Childs Nerv Syst* 1990;6:41-3.
- Choi JW, Lee JY, Phi JH, Kim SK, Wang KC. Stricter indications are recommended for fenestration surgery in intracranial arachnoid cysts of children. *Childs Nerv Syst* 2015;31:77-86.
- Cincu R, Agrawal A, Eiras J. Intracranial arachnoid cysts: Current concepts and treatment alternatives. *Clin Neurol Neurosurg* 2007;109:837-43.
- Galarza M, Pomata HB, Pueyrredón F, Bartuluchi M, Zuccaro GN, Monges JA. Symptomatic supratentorial arachnoid cysts in children. *Pediatr Neurol* 2002;27:180-5.
- Gotz-Wieckowska A, Glowka L, Brazert A, Pawlak M. Ophthalmological symptoms in children with intracranial cysts. *Sci Rep* 2017;7:13630.
- Holbrook J, Saindane AM. Imaging of intracranial pressure disorders. *Neurosurgery* 2017;80:341-54.
- Huang JH, Mei WZ, Chen Y, Chen JW, Lin ZX. Analysis on clinical characteristics of intracranial Arachnoid Cysts in 488 pediatric cases. *Int J Clin Exp Med* 2015;8:18343-50.
- Ishii T, Takagi K, Shirouzu M, Watanabe T, Shinohara T, Furuya K, *et al.* Acute onset of visual disturbance in a patient with arachnoid cyst in the middle cranial fossa. *Brain Nerve* 2008;60:97-102.
- Jafrani R, Raskin JS, Kaufman A, Lam S. Intracranial arachnoid cysts: Pediatric neurosurgery update. *Surg Neurol Int* 2019;10:15.
- Kaliaperumal C, O'Connor B, Marks C. Development of intracranial hypertension after surgical management of intracranial arachnoid cyst: report of three cases and review of the literature. *World Neurosurg* 2013;80:222.e1-4.
- Kim SK, Cho BK, Chung YN, Kim HS, Wang KC. Shunt dependency in shunted arachnoid cyst: A reason to avoid shunting. *Pediatr Neurosurg* 2002;37:178-85.
- Kural C, Kullmann M, Weichselbaum A, Schuhmann MU. Congenital left temporal large arachnoid cyst causing intraorbital optic nerve damage in the second decade of life. *Childs Nerv Syst* 2016;32:575-8.
- Li C, Yin L, Jiang T, Ma Z, Jia G. Shunt dependency syndrome after cystoperitoneal shunting of arachnoid cysts. *Childs Nerv Syst* 2014;30:471-6.
- Osaguona VB. Differential diagnoses of the pale/white/atrophic disc. *Community Eye Health* 2016;29:71-4.
- Pradilla G, Jallo G. Arachnoid cysts: Case series and review of the literature. *Neurosurg Focus* 2007;22:E7.
- Rabiei K, Jaraj D, Marlow T, Jensen C, Skoog I, Wikkelsø C. Prevalence and symptoms of intracranial arachnoid cysts: A population-based study. *J Neurol* 2016;263:689-94.
- Sunami K, Saeki N, Sunada S, Hoshi S, Murai H, Kubota M, *et al.* Slit ventricle syndrome after cyst-peritoneal shunting for temporal arachnoid cyst in children--a clinical entity difficult to detect on neuroimaging study. *Brain Dev* 2002;24:776-9.
- Wall M. Update on Idiopathic Intracranial Hypertension. *Neurol Clin* 2017;35:45-57.
- Wegener M, Prause JU, Thygesen J, Milea D. Arachnoid cyst causing an optic neuropathy in neurofibromatosis 1. *Acta Ophthalmol* 2010;88:497-9.
- Zhang B, Zhang Y, Ma Z. Long-term results of cystoperitoneal shunt placement for the treatment of arachnoid cysts in children. *J Neurosurg Pediatr* 2012;10:302-5.

How to cite this article: Ono K, Mukae N, Nishimura A, Arimura K, Mizoguchi M, Yoshimoto K, *et al.* Impaired visual acuity as an only symptom of shunt malfunction, long time after initial cyst-peritoneal shunting for arachnoid cyst: A case report. *Surg Neurol Int* 2022;13:68.