

Adrenal function and MC1R gene analysis in a prepubertal girl with generalized hyperpigmentation: case report

Aleksandra Rojek¹, Marek Niedziela²

¹Department of Paediatric Endocrinology and Rheumatology, Molecular Endocrinology Laboratory, Poznan University of Medical Sciences, Poland

²Department of Paediatric Endocrinology and Rheumatology, Poznan University of Medical Sciences, Poland

Submitted: 12 April 2011

Accepted: 17 October 2011

Arch Med Sci 2013; 9, 4: 761–764

DOI: 10.5114/aoms.2012.32791

Copyright © 2013 Termedia & Banach

Corresponding author:

Assoc. Prof. Marek Niedziela
MD, PhD

Department of Paediatric
Endocrinology
and Rheumatology
Poznan University
of Medical Sciences

27/33 Szpitalna St

60-572 Poznan, Poland

Phone: +48 61 849 14 81

Fax: 48 61 848 02 91

E-mail: mniedzie@ump.edu.pl

Generalized hyperpigmentation (GHPT) of the skin may occur as a primary defect of pigmentation or in combination with other variable manifestations. It is visible in a number of diseases such as Addison's disease (AD), haemochromatosis, porphyria cutanea tarda, scleroderma and neurofibromatosis, but it can also be associated with malignancy and the use of chemotherapeutics or it can be related to *acanthosis nigricans* in insulin resistance. Skin pigmentation depends on the differences in the amount, type and distribution of melanin produced during melanogenesis in skin melanocytes [1] and remains under the genetic control of more than 120 genes [2]. The most important one is the melanocortin 1 receptor (*MC1R*) gene [3] (OMIM ID: 155555) located on chromosome 16q24.3 and encoding for a 317-amino-acid G-protein coupled receptor. The *MC1R* receptor binds α -melanocyte-stimulating hormone (α -MSH) resulting in the activation of adenylyl cyclase, which produces cyclic adenosine monophosphate (cAMP). The increased cAMP concentration activates various intracellular molecular pathways, promotes melanin synthesis and increases the eumelanin to pheomelanin ratio [4]. *MC1R* receptor also binds ACTH, in this way contributing to the GHPT in AD.

Upregulation of *MC1R* gene expression by UV radiation and α -MSH leads to enhancement of melanogenesis and melanin synthesis induction. Loss-of-function mutations in the *MC1R* gene are associated with fair skin, poor tanning, propensity to freckles and increased skin cancer risk due to a decrease in eumelanin synthesis and subsequently impaired protection against UV radiation [5-7]. To our knowledge, to date, no data are available considering gain-of-function mutations in the human *MC1R* gene which could lead to a constant activation of the *MC1R* receptor and subsequently cause GHPT.

We present the case of a patient with a primary type of progressive GHPT in whom AD was suspected.

An 11-year-old prepubertal girl with GHPT (Figures 1A-C) was born at term with normal birth weight and height and was first brought to our hospital at the age of 3 years with a suspicion of AD. She had a diffuse grey-brownish discoloration of the skin present since birth. Over the first few years of life she developed symmetrical hyperpigmentation most pronounced on her trunk and neck. Later, hyperpigmentation began to affect her hands and feet, and finally the whole body – sparing only the cheeks and finger tips. Her skin was very dry and atopic, and scars were not hyper-

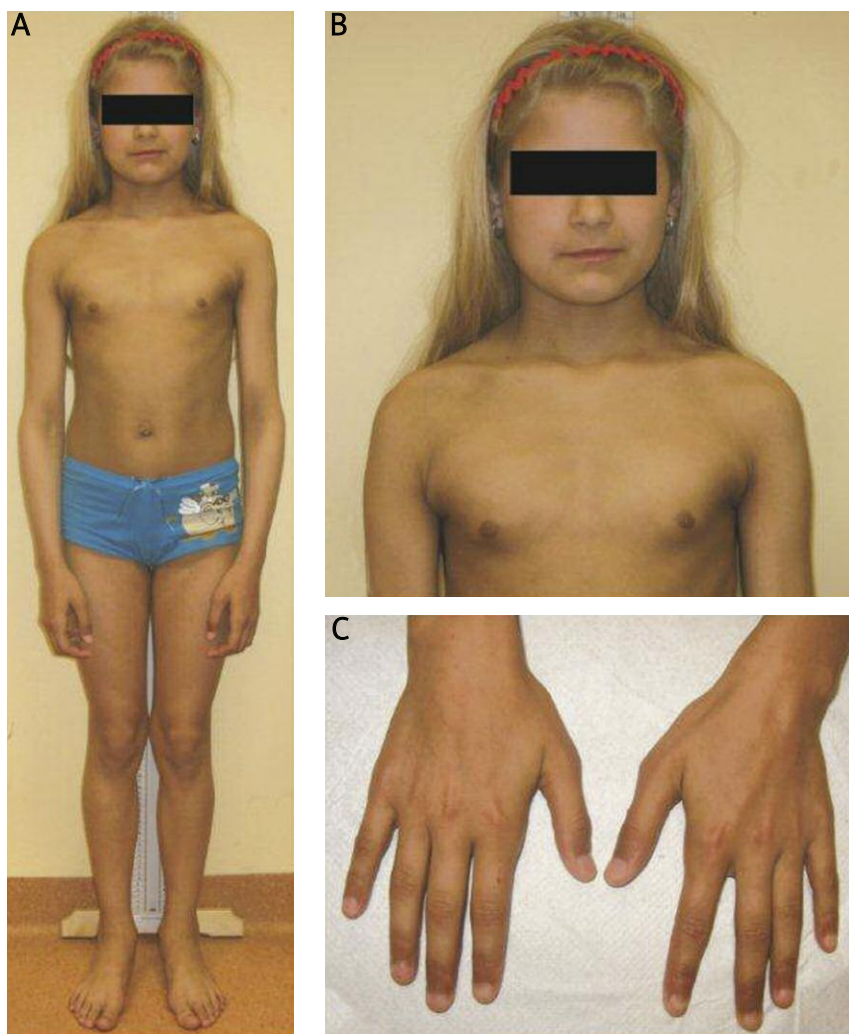


Figure 1. The proband at the age of 11 manifesting a clinical feature of generalized hyperpigmentation (A) with the most intensive pigmentation on her trunk (A, B), neck (B), extremities (A, C) and hands (C)

pigmented. Her toenails as well as fingernails had no major alterations. The girl also experienced chronic diarrhoea, once a month on average, that started at the age of 10-12 months, always considered as allergic diarrhoea. She did not have any history of repeating infections. Her mother also reported a strong ammonia odour of the girl's urine. The remainder of the physical examination, mental development, abdominal ultrasound and magnetic resonance imaging (MRI) of the head were unremarkable. The girl's height and weight both are on the 25th percentile and the onset of puberty was noticed (thelarche Tanner 2). Metabolic diseases were ruled out by serum and urine analysis. Ophthalmologic and neurologic examinations showed no abnormalities. Familial pedigree analysis did not show any similar cases in the patient's family. The adrenocorticotropin (ACTH) stimulation test was performed several times by intravenous injection of synthetic ACTH (Table I). Cortisol levels were normal after ACTH stimulation, thus excluding AD. The patient acquired a chickenpox infec-

tion which presented as small white, unpigmented spots on the whole body, but hyperpigmentation was still present, especially on the girl's neck and trunk. A histopathological examination of a skin biopsy from the buttock revealed a strong pigmentation of the epidermal basal layer and melanin aggregates within melanophages of the *stratum papillare*. The number of melanocytes within the epidermis was unchanged and *melanosis diffusa congenita* was diagnosed (OMIM ID: 145250).

Written informed consent was obtained from parents and the study was approved by the local Ethics Committee of Poznan University of Medical Sciences. Blood samples were collected and frozen at -20°C until analysis. All laboratory tests were measured in the Central Laboratory of K. Jonscher's Clinical Hospital of the University using commercial kits. Luteinizing hormone (LH), follicle-stimulating hormone (FSH), thyroid-stimulating hormone (TSH), parathyroid hormone (PTH), prolactin, estradiol, free thyroxine (fT4) and insulin were assayed

Table I. Laboratory tests in blood samples (abnormal values are given in bold). A single measurement of oestradiol was elevated at the age of 3 years but with no breast development. Slightly elevated ACTH level at the age of 8 years was probably a result of the morning stress during blood collection. The remaining results were all normal

Laboratory tests	Results						Reference range
	Age 3	Age 5	Age 6	Age 7	Age 8	Age 9	
LH [mIU/ml]	0						0.3–2.0
FSH [mIU/ml]	2.1						0.3–2.5
Oestradiol [pg/ml]	31.0						4–15
Prolactin [ng/ml]	19.5						3.24–29.12
TSH [μ IU/ml]	1.6	2.5		1.85	3.734	1.415	0.470–4.640
fT4 [ng/dl]	1.15			1.23	1.16		0.71–1.85
TPO-Ab [U/ml]				2			< 60
21-hydroxylase-Ab [U/ml]		0.82					< 1
ACTH (basal) [pg/ml]							
7 am		21.3	29.4	31.1	63.2	41.2	10–60
Cortisol [basal and stimulated (ACTH test: 250 μ g, <i>i.v.</i>)] [μ g/dl]							
7 am (time 0)	17.5			13.1	26.9		9.4–26.0
7:30 am (time + 30 min)	28.3			22.5	31.3		
8:00 am (time + 60 min)	27.5			32.9	38.5		
8:30 am (time + 90 min)	34.5			33.1	36.9		
9:00 am (time + 120 min)	36.5			35.6	43.4		
Cortisol [basal and stimulated (ahort ACTH test: 1 μ g/1.73 m ² <i>i.e.</i> 0.4 μ g, <i>i.v.</i>)] [μ g/dl]							
7 am (time 0)		14.9	15.0				9.4–26.0
7:30 am (time + 30 min)		22.9	23.2				
8:00 am (time + 60 min)		21.2	20.1				
Aldosterone [pg/ml]				36.6			29.4–161.5
PRA [ng/ml]				1.99			0–7
DHEA-S [μ mol/l]					0.65		1.02–7.16
Insulin [μ IU/ml]					4.8		0–15
C-peptide [pmol/ml]				1.39			0.59–1.56
Glucose [mg/dl]		79.4		99	93		59–101
HbA _{1c} [%]		5.2		5.3			< 6.1
Na ⁺ [mmol/l]	139	134	140	144	139		132–145
K ⁺ [mmol/l]	4.59	4.44	4.3	4.1	3.79		3.1–5.1
Mg [mg/l]				21.3			18.2–23.1
Ca [mmol/l]				2.60			2.1–2.6
P [mg/dl]				4.34			4.50–5.52
PTH [pg/ml]				26			15–65
EmA-IgA [RU/ml]				neg.			< 20
EmA-IgG				neg.			Neg/Pos.

by MEIA, thyroid peroxidase antibody (TPO-Ab), 21-hydroxylase-antibody (21-hydroxylase-Ab), cortisol, aldosterone, dehydroepiandrosterone sulphate (DHEA-S) and C-peptide by RIA, and adrenocorticotrophic hormone (ACTH) IRMA methods.

Genomic DNA was isolated from peripheral blood leukocytes using QIAamp[®] DNA Blood Mini Kit (QIAGEN). Primer sequences used to amplify

the *MC1R* gene as well as polymerase chain reaction (PCR) conditions are available on request. The samples were subjected to direct sequencing using BigDye Terminator v3.1 cycle sequencing kit (Applied Biosystems) and an ABI Prism 3130XL Genetic Analyzer (Applied Biosystems). We did not find any mutations within the whole *MC1R* gene.

The most likely diagnosis of the patient with GHPT is primary adrenal insufficiency, subsequent ACTH excess and overstimulation of MC1R in the skin. Recurrent episodes of diarrhoea in the patient could suggest an adrenal crisis but several adrenal function tests, also performed during such episodes, excluded adrenal failure.

Although we did not find any mutations in the coding region of the *MC1R* gene, or in the untranslated regions or the promoter region, it is possible that disorders in other genes are responsible for the skin pigmentation phenotype in our patient. Branicki *et al.* showed that *HERC2* rs12913832 may be one of the genes responsible for masking the effect of *MC1R* polymorphisms and significantly affect the function of the MC1R receptor [8]. The phenotype of our patient was characterized by diffuse GHPT, which varied slightly in intensity in different parts of her body. *Cafe-au-lait* macules or larger hypopigmented macules were not present. This is contrary to patients previously described in the literature [9]. Therefore, we concluded that the pathogenesis is restricted only to melanogenesis-related functions in the skin.

Familial progressive hyperpigmentation (FPH, OMIM ID: 145250) is a rare congenital diffuse hyperpigmentation disorder affecting the human skin. Familial progressive hyperpigmentation is inherited in an autosomally dominant [9] or recessive [10] manner and is characterized by patches of hyperpigmentation present at birth or in early infancy that increase in size and also in number with age. Ultimately, a large percentage of the skin becomes hyperpigmented. These skin changes always occur on the face, neck, trunk, limbs, lips, oral mucosa and on the palms and soles, but this is not the case for our patient, whose lips, oral mucosa and conjunctiva were not hyperpigmented. Histological examination reveals an increase in the amount of melanin pigment found throughout the epidermis, specifically within the stratum corneum. The skin is the only affected organ and patients do not normally suffer from any other systemic disease [11, 12]. The molecular background of the disease still remains unknown. Zhang *et al.* examined a three-generation Chinese family consisting of 17 individuals, 6 of whom were affected, including 3 males and 3 females. Contrary to the previous study and our patient, the first onset of the disease in this family was at the age of 5 years, not at birth. All 6 affected members had typical clinical manifestations of FPH. They had normal mental abilities and no systemic disease such as gastrointestinal, liver or kidney ailments. The pedigree of the family showed an autosomal dominant pattern of FPH inheritance [13]. This study gives new potential insight into the plausible bipotential role of ACTH in both adrenal stimulation via MC2R and in skin pigmentation via MC1R, both transduction processes

effectively activated at different plasma concentrations of ACTH.

Because there were no disease-causing gain-of-function mutations in the *MC1R* gene, we concluded that this gene is not responsible for the hyperpigmented phenotype in our patient. Further studies of other candidate genes crucial for human skin pigmentation as well as genetic analysis of the selected SNP polymorphisms will help us to understand the molecular background of the GHPT disorder present in our case.

Acknowledgments

This work was funded by the Department of Paediatric Endocrinology and Rheumatology, Poznan University of Medical Sciences (502-01-01104118-06037).

References

1. Frudakis T. Molecular photofitting. Predicting ancestry and phenotype using DNA. Academic Press 2008.
2. Bennet DC, Lamoreux ML. The color loci of mice – a genetic century. *Pigment Cell Res* 2003; 16: 333-44.
3. Rees JL. The genetics of sun sensitivity in humans. *Am J Hum Genet* 2004; 75: 739-751.
4. Sturm RA, Box NF, Ramsay M. Human pigmentation genetics: the difference is only skin deep. *Bioassays* 1998; 20: 712-21.
5. Box NF, Wyeth JR, O’Gorman LE, Martin NG, Sturm RA. Characterization of melanocyte stimulating hormone receptor variant alleles in twins with red hair. *Hum Mol Genet* 1997; 6: 1891-7.
6. Smith R, Healy E, Siddiqui S, et al. Melanocortin 1 receptor variants in an Irish population. *J Invest Dermatol* 1998; 111: 119-22.
7. Bastiaens M, ter Huurne J, Gruis N, et al. The melanocortin-1-receptor gene is the major freckle gene. *Hum Mol Genet* 2001; 10: 1701-8.
8. Branicki W, Brudnik U, Wojas-Pelc A. Interactions between *HERC2*, *OCA2* and *MC1R* may influence human pigmentation phenotype. *Ann Hum Genet* 2009; 73: 160-70.
9. Zanardo L, Stolz Z, Schmitz G, et al. Progressive hyperpigmentation and generalized lentiginosis without associated systemic symptoms: a rare hereditary pigmentation disorder in South-East Germany. *Acta Derm Venereol* 2004; 84: 57-60.
10. Hüffmeier U, Hausser I, Reis A, Rauchi A. Novel autosomal recessive progressive hyperpigmentation syndrome. *Am J Med Genet* 2005; 135A: 195-9.
11. Rebora A, Parodi A. Universal inherited melanodyschromatosis: a case of melanosis universalis hereditaria? *Arch Dermatol* 1989; 125: 1442-3.
12. Debaio L, Ting L. Familial progressive hyperpigmentation: a family study in China. *Brit J Derm* 1991; 125: 607.
13. Zhang C, Deng Y, Chen X, et al. Linkage of a locus determining familial progressive hyperpigmentation (FPH) to chromosome 19p13.1-pter in a Chinese family. *Eur J Dermatol* 2006; 16: 246-50.