

# Use of Neutral Argon Plasma in the Laparoscopic Treatment of Endometriosis

Ceana Nezhat, MD, Kimberly A. Kho, MD, MPH, Vadim Morozov, MD

## ABSTRACT

**Background and Objectives:** To report the feasibility and safety of the use of a novel energy source that uses an electrically neutral beam of pure argon plasma for the laparoscopic management of endometriosis.

**Methods:** In this prospective pilot study, 20 patients undergoing laparoscopic treatment of endometriosis were included. Characteristic endometriotic lesions throughout the pelvis were vaporized or resected using neutral argon plasma. Specimens were evaluated for the presence of endometriosis and thermal effects on tissue. The bases of the treated lesions were biopsied to determine whether residual endometriosis was present.

**Results:** Neutral argon plasma was used in 18 of the 20 patients for laparoscopic treatment of pelvic endometriosis. All biopsies confirmed complete vaporization or resection with no residual endometriosis at the base. Endometriosis was identified on pathology in all lesions excised. Thermal effects did not interfere with histologic analysis in any of the lesions. No complications occurred.

**Conclusion:** Neutral argon plasma can be utilized as a multi-functional device that has vaporization, coagulation, and superficial cutting capacities with minimal thermal spread and acceptable outcomes. The use of neutral argon plasma appears to be efficacious and safe for the complete treatment of endometriotic implants.

**Key Words:** Endometriosis, Neutral argon plasma, Excision of endometriosis, Vaporization of endometriosis.

## INTRODUCTION

Endometriosis is the implantation of endometrial-type cells outside of the uterine cavity. The condition is associated with chronic pain, diminished quality of life, subfertility, psychological morbidity, and work absenteeism.<sup>1,2</sup> It is the third leading cause of gynecologic hospitalizations<sup>3</sup> and mainly affects reproductive-aged women. It is found in up to 50% of women with infertility<sup>4</sup> and up to 70% of adolescents with pelvic pain recalcitrant to conservative measures.<sup>5</sup>

Because lesions are usually undetectable by examination, preoperative laboratory tests, or imaging techniques, actual operative visualization and sampling of lesions is necessary to diagnose the disease. Thus, surgical assessment by either laparoscopy or laparotomy for simultaneous diagnosis and treatment of endometriosis has become the “gold standard.” Surgical treatment may consist of excision, vaporization, coagulation of lesions, or all of these. Multiple instruments have been used for the surgical management of endometriosis including scissors, bipolar and monopolar electrosurgery, ultrasonic energy, and lasers.

The PlasmaJet system (PJS), developed by Plasma Surgical Limited (Theale, Berkshire, UK), gained FDA approval as a coagulation device in 2004 and provides an electrically neutral stream of ionized argon gas. The system emits a high-energy jet of argon plasma possessing thermal and kinetic energy that can be used to coagulate a tissue surface including small vessels and lymphatics. Since its introduction, PlasmaJet has been used safely in both open and endoscopic cases in orthopedics, oncology, gastroenterology, liver surgery, plastic surgery of the abdomen and face, and in thoracic surgery.

We report our initial experience using this novel energy source for the laparoscopic management of endometriosis.

Atlanta Center for Special Minimally Invasive Surgery and Reproductive Medicine, Atlanta, Georgia, USA (Drs. Nezhat, Kho).

Division of General Obstetrics and Gynecology, University of Maryland, Baltimore, Maryland, USA (Dr. Morozov).

Ceana Nezhat, MD, is a consultant for Plasma Surgical Limited. The PlasmaJet<sup>®</sup> System with console was loaned and 20 disposable handpieces were donated by Plasma Surgical Limited for the purposes of this study.

Address correspondence to: Ceana Nezhat, MD, Atlanta Center for Special Minimally Invasive Surgery and Reproductive Medicine, 5555 Peachtree Dunwoody Road, Suite 276, Atlanta, GA 30342, USA. Telephone: (404) 255-8778, Fax: (404) 255-5627, E-mail: ceana@nezhat.com

DOI: 4293/108680809X12589998403967

© 2009 by JSLS, *Journal of the Society of Laparoendoscopic Surgeons*. Published by the Society of Laparoendoscopic Surgeons, Inc.

## METHODS

From April to December 2008, 20 patients with surgically diagnosed endometriosis were selected. The hospital's Institutional Review Board granted exempt status to this study.

All patients underwent general anesthesia and multi-puncture operative laparoscopy as previously described.<sup>6</sup> Characteristic endometriotic lesions throughout the pelvis were vaporized or resected with the PJS at 100% power using high-temperature and high-gas flow. For vaporization, the probe was directed at the lesions from a distance of close to 5mm, spraying the tissue surface at an angle of approximately 45 degrees until the tissue surface demonstrated a characteristic silver, shiny appearance and there was visual confirmation of complete eradication of the lesions. Tissue surfaces were irrigated continuously with lactated ringers, removing debris from the area. The bases of these lesions were then biopsied with sharp scissors to determine whether residual endometriosis was present. In delicate areas, such as the ovarian cortex, fallopian tubes, parareter, bladder, and bowel serosa, lesions were visually identified and vaporized and irrigated until the appearance of underlying healthy tissue, without performing a biopsy.

Other lesions were resected using the PJS as a cutting instrument. The probe was placed closer to the tissue surface at approximately a 90-degree angle. After excision with visual judgment of complete treatment, biopsies at the site of the excised lesions were obtained sharply with scissors. Both the lesion and biopsy of the posttreatment lesion site were sent to pathology for evidence of endometriosis, as well as for thermal effects on the specimen.

One patient underwent second-look laparoscopy for adhesions 7 weeks after her initial surgery during which neutral argon plasma was used for the treatment of endometriosis. Sites where the PJS was utilized during the first procedure were biopsied. The tissue was evaluated for nonvisible residual endometriosis and posttreatment descriptive healing.

## RESULTS

Neutral argon plasma was intended for use in 20 patients, and actually used in 18 patients, for laparoscopic treatment of pelvic endometriotic lesions. All procedures were completed as planned, though in 2 cases equipment failure was encountered before initiation of treatment.

All study participants were women with a mean age of 32

years (range, 20 to 49). Mean BMI was 23.9kg/m<sup>2</sup> (range, 21 to 29), mean gravidity was 0.9 (range, 0 to 5), and mean parity was 0.4 (range, 0 to 3). During surgery, all patients were assigned an endometriosis stage according to the 1996 revised American Society for Reproductive Medicine classifications<sup>7</sup>; 5 patients had stage I endometriosis, 5 had Stage II, 4 had Stage III, and 4 had Stage IV disease. Seven patients had been diagnosed with endometriosis during a previous surgery. None of the patients had significant past medical histories.

A total of 46 lesions were safely vaporized or excised with neutral argon plasma in locations including the anterior cul-de-sac (15), ovaries (10), posterior cul-de-sac (7), pelvic sidewalls (7), pararectal spaces (2), fallopian tubes (2), broad ligament (1), uterine serosa (1), and rectal serosa (1).

Twenty-seven lesions were vaporized. Seven posttreatment lesion sites were biopsied, and all biopsy specimens confirmed complete vaporization with no residual endometriosis at the base of the lesion.

Nineteen lesions were resected using the PJS as a cutting instrument. In all 19 (100%) specimens, endometriosis was identified on pathology. Thermal effects did not interfere with histologic analysis in any of the lesions. At 8 of these sites, biopsy of the posttreatment lesion site was obtained with 100% confirmation of complete resection with no residual endometriosis at the base.

The patient who underwent a second-look laparoscopy 7 weeks after the initial treatment had no residual endometriosis at her previously treated sites. At second-look, these sites were reperitonealized and free of adhesions. Histology of these previously treated sites revealed fibroadipose tissue with reactive fibrosis and foreign body reaction and no endometriosis.

All procedures were performed in an outpatient setting. All patients were discharged within 23 hours postoperatively. There were no intraoperative or postoperative complications.

## DISCUSSION

Plasma is often described as the fourth state of matter, consisting of ionized gas in the form of high-energy particles. The PJS generates argon plasma by concentrating a low flow of inert argon gas within an insulated handpiece that contains bipolar electrodes. A low voltage of approximately 30V to 60V ionizes the argon gas, thereby producing electrically neutral, high-energy argon plasma that is

emitted from the tip of the handpiece in a precise jet stream. Possessing thermal, kinetic, and light energies, the jet of plasma first blows away debris, tissue, and blood from the point of application. A thin, flexible coagulum is then formed that seals the tissue surface. Animal studies have demonstrated a depth of penetration between 0.5mm to 2.0mm, depending on duration of application of the jet to tissue (Y. Parhomenko, S. Tartynsky, K. Kachiken, unpublished data).

With both monopolar electrosurgery and argon beam coagulation, the current is applied to the tissue and leads to coagulation through combined effects of heating and arc generation between an active electrode and grounded tissue. Arcing vaporizes tissue and results in small fissures in tissue created by sparks, which allow for deeper tissue destruction as current flows along a tissue's path of least resistance.<sup>8,9</sup> Argon-enhanced tissue fulguration causes tissue effects that depend on the electrical characteristics of tissue, its physical composition, and degree of vascular perfusion.<sup>10</sup> In contrast, the neutral argon plasma device emits an electrically neutral plasma jet, with no current flowing through the patient, and tissue penetration remains minimal. The device behaves in a similar way to the CO<sub>2</sub> laser as it desiccates and effectively vaporizes tissue by forming a series of layers of eschar without sparking, and thus without disruption of the coagulum. This is purported to provide a more effective, homogenous barrier to further bleeding (Y. Parhomenko, S. Tartynsky, K. Kachiken, unpublished data). Additionally, the PJS uses approximately 10% of the gas flow used by the argon beam coagulator; typical gas flow is less than 0.4L/min, thus theoretically decreasing the risk for air embolism and intraperitoneal overpressure (**Table 1**).

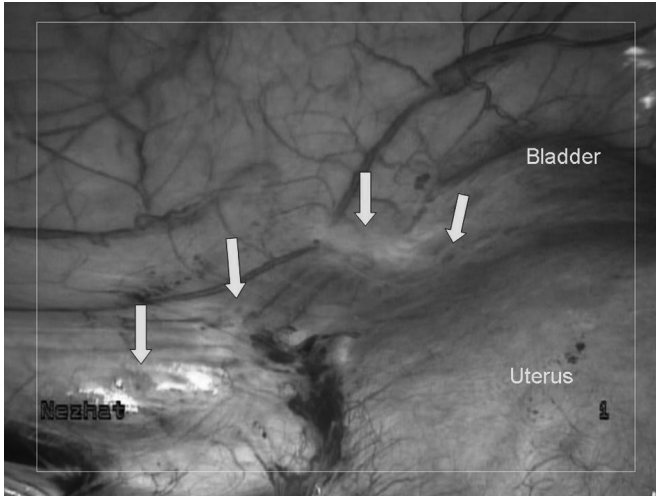
Early use of the PJS in several unpublished pilot studies has demonstrated safe application in both open and endoscopic cases in orthopedics, oncology, gastroenterology, liver surgery, plastic surgery of the abdomen and face, and in thoracic surgery (Y. Parhomenko, S. Tartynsky, K. Kachiken and J. Gugenheim, A. Ianielli, unpublished data).<sup>11,12</sup> Most analogous to endometriosis, ovarian cancer has been treated with neutral argon plasma. An investigation<sup>11</sup> of its applicability in cytoreduction for ovarian cancer demonstrated that the device effectively vaporized ovarian and peritoneal cancer cells while maintaining minimal thermal spread. The ex-vivo study of high-grade serous omental tumors revealed thermal damage to be approximately 5% of the depth of tissue vaporization. With exposures of 2 seconds to 4 seconds on standard settings, vaporization depths varied from 0.9 mm to 6.1 mm (mean 2.7; SD 1.3).

This technology is applicable to the treatment of endometriosis, as lesions are frequently superficial peritoneal implants that are diagnosed on visualization. The depth of involvement in underlying tissue may be visualized by characteristic expression of chocolate fluid or fibrosis. The goal of treatment is to completely eliminate these lesions when appropriate.<sup>13</sup>

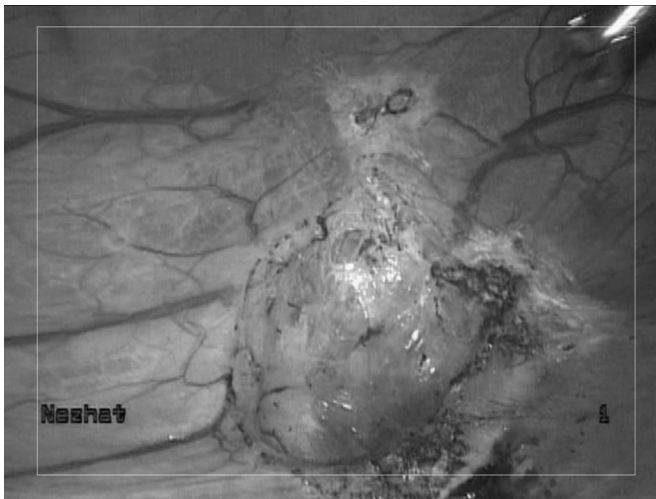
The vaporization technique used during treatment of endometriosis is analogous to that used when other energy sources are used. In an "onion peel fashion," layer by layer treatment of lesions is performed from superficial to deep layers, while alternating vaporization with irrigation until underlying healthy tissue is identified (**Figures 1 and 2**). Our experience reveals that this method of visual inspection accurately determines adequacy of treatment.

**Table 1.**  
Comparison of Argon Beam Coagulator and Neutral Argon Plasma

	Argon Beam Coagulator	Neutral Argon Plasma (PJS)
Inert argon gas	4-7 L/min	<0.4 L/min
Risks	Air embolism; Overpressure	Minimized
Thermal spread	4-10 mm	0.5-2 mm
Voltage	5000-9000	30-60
Current flow	Active electrode, requires grounding pad; Similar to monopolar electrosurgery	Electrically neutral, no electricity passes to the patient Comparable to bipolar electrosurgery
Applications	Coagulation	Vaporization, cutting, small vessel coagulation
Surgical use	No direct contact with tissue	No direct contact with tissue
Visual cues	Blue spray	Light blue glow



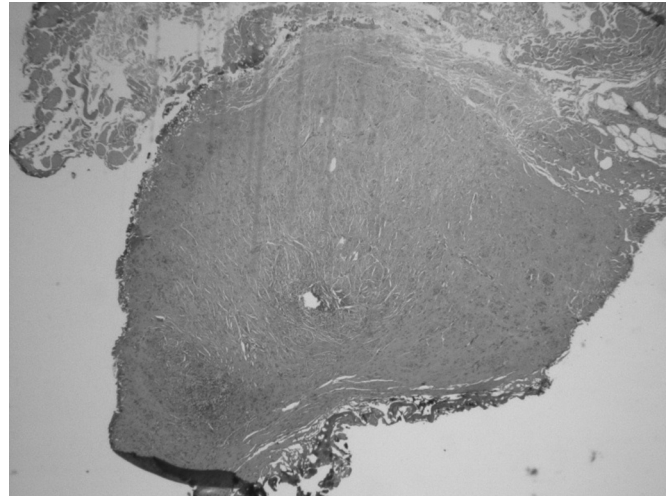
**Figure 1.** Endometriotic lesions on peritoneal surfaces of uterus and bladder.



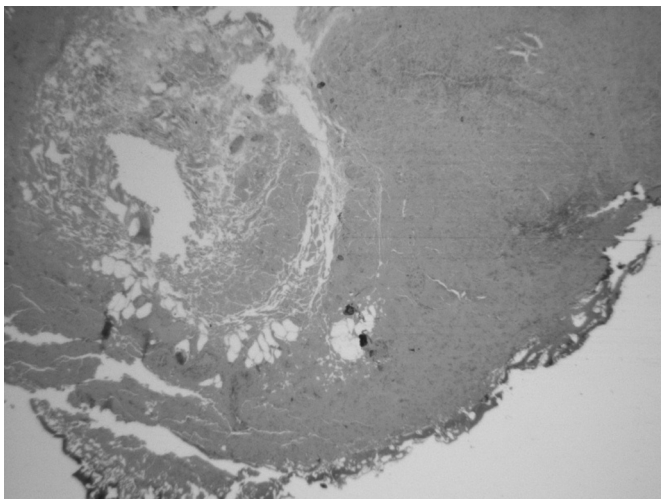
**Figure 2.** Site of endometriotic lesions uterine and bladder surfaces after vaporization with PlasmaJet. No visual evidence of endometriosis remains. Note minimal depth of penetration allows for superficial, yet complete treatment.

All pathologically proven endometriosis lesions that were vaporized or resected using neutral argon plasma, revealed no residual disease when the posttreatment lesion sites were biopsied sharply. Furthermore, during a second-look procedure, in a patient with Stage IV endometriosis, the endometriotic lesions to which neutral argon plasma were applied during the first procedure demonstrated a fibroadipose healing process with no further evidence of adhesions or disease when rebiopsied 7 weeks postoperatively.

Neutral argon plasma may also be used as a cutting device



**Figure 3.** Hematoxyline-eosin stained micrograph demonstrating <1 mm lateral thermal spread.



**Figure 4.** Area of thermal spread <1 mm.

for tissue resection by placing the jet in close proximity to tissue. All visually confirmed endometriotic lesions that were biopsied using the PJS were pathologically confirmed as endometriosis. Histopathological analysis of resected lesions demonstrated <1-mm lateral thermal spread, causing minimal specimen damage (**Figures 3 and 4**). These findings are consistent with findings in earlier studies that demonstrated minimal thermal spread, and thus minimal tissue destruction to biopsy specimens (Y. Parhomenko, S. Tartynsky, K. Kachiken, unpublished data).<sup>11</sup> Also notable, all areas of resection and vaporization were hemostatic after application of neutral argon plasma. These findings confirm earlier human and animal



studies that have demonstrated efficacy in sealing capillary and lymphatic channels in the subcutaneous fat, liver, spleen, and kidney (Y. Parhomenko, S. Tartynsky, K. Kachiken, and J. Gugenheim, A. Ianielli, unpublished data).<sup>11–13</sup>

Although this is a preliminary study in a limited number of patients considering feasibility and safety, neutral argon plasma appears to possess unique characteristics that make it a safe and useful tool for the treatment of endometriosis. Within the limitations of a pilot study, plasma energy appears to be efficacious and safe for the complete vaporization of endometriotic implants and can be used for the laparoscopic management of endometriosis. The absence of electric current flow through the patient also avoids potential complications, such as capacitive coupling, arcing, and electric burns. Larger series considering long-term outcomes will be needed to confirm these initial findings.

#### References:

1. Low WY, Edelman RJ, Sutton C. A psychological profile of endometriosis patients in comparison to patients with pelvic pain of other origins. *J Psychosom Res.* 1993;37(2):111–116.
2. Denny E. Women's experience of endometriosis. *J Adv Nurs.* 2004;46(6):641–648.
3. Eskenazi B, Warner ML. Epidemiology of endometriosis. *Obstet Gynecol Clin North Am.* 1997;24:235–258.
4. Strathy JH, Molgaard CA, Coulam CB, Melton LJ. Endometriosis and infertility (a laparoscopic study of endometriosis among fertile and infertile women). *Fertil Steril.* 1982;38:667–672.
5. Reese KA, Reddy S, Rock JA. Endometriosis in an adolescent population: the Emory experience. *J Pediatr Adolesc Gynecol.* 1996;9(3):125–128.
6. Nezhat C, Nezhat F, Nezhat C. *Nezhat's Operative Gynecologic Laparoscopy and Hysteroscopy.* Third edition. New York: Cambridge University Press; 2008.
7. Revised American Society for Reproductive Medicine classification of endometriosis: 1996. *Fertil Steril.* 1996;67(5):817–821.
8. Harrell AG, Kercher KW, Heniford BT. Energy sources in laparoscopy. *Semin Laparosc Surg.* 2004;11(3):201–209.
9. Daniell J, Fisher B, Alexander W. Laparoscopic evaluation of the argon beam coagulator: initial report. *J Reprod Med.* 1993;38(2):121–125.
10. Gale P, Adeyemi B, Ferrer K, Ong A, Brill A, Scoccia B. Histologic characteristics of laparoscopic argon beam coagulation. *J Am Assoc Gynecol Laparosc.* 1998;5(1):9–22.
11. Sonoda Y, Olvera N, Chi DS, Brown CL, Abu-Rustum N, Levine DA. Pathologic analysis of ex vivo plasma energy tumor destruction in patients with ovarian or peritoneal cancer. Presented at: 40th Annual Meeting of the Society of Gynecologic Oncologists, February 5–8, 2009, San Antonio, Texas.
12. Ianelli A, Bafghi AR, Patrono D, Sautot-Vial S, Gugenheim J. Use of PlasmaJet<sup>®</sup> system in patients undergoing abdominal lipectomy following massive weight loss resulting from bariatric surgery: early experience. *Obes Surg.* 2006;16:1504–1507.
13. Nezhat C, Berger G, Nezhat F, Buttram V, Nezhat C. *Endometriosis: Advanced Management and Surgical Techniques.* New York: Springer-Verlag; 1995.