



# Joystick of the Talus for Correcting Malalignment During Arthroscopic Ankle Arthrodesis: A Surgical Tip

Alessio Bernasconi, M.D., Nazim Mehdi, M.D., Julien Laborde, M.D., Cesar de Cesar Netto, M.D., Ph.D., Louis Dagneaux, M.D., and François Lintz, M.D., F.E.B.O.T.

**Abstract:** Ankle arthrodesis has been widely reported as an effective solution in treating tibiotalar joint osteoarthritis. The arthroscopic tibiotalar approach for arthrodesis has also been proven to give excellent results in terms of bone fusion rates and reduction of wound-related pain and complications. Historically, ankle malalignment has represented one of the main contraindications for the arthroscopic procedure, but interestingly some investigators have shown that the coronal joint deformity may be addressed arthroscopically as well. Other investigators have also demonstrated that part of the valgus/varus is due to malrotation of the talus within the mortise; therefore, controlling the talar position becomes crucial for correcting more severe deformities. We present here a technique for correcting tibiotalar malalignment during arthroscopic arthrodesis in varus or valgus ankles, performed through a K-wire used as a joystick to manage the talar position on both the coronal and axial planes.

After the first description of arthroscopic ankle arthrodesis (AAA) reported in 1983 by Schneider,<sup>1</sup> many studies have documented excellent

clinical results in association with a lower complication rate when compared with traditional open surgery.<sup>2</sup> Classically, the presence of valgus or varus malalignment (over 10°-15°) has been considered a formal contraindication for the arthroscopic procedure.<sup>3,4</sup> However, some studies have reported good results after AAA performed in patients with a significant preoperative coronal tibiotalar deformity, suggesting that it should only be considered as a relative contraindication for arthroscopic fusion.<sup>5,6</sup>

*From the Orthopaedic and Traumatology Unit, Department of Public Health, "Federico II" Naples University (A.B.), Napoli, Italy; Department of Trauma and Orthopaedics, St. George's Hospital (A.B.), London, United Kingdom; Clinique de l'Union, Ankle and Foot Surgery Center (N.M., J.L., F.L.), Saint-Jean, France; Hospital for Special Surgery (C.d.C.N.), New York, New York, U.S.A.; and Hip, Knee and Foot Surgery Unit, Montpellier University Hospital (L.D.), Montpellier, France.*

Looking at the current literature, there is a wide consensus about the importance of achieving a good alignment of the hindfoot and an adequate talar rotation as key elements for the long-term success of fusion.<sup>7</sup> To the best of our knowledge, no specific techniques have been described to address coronal and axial deformities of the ankle during AAA.<sup>5,6</sup>

*The authors report the following potential conflicts of interest or sources of funding: N.M. receives support from Novastep and Integra. J.L. receives support from Novastep and FH. C.d.C.N. receives support from CurveBeam and Ossio. F.L. receives support from CurveBeam and Newclip Techniques. A commercial entity (Stryker) paid or directed, or agreed to pay or direct, benefits (publication fees) to a research fund, foundation, educational institution, or other charitable or nonprofit organization with which the authors are affiliated or associated. None of the authors received payments or other benefits or a commitment or agreement to provide such benefits from a commercial entity. Full ICMJE author disclosure forms are available for this article online, as supplementary material.*

Our goal is to report a technical tip for the intraoperative management of the tibiotalar coronal alignment during AAA, using a 3-mm K-wire as a joystick for driving the talus (joystick of the talus [JOT]). The objective of the JOT technique is to control the talar tilt (coronal plane) as well as rotation (axial plane) in order to obtain full intra-articular reduction of the talus inside the ankle mortise. This technique can be used in patients diagnosed with a primary or secondary varus or valgus correctable tibiotalar arthritis, complaining of

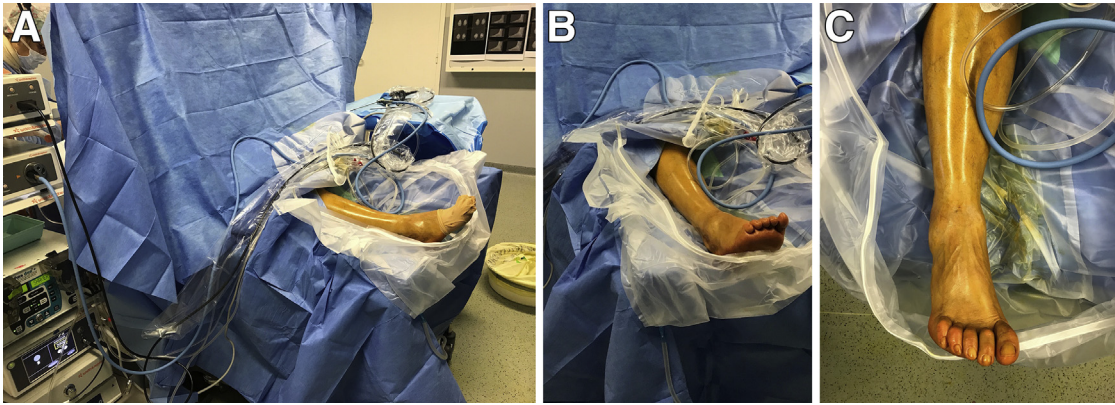
*Received December 1, 2017; accepted January 15, 2018.*

*Address correspondence to Alessio Bernasconi, M.D., Orthopaedics and Traumatology Unit, Department of Public Health, University Federico II of Naples, via Pansini n 5, 90131 Naples, Italy. E-mail: alebernas@gmail.com*

*© 2018 Published by Elsevier on behalf of the Arthroscopy Association of North America. This is an open access article under the CC BY-NC-ND license (<http://creativecommons.org/licenses/by-nc-nd/4.0/>).*

*2212-6287/171485*

*<https://doi.org/10.1016/j.eats.2018.01.005>*



**Fig 1.** (A) During an arthroscopic ankle arthrodesis the patient is placed in the supine position on the operating table under general or locoregional anaesthesia. (B) A picture showing the slight flexion of the knee (around 20°) during an arthroscopic ankle arthrodesis, achieved by applying a support under the popliteal cavus. (C) A picture showing the ankle and the foot as seen by the surgeon during an arthroscopic ankle arthrodesis.

ankle pain exacerbated by weight bearing and walking on uneven ground, and presenting (not systematically) with swelling and stiffness of the tibiotalar joint at physical examination. Weight-bearing cone beam computed tomography (PedCat, CurveBeam, Warrington, PA) is systematically performed to confirm diagnosis and to characterize the stage of arthritis and the 3-dimensional deformity of the ankle joint. We consider a rigid deformity (defined as lack of correction under stress) to be a contraindication for this technique. As for other kinds of AAA, this procedure is also contraindicated in case of important bone defects, active infection, and revision of previous nonunion or arthroplasty requiring autologous grafting.

## Surgical Technique

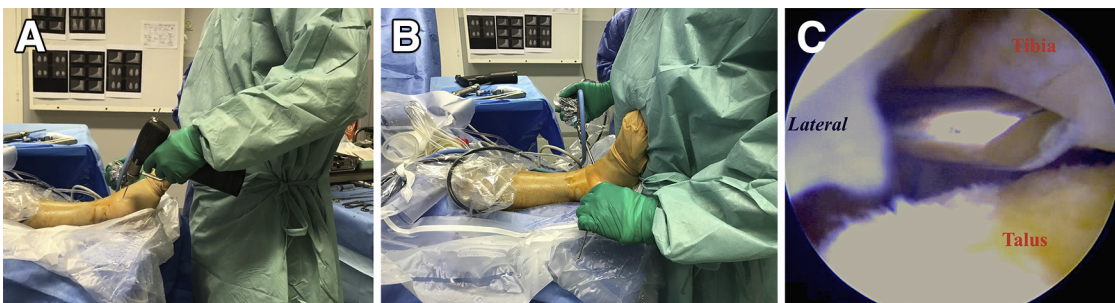
### Patient Positioning

The patient is placed in the supine position on the operating table under general or locoregional anaesthesia (Fig 1). A well-padded high-thigh 300-mmHg

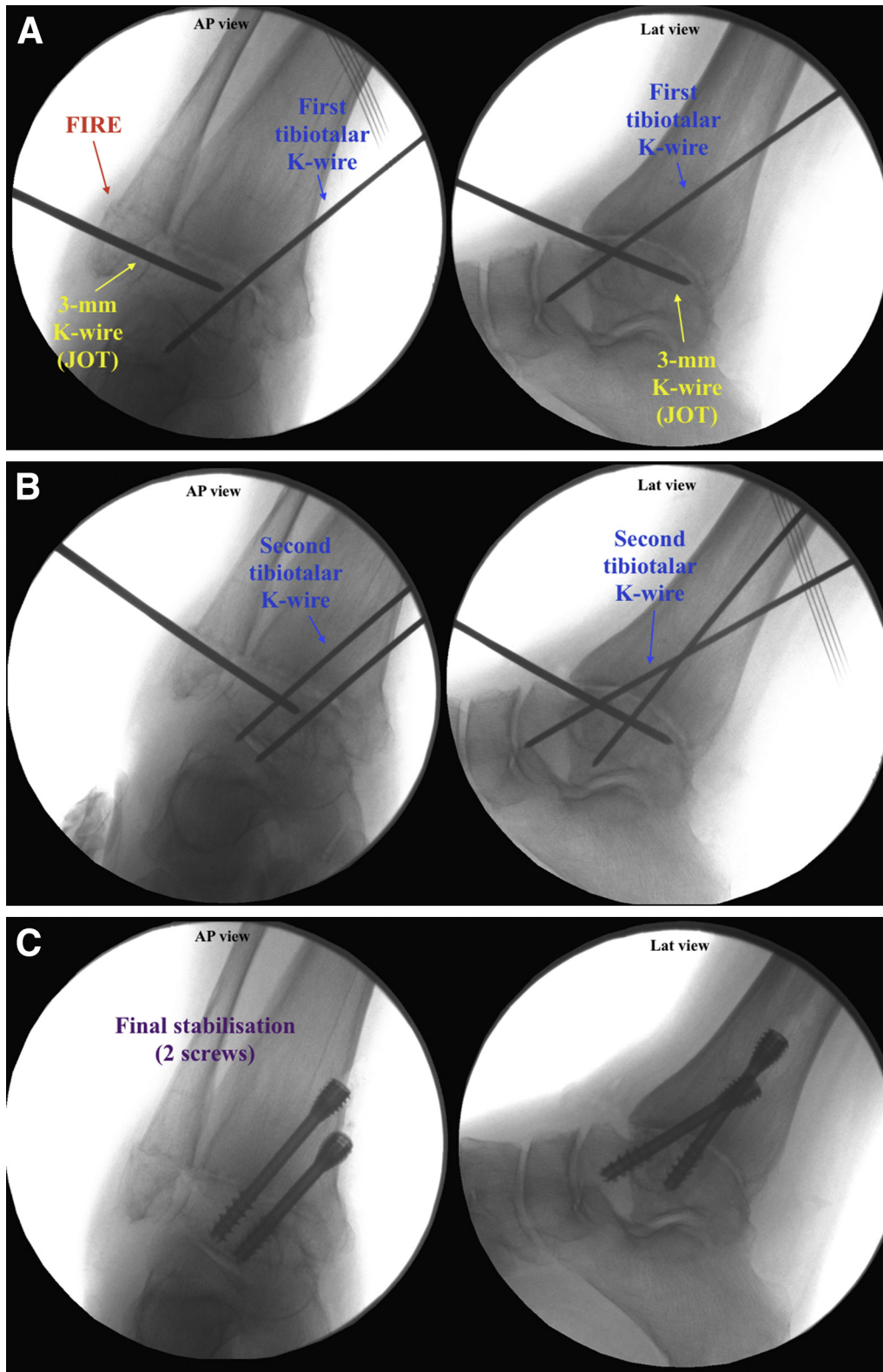
tourniquet is inflated, and the knee is slightly flexed (around 20°) by applying a support under the popliteal cavus (Video 1).

### Arthroscopic Technique

The skin projection of the joint line is found out by repetitive flexion-extension movements of the ankle. Skin landmarks are identified such as the medial malleolus, the tibialis anterior tendon, the extensor digitorum longus tendon (EDL), and the lateral malleolus (Fig 1). At this level, a needle is placed medially to the tibialis anterior tendon, and 5 to 10 mL of 0.9% saline solution is injected to verify the needle position as the elastic refilling of the syringe corresponds to the passive capsular retensioning, confirming the correct needle position. If possible, the superficial peroneal nerve should also be marked on the skin and avoided. The portals should be positioned slightly distally to this joint line to take into account the curvature of talus and to avoid being ill exposed for freshening the anterior part of the tibial plafond.



**Fig 2.** Arthroscopic arthrodesis of a right ankle in a patient with severe post-traumatic varus tibiotalar arthritis. The patient is placed in the dorsal position. The image shows some phases of the joystick of the talus technique. In the upper inset (A), the pin is progressed through the talus into the opposing cortex, taking care not to pierce through and behind the medial malleolus to preserve the posterior tibial neurovascular bundle. In the main image (B), the reduction maneuver is performed through a combined solid derotation of the talus along with a correction of the coronal plane using the K-wire in the left hand, while at the same time pushing under the sole of the foot with the abdomen to ensure plantigrade position. The right hand serves to follow arthroscopically the pin insertion (as shown in the lower inset) (C).



**Fig 3.** Arthroscopic arthrodesis of a right ankle in a patient with severe post-traumatic varus tibiotalar arthritis. The patient is placed in the dorsal position. After a careful freshening of the articular surfaces, the fibular intra-articular resection (FIRE) facilitates the ascension of the talus under the tibia. To perform the joystick of the talus technique, a 3-mm K-wire is introduced in the talus through the lateral portal under optical control from the medial portal and scopically checked (A). After derotation of the talus within the mortise and keeping the foot in neutral dorsiflexion, 5° of valgus and 10° of external rotation, 2 K-wires are introduced in parallel (or almost parallel) configuration on the medial distal aspect of the tibia. Their direction is from medial to lateral, proximal to distal, and posterior to anterior (B). Two cannulated compression percutaneous screws (AutoFix 6.5-mm compression screws) are used to fix the arthrodesis, taking care to completely insert the distal threads into the talus (C).

**Table 1.** Indications and Contraindications for Arthroscopic Ankle Arthrodesis with Joystick of the Talus (JOT)

Indications	Contraindications
Malaligned (correctable) ankle arthritis <ul style="list-style-type: none"> <li>• Idiopathic</li> <li>• Secondary</li> <li>• Post-traumatic</li> <li>• Related to arthritic systemic conditions</li> <li>• Ankle instability</li> <li>• Neurological conditions</li> </ul>	Stiff malalignment Large bone defects Active infection Revision of previous no union or arthroplasty requiring autologous grafting

A 5-mm incision corresponding to the anteromedial portal (AMP) is placed where the needle was, blunt dissection is performed, and the arthroscopic cannula introduced. The introducer is then removed, and a 4.0-mm 30° arthroscope (Dyonics, Smith and Nephew, Andover, MA) is positioned (hydraulic pump at 50 mmHg pressure). By means of transillumination (outside-in technique) the anterolateral portal (ALP) is placed through a 5-mm incision somewhere medial to the lateral malleolus and lateral to the EDL. A careful synovectomy and debridement of the anterior fibrous scar tissue are performed using a synovial resector (Dyonics), and then the inside of the joint is well visualized and examined (Video 1).

Thereafter, a 4-mm burr is inserted to freshen the joint surfaces of the tibia and the talus, including the gutters, moving from anterior to posterior and vice versa. When progression in the posterior joint is difficult, it is likely that some anterior osteophytes had been missed, their excision being required to carry out the procedure correctly. A curved curette or a microfracture tool can be used to better expose the subchondral bone. Once articular surfaces look completely freshened, exchanging instruments in portals may be useful to freshen zones not accessible with the burr in the ALP. A fibular intra-articular resection is then performed, according to the previously described technique.<sup>8,9</sup> At the end of the procedure, the tourniquet is deflated to appreciate a consistent trabecular bone bleeding and to rule out any major vascular injuries. Bone grafting is never used. Skin portals are sutured.

### Talar Realignment Using the Joystick of the Talus Technique (JOT)

A 3-mm K-wire is introduced in the talus through the ALP under optical control from the AMP (Fig 2). In case of varus deformity and internal rotation of the talus, the pin is introduced as anteriorly as possible on the lateral aspect of the talar neck. Its position in the coronal plane is parallel to the talar dome or aiming proximal to obtain maximum reduction power. In patients with valgus deformity and the talus externally rotated, the pin is positioned as far posteriorly as possible considering the limitation due to the fibula. In the coronal plane, the

**Table 2.** Advantages and Disadvantages of Arthroscopic Ankle Arthrodesis with Joystick of the Talus (JOT)

Advantages	Disadvantages
Arthroscopy versus open: <ul style="list-style-type: none"> <li>• Decreased postoperative pain and edema</li> <li>• Shorter hospital stays</li> <li>• Fewer complications</li> <li>• Reduced time to union</li> </ul>	Arthroscopic skills required Grafting not allowed Contraindicated in stiff malalignment
JOT versus no JOT <ul style="list-style-type: none"> <li>• Varus/valgus malalignment addressed</li> <li>• Full tibiotalar contact</li> </ul>	

K-wire should be positioned parallel to the talar dome or aiming plantarly. The pin is progressed through the talus, taking care not to violate the posteromedial cortex of the talus, avoiding injury of the posterior tibial neurovascular bundle (Fig 3). For a right-handed operator, the reduction manoeuvre is represented by a derotation of the talus along with a correction of the coronal plane using the K-wire in the left hand, while at the same time pushing under the sole of the foot with the abdomen to ensure plantigrade position (Fig 2). The right hand serves to insert the guide pins during fixation. It is of paramount importance to feel the derotation of the talus within the mortise as this gesture enables the most powerful correction.

### Fixation of the Arthrodesis

Keeping the foot in neutral dorsiflexion, 5° of valgus and 10° of external rotation, 2 K-wires are introduced in parallel (or almost parallel) configuration on the medial distal aspect of the tibia (the second wire entry point placed 1 cm proximal and 0 to 1 cm anterior to the first). Their orientation is from medial to lateral, proximal to distal, and posterior to anterior (Fig 3).

**Table 3.** Pearls and Pitfalls of Arthroscopic Ankle Arthrodesis (AAA) with Joystick of the Talus (JOT)

Pearls
Traditional portals are placed on the joint line; despite this, the incisions should be slightly distal to this line to help visualize and debride the articular surfaces.
JOT technique allows performance of AAA in malaligned arthritis, as long as correctable.
The reduction of the deformity must be checked preoperatively, and the patient must be aware of a possible conversion to open surgery.
It is paramount to feel the derotation of the talus within the mortise.
Joining a fibular resection and JOT technique enables the most powerful correction of the preoperative deformity.
Pitfalls
Due to the subtalar joint curvature, a curette must be used to complete debridement.
There is risk of lesion of the posterior tibial neurovascular bundle when placing the 3-mm pin for performing JOT; caution and scopic control are recommended.

If an aide is available, the pins may be preintroduced only in the tibia, checking their orientation under fluoroscopy. In this scenario, both of the surgeon's hands can be available for the reduction maneuver, and the assistant can progress the prepositioned wires, fixing the talus in place once reduction has been obtained. Two cannulated interfragmental compression percutaneous screws (AutoFix 6.5-mm compression screws, Stryker, Mahwah, NJ) are used to fix the arthrodesis, taking care to completely insert the distal threads into the talus (Video 1). Every step is performed and checked under fluoroscopy. Skin portals are then closed.

### Postoperative Protocol

Patient is immobilized in a non-weight-bearing 3-week cast, and walking is allowed using crutches. The patient is discharged the day after surgery. After 3 weeks, a progressive weight-bearing protocol is allowed, initially in a swimming pool. Full weight bearing is allowed after this period, and a weight-bearing cone beam computed tomography assessment is performed to verify the quality of bone healing and the weight-bearing alignment. Full activity recovery generally occurs between 3 and 6 months.

### Discussion

AAA has been widely proven as an efficient way to treat ankle arthritis, providing lasting results even at long-term follow-up,<sup>2,10</sup> but the presence of a hindfoot malalignment has commonly represented one of the limitations to the arthroscopy.<sup>3,4</sup> The JOT technique performed during AAA addresses this issue, obtaining a correct alignment of the hindfoot and a full intra-articular contact also in valgus and varus ankles deformities, while retaining the advantages of an arthroscopic procedure (Tables 1-3).

As mentioned, some investigators have tried to go over the classical concept of joint malalignment as a contraindication for arthroscopy.<sup>5,6</sup> Winson et al.<sup>5</sup> and Dannawi et al.,<sup>6</sup> when describing arthroscopic fusions in malaligned ankles, have generically indicated an external controlled pressure applied to the plantar surface before and during fixation for obtaining a good foot position. However, so far, no one has specifically focused attention on the way to reach a satisfying reduction of the coronal deformity of the tibiotalar joint. As described in other studies, a force applied under the foot and directed upward may certainly help in compressing the talus and the tibia, this being necessarily performed in all arthroscopic fusion procedures.<sup>2</sup> Conversely, the mechanical transmission of a rotational force (against the coronal deformity) applied under the foot upward might be obstructed by the presence of soft tissues and the subtalar joint motion, resulting in insufficient capacity to properly control the talar overall alignment. Furthermore, the rotation of

the talus has been proven crucial in ankle fusion as a persistent talar tilt might promote hindfoot destabilization and the development of peritalar instability.<sup>7</sup> Interestingly, the JOT application allows the direct rotation of the talar bone, giving direct control of a correct positioning of the hindfoot. As per the technique described above, particular care must be taken in determining the K-wire lateral bone entry point as a mistake at this stage may decrease the mechanical efficacy of the maneuver for correcting the deformity. Furthermore, when positioning the K-wire, the risk of damage to the tibialis posterior neurovascular bundle on the opposite side of the talus must be always considered. However, a controlled progression under image intensifier may represent the safest way to implant this "joystick" without complications. Obviously, this technique shares the same absolute contraindications as AAA, such as important bone defects requiring grafting and active infections. Beyond these contraindications, its only specific limit is represented by an excessive stiffness of soft tissues, making impossible any reduction. For this reason, the presence of a correctible deformity must be checked prior to the operation, through a combination of clinical examination prior to and under general anesthesia, stress radiographs, and/or intraoperative fluoroscopy. Furthermore, the patient presenting a with coronal ankle malalignment and who is candidate for the arthroscopic procedure should be made aware that the fusion will be carried out arthroscopically unless the deformity appears uncorrectable, in which case a conversion to open surgery will be required.

In conclusion, the JOT technique during AAA might usefully contribute to obtaining a physiological tibiotalar realignment in malaligned correctible ankle arthritis. This probably represents a stepping stone on the path to a further diffusion of the arthroscopic technique and to reducing complications related to the open surgery even in severe but flexible varus or valgus end-stage arthritis.

### References

1. Schneider DA. Arthroscopic ankle fusion. *Arthrosc Video J* 1983;3:35-47.
2. Park JH, Kim HJ, Suh DH, et al. Arthroscopic versus open ankle arthrodesis: a systematic review. *Arthroscopy* 2018;34:988-997.
3. Glick JM, Morgan CD, Myerson MS, Sampson TG, Mann JA. Ankle arthrodesis using an arthroscopic method: long-term follow-up of 34 cases. *Arthroscopy* 1996;12:428-434.
4. O'Brien TS, Hart TS, Shereff MJ, Stone J, Johnson J. Open versus arthroscopic ankle arthrodesis: a comparative study. *Foot Ankle Int* 1999;20:368-374.
5. Winson IG, Robinson DE, Allen PE. Arthroscopic ankle arthrodesis. *J Bone Joint Surg Br* 2005;87:343-347.
6. Dannawi Z, Nawabi DH, Patel A, Leong JJ, Moore DJ. Arthroscopic ankle arthrodesis: are results reproducible

- irrespective of pre-operative deformity? *Foot Ankle Surg* 2011;17:294-299.
7. Colin F, Zwicky L, Barg A, Hintermann B. Peritalar instability after tibiotalar fusion for valgus unstable ankle in stage IV adult acquired flatfoot deformity: case series. *Foot Ankle Int* 2013;34:1677-1682.
  8. Bernasconi A, Mehdi N, Lintz F. Fibular intra-articular resection during arthroscopic ankle arthrodesis: the surgical technique. *Arthrosc Tech* 2017;6:e1865-e1870.
  9. Mehdi N, Bernasconi A, Laborde J, Lintz F. An original fibular shortening osteotomy technique in tibiotalar arthrodesis. *Orthop Traumatol Surg Res* 2017;103:717-720.
  10. Yasui Y, Hannon CP, Seow D, Kennedy JG. Ankle arthrodesis: a systematic approach and review of the literature. *World J Orthop* 2016;7:700-708.