

Evaluation of Fat Excision versus Sparing in Lower Blepharoplasty Using Orbital Gray Scale Analysis

Adnan Gamal Etman, MSc
 Mohamed Samir Badawy, MD
 Hany Saad Setta, MD
 Amr Magdy, MD
 Ahmed EL-badawy, MD

Background: Orbital septum plication provides various benefits, including eliminating the necessity for a septal incision and the ability to relocate infraorbital fat in a more anatomically suitable manner. This study aimed to compare the results of traditional lower blepharoplasty with fat excision and the orbital septal plication method using orbital grey scale analysis as a new objective method for assessment.

Methods: We conducted a prospective cohort study on patients with bilateral baggy lower eyelids who underwent traditional lower blepharoplasty with fat excision or fat-sparing technique using orbital septal plication. All patients were followed up closely for 1 week and then after 1, 3, and 6 months postoperatively to evaluate the study's outcomes.

Results: The study was conducted using 40 patients (20 patients per group). The total (medial, central, and lateral) orbital grey scale analysis showed a significant reduction in the fat-sparing and traditional groups ($P < 0.001$, each). However, the percentage of reduction was significantly higher in the fat-sparing group (34.6 ± 2.9 versus 15.5 ± 3.3 in the traditional groups; $P < 0.001$).

Conclusions: The application of the fat-sparing technique is associated with favorable cosmetic outcomes and a lower complication rate than those of the traditional technique with fat excision. Further studies with a longer duration of follow-up and a larger sample size are required to estimate the risk of recurrence and the need for a revision procedure. (*Plast Reconstr Surg Glob Open* 2022;10:e4530; doi: 10.1097/GOX.0000000000004530; Published online 30 September 2022.)

INTRODUCTION

Lower blepharoplasty has two current trends: a conservative strategy to reduce postoperative complications and an aggressive approach to maximize the cosmetic outcome.¹ For the past few decades, excision of herniated fat has been the primary concept and conventional procedure for classic lower blepharoplasty, and many surgeons still utilize this technique.^{2,3} On the other hand, contour abnormalities, hematomas, and abnormally sunken eyelids were reported as lower blepharoplasty disadvantages. Excessive fat removal creates undesired concavity of the lower eyelid, which is more noticeable due to the aged cheek's greater convexity.⁴

Fat herniation is caused by structural deterioration that occurs because of the aging process. As a result, the treatment of this hernia is comparable to the repair of

abdominal hernias by the structural strengthening of the septum.⁵ Therefore, the septal plication provides various benefits, including eliminating the necessity for a septal incision and the ability to relocate infraorbital fat in a more anatomically suitable manner, which may be useful in subsequent operations such as tear-trough deformity repair.⁶

De la Plaza presented the concept of fat preservation in the 1980s,⁷ and subsequently, in the 1990s, the septal reset technique was discussed in more detail by Mendelson and Hamra.^{8,9} Septal reset involves mobilizing and changing the position of the fat bag to correct abnormalities, such as lower orbital rim skeletonization, tear-trough deformity, and nasojugal grooves. The fat repositioning technique, introduced by Goldberg in 2000,¹⁰ aims to relocate the fat bag to its normal youthful position in the orbit, by repositioning fat into the subperiosteal pocket. Furthermore, Huang stated in 2000 that the fat pad volume in aging eyelids remained unchanged, and that attenuation of the orbital septum is the primary cause of a bulging deformation.¹¹

To estimate the severity of lower eyelid aging and postoperative results, many studies applied global assessments.

From the Plastic, Burn, and Maxillofacial Surgery Department, Ain Shams University, Cairo, Egypt.

Received for publication April 23, 2022; accepted July 27, 2022.

Copyright © 2022 The Authors. Published by Wolters Kluwer Health, Inc. on behalf of The American Society of Plastic Surgeons. This is an open-access article distributed under the terms of the Creative Commons Attribution-Non Commercial-No Derivatives License 4.0 (CCBY-NC-ND), where it is permissible to download and share the work provided it is properly cited. The work cannot be changed in any way or used commercially without permission from the journal.

DOI: 10.1097/GOX.0000000000004530

Disclosure: The authors have no financial interest to declare in relation to the content of this article. The authors received no financial support for the research, authorship, and publication of this article.

They are simple and easy to use, but they are subjective tools with significant inter-and intra-evaluator variability.¹²⁻¹⁴ Jo et al introduced orbital gray scale (OGS) analysis as a novel and reliable image analysis method for classification and severity assessment of baggy eyelids and to evaluate the treatment outcome.¹⁵

The junction between the lower eyelid and cheek shows a smooth and uniform continuum in a youthful appearance; herniation of the infraorbital fat pads exaggerates baggy infraorbital folds such as the nasojugal fold and palpebromalar groove. As baggy lower eyelids accompany visible baggy infraorbital folds, Jo et al evaluated the severity of the baggy eyelid using the linear gray scale analysis of the fold, which was useful for evaluating the severity of nasolabial wrinkles.^{15,16} This study aimed to compare the results of traditional lower blepharoplasty with fat excision and fat-sparing technique using the orbital septal plication method without an incision to the orbital septum using OGS as an objective method for assessment.

METHODS

The current study gained ethical clearance from the institutional review board and was planned per the recommendations of the STROBE guidelines.¹⁷ We confirm that none of the study's procedures violated the main principles of the Declaration of Helsinki.¹⁸ All patients signed the written informed consent before enrollment.

Study Design and Patients

We conducted a prospective comparative study that recruited patients with bilateral baggy lower eyelids who were scheduled to undergo lower blepharoplasty at Ain Shams University Educational hospitals through the period from July 2019 to January 2021. We excluded pediatric patients, patients with a history of lower eyelids surgery, traumatic eyelids, Bell's palsy, and/or combined conditions. Eligible patients were divided randomly between both groups and allocated in a 1:1 ratio to receive traditional lower blepharoplasty with fat excision or fat-sparing technique using the septal plication method.

Surgical Techniques

All patients were assessed preoperatively, snap-back and lateral canthal laxity tests were done, and patients were evaluated for tear-trough deformity and degree of scleral show. Informed consent was obtained from all patients, which included photography, operative details, potential risks, and complications such as anesthesia complications, edema, ecchymosis, asymmetry, under or overcorrection, scleral show, and ectropion.

Preoperative standardized digital photographs of each patient were taken in the same environment, including lighting and composition using a Nikon digital camera canon power shot (SX50HS). Preoperative OGS analysis was done using frontal-view photographs.

Intraoperatively, patients underwent general anesthesia. The transcutaneous skin-muscle flap approach was used in our entire cohort of patients, where we started with subciliary incision, 1 to 2 mm below the eyelash line,

Takeaways

Question: What will we find when we compare the results of traditional lower blepharoplasty with fat excision and fat-sparing with the orbital septal plication method using orbital gray scale analysis as a new objective method for assessment.

Findings: The postoperative reduction percentage in total orbital gray scale score was significantly higher in the fat-sparing group.

Meaning: The application of the fat-sparing technique with orbital septum plication is associated with favorable cosmetic outcomes and a lower complication rate than the traditional technique with fat excision.

followed by raising the skin flaps nearly 6 mm below the lid margins. The orbicularis oculi muscle was split to expose the retro muscular space, the capsulopalpebral fascia, and the inferior orbital rim. In the fat-sparing group, our used technique was and has remained as that of de la Plaza, in which herniated fat is returned to the orbital cavity and the capsulopalpebral fascia is sutured to the arcus marginalis (the confluence of the periosteum and the orbital septum) of the inferior orbital rim, using interrupted sutures (5-0 nonabsorbable monofilament sutures) instead of running closure as a modification and without incision of the orbital septum and with the placement of each suture, the position of the lid margin was checked to avoid any downward traction (Figs. 1 and 2). In the traditional group, excess orbital fat was removed with fine forceps and then resected with fine-tip insulated electrocautery. In all patients, muscle suspension is carried out by suturing the preseptal orbicularis muscle (attached to the lower skin flap) to the inferior aspect of the periosteum of the lateral orbital rim with a single stitch of 5-0 monofilament suture. Finally, any excess skin was removed, and wound margins were closed with interrupted 6-0 nonabsorbable monofilament sutures. All patients were followed up closely for 1 week and then after 1, 3, and 6 months postoperatively to evaluate the study's outcomes.

Study Outcomes

The primary outcome of the present study was the assessment and comparing of preoperative and 6 months postoperative OGS analysis of frontal-view photographs (using the ImageJ software; <https://imagej.nih.gov/ij/index.html>). The photographs were formatted as digital JPEGs of 8-bit RGB and size 2152 × 2740 pixels. An image segment of size 500 × 500 pixels containing the infraorbital folds was retrieved from the original photograph for each patient. Among various abilities of ImageJ software, the gray value measurement was utilized for the evaluation of brightness. It returns 0 for pure black and 255 for pure white. Because there are varieties of artifacts on the face, such as facial pores, pigmented skin lesions, and skin creases, the gray values of the cheek and lower eyelid were averaged by applying the mean filter on each area. We drew lines from the cheek to the lower eyelid that perpendicularly crossed the medial, central, and lateral

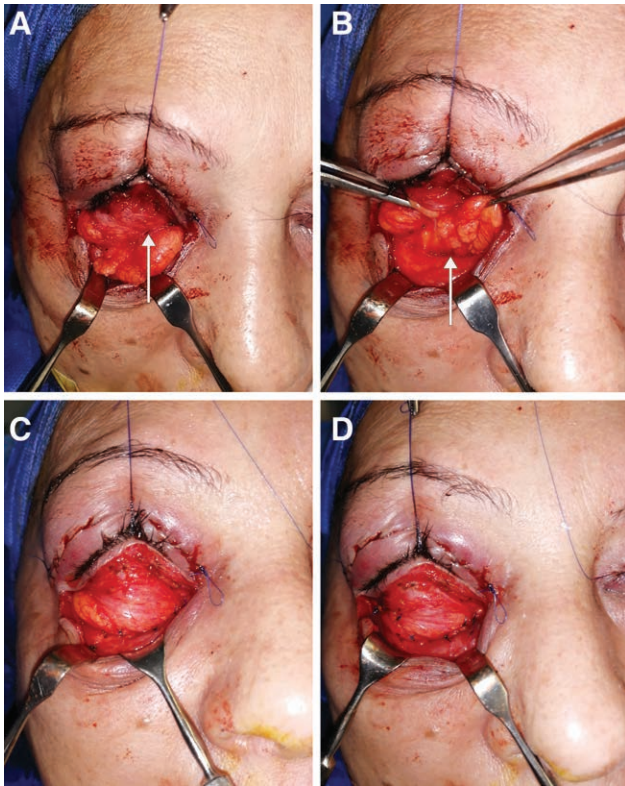


Fig. 1. Intraoperative photographs showing the amount of herniated fat in the right lower eyelid of a 53-year-old woman. (A) Lower part of capsulopalpebral fascia indicated by an arrow. (B) Arcus marginalis indicated by an arrow. (C) Repair of the fatty hernia with the approximation of the capsulopalpebral fascia and the arcus marginalis with interrupted 5-0 nonabsorbable monofilament sutures; the lateral compartment has not yet been closed. (D) After repositioning of herniated fat in the orbital cavity and orbital septal plication.

parts of the infraorbital folds (Fig. 3). Then, we used the plot profile option along each line, which displays a two-dimensional graph of the intensities of pixels along a line within the image (Fig. 3). The x-axis represents distance along the line, and the y-axis is the pixel intensity. The gray values were measured along the line. Because the pixels on the infraorbital folds were expected to have lower gray values, the infraorbital folds would appear as a dip in the graph of gray values plotted along the line (Fig. 3).

Hence, if we assign the higher grey value of the averaged cheek and lower eyelid as the surrounding gray value, the OGS is defined as the following formulas:

Surrounding gray value = max (average cheek gray value, average lower eyelid gray value)

OGS value = (surrounding gray value – lowest gray value in the dip)

Theoretically, OGS could be 0 for the minimum, and 255 for the maximum.

In each subject, we measured the medial, central, and lateral orbital grayscale values from the medial, mid, and lateral parts of the baggy infraorbital fold, respectively (Fig. 3). Besides, we assessed the patient satisfaction 6 months postoperatively through a single question/answer and ranked them as good, fair, or poor.

Statistical Analysis

The statistical software SPSS (IBM SPSS Statistics for Windows, version 24.0; IBM Corp, Armonk, N.Y.) was used for data processing and analysis. According to the normality of data distribution, the central tendency and variability of the numerical data were presented in the form of mean \pm SDs (SD) or median with interquartile range (IQR). Frequency counts and percentages summarized

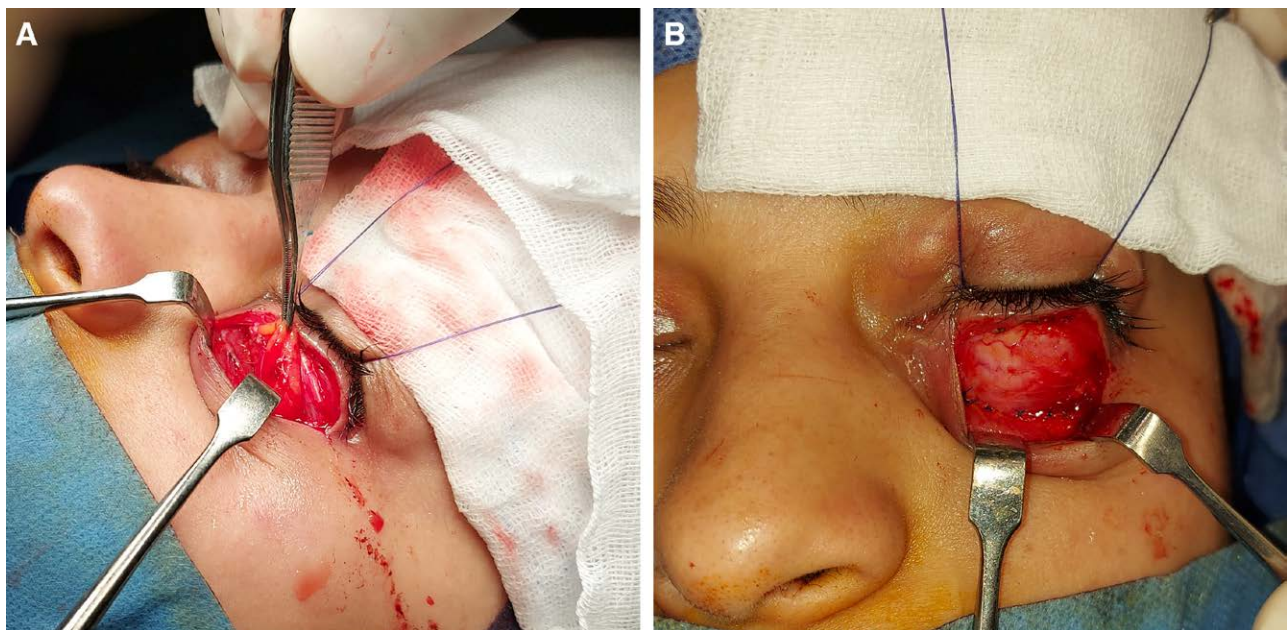


Fig. 2. Intraoperative photographs showing the amount of herniated fat in the left eye of a 24-year-old woman before (A) and after (B) plication of the orbital septum with the approximation of the capsulopalpebral fascia and the arcus marginalis with interrupted 5-0 nonabsorbable monofilament sutures.

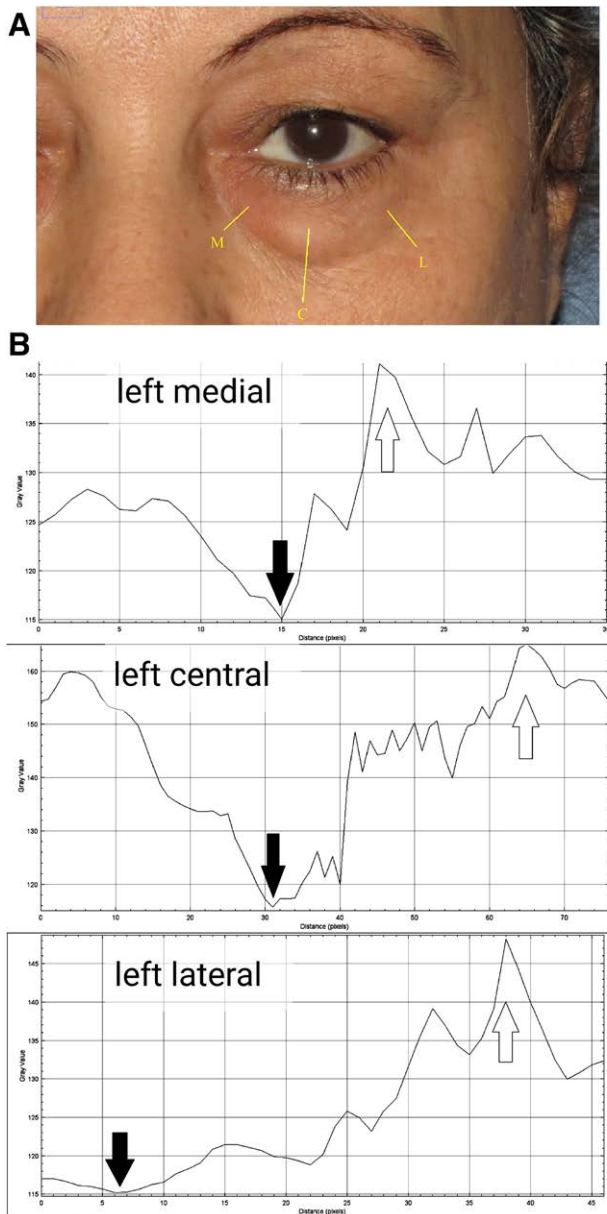


Fig. 3. After applying the mean filter to the lower eyelid and cheek, lines were drawn crossing the medial (line M), central (line C), and lateral (line L) parts of the infraorbital fold (A). The gray scale values were measured along with lines M, C, and L, and the differences between the average surrounding gray scale values (white arrows) and the lowest dip values (black arrows) were calculated as medial, central, and lateral orbital grey scale values, respectively (B).

categorical variables. The hypothesis of significant association between the surgical technique and other variables was tested using the Mann-Whitney test and the chi-square test, with Fisher exact correction when needed. A *P* value less than 0.05 was regarded as statistically significant.

RESULTS

The study was conducted using 40 patients (20 patients per group). The mean age of the included patients was 44.9 ± 9.2 and 42.5 ± 10.9 years old in fat-sparing and

traditional groups respectively ($P = 0.44$), with female predominance ($P = 0.72$).

The right medial OGS showed a significant reduction in both fat-sparing and traditional groups ($P < 0.001$, each). However, the percentage of reduction was higher in the fat-sparing group than in the traditional group (35.8 ± 2.8 in fat-sparing versus 14.6 ± 3.4 in traditional groups; $P < 0.001$). Similarly, the left medial OGS showed a notable decrease in both groups ($P < 0.001$, each). The percentage of reduction was also higher in the fat-sparing group (35.9 ± 2.9 in the fat-sparing group versus 14.7 ± 3.3 in the traditional group; $P < 0.001$) (Fig. 4).

Regarding the central OGS, the left and right sides demonstrated a considerable reduction in the fat-sparing and traditional groups ($P < 0.001$, each). The percentage of reduction was again higher in the fat-sparing group ($P < 0.001$, each) (Fig. 5).

While regarding the lateral OGS, the right and left OGS showed a considerable reduction in the fat-sparing and traditional groups ($P < 0.001$, each). For the right lateral OGS, the percentage of reduction was higher in the fat-sparing group (32.6 ± 2.4 fat-sparing versus 17.8 ± 1.6 in the traditional groups; $P < 0.001$). Likewise, the left lateral OGS showed a decrease in the fat-sparing and traditional groups ($P < 0.001$, each) with a higher percentage of reduction in the fat-sparing group (33.1 ± 2.1 fat-sparing versus 17.8 ± 1.5 in the traditional groups; $P < 0.001$) (Fig. 6).

Overall, the total OGS score showed a significant reduction postoperatively. Particularly, the fat-sparing group showed a higher reduction percentage than the traditional groups postoperatively (34.6 ± 2.9 in fat-sparing versus 15.5 ± 3.3 in traditional groups; $P < 0.001$), as shown in Table 1.

The intraoperative time was significantly shorter in the fat-sparing group (72.5 ± 7.2 versus 109.2 ± 5.8 minutes in the traditional groups; $P < 0.001$). Likewise, the duration of postoperative edema and ecchymosis was significantly shorter in the fat-sparing than in the traditional groups ($P < 0.001$, each). On the contrary, Postoperative lid retraction was nonsignificantly less frequent in the fat-sparing group ($P = 0.41$). Complete improvement in cases with postoperative lid retraction nonsignificantly occurred only in the fat-sparing group. Postoperative sunken eye was nonsignificantly absent in the fat-sparing group ($P = 0.487$), as shown in Table 2.

The satisfaction grades were significantly higher among the fat-sparing group. (Fig. 7). Figure 8 shows preoperative and postoperative frontal-view photographs of a case who underwent lower blepharoplasty using fat-sparing technique with plication of the orbital septum. (Fig. 8). Preoperative and postoperative frontal-view photographs of a case who underwent traditional lower blepharoplasty with excision of herniated orbital fat are shown in Fig. 9.

DISCUSSION

Lower eyelid blepharoplasty has continued to evolve over the previous many decades. A variety of techniques have been designed and documented to improve the aesthetic outcome while reducing postoperative

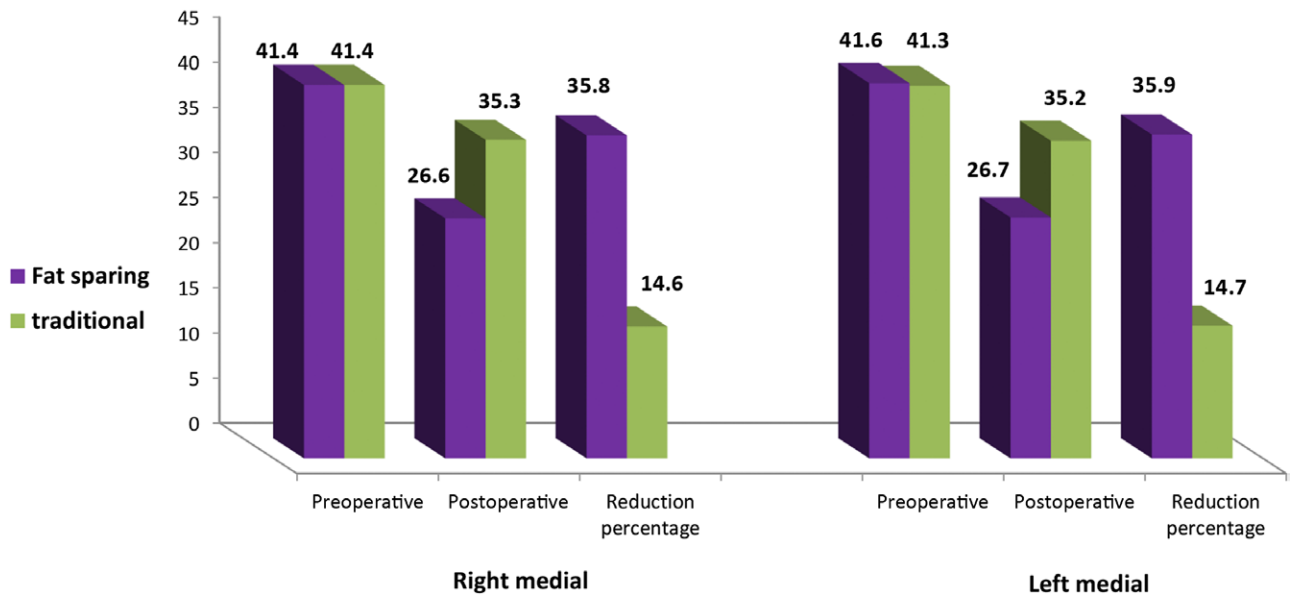


Fig. 4. Comparison between the fat-sparing group who underwent orbital septal plication and the traditional group who underwent orbital fat excision as regards preoperative, postoperative, and reduction percentage in medial OGS values on both the right and the left side.

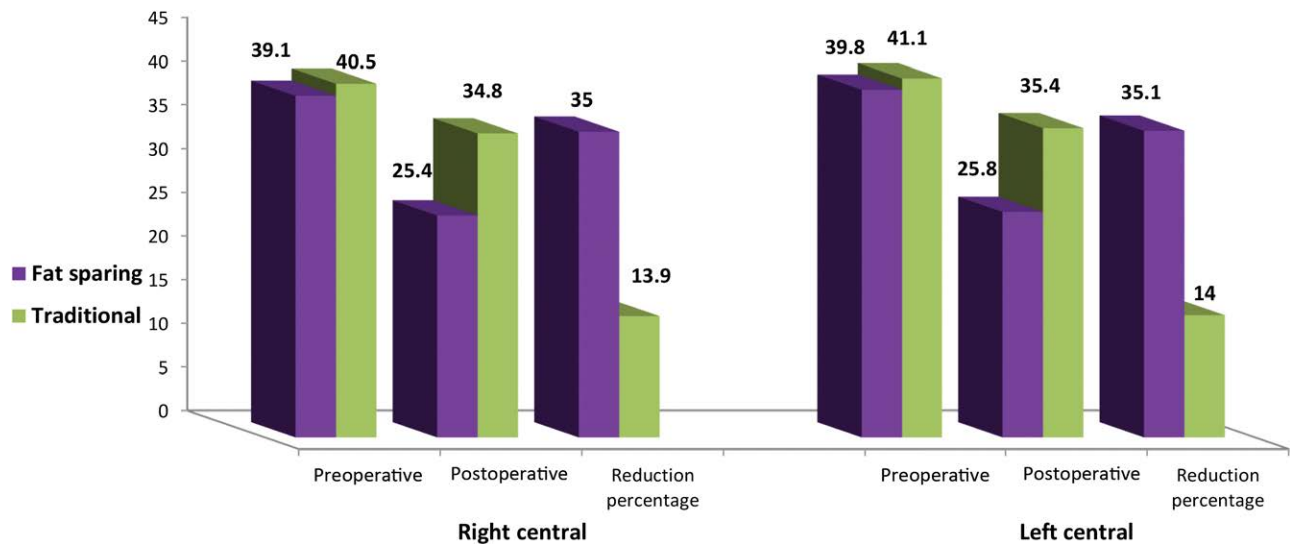


Fig. 5. Comparison between the fat-sparing group who underwent orbital septal plication and the traditional group who underwent orbital fat excision as regards preoperative, postoperative, and reduction percentage in central OGS values on both the right and the left side.

complications. To that end, surgeons are still debating access incisions, orbital fat management, and lateral canthal manipulation.^{19–22}

For many years, the usual procedure for lower blepharoplasty has been the excision of herniated fat from the lower lid through various incisions. The goal of this procedure was to eliminate the fat pad bulge that occurs as a result of aging. It is a straightforward method that yields acceptable outcomes. When indicated, the procedure has strong supporters and can be a feasible option.²³

Fat removal, on the other hand, does not address the anatomic causes of lower lid aging and might result in an

exaggerated hollowed or sunken appearance, as well as scleral show due to skin scarcity, cicatricial shortening, or tethering of the middle lamella or septum.^{23,24}

Orbital fat is considered crucial, and several studies recommend preserving it.^{7,8,24–32} It is redraped to correct some contour deformities such as lower orbital rim skeletonization, tear-trough deformity, and nasojugal groove.^{24,26,33} Although these techniques produce good outcomes and aid in periorbital rejuvenation, they compromise the normal anatomy of the lower eyelid. The anatomy of the lower lid and periorbital area has been extensively researched. Structures such as skin, orbicularis

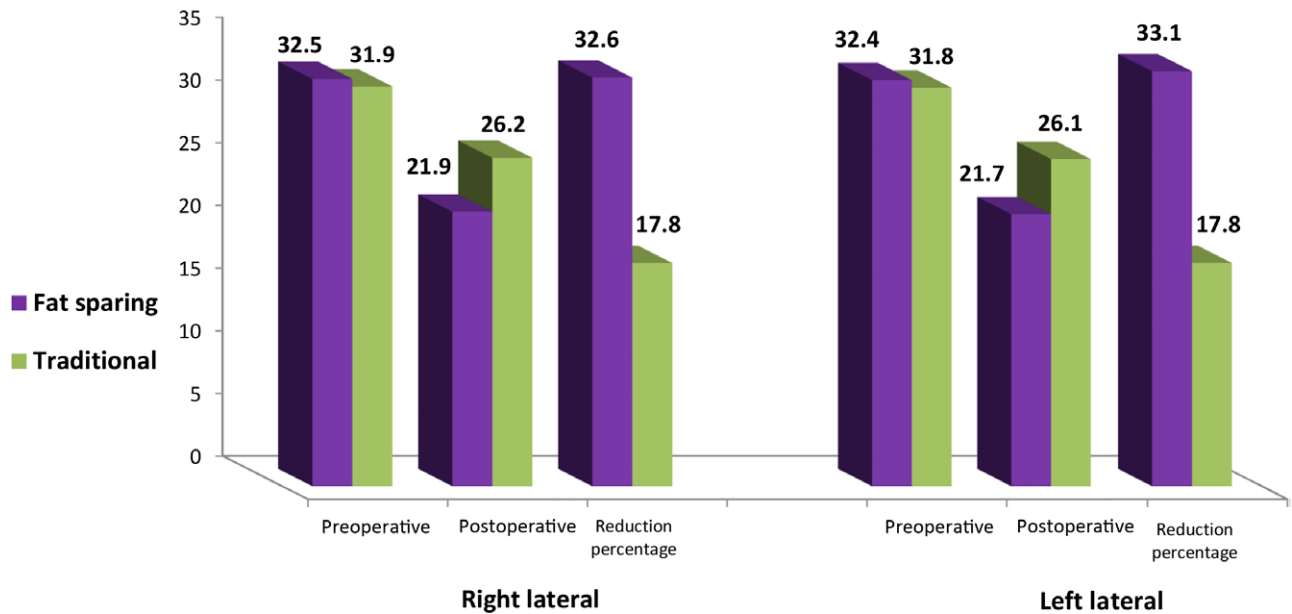


Fig. 6. Comparison between the fat-sparing group who underwent orbital septal plication and the traditional group who underwent orbital fat excision as regards preoperative, postoperative, and reduction percentage in lateral OGS values on both the right and the left side.

Table 1. Total Orbital Gray Scale Score

Time	Measures	Fat-sparing (N = 120)	Traditional (N = 120)	P Value* (Groups)	Relative Effect,
					Mean ± SE 95% CI
Preoperative	Mean ± SD	37.8±4.8	38.0±5.0	0.810	-0.2±0.6
	Range	26.1–46.8	27.7–47.9		-1.4–1.1
Postoperative	Mean ± SD	24.7±2.9	32.2±4.9	<0.001†	-7.5±0.5
	Range	18.0–30.4	22.7–42.1		-8.5–6.5
Reduction percentage	Mean ± SD	34.6±2.9	15.5±3.3	<0.001†	19.1±0.4
	Range	28.6–44.7	7.5–21.8		18.3–19.9

‡P value (times)

*Independent t-test (comparing groups).

†Significant. Relative effect: value of fat-sparing relative to traditional.

‡Paired t-test (comparison pre and postoperative). CI: Confidence interval.

Table 2. Operation Time and Rate of Postoperative Complications in Both Techniques

Measures		Fat-sparing (N = 20)	Traditional (N = 20)	P Value
		Mean ± SD	Mean ± SD	
Operation time (min)	Mean ± SD	72.5±7.2	109.2±5.8	<0.001*
	Range	63.0–86.0	97.0–117.0	
Duration (d) of postoperative edema	Mean ± SD	11.5±1.4	16.3±2.0	<0.001*
	Range	9.0–14.0	13.0–20.0	
Duration (d) of postoperative ecchymosis	Mean ± SD	7.6±1.6	12.5±2.1	<0.001*
	Range	5.0–11.0	10.0–17.0	
Sunken eye	Present	0 (0.0%)	2 (10.0%)	0.487
	Absent	20 (100.0%)	18 (90.0%)	
Lid retraction	Present	2 (10.0%)	5 (25.0%)	0.407
	Absent	18 (90.0%)	15 (75.0%)	
Improvement of lid retraction within 6 months follow-up	Complete	2 (100.0%)	3 (60.0%)	0.99
	Partial	0 (0.0%)	2 (40.0%)	

*Significant. Relative effect: value of fat-sparing relative to traditional. Independent t-test. CI: Confidence interval.

muscle, orbital septum, Lockwood ligament, and lateral canthus may have a role in the pathogenesis of the lower lid bulge.^{34–36} Changes in these structures can cause the orbital fat to migrate outside the orbital cavity, giving the appearance of “fat herniation.” Many authors have attempted to reverse this aging mechanism by strengthening supporting structures and relocating orbital fat into the orbital cavity, resulting in more anatomic alternatives for the treatment of the lower lid bulge.^{26,27}

As the treatment options for baggy lower eyelids become increasingly varied, each approach is being tested in specific scenarios.³⁷ Barton et al, for example, developed a three-point grading scale to assess their own surgical method.³⁸ Most surgeons, on the other hand, evaluate their surgical outcomes only on the basis of patient satisfaction or a basic grading system based on “improvement” and “deterioration” assessments.^{39–43} Despite the fact that numerous surgeons have tried to evaluate their

own procedures using various assessment techniques, only one study has objectively compared two approaches. The authors used a five-point scale to compare the transconjunctival and transcutaneous techniques of blepharoplasty in that study; however, their focus was on complications rather than on therapeutic results.⁴⁴ These scales are subjective and require advanced training to analyze each score accurately.

Jo et al conducted a prospective study to define the age- and sex-related changes in baggy lower eyelids assessed by the OGS, where OGS values showed a significant correlation with the clinical patterns of baggy lower eyelids, and they concluded that the OGS could be a potent objective assessment tool for baggy lower eyelids due to its advantages of delicacy sensitivity and

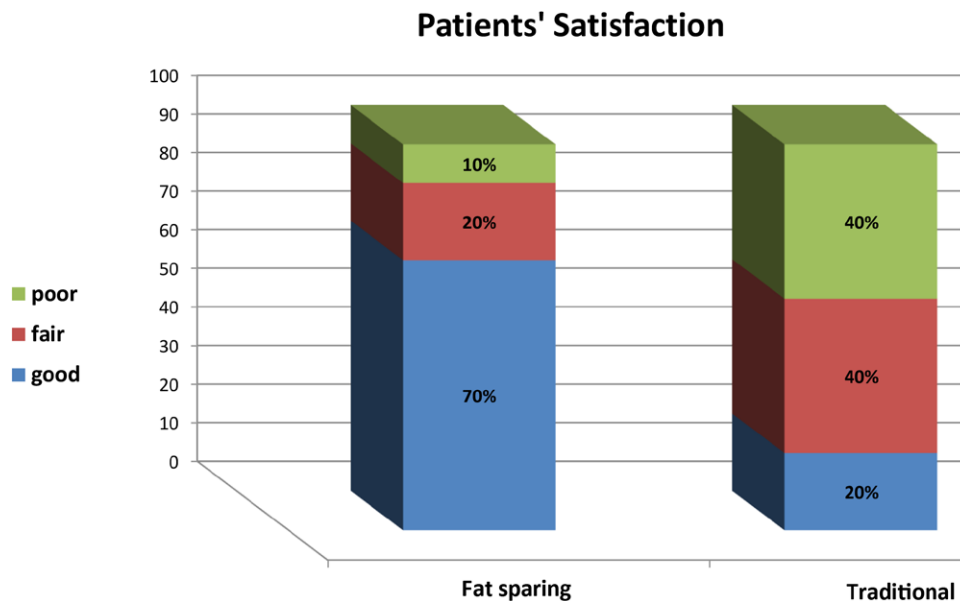


Fig. 7. Patient satisfaction among the studied groups.

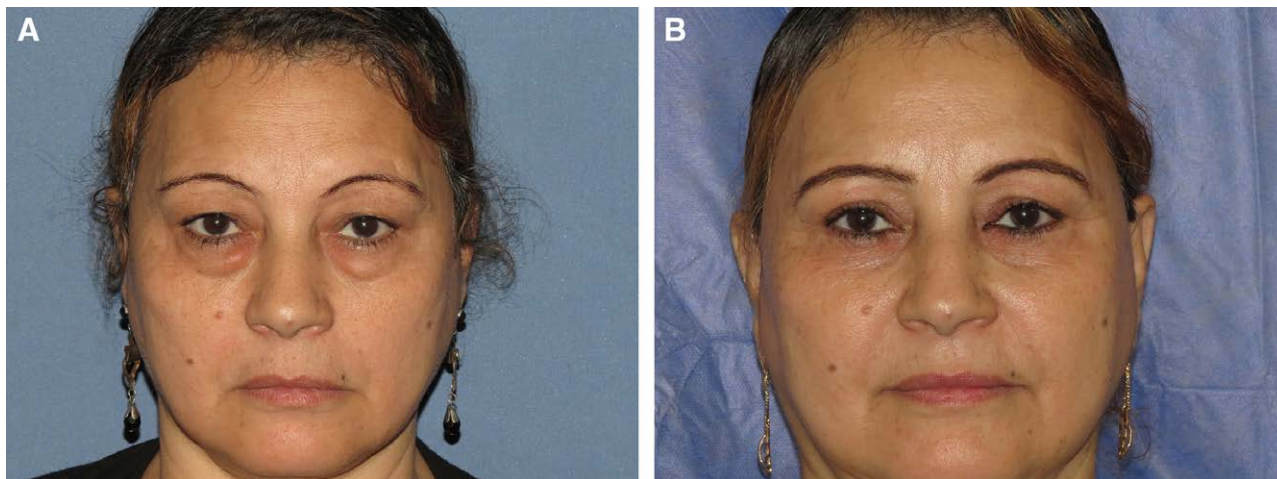


Fig. 8. Preoperative (A) and 6 months postoperative (B) frontal-view of a 53-year-old woman who underwent the fat-sparing technique with orbital septal plication, showing marked and symmetrical improvement of lower eyelid bulging in both sides.

good reproducibility.¹⁵ The junction between the lower eyelid and cheek shows a smooth and uniform continuum in a youthful appearance; herniation of the infraorbital fat pads exaggerates baggy infraorbital folds such as the nasojugal fold and palpebromalar groove. As baggy lower eyelids accompany visible baggy infraorbital folds, Jo et al evaluated the severity of the baggy eyelid using the linear gray scale analysis of the fold, which was useful for evaluating the severity of nasolabial wrinkles.^{15,16}

Yang et al used OGS as an objective method for evaluating the surgical outcomes of baggy eyelid correction; they concluded that the total OGS change was significantly associated with improvements in tear-trough depression and fat bulging. Therefore, it could be a convenient objective evaluation measure for eyelid correction procedures.³⁷ In our study, we compared the results of traditional lower blepharoplasty with fat excision and

the fat-sparing technique using the orbital septal plication method without an incision to the orbital septum using OGS analysis as an objective method for assessment.

The total OGS score showed a significant reduction postoperatively. Particularly, the fat-sparing group showed a higher reduction percentage than the traditional group postoperatively (34.6 ± 2.9 in fat-sparing versus 15.5 ± 3.3 in traditional groups; $P < 0.001$).

Yang et al used a transconjunctival technique and orbital fat excision and discovered that the more fat removed during surgery, the greater the improvement in the OGS.³⁷ Similarly, insufficient orbital fat excision during the management of the medial, central, and lateral compartments will reduce OGS improvement, which could explain our findings, which indicate higher improvement in OGS in the fat-sparing group using orbital septal plication than the traditional group postoperatively as in contrast to the

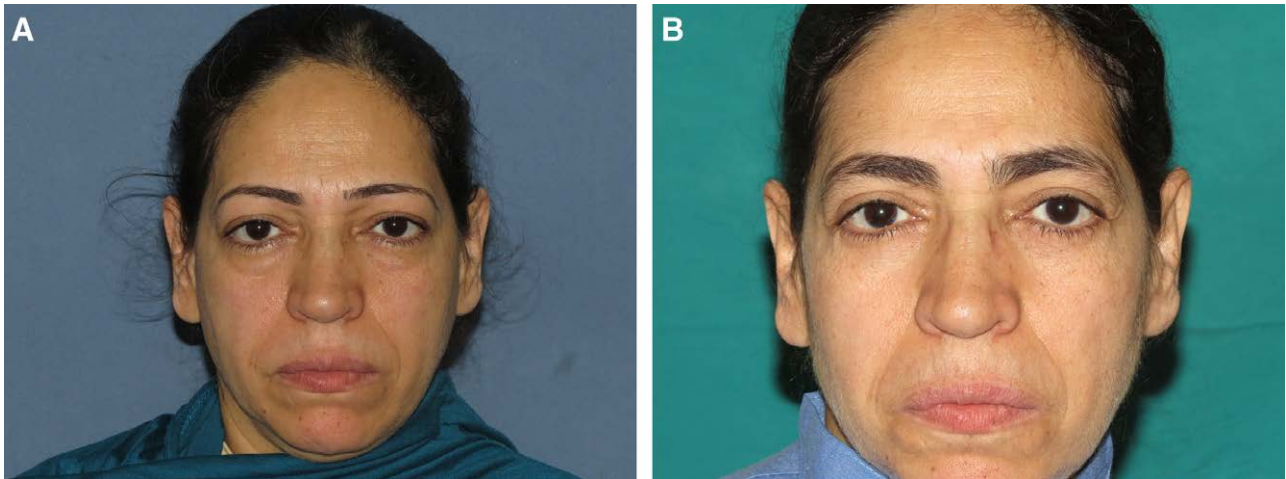

Fig. 9. Preoperative (A) and 6 months postoperative (B) frontal-view of a 43-year-old woman who underwent traditional technique with orbital fat excision, showing improvement of lower eyelid bulging in both sides with satisfactory results.

standard fat resection, the capsulopalpebral fascia repair does not require the difficult task of estimating the exact amount of fat to be removed.

After comparing the total operative time between the two procedures we found that the intraoperative time was relatively shorter in the fat-sparing group than that in the traditional group; we can only postulate that because no fat is excised in capsulopalpebral fascia hernia repair, eliminating traction and coagulation of the fatty tissue, decreasing steps, and measures required to control bleeding during fat excision. Similarly, the duration of postoperative edema and ecchymosis was significantly shorter in the fat-sparing than in the traditional group, which can be explained by the fact that intraorbital fat is not violated by resection and coagulation in fat-sparing group providing a less traumatic approach.

Two patients showed a mild degree of hollowing after standard fat excision, which can be attributed to the difficult estimation of the exact amount of fat to be removed with the possibility of over resection, as has been observed by others.^{24,45}

Two patients in the fat-sparing group had mild lid retraction on one lower eyelid that improved completely within 6 months, whereas five patients in the fat excision group had lid retraction in one lower eyelid, three of whom improved completely within 6 months, and the other two patients had residual mild lid retraction after 6 months follow-up, which could be due to increased scar contracture caused by coagulation of fatty tissue and orbital septum during fat excision.

During the assessment of patient satisfaction, we found that the satisfaction grades were higher among the fat-sparing group; however, Yang et al believed that satisfaction is a complex concept that involves various aspects, including psychosocial and clinical factors. As a result, it cannot be used to assess surgical outcomes in a representative manner.³⁷

To the best of our knowledge, this is the first study that compared the results of traditional lower blepharoplasty with fat excision and orbital septal plication method using orbital scale analysis as an objective method for assessment

and determined the satisfaction score in addition to the early and late complications. However, this study has some limitations that may hinder the generalizability of these findings, including the small sample size, the short follow-up, and the single-center setting.

In conclusion, the current evidence suggests that both techniques are effective in terms of cosmetic outcomes and are associated with a low complication rate. However, the application of the fat-sparing technique is associated with favorable cosmetic outcomes and a lower complication rate compared with the traditional technique with fat excision. Further studies with a longer duration of follow-up and a larger sample size are required to estimate the risk of recurrence and the need for a revision procedure.

Adnan Gamal Etman, MSc

Plastic, Burn, and Maxillofacial Surgery Department
Ain Shams University
6 October Street, Nasr City
Cairo 11528, Egypt

E-mail: Adnan_etman@yahoo.com

PATIENT CONSENT

The patients provided written consent for the use of their images.

REFERENCES

1. Wong CH, Mendelson B. Extended transconjunctival lower eyelid blepharoplasty with release of the tear trough ligament and fat redistribution. *Plast Reconstr Surg*. 2017;140:273–282.
2. Hamra ST. The role of the septal reset in creating a youthful eyelid-cheek complex in facial rejuvenation. *Plast Reconstr Surg*. 2004;113:2124–41; discussion 2142.
3. Hidalgo DA. An integrated approach to lower blepharoplasty. *Plast Reconstr Surg*. 2011;127:386–395.
4. Oestreicher J, Mehta S. Complications of blepharoplasty: prevention and management. *Plast Surg Int*. 2012;2012:252368.
5. Huang T. Reduction of lower palpebral bulge by plicating attenuated orbital septa: a technical modification in cosmetic blepharoplasty. *Plast Reconstr Surg*. 2000;105:2552–8; discussion 2559.

6. Pak C, Yim S, Kwon H, et al. A novel method for lower blepharoplasty: Repositioning of the orbital septum using inverted t-shaped plication. *Aesthet Surg J*. 2018;38:707–713.
7. De la Plaza R, Arroyo JM. A new technique for the treatment of palpebral bags. *Plast Reconstr Surg*. 1988;81:677–687.
8. Mendelson BC. Herniated fat and the orbital septum of the lower lid. *Clin Plast Surg*. 1993;20:323–330.
9. Hamra ST. Arcus marginalis release and orbital fat preservation in midface rejuvenation. *Plast Reconstr Surg*. 1995;96:354–362.
10. Goldberg RA. Transconjunctival orbital fat repositioning: transposition of orbital fat pedicles into a subperiosteal pocket. *Plast Reconstr Surg*. 2000;105:743–8; discussion 749.
11. Huang T. Reduction of lower palpebral bulge by plicating attenuated orbital septa: a technical modification in cosmetic blepharoplasty. *Plast Reconstr Surg*. 2000;105:2552–8; discussion 2559.
12. Ablon G, Rotunda AM. Treatment of lower eyelid fat pads using phosphatidylcholine: clinical trial and review. *Dermatol Surg*. 2004;30:422–7; discussion 428.
13. Goldberg RA, McCann JD, Fiaschetti D, et al. What causes eyelid bags? Analysis of 114 consecutive patients. *Plast Reconstr Surg*. 2005;115:1395–402; discussion 1403.
14. Youn S, Shin JI, Kim JT, et al. Transconjunctival subperiosteal fat reposition for tear trough deformity: pedicled fat redraping versus septal reset. *Ann Plast Surg*. 2014;73:479–484.
15. Jo SJ, Kim HS, Park JT, et al. Assessment of age- and sex-related changes in baggy lower eyelids using a novel objective image analysis method: Orbital gray scale analysis. *J Cosmet Dermatol*. 2018;17(5):874–80.
16. Choi JW, Ryu HH, Kim DY, et al. Development of linear grey scale analysis of wrinkle image for the scoring of nasolabial wrinkle severity. *Br J Dermatol*. 2013;168:1132–1133.
17. von Elm E, Altman DG, Egger M, et al. STROBE Initiative. The Strengthening of Reporting of Observational Studies in Epidemiology (STROBE) Statement: guidelines for reporting observational studies. *Int J Surg*. 2014;12:1495–1499.
18. JAVA. Declaration of Helsinki World Medical Association Declaration of Helsinki. *Bull World Heal Organ*. 2013;79:373–4.
19. Trussler AP, Rohrich RJ. MOC-PSSM CME article: Blepharoplasty. *Plast Reconstr Surg*. 2008;121(1 Suppl):1–10.
20. Drolet BC, Sullivan PK. Evidence-based medicine: Blepharoplasty. *Plast Reconstr Surg*. 2014;133:1195–1205.
21. Branham GH. Lower Eyelid Blepharoplasty. *Facial Plast Surg Clin North Am*. 2016;24:129–138.
22. Hashem AM, Couto RA, Waltzman JT, et al. Evidence-based medicine: a graded approach to lower lid blepharoplasty. *Plast Reconstr Surg*. 2017;139:139e–150e.
23. Yaremchuk MJ. Restoring palpebral fissure shape after previous lower blepharoplasty. *Plast Reconstr Surg*. 2003;111:441–50; discussion 451.
24. Hamra ST. The role of orbital fat preservation in facial aesthetic surgery. A new concept. *Clin Plast Surg*. 1996;23:17–28.
25. Camirand A, Doucet J, Harris J. Eyelid aging: the historical evolution of its management. *Aesthetic Plast Surg*. 2005;29:65–73.
26. Mohadjer Y, Holds JB. Cosmetic lower eyelid blepharoplasty with fat repositioning via intra-SOOF dissection: surgical technique and initial outcomes. *Ophthalmic Plast Reconstr Surg*. 2006;22:409–413.
27. Huang T. Reduction of lower palpebral bulge by plicating attenuated orbital septa: a technical modification in cosmetic blepharoplasty. *Plast Reconstr Surg*. 2000;105:2552–8; discussion 2559.
28. Hamra ST. Arcus marginalis release and orbital fat preservation in midface rejuvenation. *Plast Reconstr Surg*. 1995;96:354–362.
29. Hamra ST. Prevention and correction of the “face-lifted” appearance. *Facial Plast Surg*. 2000;16:215–229.
30. Baker SR. Orbital fat preservation in lower-lid blepharoplasty. *Arch Facial Plast Surg*. 1999;1:33–37.
31. Pessa JE, Desvigne LD, Lambros VS, et al. Changes in ocular globe-to-orbital rim position with age: implications for aesthetic blepharoplasty of the lower eyelids. *Aesthetic Plast Surg*. 1999;23:337–342.
32. Atiyeh BS, Hayek SN. Combined arcus marginalis release, preseptal orbicularis muscle sling, and SOOF plication for midfacial rejuvenation. *Aesthetic Plast Surg*. 2004;28:197–202.
33. Hamra ST. The role of the septal reset in creating a youthful eyelid-cheek complex in facial rejuvenation. *Plast Reconstr Surg*. 2004;113:2124–41; discussion 2142.
34. Aiache AE, Ramirez OH. The suborbicularis oculi fat pads: an anatomic and clinical study. *Plast Reconstr Surg*. 1995;95:37–42.
35. Knize DM. The superficial lateral canthal tendon: anatomic study and clinical application to lateral canthopexy. *Plast Reconstr Surg*. 2002;109:1149–57; discussion 1158.
36. Muzaffar AR, Mendelson BC, Adams WP Jr. Surgical anatomy of the ligamentous attachments of the lower lid and lateral canthus. *Plast Reconstr Surg*. 2002;110:873–84; discussion 897.
37. Yang S, Kim BR, Kim HS, et al. A quantitative, objective method for evaluating the surgical outcomes of baggy eyelid correction using orbital gray scale analysis. *J Cosmet Dermatol*. 2019;18:1814–1820.
38. Barton FE Jr, Ha R, Awada M. Fat extrusion and septal reset in patients with the tear trough triad: a critical appraisal. *Plast Reconstr Surg*. 2004;113:2115–21; discussion 2122.
39. Baylis HI, Long JA, Groth MJ. Transconjunctival lower eyelid blepharoplasty. Technique and complications. *Ophthalmology*. 1989;96:1027–1032.
40. Ablon G, Rotunda AM. Treatment of lower eyelid fat pads using phosphatidylcholine: clinical trial and review. *Dermatol Surg*. 2004;30:422–7; discussion 428.
41. Morley AM, Malhotra R. Use of hyaluronic acid filler for tear-trough rejuvenation as an alternative to lower eyelid surgery. *Ophthalmic Plast Reconstr Surg*. 2011;27:69–73.
42. Kane MA. Treatment of tear trough deformity and lower lid bowing with injectable hyaluronic acid. *Aesthetic Plast Surg*. 2005;29:363–367.
43. Kashkoui MB, Pakdel F, Kiavash V, et al. Transconjunctival lower blepharoplasty: a 2-sided assessment of results and subjects’ satisfaction. *Ophthalmic Plast Reconstr Surg*. 2013;29:249–255.
44. Netscher DT, Patrinely JR, Peltier M, et al. Transconjunctival versus transcutaneous lower eyelid blepharoplasty: a prospective study. *Plast Reconstr Surg*. 1995;96:1053–1060.
45. Loeb R. Fat pad sliding and fat grafting for leveling lid depressions. *Clin Plast Surg*. 1981;8:757–776.