

Recurrent pyometra and xanthogranulomatous salpingitis: A rare pathologic association in a postmenopausal lady

Neha Gami, Rajlaxmi Mundhra, Kiran Guleria, Vinod Kumar Arora¹, Shipra Garg¹

Departments of Obstetrics and Gynecology, and ¹Pathology, University College of Medical Sciences and Guru Teg Bahadur Hospital, New Delhi, India

ABSTRACT

Xanthogranulomatous inflammation is a rare, non-neoplastic variant of chronic inflammation. Of the 15 reported cases of Xanthogranulomatous endometritis, majority (60%) were accompanied by endometrial carcinoma. We herein report a case of a postmenopausal woman presenting with recurrent pyometra who was suspected to be case of cervical tuberculosis and treated for the same. In spite of antitubercular therapy, she had cervical stenosis and developed recurrent pyometra over the next 2 years requiring repeated drainage. She then underwent hysterectomy and was found to have co-existent Xanthogranulomatous salpingitis (XGS) on histopathological examination. Xanthogranulomatous inflammation is a rare pathological diagnosis that gynecologists need to be aware of while managing such patients.

Key Words: Recurrent pyometra, salpingitis, xanthogranulomatous inflammation

INTRODUCTION

Xanthogranulomatous inflammation is an uncommon form of chronic inflammation, causing destruction of affected organs and is characterized by the presence of lipid laden histiocytes admixed with lymphocytes, plasma cells and leucocytes.^[3] It usually involves kidneys and gall bladder.^[4] Involvement of female genital tract as such is rare but when it does so, it is the endometrium which usually gets affected. To our knowledge, no case of Xanthogranulomatous salpingitis (XGS) has been reported in association with recurrent pyometra.

CASE REPORT

60-years-old, P₇L₇, postmenopausal lady presented with complaints of foul smelling pus like discharge per vaginum for 3 months. She was a known hypertensive and is on regular medication. General physical and abdominal examination was unremarkable. Per Speculum examination revealed an inflamed cervix, flushed with the vagina and pus like discharge coming through os. On per vaginal

examination, uterus was bulky, bilateral fornices were free. Pelvic ultrasound revealed intrauterine collection. Pap smear was taken and cervical dilatation with pyometra drainage was done. Around 5 cc pus was drained. Pus culture was sterile and negative for acid fast bacilli. Pap smear showed granulomatous cervicitis [Figure 1] and based on it the patient was started on anti-tubercular therapy for 6 months. Nine months later, the woman presented with blood mixed discharge per vaginum and underwent dilatation and curettage which suggested chronic endometritis. A repeat Pap smear was done and it showed inflammatory smear. Antibiotic course was given with an advice to follow-up.

A year later, she presented again with pyometra. Drainage was done. Culture was sterile and negative for acid fast bacilli and she continued to have pus discharge. Ultrasound was repeated which showed 100 cc intrauterine collection. Repeat drainage was done,

Address for Correspondence: Dr. Rajlaxmi Mundhra,
Department of Obstetrics and Gynecology, Guru Teg Bahadur
Hospital, New Delhi - 110 095, India.
E-mail: rmundhra54@yahoo.com

Access this article online

Quick Response Code:



Website:
www.jmidlifehealth.org

DOI:
10.4103/0976-7800.141227

for the third time, and an intrauterine Foleys catheter no 8 was put for continuous drainage. Pus culture showed *E. Coli* infection and based on sensitivity, antibiotics were started. In view of recurrent pyometra, a differential of tubercular endometritis or endometrial malignancy was suspected. In view of recurrent pyometra requiring repeated drainage she was taken up for hysterectomy with bilateral salpingo-oophorectomy. The abdominal route was planned as the uterus was very soft and cervix was flushed with the vagina. During the surgery, it was seen that the uterus was very soft and bulky. Bilateral tubes were studded with tubercles. A 2 × 1 cm solid, yellow nodule was present near the cornual end of right tube, which on cut section showed exudation of caseous purulent material [Figure 2]. Clinical suspicion of fallopian tube malignancy was made.

Pathology

The gross examination of the specimen revealed dilated right fallopian tube measuring 5.5 cm in length with a solid 2 × 1 × 0.5 cm yellow colored nodule at the cornual end. The left fallopian tube measured 4.5 cm in length with unremarkable uterus and cervix. The bilateral ovaries showed corpus luteum. The histopathological examination of bilateral fallopian tubes showed acute and Xanthogranulomatous inflammation, composed of mainly foamy histiocytes, lymphocytes, plasma cells and few neutrophils [Figure 3]. Sections from uterus showed surface ulceration with chronic endometritis. The bilateral ovaries were unremarkable.

The post-operative period was unremarkable and the woman was discharged on 6th post-operative day with an advice to follow-up.

DISCUSSION

Xanthogranulomatous inflammation is a rare, chronic inflammation affecting the organs of the female genital system. XGS mainly involves unilateral fallopian tubes, occasionally occurs bilaterally. It is clinically often accompanied with inflammation in vagina, cervix and endometrium. The visibly thickened fallopian tube is variable in length, with an appearance of mass lesion. There is exudation on the serosal surface and the fimbriated end of fallopian tube is usually obliterated. Morphologically, the fallopian tube structure remains intact.^[5]

The exact etiology has remained elusive but it has been associated with infection, ineffective antibiotic therapy leading to ineffective clearance of bacteria by phagocytes, endometriosis and pelvic inflammatory disease.^[6,7] Organisms such as *E coli*, *Proteus spp.*, *Staphylococcus aureus*,

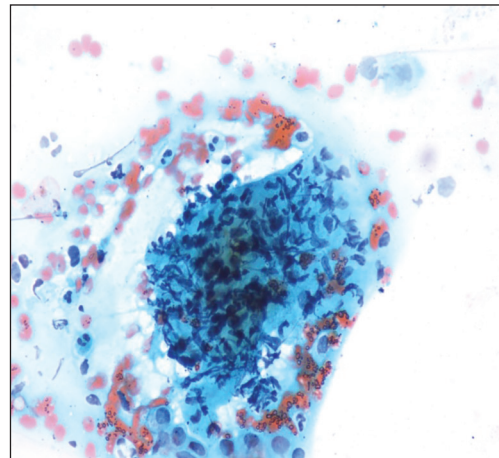


Figure 1: Pap smear showing histiocytic granuloma

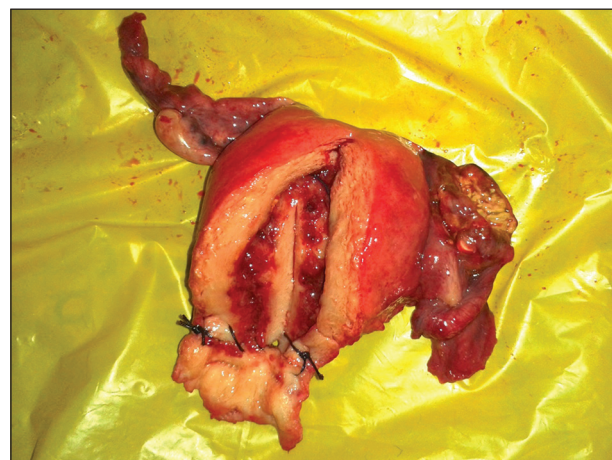

Figure 2: Hysterectomy specimen showing granuloma in right tube

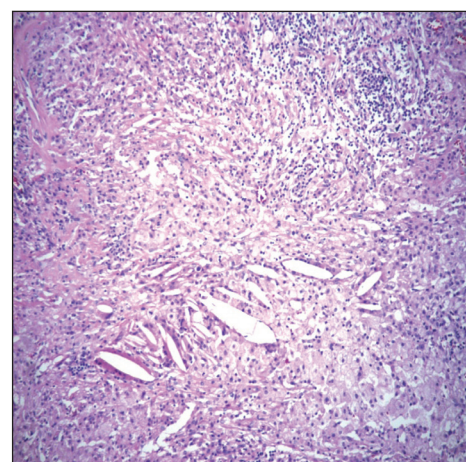


Figure 3: 40x photomicrograph of cholesterol clefts surrounded by xanthomous cells and chronic inflammation

Bacterioides fragilis and *Salmonella typhi* have been isolated from bacterial culture.^[8]

In our case of recurrent pyometra, a combination of factors may have been responsible for the development

of Xanthogranulomatous inflammation of the fallopian tubes. Granulomatous cervicitis, probably secondary to tuberculosis led to cervical stenosis. This led to recurrent pyometra in the lady. Chronic collection of pus in the uterine cavity leading to obstruction of the fallopian tubes may have predisposed to infection in the tubes followed by tissue necrosis and release of cholesterol and other lipids, and phagocytosis by macrophages. Also we had found infection with *E coli* which has been found to be associated with Xanthogranulomatous inflammation.

A review of the literature done by Margaret *et al.*, revealed that patients with XGS ranged from 23-72 years old and initial presentation most often included lower abdominal or suprapubic pain, fever, menorrhagia or vaginal bleeding, and physical examination typically showed a pelvic mass with adnexal tenderness.^[9] But this is probably the first reported case of XGS found in association with recurrent pyometra. Pyometra was seen to be associated with Xanthogranulomatous endometritis in 74-year-old woman in a case reported by Santamaria *et al.*^[10] Pyometra was found in association with Xanthogranulomatous endometritis was also seen in a 69-year-old woman with a short history of abdominal pain and a palpable mass in the pouch of Douglas.^[2] A case of cavernous ovarian hemangioma with xanthogranulomatous salpingo-oophoritis in the contralateral adnexa has also been reported in a 61-year-old patient presenting with postmenopausal bleeding and pain abdomen.^[11]

The importance of Xanthogranulomatous inflammation lies in the fact that it can present as a lump or tumor and can even mimic malignancy. Hence, gynecologists need to be aware of this entity and be able to differentiate it from endometrial, ovarian or tubal malignancy. Untreated Xanthogranulomatous inflammation has also been reported to be lethal by causing systemic inflammation.^[2] Hence, aggressive treatment in the form of surgery should be strongly considered, if diagnosed pre-operatively. In our case, timely hysterectomy prevented any progress of the condition and prevented systemic inflammation and

its consequences.

Xanthogranulomatous inflammation is a rare condition affecting the female genital system. It should be borne in mind while managing chronic infective conditions like recurrent pyometra, as it has been known to progress to systemic inflammation which can be lethal.

REFERENCES

1. Kunakemakorn P, Ontai H, Balin H. Pelvic inflammatory pseudotumor: A case report. *Am J Obstet Gynecol* 1976;26:286-7.
2. Noack F, Briese J, Stellmacher F, Hornung D, Horny HP. Lethal outcome in xanthogranulomatous endometritis. *APMIS* 2006;114:386-8.
3. Franco V, Florena AM, Guarneri G, Gargano G. Xanthogranulomatous salpingitis. Case report and review of the literature. *Acta Eur Fertil* 1990;21:197-9.
4. Mittal BV, Badhe BP. Xanthogranulomatous pyelonephritis — (a clinicopathological study of 15 cases). *J Postgrad Med* 1989;35:209-14.
5. Zhang XS, Dong HY, Zhang LL, Desouki MM, Zhao C. Xanthogranulomatous inflammation of the female genital tract: Report of three cases. *J Cancer* 2012;3:100-6.
6. Cozzutto C. Xanthogranulomatous osteomyelitis. *Arch Pathol Lab Med* 1984;108:973-6.
7. Usamentiaga E, Val-Bernal JF, Alonso-Bartolome P, Lopez-Rasines G, del Valle JI, Calabia A. Xanthogranulomatous orchitis. *Urology* 1998;52:891-2.
8. Gray Y, Libbey NP. Xanthogranulomatous salpingitis and oophoritis: A case report and review of the literature. *Arch Pathol Lab Med* 2001;125:260-3.
9. Howey JM, Mahe E, Radhi J. Xanthogranulomatous salpingitis associated with a large uterine leiomyoma. *Case Rep Med* 2010;2010:970805.
10. Santamaría IB, Ulacia MA, Perez JM. Endometritis xantogranulomatosa. *Rev Esp Patol* 2004;37:419-22.
11. Shashikala K, Sharmila PS, Sushma TA, Francis P. Ovarian haemangioma with synchronous xanthogranulomatous inflammation—a rare pathological finding. *Int J Health Sci Res* 2013;3:116-9.

How to cite this article: Gami N, Mundhra R, Guleria K, Arora VK, Garg S. Recurrent pyometra and xanthogranulomatous salpingitis: A rare pathologic association in a postmenopausal lady. *J Mid-life Health* 2014;5:156-8.

Source of Support: Nil, **Conflict of Interest:** None declared.