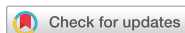

## Case Report



# Asymptomatic Bladder Diverticulum Can Develop New Urinary Symptoms after a New Onset of Stroke: a Case Report

## OPEN ACCESS

Won-Jae Jo, Yong-Soon Yoon, Eun-Sil Kim, Jun-Hyun Choi, Kwang-Jae Lee

**Received:** Aug 29, 2019

**Revised:** Sep 19, 2019

**Accepted:** Sep 22, 2019

### Correspondence to

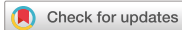**Kwang-Jae Lee**

Department of Physical Medicine and Rehabilitation, Medical Device Clinical Trial Center, Presbyterian Medical Center, 365 Seowon-ro, Wansangu, Jeonju 54987, Korea.  
E-mail: rytt@naver.com

## HIGHLIGHTS

- We report an incidental bladder diverticulum in a stroke patient with benign prostatic hyperplasia.
- The patient complained of new onset urinary symptoms after stroke.
- The patient continues to follow-up in our outpatient clinic and reports an improved quality of life without any concerning urinary symptoms after diverticulectomy.

## Case Report



# Asymptomatic Bladder Diverticulum Can Develop New Urinary Symptoms after a New Onset of Stroke: a Case Report

Won-Jae Jo ,<sup>1</sup> Yong-Soon Yoon ,<sup>1,2</sup> Eun-Sil Kim ,<sup>1</sup> Jun-Hyun Choi ,<sup>1</sup> Kwang-Jae Lee <sup>1,2</sup>

<sup>1</sup>Department of Physical Medicine and Rehabilitation, Presbyterian Medical Center, Jeonju, Korea

<sup>2</sup>Medical Device Clinical Trial Center, Presbyterian Medical Center, Jeonju, Korea

## OPEN ACCESS

**Received:** Aug 29, 2019

**Revised:** Sep 19, 2019

**Accepted:** Sep 22, 2019

### Correspondence to

**Kwang-Jae Lee**

Department of Physical Medicine and Rehabilitation, Medical Device Clinical Trial Center, Presbyterian Medical Center, 365 Seowon-ro, Wansangu, Jeonju 54987, Korea.  
E-mail: rytt@naver.com

Copyright © 2020. Korean Society for Neurorehabilitation

This is an Open Access article distributed under the terms of the Creative Commons Attribution Non-Commercial License (<https://creativecommons.org/licenses/by-nc/4.0>) which permits unrestricted non-commercial use, distribution, and reproduction in any medium, provided the original work is properly cited.

### ORCID iDs

Won-Jae Jo

<https://orcid.org/0000-0002-7124-7153>

Yong-Soon Yoon

<https://orcid.org/0000-0003-4709-3964>

Eun-Sil Kim

<https://orcid.org/0000-0003-1996-4451>

Jun-Hyun Choi

<https://orcid.org/0000-0001-7014-8578>

Kwang-Jae Lee

<https://orcid.org/0000-0001-7148-3765>

### Conflict of Interest

The authors have no potential conflicts of interest to disclose.

## ABSTRACT

Bladder diverticulum can be caused by many varying factors. It is usually asymptomatic in nature and thus often found by chance. In adult males, it can develop as a result of increased intravesicular pressure in the presence of an underlying benign prostatic hyperplasia. We observed a case in which a patient with asymptomatic bladder diverticulum developed new urinary symptoms owing to an underlying neurogenic lower urinary tract disorder which occurred following a cerebral infarction.

**Keywords:** Bladder Diverticulum; Stroke; Neurogenic Bladder

## INTRODUCTION

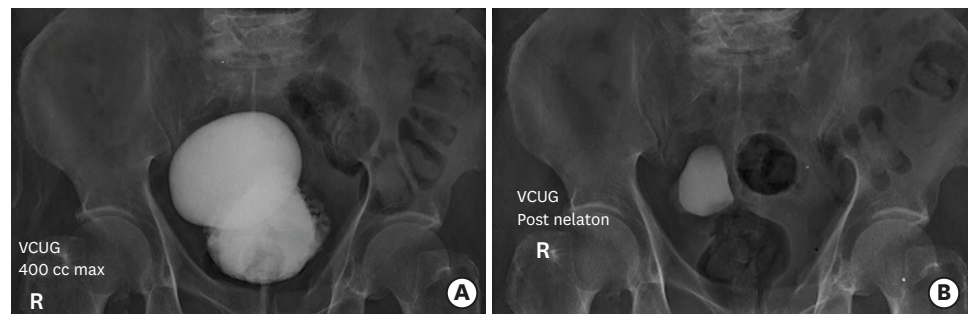
Neurogenic bladder is a common complication in stroke patients and it is known that about 65% of patients in the early stages of stroke experience voiding dysfunction [1,2]. If patients have a urological disorder as well as neurogenic bladder, only drug treatment may have difficulty improving the symptoms of voiding dysfunction. Bladder diverticulum is a protrusion of the mucous membrane via the thin layer of the bladder wall muscle [3]. In adults, it is usually caused by the closure of the bladder outlet. In most cases, the condition is asymptomatic and incidentally found on imaging studies upon workup of other underlying co-morbidities. And thus, it is difficult to account for the actual underlying disease incidence. However, the prevalence of bladder diverticula associated with benign prostatic hyperplasia (BPH) is approximately 6% [4]. We report an incidental bladder diverticulum discovered in a patient with recent stroke onset and previously underlying BPH who complained of new onset urinary symptoms.

## CASE REPORT

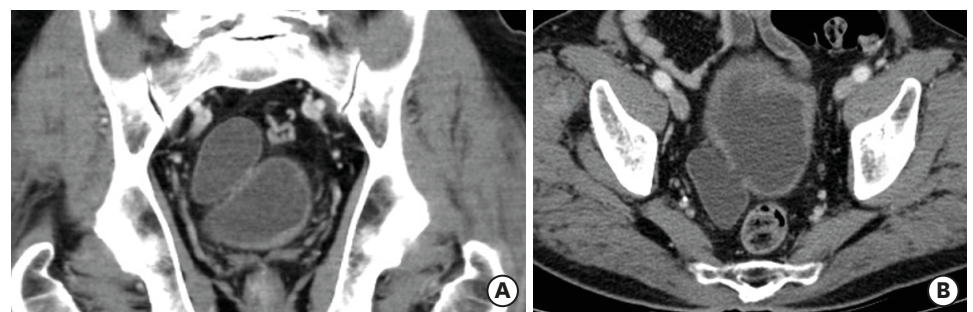
A 79-year-old male with acute lateral medullary infarction complained of new onset urinary symptoms of voiding difficulty with hesitancy, frequency and retention 3 days following a recent onset of stroke. His past medical history is significant for an underlying mild BPH

which had been managed with medications for 6 years without any concerning urinary symptoms. The patient's BPH medications were dutasteride (5 $\alpha$ -reductase) and silodosin ( $\alpha$ 1-adrenoceptor antagonist) and began to complain of voiding-related symptoms that were not present before the stroke even though the BPH medications were still taken after the stroke. Post-voiding residual volume of greater than 100 mL was noted on evaluation concurrent with subjective complaints of frequency, bladder fullness and difficulty in initiation.

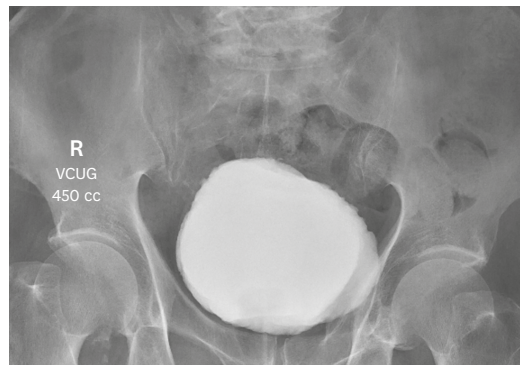
About 30 gm of mild BPH was detected on the prostate ultrasound. Urology input regarding management with new pharmaco-therapeutics added to his clinical regimen offered no improvement. We conducted a voiding cystourethrography (VCUG) and discovered 2 cyst-like spaces filled with dye (Fig. 1). Thereafter we performed a computed tomography which confirmed that one of the 2 filled spaces was a diverticulum located on the upper right side of the bladder (Fig. 2). The patient's urinary symptoms persisted and interfered significantly with daily life activities. We tried to change the medication several times in consultation with the urologist, but there was no significant improvement in urinary symptoms. This prompted subsequent urology consultation regarding alternative treatment options. Surgical intervention was agreed upon as the next step in management. The patient was fully informed regarding the risks and benefits of the procedure. The patient agreed and underwent a diverticulectomy. Post-operative hematuria indicated the placement of an indwelling catheter following the procedure. Two weeks later, hematuria improved and the catheter was removed. Previously reported urinary symptoms also improved. VCUG was performed once again which showed non-specific findings with the exception of trabeculations of the bladder wall (Fig. 3). The patient maintained the BPH medication for BPH control even after diverticulectomy and continues to follow-up in our outpatient clinic and reports an improved quality of life without any concerning urinary symptoms.



**Fig. 1.** The VCUG test show the bladder diverticulum (A) and a residual urine after voiding phase in the bladder diverticulum (B) before surgery. VCUG, voiding cystourethrography.



**Fig. 2.** A coronal (A) and horizontal (B) cut of CT demonstrating a diverticulum superior and posterior to the bladder. CT, computed tomography.



**Fig. 3.** The VCUG test shows the recovery to normal bladder volume and the diverticulum disappear after surgery. VCUG, voiding cystourethrography.

## DISCUSSION

Bladder diverticulum is the protrusion of the bladder mucosa through the layer of muscular fibers which comprise the bladder wall [3]. It can be acquired and usually occurs in men over the age of 60 years. In adults, diverticula are often located along the lateral aspects of the bladder wall [5,6]. Similar to the mechanism by which it develops in children with posterior urethral valves, increased intravesical pressure due to prostatic disease or other underlying neurological conditions such as stroke, as in the case of our patient, is thought to be the primary pathophysiologic cause in adults [7,8]. Small diverticula are mostly asymptomatic, while larger diverticula can be accompanied by various symptoms such as urinary retention, urinary tract infection and hematuria [9]. However, most cases are subclinical but many are detected during work up of other underlying co-morbidities. Cases about asymptomatic large bladder diverticulum have also been reported [10]. In this case, the gradually bred diverticulum was caused by an underlying condition, however, without obvious accompanying symptoms despite several years of having had underlying BPH (the culprit, a pre-existing urinary obstructive pathology). In another case report, neurogenic bladder was reported following a lateral medullary infarction [11]. In our case, stroke may have aggravated the underlying neurogenic bladder thereby manifested in the presenting symptoms. The subjective sense of urinary retention and objective measurement of post-voiding residual urine volume greater than 100 mL can be explained by the actual presence of residual urine in the bladder diverticulum observed on the preoperative VCUG.

Neurogenic bladder can result from central nervous system pathology such as a stroke. The neurogenic bladder may appear as an overactive or underactive bladder pattern. In the case of our patient, neurogenic bladder appear as an underactive bladder pattern which manifests as decreased bladder detrusor activity. This may explain the residual urine in the diverticulum.

It was thought that the patient was without specific urinary symptoms, prior to the onset of stroke, because there was sufficient detrusor function to completely excrete the urine contained in the bladder diverticula. Hence, it was concluded that the neurogenic bladder developed subsequent to stroke onset, which may have caused symptoms that were not pre-existing even with the presence of the diverticulum. The association between the severity of BPH and the size of the bladder diverticulum is not yet clear. The patient had mild BPH, but had a large size bladder diverticulum and before the stroke, the patient was able to live without any discomfort just by taking the BPH medications. Therefore, if neurogenic

bladder arises in the setting of a stroke among patients with prior underlying BPH, bladder diverticulum should be considered as an etiological cause. If a patient has both BPH and neurogenic bladder, BPH treatment must be combined to control neurogenic bladder symptoms [12]. In our patient, the symptoms of neurogenic bladder improved following surgical removal of the diverticulum with BPH medication treatment.

## REFERENCES

1. Brittain KR, Perry SI, Peet SM, Shaw C, Dallosso H, Assassa RP, Williams K, Jagger C, Potter JE, Castleden CM. Prevalence and impact of urinary symptoms among community-dwelling stroke survivors. *Stroke* 2000;31:886-891.  
[PUBMED](#) | [CROSSREF](#)
2. Burney TL, Senapati M, Desai S, Choudhary ST, Badlani GH. Acute cerebrovascular accident and lower urinary tract dysfunction: a prospective correlation of the site of brain injury with urodynamic findings. *J Urol* 1996;156:1748-1750.  
[PUBMED](#) | [CROSSREF](#)
3. Garat JM, Angerri O, Caffaratti J, Moscatiello P, Villavicencio H. Primary congenital bladder diverticula in children. *Urology* 2007;70:984-988.  
[PUBMED](#) | [CROSSREF](#)
4. Burns E. Diverticula of the urinary bladder. *Ann Surg* 1944;119:656-667.  
[PUBMED](#) | [CROSSREF](#)
5. Wein AJ, Kavoussi LR, Novick AC. *Campbell-Walsh urology*. 9th ed. Philadelphia, PA: W.B. Saunders; 2006.
6. Prakash RT, Rajini T, Kumar Bhardwaj A, VJ, Kalyani Rao P, Singh G. Urinary bladder diverticulum and its association with malignancy: an anatomical study on cadavers. *Rom J Morphol Embryol* 2010;51:543-545.  
[PUBMED](#)
7. Russell RC, Williams NS, Bulstrode CJ. *Bailey and Love's short practice of surgery*. 23rd ed. London: Hodder Arnold; 2000.
8. Gerridzen RG, Futter NG. Ten-year review of vesical diverticula. *Urology* 1982;20:33-35.  
[PUBMED](#) | [CROSSREF](#)
9. Silberman M, Jeanmonod R. Bladder diverticulitis: a case report. *Case Rep Emerg Med* 2011;2011:303498.  
[PUBMED](#) | [CROSSREF](#)
10. Torella M, De Francis P, Mainini G, Marcello A, Matteo M, Ammaturo FP, Di Donna MC, Schettino MT. Asymptomatic large bladder diverticulum. *Clin Exp Obstet Gynecol* 2014;41:87-89.  
[PUBMED](#)
11. Tokushige S, Maekawa R, Nose Y, Shiio Y. A case of lateral medullary syndrome with neurogenic bladder. *Rinsho Shinkeigaku* 2012;52:79-83.  
[PUBMED](#) | [CROSSREF](#)
12. Noordhoff TC, Groen J, Scheepe JR, Blok BF. Surgical management of anatomic bladder outlet obstruction in males with neurogenic bladder dysfunction: a systematic review. *Eur Urol Focus* 2018;S2405-4569(18)30071-3.  
[PUBMED](#) | [CROSSREF](#)