

Incidental colorectal focal ^{18}F -FDG uptake: a novel indication for colonoscopy



Authors

Eugénie Rigault¹, Laurence Lenoir², Guillaume Bouguen¹, Mael Pagenault¹, Astrid Lièvre¹, Etienne Garin², Laurent Siproudhis¹, Jean-François Bretagne¹

Institutions

- 1 Service des Maladies de l'Appareil Digestif, Hôpital Pontchaillou, Centre Hospitalo-Universitaire, Rennes
- 2 Service de Médecine Nucléaire, Centre Eugène Marquis, Rennes

submitted 19.3.2017

accepted after revision 26.6.2017

Bibliography

DOI <https://doi.org/10.1055/s-0043-116384> |
Endoscopy International Open 2017; 05: E924–E930
© Georg Thieme Verlag KG Stuttgart · New York
ISSN 2364-3722

Corresponding author

Pr. Jean-François Bretagne, Service des Maladies de l'Appareil Digestif, Hôpital Pontchaillou, 35033 Rennes cedex, France
Fax: + 33 2 99 28 41 89
jf.bretagne@gmail.com

ABSTRACT

Background and study aims The relevance of incidental colorectal focal ^{18}F -FDG PET/CT uptake is debatable. All patients who were referred for colonoscopy because of incidental colonic focal FDG uptake were included in this retrospective study.

Patients and methods PET/CT imaging characteristics were reviewed by a nuclear physician who was blinded to endoscopic and histopathological findings to determine the location of FDG uptake sites and to measure the maximum standardized uptake values (SUVmax) and metabolic volume (MV). Endoscopic findings were categorized as malignant lesions (ML), high-risk polyps (HRP), low-risk polyps (LRP) or other non-neoplastic lesions (NNL).

Results Seventy patients with 84 foci of FDG uptake were included. The proportions of true-positive (lesions found at colonoscopy at the same location) and false-positive (no lesion at colonoscopy) PET/CT findings were 65.5% ($n=55$) and 34.5% ($n=29$). Median SUVmax values did not differ between true-positive and false-positive findings ($P=0.27$). Median MV30 values differed significantly between true-positive (5.5 cm^3 , [3.3–10.9 cm^3]) and false-positive (9.7 cm^3 , [5.2–40.8 cm^3]) findings ($P=0.015$). Among the 55 true-positive FDG uptake sites, there were 14 (25.5%) malignant lesions, 30 (54.5%) HRP, 4 (7.3%) LRP, and 7 (12.7%) NNL. Median MV30 values differed significantly between advanced neoplasia (5.0 cm^3 , [2.9–9.7 cm^3]) and other endoscopic findings (9.4 cm^3 , [5.2–39.8 cm^3]) ($P=0.001$); the AUROC was 0.71. By per-colonic segment analysis, the distribution of true-positive, false-negative, false-positive, and true-negative FDG PET/CT findings was as follows: 21.5%, 14.2%, 11.5%, and 52.8%, respectively.

Conclusion Our study demonstrates that follow-up complete colonoscopy is mandatory in all patients with incidental colorectal focal ^{18}F -FDG PET/CT uptake.

Introduction

Positron emission tomography, which uses the glucose analogue ^{18}F -fluorodeoxyglucose with computed tomography (^{18}F -FDG PET/CT), is increasingly used in oncology for the initial staging of cancer and monitoring the treatment response. As a result of the increased availability of ^{18}F -FDG PET/CT, unexpected ^{18}F -FDG uptake has been identified in a variety of sites, including the large bowel [1–5]. Incidental colorectal FDG uptake is found in approximately 3.6% of patients undergoing evaluation for non-gastrointestinal disease [6]. FDG uptake can be diffuse, segmental or focal. Diffuse or segmental FDG

uptake generally results from physiological or inflammatory processes [7–9]. In contrast, focal FDG uptake, which is observed in 0.4% to 16.3% of patients undergoing PET/CT examinations, is usually associated with the discovery of malignant and pre-malignant lesions in almost 68% of patients [6]. Consequently, false-positive findings have been reported in 9.3% to 63% of these cases [9–22]. Although the mechanisms of FDG uptake in the large bowel are unclear, false-positive uptake is thought to be the consequence of the physiological accumulation of FDG [23, 24].

To avoid the need for invasive diagnostic procedures, the use of parameters such as FDG maximum standardized uptake val-

ue (SUV_{max}) was proposed to discriminate malignant from benign conditions. Although some studies showed significant differences in SUV_{max} values between malignant and benign lesions [20, 25, 26], others did not [11, 12, 17, 19]. Moreover, no differences in SUV_{max} between true-positive and false-positive FDG uptake have been recently reported [10, 21].

Another issue with the use of FDG PET/CT findings for screening colorectal lesions is the occurrence of false-negative results. Some patients without any colorectal FDG accumulation on PET/CT are found to have premalignant or malignant lesions at colonoscopy [10, 19]. However, few data are available on these non-FDG-avid colorectal lesions. Therefore, the aim of this study was to evaluate the correlation between FDG PET/CT and endoscopic findings in patients with incidental focal colorectal FDG uptake and to assess the characteristics of non-FDG-avid colonic lesions.

Patients and methods

Patients

The database of colonoscopies performed at the University Hospital of Rennes was reviewed. Among 27,170 colonoscopies or flexible sigmoidoscopies performed between 2005 and 2015, we selected examinations that were performed to determine incidental colorectal FDG uptake on PET/CT.

Patient demographics and medical histories at the time of FDG PET/CT and indications for FDG PET/CT were extracted from the database. Patients with personal histories of colorectal disease were excluded.

PET/CT imaging analysis

The patients fasted for at least 4 hours before PET/CT. The blood glucose level was controlled before FDG injection. Acquisition was performed 60 to 90 minutes after intravenous injection of 4 MBq/kg of FDG, but no delayed acquisition was performed. All PET/CT studies were performed with a hybrid PET/CT scanner (Discovery LS, GE Medical Systems Inc., Waukesha, WI, USA) from the base of the skull to the proximal thighs without contrast-enhancement. The acquired data were (ordered-subset expectation maximization) iteratively reconstructed before and after attenuation correction.

PET/CT images were reassessed by a physician at the Department of Nuclear Medicine, who was blinded to endoscopic and histopathologic findings, to include patients with focal FDG uptake, to exclude those with segmental or diffuse FDG uptake, to record the location of colorectal FDG uptake sites and to measure the maximum standard uptake value (SUV_{max}) and the metabolic volume (MV) using automated SUV-based 3D contouring software that was available at the workstation. MV was defined as the volume produced by segmentation at a fixed 50% (MV50) or 30% (MV30) of the SUV_{max} threshold obtained using a region-growing algorithm and using the maximum intensity voxel as seed [21].

The colon was divided into 4 segments: the rectosigmoid, left colon, transverse colon and right colon. Incidental colorectal FDG uptake was defined as intense uptake located in the colon or in the rectum in comparison to the background activity;

no specific SUV_{max} was used to define this parameter. Colorectal FDG accumulations were classified in 3 categories according to their pattern: focal for nodular uptake and segmental or diffuse for colonic wall uptake that was shorter or longer than one colonic segment.

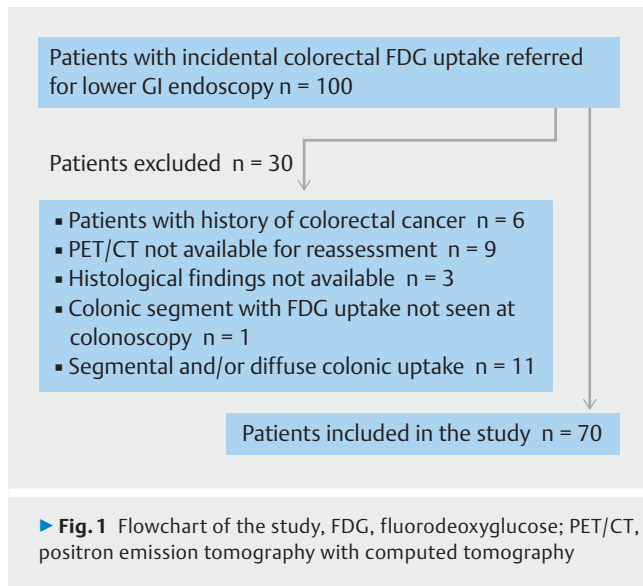
Endoscopy

Information on characteristics of colonoscopies or flexible sigmoidoscopies was collected. The segments seen at colonoscopy were recorded. Patients were excluded from this study when the segment with FDG uptake was not seen at colonoscopy. The quality of bowel preparation was assessed according to the overall and per-segment Boston score [27].

For each segment (rectosigmoid, left colon, transverse colon and right colon), we recorded presence of lesions or a lack of abnormalities. Macroscopic aspects and the size of the lesions were recorded. Histologic results were obtained from an analysis of biopsy specimens or of lesions that were resected at colonoscopy or surgically. Colorectal lesions were divided into 4 categories according to histologic results: a malignant lesion corresponded to an intramucosal or more invasive colorectal adenocarcinoma or to other malignancy; high-risk polyps (HRPs) corresponded to adenomas that were ≥ 10 mm or with high-grade dysplasia and to sessile serrated polyps with dysplasia; low-risk polyps (LRPs) corresponded to adenomas that were < 10 mm and with low-grade dysplasia and to sessile serrated polyps without dysplasia; non-neoplastic lesions (NNLs) corresponded to hyperplastic polyps and other various lesions. The sum of malignant lesions and HRPs corresponded to advanced neoplasia.

Statistical analyses

Quantitative variables are expressed as median and interquartile ranges (IQR), and qualitative variables are expressed as numbers and percentages. Per-patient, per-FDG uptake, per-lesion and per-segment analyses were performed. For per-patient analyses, patients were regarded as true-positive if they had at least one focal colorectal FDG uptake with a corresponding endoscopic lesion at the same location and as false-positive if they did not have any relevant endoscopic findings in the segment with focal FDG accumulation. For per-uptake analyses, findings were defined as true-positive when uptake was seen with a corresponding lesion at colonoscopy and as false-positive when uptake was seen without a corresponding lesion at colonoscopy. Lesions that were seen at colonoscopy but lacked corresponding FDG accumulation on PET/CT were characterized as false-negative PET/CT results. For per-lesion analysis, we defined those with corresponding FDG uptake as FDG-avid lesions and those without corresponding FDG uptake as non-FDG-avid lesions. When adjacent lesions were seen at colonoscopy, the focal FDG uptake was associated with the most advanced lesion; it was not possible to provide a decision for other lesions. Therefore, we also performed a per-segment analysis: segments with endoscopic lesion(s) and focal FDG uptake were considered true-positive FDG results, segments with endoscopic lesion without FDG uptake were considered false-negative FDG results, segments with FDG uptake but without



lesion were considered false-positive FDG results, and segments without FDG uptake and endoscopic lesion were considered true-negative FDG results.

SUV_{max} and MV were compared between FDG-PET true-positive and false-positive findings and according to the various histologic groups using the Wilcoxon test. To measure discriminatory accuracy of MV for diagnosing advanced neoplasia, receiver operating characteristic (ROC) analysis was performed, and the area under the ROC curve (AUROC) was calculated. Sensitivity, specificity, positive predictive value and negative predictive value were calculated. Statistical analysis was performed using JMP pro v10 software. *P* values < 0.05 were considered statistically significant.

Results

Study population

From 2005 to 2015, 100 consecutive patients with incidental colorectal uptake on FDG PET/CT were referred to our center for colonoscopy. Thirty patients were excluded for various reasons (► **Fig. 1**). Thus, 70 patients were included in the study.

Baseline demographic and clinical characteristics of the 70 patients are described in ► **Table 1**. The patients were mostly male (62.9%) and presented a median age of 67.2 [IQR, 57.5–74.4] years.

FDG PET/CT was performed for diagnosis, follow-up and staging in 29 (41.4%), 23 (32.9%) and 18 (25.7%) of patients, respectively. For follow-up and staging indications, the main primary diseases were as follows: hematologic tumor in 12 (29.3%) patients, head and neck cancer in 8 (19.5%) patients and lung cancer in 6 (14.6%) patients (► **Table 1**).

Colonoscopy characteristics

Colonoscopy was performed within a median period of 1.4 [0.7–3.4] months after FDG PET/CT by 18 different experienced endoscopists in our center.

► **Table 1** Patient characteristics at baseline.

Characteristics	Value
Age (years)	67.2 [57.5–74.4]
Sex (male)	44 (62.9)
¹⁸ F-FDG PET/CT indications	
▪ Diagnosis	29 (41.4)
▪ Follow-up of known carcinoma	23 (32.9)
▪ Staging of known carcinoma	18 (25.7)
Primary disease	
▪ Hematologic tumors	12 (29.3)
▪ Head and neck cancers	8 (19.5)
▪ Lung cancers	6 (14.6)
▪ Gynecological cancers (breast, uterine cervix)	6 (14.6)
▪ Urological cancers (bladder, kidney, prostate)	4 (9.8)
▪ Cancers of the digestive tract (esophagus, stomach)	3 (7.3)
▪ Melanoma	2 (4.9)
¹⁸ F-FDG PET/CT, fluorine-18-fluorodeoxyglucose positron emission tomography with computed tomography Categorical variables are expressed as numbers and percentages, and continuous variables are expressed as medians and interquartile ranges.	

Segments with FDG uptake were constantly assessed by endoscopy: 52 (74.3%) patients underwent colonoscopy under general anesthesia, and 18 patients with FDG uptake that was localized only in the rectosigmoid underwent flexible sigmoidoscopy. The right colon, transverse colon and left colon were not seen in 18, 16 and 13 patients, respectively. Thus, a total of 233 (82%) out of 280 segments were assessed by endoscopy.

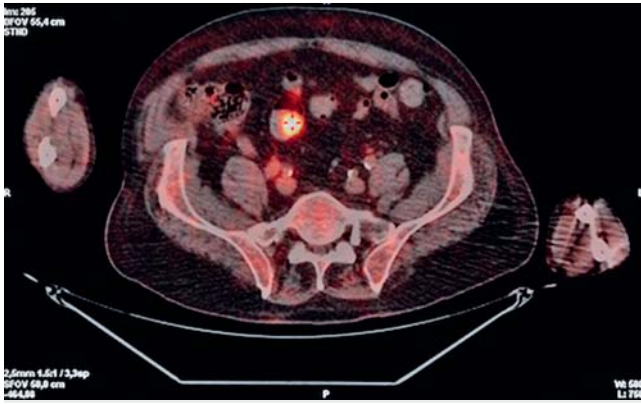
For bowel preparation, a standard 4L-PEG solution administered entirely the day before the colonoscopy was mainly used for total colonoscopy, and an enema was used for flexible sigmoidoscopy. The median overall Boston score for colonoscopy was 8 [6.5–9], and the median Boston score per segment was 3 [2–3].

Per-patient analysis

Of the 70 patients with focal FDG uptake, 46 patients (65.7%) had at least 1 concordant endoscopic lesion. No lesion at the localization of FDG uptake was seen by scope procedure in 24 patients.

Per-uptake analysis

Eighty-four foci of colonic FDG uptake were detected in the 70 patients (► **Fig. 2**). Among these 84 uptake sites, 43 (51.2%) were located in the rectosigmoid, 12 (14.3%) in the left colon, 9 (10.7%) in the transverse colon and 20 (23.8%) in the right colon. The proportions of true-positive (lesions found at colonoscopy at the same location) and false-positive (no lesion seen at colonoscopy) PET/CT findings were 65.5% (n = 55) and



► **Fig. 2** An incidental focal FDG-uptake that was found in the sigmoid in 1 study patient

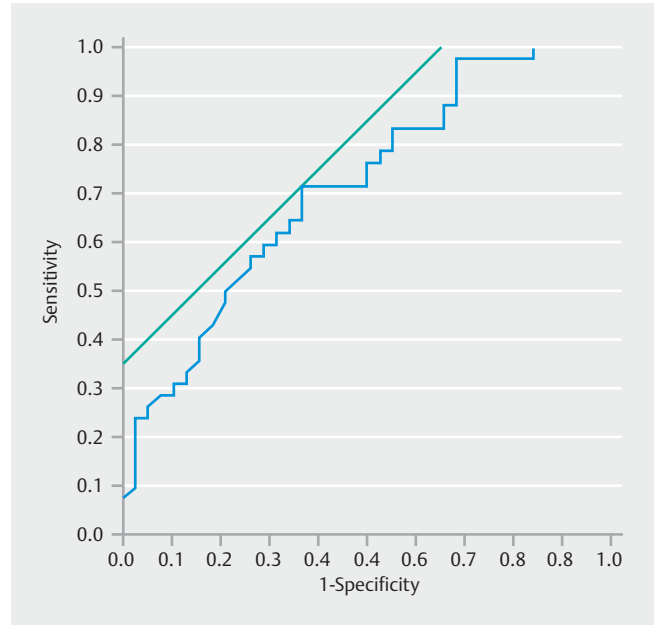
34.5% (n=29), respectively. In the true-positive group, 14 (25.5%) uptake sites corresponded to malignant lesions, 30 (54.5%) corresponded to HRP, 4 (7.3%) corresponded to LRP and 7 (12.7%) corresponded to NNL. Thus, incidental focal colonic FDG uptake corresponded to advanced neoplasia in more than half of the sites (52.4%).

FDG uptake SUV_{max} values ranged from 3.3 to 40.6. Median SUV_{max} values did not differ significantly between true-positive (8.9, [IQR, 6–13.3]) and false-positive (7.1, [IQR, 5.8–9.8]) findings ($P=0.27$). Similar results were obtained by calculating the colonic/liver SUV_{max} ratio (data not shown). MV30 values ranged from 1.08 to 68.7. Median MV30 values differed significantly between true-positive (5.5 cm^3 , [IQR, 3.3–10.9 cm^3]) and false-positive (9.7 cm^3 , [IQR, 5.2–40.8 cm^3]) findings ($P=0.015$) and between advanced neoplasia (5.0 cm^3 , [IQR, 2.9–9.7 cm^3]) and other endoscopic findings (9.4 cm^3 , [IQR, 5.2–39.8 cm^3]) ($P=0.001$). A ROC curve of the MV30 for the diagnosis of advanced neoplasia is shown in ► **Fig. 3**; the AUROC was 0.71. The sensitivity and specificity of MV30 for use in differentiating advanced neoplasia from other endoscopic findings were 71% and 63.2%, respectively, with the cutoff value of 7.7 cm^3 for the maximum sum of sensitivity and specificity (► **Fig. 3**). MV50 was found less accurate than MV30 for differentiating advanced neoplasia from other endoscopic findings (AUROC=0.63, sensitivity=64.3%, and specificity=58% when using the optimal cut off of 2.74).

Per-lesion analysis

One hundred seven lesions were found in 48 patients, and the median number of lesions seen at colonoscopy per patient was 1 [0–3]. Among the 107 lesions, 15 were malignant (14%), 48 were HRP (44.9%), 37 were LRP (34.6%), and 7 (6.4%) were NNL. Lesions were located especially (51.4%) in the rectosigmoid (► **Table 2**).

All 15 malignant lesions were FDG-avid (one patient had two synchronous adjacent cancers). Among the 48 HRP, 43 (89.6%) were FDG-avid and 5 (10.4%) were not. Among the 34 (31.8%) non-FDG-avid lesions, 5 corresponded to HRP (14.7%), 27 corresponded (79.4%) to LRP, and 2 corresponded (5.9%) to NNL. Non-FDG-avid lesions were located throughout the co-



► **Fig. 3** Receiver operating characteristic curve of the metabolic volume (MV30) for differentiating between advanced neoplasia and other findings at colonoscopy in FDG PET-positive areas.

lon, in the left (29.4%), transverse (32.3%) and right colon (20.6%), but were less frequent in the rectosigmoid (17.6%). All non-FDG-avid lesions were found in true-positive patients. Among the 5 HRP that were missed at colonoscopy, there were two adenomas with low-grade dysplasia, two adenomas with high-grade dysplasia and one sessile serrated polyp without dysplasia; all lesions were ≥ 10 mm.

The majority of HRP and LRP corresponded to adenomas; the exceptions were 6 sessile serrated polyps that were found in 2 patients. All sessile serrated polyps, except 1, were FDG-avid.

Per-segment analysis

Colorectal lesions were found in 83 of 233 (35.6%) segments seen at colonoscopy. The relationship between the colonoscopy and FDG PET/CT findings is outlined in ► **Table 3**. Thus, the true-positive, false-negative, false-positive, and true-negative FDG PET/CT results were distributed as follows: 21.5%, 14.2%, 11.5%, and 52.8%. The sensitivity, specificity, PPV and NPV of FDG PET/CT for use in the diagnosis of colorectal lesions were 60.2%, 82%, 64.9% and 78.8%, respectively. Corresponding figures for advanced neoplasia were 89.8%, 82.1%, 57.1% and 96.8%, respectively.

Discussion

In this cohort study of 70 patients representing 84 sites of incidental colonic focal FDG uptake, two-thirds (65.5%) of the foci corresponded to true-positive findings at colonoscopy and approximately half (52.4%) of the foci corresponded to advanced neoplasia at colonoscopy. Per-patient analysis confirms concordance between FDG uptake and presence of lesions at colonos-

► **Table 2** Characteristics of 107 lesions seen at colonoscopy.

Lesion groups	n	Location				Size (mm) median [IQR]	Macroscopic appearance					Histologic diagnosis
		RS	LC	TC	RC		TL	Pedunculated polyp	Sessile polyp	Flat polyp	Unknown	
Malignant lesions	15	11	0	1	3	30 [21–40] ¹	5	3	6	0	1	Invasive colorectal adenocarcinoma, n = 14 (13 patients) Lymphoma, n = 1
High-risk polyps	48	30	7	5	6	15 [11.5–20] ²	1	20	16	1	10	<i>In situ</i> colorectal adenocarcinoma, n = 4 Adenoma, n = 38 Sessile serrated polyp, n = 6
Low-risk polyps	37	8	10	9	10	4 [4–6] ¹	0	3	4	15	15	Adenoma, n = 37
Non-neoplastic lesions	7	6	0	1	0	6 [4–6] ³	0	1	0	4	2	Hyperplastic polyp, n = 4 Inflammatory lesion, n = 3

RS: rectosigmoid; LC, left colon; TC, transverse colon; RC, right colon; TL, tumor-Like
Continuous variables are expressed as medians and interquartile ranges (IQR).

¹ Missing data for 4 patients

² Missing data for 1 patient

³ Missing data for 2 patients

► **Table 3** Relationship between colonoscopy and ¹⁸F-FDG PET/CT findings: analysis by colonic segment.

Focal FDG-uptake at PET/CT	Lesion seen at colonoscopy	
	Yes	No
Yes	50	27
No	33	123
Total	83	150

¹⁸F-FDG PET/CT, fluorine-18-fluorodeoxyglucose positron emission tomography with computed tomography; FDG, fluorodeoxyglucose; PET/CT, positron emission tomography with computed tomography.

copy in two-thirds of patients. The proportion of true-positive findings reported in the literature varies widely from less than 50% to more than 90%; however, our results are consistent with most recent reports. Indeed, Keyzer et al. [21] showed that 61% of 107 FDG uptake foci corresponded to a lesion at colonoscopy and that true-positive findings were malignant or premalignant in 50.4% of cases. Similarly, pooled risk of malignant or premalignant lesions among the true-positive FDG uptakes was 68% according to a recent meta-analysis [6].

Our study highlighted a poor role of SUV_{max} values for differentiating between true-positive and false-positive findings. The value of SUV_{max} has often been recognized in the past as the best parameter for distinguishing false-positive FDG uptake from advanced neoplasia [28,29], although other studies did

not show any correlation between SUV_{max} values and the probability of finding endoscopic lesions [21,27]. Moreover, no validated SUV_{max} cut-off is available that enables the exemption of some patients from additional examinations. The optimal SUV_{max} threshold found by Luboldt et al. [28] was 5. However, their results cannot be generalized because 14 advanced neoplasias found in our work had SUV_{max} values ≤ 5. Metabolic volume has been suggested to be of potential interest in two recent studies [16,21]. Although the present study emphasizes the better accuracy of MV30 compared to SUV_{max} for differentiating true-positive from false-positive findings and for differentiating advanced neoplasia from other endoscopic findings, the sensitivity and specificity of MV30 remains unsatisfactory. Consequently, all patients with incidental colonic focal FDG uptake should be further examined by colonoscopy.

Our study showed that among the 107 lesions found at colonoscopy, 34 (31.7%) were found in colonic segments without FDG uptake. Although the majority of lesions missed by PET/CT corresponded to low-risk polyps or various non-relevant lesions, we observed presence of advanced neoplasia in 5 cases (complete colonoscopy was not performed for all cases). Characteristics of the lesions that were missed at colonoscopy have rarely been studied in detail until now. Weston et al. [22] found that colonoscopy revealed premalignant or malignant lesions in 8% of patients without any FDG uptake. These authors did not consider polypoid lesions smaller than 10 mm in their analysis, probably explaining our higher rate of false-negative lesions. On the other hand, Keyzer et al. [21] included polypoid lesions < 10 mm and found 57% of false-negative findings in a per-le-

sion analysis. The higher percentage of non-FDG-avid lesions in the latter study is probably explained by the higher proportion of complete colonoscopies. In addition, Lee et al. [26] showed that among 125 patients with focal FDG uptake confined to the left-sided colon, 8% had advanced neoplasms in the right side of the colon; they also showed that within the 62 patients who had FDG uptake sites localized in the right colon, 6 (9.7%) had advanced lesions in the left side of the colon. In any case, these results underline the significant risk of false-negative lesions, which suggests that clinicians should perform a colonoscopy and not a flexible sigmoidoscopy when patients are referred for the evaluation of incidental focal colorectal FDG uptake.

It is noteworthy that among the 107 lesions identified at colonoscopy in the current study, 6 (5.6%) corresponded to sessile serrated polyps, with dysplasia in 2 cases. All except 1 of these polyps were FDG-avid. Although this particular histopathological group has been previously mentioned in FDG studies [13], it is interesting to note that not only advanced adenomas but also sessile serrated polyps with dysplasia could be associated with FDG uptake. Because these lesions are at high risk of malignant transformation [30], early detection may improve patient outcome.

Because it is difficult to determine which lesion is responsible for FDG uptake in cases of adjacent lesions seen at colonoscopy, we performed a per-segment analysis in addition to the per-lesion analysis. Thus, we demonstrated that sensitivity, specificity, PPV and NPV of FDG-PET/CT for diagnosis of colorectal advanced neoplasia were 89.8%, 82.1%, 57.1% and 96.8%, respectively; these figures are higher than those found in previous studies [26].

The strengths of the current study are the size of the cohort (70 patients, 84 foci of FDG uptake), the examination of 83.2% of the whole colonic segments at colonoscopy and the use of a clinically relevant histopathological classification of polypoid lesions [31]. However, our study has some limitations. First, it was limited by its retrospective and monocentric design. Second, patient selection might have suffered from bias. Thus, this study included only patients with incidental colorectal FDG uptake who were referred for colonoscopy; we did not consider those patients who did not undergo colonoscopy. However, it is possible that physicians only referred to our center those colonoscopy patients whose treatment or cancer prognosis could have changed according to the colonoscopy findings. Furthermore, the aim of our study was not to evaluate the effect of the colonoscopy findings on the management of the primary cancer giving rise to FDG. Third, although the nuclear physician was blinded to endoscopic and histopathological findings, his interpretation might have been influenced by the knowledge of the presence of a colorectal FDG uptake in the initial report. Fourth, regarding to FDG PET/CT imaging no delayed acquisition and only unenhanced PET/CT scans were performed in our study like in numerous previous studies.

Conclusion

In conclusion, incidental focal colorectal FDG uptake on PET/CT imaging is associated with endoscopic lesions in two-thirds of cases, with a high rate of advanced neoplasms. Colonoscopy should be performed in every patient because no isotopic measurements enable accurate discrimination between true-positive and false-positive FDG findings. The proportion of non-FDG-avid lesions found in this study population suggests that complete colonoscopy be performed, although most of the non-FDG-avid lesions corresponded to non-relevant lesions.

Competing interests

None

References

- [1] Agress H, Cooper BZ. Detection of clinically unexpected malignant and premalignant tumors with whole-body FDG PET: histopathologic comparison. *Radiology* 2004; 230: 417–422
- [2] Even-Sapir E, Lerman H, Gutman M et al. The presentation of malignant tumours and pre-malignant lesions incidentally found on PET-CT. *Eur J Nucl Med Mol Imaging* 2006; 33: 541–552
- [3] Ozkol V, Alper E, Aydin N et al. The clinical value of incidental 18F-fluorodeoxyglucose-avid foci detected on positron emission tomography/computed tomography. *Nucl Med Commun* 2010; 31: 128–136
- [4] Ishimori T, Patel PV, Wahl RL. Detection of unexpected additional primary malignancies with PET/CT. *J Nucl Med* 2005; 46: 752–757
- [5] Beatty JS, Williams HT, Aldridge BA et al. Incidental PET/CT findings in the cancer patient: how should they be managed? *Surgery* 2009; 146: 274–281
- [6] Treglia G, Taralli S, Salsano M et al. Prevalence and malignancy risk of focal colorectal incidental uptake detected by 18F-FDG-PET or PET/CT: a meta-analysis. *Radiol Oncol* 2014; 48: 99–104
- [7] Şimşek FS, İspiroğlu M, Taşdemir B et al. What approach should we take for the incidental finding of increased 18F-FDG uptake foci in the colon on PET/CT? *Nucl Med Commun* 2015; 36: 1195–1201
- [8] Tatlıdil R, Jadvar H, Bading JR et al. Incidental colonic fluorodeoxyglucose uptake: correlation with colonoscopic and histopathologic findings. *Radiology* 2002; 224: 783–787
- [9] Salazar AndíaG, Prieto SorianoA, Ortega Candila et al. Clinical relevance of incidental finding of focal uptakes in the colon during 18F-FDG PET/CT studies in oncology patients without known colorectal carcinoma and evaluation of the impact on management. *Rev Esp Med Nucl E Imagen Mol* 2012; 31: 15–21
- [10] Gutman F, Alberini J-L, Wartski M et al. Incidental colonic focal lesions detected by FDG PET/CT. *Am J Roentgenol* 2005; 185: 495–500
- [11] Peng J, He Y, Xu J et al. Detection of incidental colorectal tumours with 18F-labelled 2-fluoro-2-deoxyglucose positron emission tomography/computed tomography scans: results of a prospective study. *Colorectal Dis Off J Assoc Coloproctology G B Irel* 2011; 13: e374–378
- [12] Treglia G, Calcagni ML, Rufini V et al. Clinical significance of incidental focal colorectal (18)F-fluorodeoxyglucose uptake: our experience and a review of the literature. *Colorectal Dis Off J Assoc Coloproctology G B Irel* 2012; 14: 174–180

- [13] Fuertes J, Montagut C, Bullich S et al. Incidental focal uptake in colorectal location on oncologic FDG PET and PET/CT studies: histopathological findings and clinical significances. *Rev Esp Med Nucl E Imagen Mol* 2015; 34: 95–101
- [14] Rainis T, Kaidar-Person O, Keran D et al. Correlation between incidental FDG PET/CT colorectal observations and endoscopic and histopathological results. *Oncol Lett* 2014; 7: 479–482
- [15] Purandare NC, Gawade SK, Puranik AD et al. Etiology and significance of incidentally detected focal colonic uptake on FDG PET/CT. *Indian J Radiol Imaging* 2012; 22: 260–266
- [16] Oh J-R, Min J-J, Song H-C et al. A stepwise approach using metabolic volume and SUVmax to differentiate malignancy and dysplasia from benign colonic uptakes on 18F-FDG PET/CT. *Clin Nucl Med* 2012; 37: e134–140
- [17] Putora PM, Müller J, Borovicka J et al. Relevance of incidental colorectal FDG-PET/CT-enhanced lesions. *Onkologie* 2013; 36: 200–204
- [18] Fleming M, Knox M, Kennedy MJ. Incidental detection of colorectal malignancies using FDG PET-CT. *Ir Med J* 2013; 106: 151–153
- [19] Kei PL, Vikram R, Yeung HWD et al. Incidental finding of focal FDG uptake in the bowel during PET/CT: CT features and correlation with histopathologic results. *AJR Am J Roentgenol* 2010; 194: W401–406
- [20] Van Hoeij FB, Keijsers RGM, Loffeld BC et al. Incidental colonic focal FDG uptake on PET/CT: can the maximum standardized uptake value (SUVmax) guide us in the timing of colonoscopy? *Eur J Nucl Med Mol Imaging* 2015; 42: 66–71
- [21] Keyzer C, Dhaene B, Blocklet D et al. Colonoscopic findings in patients with incidental colonic focal FDG uptake. *AJR Am J Roentgenol* 2015; 204: W586–591
- [22] Weston BR, Iyer RB, Qiao W et al. Ability of integrated positron emission and computed tomography to detect significant colonic pathology. *Cancer* 2010; 116: 1454–1461
- [23] Abouzied MM, Crawford ES, Nabi HA. 18F-FDG Imaging: pitfalls and artifacts. *J Nucl Med Technol* 2005; 33: 145–155
- [24] Shreve PD, Anzai Y, Wahl RL. Pitfalls in oncologic diagnosis with FDG PET imaging: physiologic and benign variants. *RadioGraphics* 1999; 19: 61–77
- [25] Cho SH, Kim SW, Kim WC et al. Incidental focal colorectal 18F-fluorodeoxyglucose uptake on positron emission tomography/computed tomography. *World J Gastroenterol WJG* 2013; 19: 3453–3458
- [26] Lee C, Koh S-J, Kim JW et al. Incidental colonic 18F-fluorodeoxyglucose uptake: do we need colonoscopy for patients with focal uptake confined to the left-sided colon? *Dig Dis Sci* 2013; 58: 229–235
- [27] Lai EJ, Calderwood AH, Doros G et al. The Boston Bowel Preparation Scale: a valid and reliable instrument for colonoscopy-oriented research. *Gastrointest Endosc* 2009; 69: 620–625
- [28] Luboldt W, Volker T, Wiedemann B et al. Detection of relevant colonic neoplasms with PET/CT: promising accuracy with minimal CT dose and a standardised PET cut-off. *Eur Radiol* 2010; 20: 2274–2285
- [29] Na S-Y, Kim K-J, Han S et al. Who should undergo a colonoscopy among patients with incidental colon uptake on PET-CT? *Scand J Gastroenterol* 2015; 50: 1045–1053
- [30] Erichsen R, Baron JA, Hamilton-Dutoit SJ et al. Increased risk of colorectal cancer development among patients with serrated polyps. *Gastroenterology* 2016; 150: 895–902.e5
- [31] Atkin W, Valori R, Kuipers E et al. European guidelines for quality assurance in colorectal cancer screening and diagnosis. First Edition – Colonoscopic surveillance following adenoma removal. *Endoscopy* 2012; 44: SE151–SE163