

Intramedullary nailing for impending or pathologic fracture of the long bone: titanium vs carbon fiber peek nailing

Elisa Pala, Alberto Procura, Giulia Trovarelli, Antonio Berizzi and Pietro Ruggieri¹

Department of Orthopedics and Orthopedic Oncology, University of Padova, Padova, Italy

Correspondence should be addressed to P Ruggieri

Email
pietro.ruggieri@unipd.it

- **Purpose:** The aim of this study is to compare titanium vs carbon fiber intramedullary (IM) nailing in terms of response to radiotherapy, local control of the disease, time of surgery, fluoroscopy exposure, and complications.
- **Methods:** From 2015 to 2021, 52 impending or pathologic fractures were treated with IM nailing in 47 patients: 18 males and 29 females with a mean age of 73. Titanium nails were used in 27 cases: femur (17 cases), humerus (8 cases), and tibia (2 cases). Carbon fiber nails were used in 25 cases: femur (17 cases), humerus (7 cases), and tibia (1 case).
- **Results:** At a mean follow-up of 8.4 months, most patients died from the disease (63.4%). Fracture healing without osteolysis progression was present in 52% of titanium nailing at a mean time of 6 months and in 53% of carbon fiber nails at a mean time of 4.6 months. No statistically significant difference has been shown in terms of healing ($P=0.5$), intraoperative fluoroscopy ($P=0.7$), and time of surgery in femoral nailing ($P=0.6$), while a significantly lower surgical time for carbon fiber humeral nailing ($P=0.01$) was found. Two breakages of carbon fiber femoral nails were observed, and both were treated with revision with modular tumor megaprosthesis.
- **Conclusions:** Our results suggest that surgical time and fluoroscopy exposure are not longer for carbon fiber nails compared to titanium ones. Healing seems to be faster in carbon fiber nails. Further clinical studies are needed to clarify the long-term outcomes of these implants.

Keywords

- ▶ carbon fiber nail
- ▶ pathologic fracture
- ▶ bone metastasis

EFORT Open Reviews
(2022) 7, 611–617

Introduction

Bones are a frequent location of metastases from carcinomas; the most common sites are the spine and pelvis, followed by the long bones, especially the proximal femur (1). All types of malignant tumors have the potential to metastasize to the bone. Still, the most frequent histotypes are breast cancer, pulmonary cancer (non-small cell lung cancer), thyroid, and prostatic cancer (1). These four histotypes account for 80% of all bone metastases (1).

There are various parameters to consider when approaching a patient with bone metastasis, such as age, performance status, number and site of metastases, the free interval of disease, histotypes of the primary tumor, and expected survival (2, 3). The treatment of long bone metastases must consider all of these to choose the most effective procedure (2, 3, 4). Conservative treatment can

be an option in very selected cases when the patient has a short life expectancy and poor general condition that contraindicates every type of surgery. Wide bone resection and reconstruction with megaprotheses are indicated in young patients with good prognosis and health conditions, with single or oligo metastasis, favorable histotype, and long disease-free interval (1). When all of these conditions are present, an aggressive surgical approach is justified by the evidence of better oncologic outcomes in the mid and long term (5, 6, 7, 8, 9, 10, 11, 12, 13, 14). In most recent years, many patients have been treated with bone resection and tumor prosthesis. This upsurge is due to the development of new effective medical therapies, improving patients' survival, associated with satisfactory functional results, and a low incidence of complications of this type of reconstruction. Another treatment option for long bone metastases is intramedullary (IM) nailing. Unfortunately, it is indicated in treating old patients

with poor prognosis, multiple metastases, unfavorable histotype, and short disease-free interval. Thus, it is often considered a palliative treatment since most patients have a life expectancy shorter than 3–6 months (14, 15, 16). In this setting, the primary indication of IM nailing is the treatment of diaphyseal lesions.

Classic titanium nails have excellent mechanical resistance and still represent an option when approaching a pathologic or impending fracture of long bones (14, 15, 16, 17). However, titanium nails show some limits, especially during the follow-up of patients. First, titanium is a radiopaque metal that can interfere with the correct visualization of bone healing at the x-rays or CT scans. Moreover, because it is a paramagnetic metal, it significantly interferes with MRI, thus impeding a good visualization of the pathologic tissue (18).

However, recent studies have proposed Carbon Fibre Reinforced Polyaryl-Ether-Ether-Ketone (CFR-PEEK) nails as an alternative to titanium implants. Indeed, due to their radiolucency, there is an imaging artifact reduction. Consequently, it is possible to better visualize the bone, permitting a more reliable and effective radiation dose delivery (18). The prominent disadvantages of these implants seem to be the longer surgical time and fluoroscopy exposure required. Some authors have studied the CFR-PEEK nailing in oncologic and orthopedic surgeries (19, 20, 21, 22); however, literature comparing CFR-PEEK nailing with titanium nailing is lacking (23).

This retrospective study aims to compare titanium vs CFR-PEEK nailing in terms of (i) time of surgery and fluoroscopy exposure, (ii) incidence and types of complications, and (iii) response to radiotherapy (callus formation and local control of the disease).

Materials and methods

All oncologic patients treated with IM nailing at our Orthopedic Oncologic Clinic from October 2015 to September 2021 were included.

This study was approved on October 23, 2019 (IRB approval no. 1269).

A total of 47 patients were included: 18 males and 29 females with a mean age of 73 (range: 51.4–91.9 years old) (Table 1). Five patients presented multiple lesions requiring nailing: 52 IM nail fixations were performed. Indications to treatment were (i) impending fracture (21 cases) or pathologic fracture (30 cases) due to long bone metastatic lesions or (ii) post-radiation fracture in patients previously treated for soft tissue sarcoma (1 case). We decided to also include the last patient in the study because post-radiation fracture has a high risk of non-union and needs a careful follow-up.

The long bone treated with IM nailing was the femur (34 cases), followed by the humerus (15 cases) and tibia

Table 1 Population analysis.

Data	Titanium	Carbon	Total
Age, years			
Mean ± s.d.	72.9 ± 6.7	72.8 ± 11.9	72.8 ± 9.6
Range	63.7–91.9	51.4–87.1	51.4–91.9
Gender			
Male	9	9	18
Female	15	14	29
Type of cancer/lesion			
Breast			13
Lung			9
MM			6
Renal			6
Urothelial			3
Liver			2
Gastrointestinal			2
Prostate			1
Endometrial			1
Pancreas			1
Merkel's cell carcinoma			1
Colangiocarcinoma			1
Hyatrogenic fracture post-irradiation			1
Total			41
Site			
Femur	17	17	34
Humerus	8	7	15
Tibia	2	1	3
Pathological fracture			
Actual	16	15	31
Impending	11	10	21

(3 cases) (Table 1). In metastatic patients, the diagnoses of the primary tumor were: breast cancer (13), lung cancer (9), multiple myeloma (6), renal cancer (6), urothelial cancer (3), hepatocarcinoma (2), gastrointestinal cancer (2), and endometrial cancer, prostate cancer, pancreas cancer, Merkel's cells carcinoma, and cholangiocarcinoma in one each. We decided to include patients with multiple myeloma because they can be comparable to metastatic bone patients regarding treatment strategies and outcomes (24). The patient with post-radiation fracture was treated 3 years before with excision and two cycles of adjuvant radiotherapy for a liposarcoma of the thigh.

Patients were divided into two groups. Group A included patients who received titanium IM nails; Group B included patients treated with CFR-PEEK nails. In Group A, 27 procedures were performed: 17 in the femur, 8 in the humerus, and 2 in the tibia (Figs 1 and 2). In Group B, 25 nails were implanted: 17 in the femur, 7 in the humerus, and 1 in the tibia (Table 1).

After surgery, all patients can walk with complete weight-bearing and crutches from the first postoperative days. An expert radiotherapist evaluated patients to start radiotherapy after the complete wound healing. Follow-up was performed with x-rays of the operated limb and a clinical evaluation at 1 month, and then every 3 months. For all these patients, the data analyzed were time of surgery and fluoroscopy exposure, complications, the dose of radiotherapy, oncologic follow-up of patients,

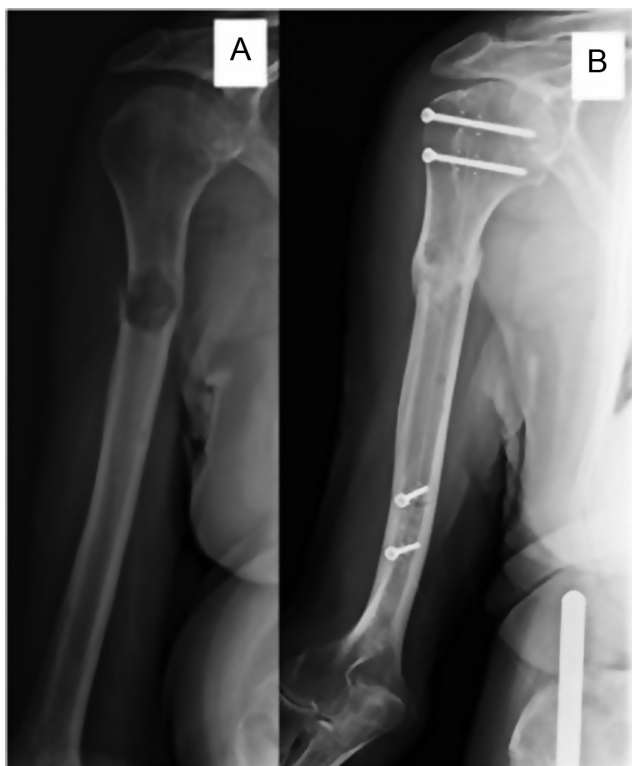

Figure 1
 (A) An 86-year-old male with pathological fracture of the right humeral diaphysis from multiple myeloma treated with a long CFR-PEEK humeral nail. Postoperative radiotherapy 20 Gy. (B) X-ray after 6 months from surgery and adjuvant radiation therapy showing complete healing of the fracture. AWD after 32 months from humeral surgery.

and response to radiotherapy (fracture consolidation and local control of the disease).

Data were tabulated using a spreadsheet (Microsoft Excel). Statistical analysis was performed with Kaplan–Meier curves and significance was defined as a *P*-value of 0.05 or less. Statistical analysis (25) was performed using the MedCalc Software Version 11.1 (MedCalc Software Broekstraat 52, Mariakerke, Belgium).

Results

Oncologic follow-up

At a mean follow-up of 8.4 months (min 0.33–max 2.7 years), 13 patients were alive with Disease (AWD), and 33 were dead with disease; 16 patients died within 2 months. Only the patient treated for post-radiation fracture resulted free of disease.

After surgery, 88% (47/52) of nailing was followed by adjuvant radiotherapy. One patient refused any adjuvant therapy (Group A), while 3 patients died before the start of treatment (Group B). The radiotherapy dose was at least 8 Gy (min 8–max 20 Gy). The patient who had treatment for post-radiation fracture did not necessitate adjuvant radiotherapy.

Time of surgery and fluoroscopy exposure

The overall mean duration of surgery was 105 min (min 35–max 187 min). In femoral nailing, the mean intervention time was 96.6 min (min 35–max 142 min) in Group A, and 111.0 min (min 80–max 183 min) in Group B, without a statistically significant difference ($P=0.323$). In humeral nailing, the mean surgery time was 119.3 min (min 69–max 101 min) in Group A, and 78.4 min (min 75–max 175 min) in Group B, with a significantly lower surgical time for carbon fiber nails ($P=0.014$).

The overall mean time of fluoroscopy exposure was 107.4 s in Group A and 102.6 s in Group B. In femoral nailing, the mean time of fluoroscopy was 132.5 s (min 15–max 270 s) in Group A, and 150 s (min 100–max 254 s) in Group B, without a significant difference ($P=0.573$). In humeral nailing, the mean time of fluoroscopy was 117.7 s (min 10–max 215 s) in Group A, and 108.0 s (min 92–max 150 s) in Group B, without significant differences ($P=0.780$) (Table 2).

Complications

Overall, five complications were registered: one in Group A and four in Group B (Table 3).

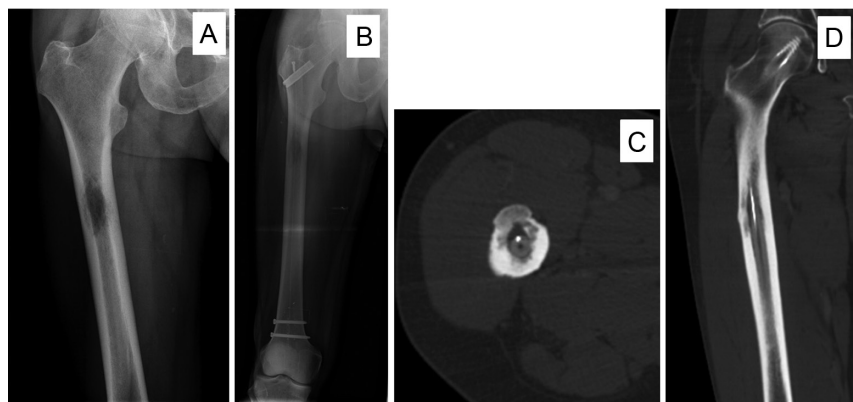


Figure 2
 (A) A 63-year-old male with right femur diaphyseal metastasis from lung cancer. X-rays show an osteolytic lesion in the proximal third of the femoral diaphysis. The patient underwent radiation therapy (20 Gy). (B) X-rays after 7 months showed complete healing of the lesion. (C and D) CT scan at 7 months follow-up also showed good results. The patient is AWD after 16 months after the last surgery.

Table 2 Time of surgery and fluoroscopy.

	Femur		Humerus	
	Surgery (min)	Fluoroscopy (s)	Surgery (min)	Fluoroscopy (s)
Titanium	96.6 (35–142)	132.5 (15–270)	119.3 (69–101)	117.7 (10–215)
Carbon fiber	111.0 (80–183)	150.0 (100–254)	78.4 (75–175)	108.0 (92–150)
P-value	0.323	0.573	0.014	0.780

A trochanteric fracture (Group B) occurred intraoperatively but did not require further intervention.

Two complications were early postoperative: one post-surgical hematoma (Group B) treated with a surgical drain during the second postoperative day and one radial nerve deficit (Group A) treated with physical therapy and a wrist-hand splint.

Two patients had implant failure (Group B). Nail breakage at the site of the original pathologic fracture occurred in the absence of trauma in one patient 1 month after treating subtrochanteric pathologic fracture due to breast cancer metastasis and in the other one, 2 months after treatment of the post-radiation fracture. Both cases were treated with nail removal, proximal femur resection, and reconstruction with modular prosthesis (Fig. 3). We did not observe any implant failure in Group A.

Response to radiotherapy

We considered fracture consolidation with callus osseous formation and absence of osteolysis progression as radiographic signs of healing and local control in response to radiotherapy.

Thus, we performed this evaluation only in cases with at least 2 months of follow-up and, therefore, about 1 month after finishing radiotherapy. Thirty-six lesions were included: 21 of Group A and 15 of Group B.

Healing was present in 19/36 (52.7%) lesions at a mean time of 5.1 months (min 2–max 11 months). Healing occurred in 11/21 cases (52.3%) at a mean time of 6 months (min 2–max 11 months) in Group A and in 8/15 lesions (53.3%) at a mean time of 4.6 (min 2–max 8) in Group B (Table 4). There was no statistical difference in the average time of healing between the two groups (P=0.519). No patients showed radiographic progression of osteolysis; thus, no cases of

local progression of the disease were registered in both groups.

Discussion

Even if the treatment with tumor resection and prosthetic reconstruction increases in patients affected by long bone metastasis, IM nail is still indicated. The indications for IM nail are poor patient prognosis, multiple lesions, unfavorable histotype, short disease-free interval, and bad general condition, mostly in lesions in the middle shaft of the diaphysis (26, 27).

It has been a short time since CFR-PEEK has been available as a material for orthopedic implants. Collis *et al.*, in 2011, first described a case of a patient affected by a humeral location of melanoma, treated with a CFR-PEEK nail (22). After that, few authors analyzed CFR-PEEK implants in oncologic surgery (19, 20, 21), while their use in traumatology and orthopedic surgery is poorly documented (23, 31).

The main advantage of CFR-PEEK implants is their radiolucency. It permits avoiding artifacts during imaging exams (18, 30): x-rays and CT scans are of better quality, and it is possible to visualize fracture healing during the follow-up. Moreover, because carbon is non-magnetic, the quality of the images in MRI is considerably higher without artifacts, permitting a better evaluation of the pathologic tissue (23, 30) (Fig. 4). The main drawback of radiolucency of CFR-PEEK nails may be the more complex identification of holes leading to difficult perforation and insertion of the distal locking screws with consequent longer operative time and fluoroscopy exposure (). Since CFR-PEEK implants have a low diffraction power, thanks to the low atomic number of carbon, they offer benefits for radiotherapy (26). Indeed, the radiation dose is more reliable and more effective delivery to an osseous target

Table 3 Complications.

Nail	Complication	Treatment
Titanium	Intraoperative Radial nerve deficit (1)	Physiotherapy and splint
	Postoperative None	
Carbon fiber	Intraoperative Greater throcanter fracture (1)	None
	Postoperative Deep hematoma (1)	
	Breakage of the nail (2)	

Table 4 Patients with at least 2 months of follow-up that showed radiographic signs of healing.

Nail	Healing	%	Time in months (min–max)
Titanium	11/21	52.3	6 (2–11)
Carbon fiber	8/15	53.3	4.6 (2–8)
Total	19/36	52.7	5.1 (2–11)

volume, avoiding irradiation of adjacent tissues and potentially having a better result in controlling the local progression of the tumor (18, 26, 30). Other features of CFR-PEEK implants are the low modulus of elasticity and high fatigue properties. However, controversies are reported considering their potential effect on accelerating bone healing (23, 31). Ziran *et al.* (23) analyzed the healing of diaphyseal tibia fractures; they reported that using CFR-PEEK nails resulted in faster healing when compared with titanium nails. On the contrary, Fragomen *et al.* (31) assessed a high rate of implant failure and non-union (31% of non-union) using CFR-PEEK nails following osteotomies to correct lower limb deformities. In the same series, the two patients treated with CFR-PEEK nails for tibial fracture did not develop any complications, and the fracture healed. The authors suggested that the increased elasticity of the carbon fiber polymer may allow significant motion at the osteotomy site with delayed union and non-union in treating long bone deformities with osteotomies (31).

The reported advantages of CFR-PEEK in terms of radiolucency make CFR-PEEK nails a new and promising alternative to classic titanium nails in the treatment of patients with pathologic fractures.

Some authors have studied the CFR-PEEK nailing in oncologic and orthopedic surgeries (19, 20, 21, 22); however, literature comparing CFR-PEEK nailing with titanium nailing is lacking (23). We performed a retrospective analysis of all oncologic patients treated with

IM nailing at our Institute, comparing titanium vs CFR-PEEK nailing in terms of the time of surgery and fluoroscopy exposure, complications, and response to radiotherapy.

Piccioli *et al.* in 2017 published the most extensive multicentric study on CFR-PEEK nailing for metastatic or primary bone diseases (29). In their experience with 53 CFR-PEEK nails, the average surgical procedure time was 69 min, and the mean intraoperative fluoroscopy exposition was 96 s. In our series, using CFR-PEEK nails, the mean duration of surgery was 111 min in the femur and 78.4 min in the humerus. Moreover, the implantation time of CFR-PEEK nails was not significantly longer than titanium nails in the femur ($P= 0.323$), while it resulted shorter in the humerus than titanium ones ($P=0.014$). However, the bias consequent to the limited number of humeral nails and the low power of the statistical analysis must be considered. Fluoroscopy time was similar for titanium and CFR-PEEK nails in the femur ($P= 0.573$) and the humerus ($P=0.780$). The learning curve of our surgeons could explain this high surgical time for the insertion of CFR-PEEK nails; in fact, the surgical times progressively decreased in the last procedures. After the learning curve, radiolucency is not an obstacle for surgery. Indeed, the presence of radio-opaque markers allows good visualization of the entry holes. Thus, identifying the holes and adjusting the drill is easy.

Complications with these newer nails are reported to be similar to the ones with titanium nails (20, 21, 29). Takashima *et al.* (21) reported their experience in treating proximal femur fracture with CFR-PEEK nails; no complications were described, and consolidation of the fracture was noted in 95% (19/20) of patients. Piccioli *et al.* (29) reported 13 complications: only 2 major complications occurred late postoperatively (1 stress fracture proximally to the distal static screw and 1 screw loosening). In the current series, only two

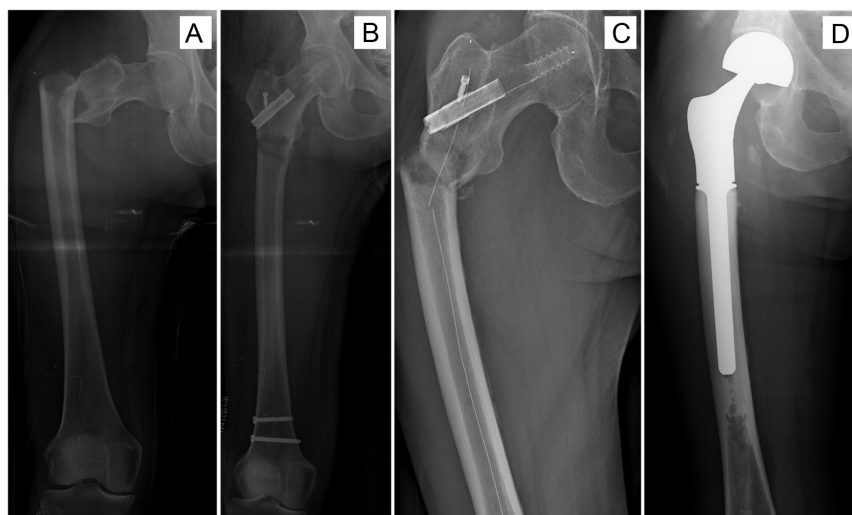

Figure 3

(A) A 66-year-old female with multiple metastases from breast cancer; pathologic subtrochanteric fracture of the right femur. (B) Postoperative x-ray shows reduction and fixation with a long CFR-PEEK nail. (C) Two months postoperative breakage of the nail. (D) The patient was treated with nail removal, resection of the proximal femur, reconstruction with modular proximal femur tu-mor megaprosthesis with cemented stem, and postoperative radiotherapy (8 Gy). AWD 12 months after the last surgery.

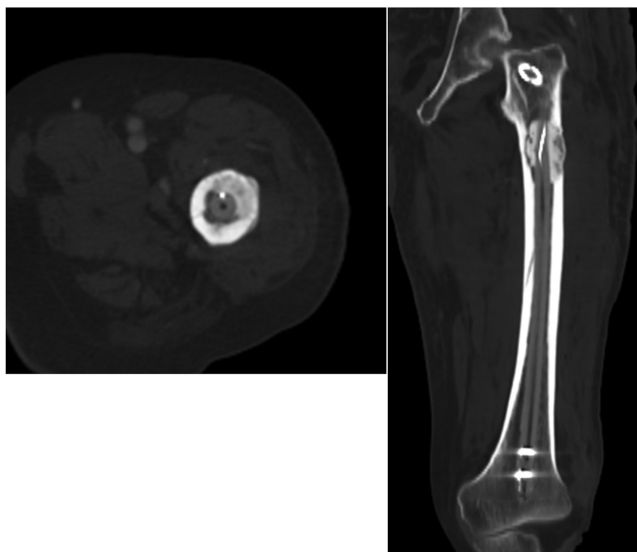


Figure 4

A 56-year-old male with multiple metastases from clear cell renal carcinoma; impending fracture of the proximal left femur treated with CFR-PEEK nailing. Pictures show the axial and coronal view of the CT scan: the nail is radiotransparent, allowing a good visualization of the fracture and surrounding bone, while cephalic and distal screws are radio-opaque. In the subtrochanteric region, cement augmentation after curettage of the metastasis.

major complications occurred, both in the group of patients treated with CFR-PEEK nails. The nail's breakage at the original pathologic fracture site emerged without trauma, requiring implant removal, resection of the proximal femur, and modular prosthetic reconstruction. It is hard to say that these complications are related to implant material; carbon fiber nails, as reported in the literature, have a higher resistance to fatigue fracture than titanium nails (23). Moreover, these two patients did not report any trauma or causes that can explain breakage except for missing consolidation of the femur fracture; an analysis of the implants reported no defect of fabrications; for these reasons, we have no explanation for these complications.

Fracture healing and disease local control are proof of response to radiotherapy. For example, Piccioli *et al.* (29) reported signs of the radiographic union in 14 (26.4%) patients at an average of 16 weeks; however, 8 (15%) cases of local progression ensued. In our series, response to radiotherapy was evaluated in 36 patients. Signs of healing were present in 53.3% of cases at a mean time of 4.6 months in the CFR-PEEK group and 52.3% of cases at 6 months in the titanium group. The incidence of healing in the CFR-PEEK group seems higher than in the titanium group, even if a more extensive series is needed for confirmation. No cases of local progression occurred in both groups.

The main limitation of this study is the impossibility of comparing homogeneous populations since all patients treated are oncologic patients, with a heterogeneity of diagnosis. Moreover, the short survival of these patients is a strong bias, and this must be taken into consideration. The mean follow-up in the whole population was 8.4 months; only 14 patients were alive at the last follow-up.

Conclusion

CFR-PEEK nails seem to be a good solution in patients with pathologic or impending fractures of the long bones. Indeed, their radiolucency allows better visualization of the pathologic site and minor interference with adjuvant radiotherapy, leading to more proper targeting and dosing volume. It could explain why signs of healing seem to be faster with CFR-PEEK nails than with titanium ones. In addition, our results suggest that surgical time and fluoroscopy exposure are no longer with CFR-PEEK nails compared to titanium ones.

The use of CFR-PEEK nails could also be enlarged in traumatology surgery; however, the long-term resistance and complications are unknown since they, until now, have been mainly used in a population of patients with a short life expectancy. Therefore, further clinical studies are needed to clarify the long-term outcomes of these implants.

ICMJE Conflict of Interest Statement

Pietro Ruggieri is Consultant and Designer for Stryker and Exactech. Each author certifies that he or she has no commercial associations (e.g. consultancies, stock ownership, equity interest, patent/licensing arrangements, etc.) that might pose a conflict of interest in connection with the submitted article.

Funding Statement

This work did not receive any specific grant from any funding agency in the public, commercial, or not-for-profit sector.

References

1. Hage WD, Aboulaflia AJ & Aboulaflia DM. Incidence, location and diagnostic evaluation of metastatic bone disease. *Orthopedic Clinics of North America* 2000 **31** 515–528. ([https://doi.org/10.1016/s0030-5898\(05\)70171-1](https://doi.org/10.1016/s0030-5898(05)70171-1))
2. Angelini A, Trovarelli G, Berizzi A, Pala E, Breda A, Maraldi M & Ruggieri P. Treatment of pathologic fractures of the proximal femur. *Injury* 2018 **49** (Supplement 3) S77–S83. (<https://doi.org/10.1016/j.injury.2018.09.044>)
3. Cappellari A, Trovarelli G, Crimi A, Pala E, Angelini A, Berizzi A & Ruggieri P. New concepts in the surgical treatment of actual and impending pathological fractures in metastatic disease. *Injury* 2020 In press. (<https://doi.org/10.1016/j.injury.2020.11.025>)
4. Capanna R, Piccioli A, Di Martino A, Daolio PA, Ippolito V, Maccauro G, Piana R, Ruggieri P, Gasbarrini A, Spinelli MS, *et al.* Management of long bone metastases: recommendations from the Italian Orthopaedic Society (SIOT) bone metastasis study group. *Expert Review of Anticancer Therapy* 2014 **14** 1127–1134. (<https://doi.org/10.1586/14737140.2014.947691>)

- 5. Coleman RE.** Metastatic bone disease: clinical features, patho-physiology and treatment strategies. *Cancer Treatment Reviews* 2001 **27** 165–176. (<https://doi.org/10.1053/ctrv.2000.0210>)
- 6. Wood TJ, Racano A, Yeung H, Farrokhyar F, Ghert M & Dehesi BM.** Surgical management of bone metastases: quality of evidence and systematic review. *Annals of Surgical Oncology* 2014 **21** 4081–4089. (<https://doi.org/10.1245/s10434-014-4002-1>)
- 7. Scolaro JA & Lackman RD.** Surgical management of metastatic long bone fractures: principles and techniques. *Journal of the American Academy of Orthopaedic Surgeons* 2014 **22** 90–100. (<https://doi.org/10.5435/JAAOS-22-02-90>)
- 8. Wedin R & Bauer HCF.** Surgical treatment of skeletal metastatic lesions of the proximal femur: endoprosthesis or reconstruction nail? *Journal of Bone and Joint Surgery: British Volume* 2005 **87** 1653–1657. (<https://doi.org/10.1302/0301-620X.87B12.16629>)
- 9. Gao H, Liu Z, Wang B & Guo A.** Clinical and functional comparison of endoprosthesis replacement with intramedullary nailing for treating proximal femur metastasis. *Chinese Journal of Cancer Research* 2016 **28** 209–214. (<https://doi.org/10.21147/j.issn.1000-9604.2016.02.08>)
- 10. Katagiri H, Takahashi M, Wakai K, Sugiura H, Kataoka T & Nakanishi K.** Prognostic factors and scoring system for patients with skeletal metastasis. *Journal of Bone and Joint Surgery: British Volume* 2005 **87** 698–703. (<https://doi.org/10.1302/0301-620X.87B5.15185>)
- 11. Biermann JS, Holt GE, Lewis VO, Schwartz HS & Yaszemski MJ.** Metastatic bone disease: diagnosis, evaluation, and treatment. *Journal of Bone and Joint Surgery: American Volume* 2009 **91** 1518–1530.
- 12. Cheung FH.** The practicing orthopedic surgeon's guide to managing long bone metastases. *Orthopedic Clinics of North America* 2014 **45** 109–119. (<https://doi.org/10.1016/j.ocl.2013.09.003>)
- 13. Capanna R & Campanacci DA.** The treatment of metastases in the appendicular skeleton. *Journal of Bone and Joint Surgery: British Volume* 2001 **83** 471–481. (<https://doi.org/10.1302/0301-620x.83b4.12202>)
- 14. Ruggieri P, Mavrogenis AF, Casadei R, Errani C, Angelini A, Calabrò T, Pala E & Mercuri M.** Protocol of surgical treatment of long bone pathological fractures. *Injury* 2010 **41** 1161–1167. (<https://doi.org/10.1016/j.injury.2010.09.018>)
- 15. Moholkar K, Mohan R & Grigoris P.** The long gamma nail for stabilisation of existing and impending pathological fractures of the femur: an analysis of 48 cases. *Acta Orthopaedica Belgica* 2004 **70** 429–434.
- 16. Maccauro G, Muratori F, Liuzza F, Rossi B & Logroscino CA.** Anterograde femoral nail for the treatment of femoral metastases. *European Journal of Orthopaedic Surgery and Traumatology* 2008 **18** 509–513. (<https://doi.org/10.1007/s00590-008-0343-4>)
- 17. Streitbürger A, Harges J, Nottrott M & Guder WK.** Reconstruction survival of segmental megaendoprostheses: a retrospective analysis of 28 patients treated for intercalary bone defects after musculoskeletal tumor. *Archives of Orthopaedic and Traumatic Surgery* 2022 **142** 41–56. (<https://doi.org/10.1007/s00402-020-03583-4>)
- 18. Zimel MN, Hwang S, Riedel ER & Healey JH.** Carbon fiber intramedullary nails reduce artifact in postoperative advanced imaging. *Skeletal Radiology* 2015 **44** 1317–1325. (<https://doi.org/10.1007/s00256-015-2158-9>)
- 19. Maniscalco P, Caforio M, Groppi G, Vallisa D & Cavanna L.** The carbon fiber intramedullary nail in pathological humeral shaft fractures: two case reports. *Jacobs Journal of Orthopedics and Rheumatology* 2015 **1** 008.
- 20. Hak DJ, Mauffrey C, Seligson D & Lindeque B.** Use of carbon-fiber-reinforced composite implants in orthopedic surgery. *Orthopedics* 2014 **37** 825–830. (<https://doi.org/10.3928/01477447-20141124-05>)
- 21. Takashima K, Nakahara I, Uemura K, Hamada H, Ando W, Takao M & Sugano N.** Clinical outcomes of proximal femoral fractures treated with a novel carbon fiber-reinforced polyetheretherketone intramedullary nail. *Injury* 2020 **51** 678–682. (<https://doi.org/10.1016/j.injury.2020.01.007>)
- 22. Collis PN, Clegg TE & Seligson D.** The invisible nail: a technique report of treatment of a pathological humerus fracture with a radiolucent intramedullary nail. *Injury* 2011 **42** 424–426. (<https://doi.org/10.1016/j.injury.2010.10.012>)
- 23. Ziran BH, O'Pry EK & Harris RM.** Carbon fiber-reinforced PEEK versus titanium tibial intramedullary nailing: a preliminary analysis and results. *Journal of Orthopaedic Trauma* 2020 **34** 429–433. (<https://doi.org/10.1097/BOT.0000000000001756>)
- 24. Mavrogenis AF, Angelini A, Pala E, Zinzani P & Ruggieri P.** The role of surgery for haematologic neoplasms of bone. *Acta Orthopaedica Belgica* 2012 **78** 382–392.
- 25. Kaplan EL & Meier P.** Nonparametric estimation from incomplete observations. *Journal of the American Statistical Association* 1958 **53** 457–481. (<https://doi.org/10.1080/01621459.1958.10501452>)
- 26. Laux CJ, Villefort C, Ehrbar S, Wilke L, Guckenberger M & Müller DA.** Carbon fiber/polyether ether ketone (CF/PEEK) implants allow for more effective radiation in long bones. *Materials* 2020 **13** 1754. (<https://doi.org/10.3390/ma13071754>)
- 27. Piccioli A, Rossi B, Scaramuzza L, Spinelli MS, Yang ZY & Maccauro G.** Intramedullary nailing for treatment of pathologic femoral fractures due to metastases. *Injury* 2014 **45** 412–417. (<https://doi.org/10.1016/j.injury.2013.09.025>)
- 28. Janssen SJ, Teunis T, Hornicek FJ, van Dijk CN, Bramer JA & Schwab JH.** Outcome after fixation of metastatic proximal femoral fractures: a systematic review of 40 studies. *Journal of Surgical Oncology* 2016 **114** 507–519. (<https://doi.org/10.1002/jso.24345>)
- 29. Piccioli A, Piana R, Lisanti M, Di Martino A, Rossi B, Camnasio F, Gatti M, Maniscalco P, Gherlinzoni F, Spinelli MS, et al.** Carbon-fiber reinforced intramedullary nailing in musculoskeletal tumor surgery: a national multicentric experience of the Italian Orthopaedic Society (SIOT) Bone metastasis Study Group. *Injury* 2017 **48** (Supplement 3) S55–S59.
- 30. Krätzig T, Mende KC, Mohme M, Kniep H, Dreimann M, Stangenberg M, Westphal M, Gauer T & Eicker SO.** Carbon fiber-reinforced PEEK versus titanium implants: an in vitro comparison of susceptibility artifacts in CT and MRI imaging. *Neurosurgical Review* 2021 **44** 2163–2170. (<https://doi.org/10.1007/s10143-020-01384-2>)
- 31. Fragomen AT, Teplensky J & Robert Rozbruch S.** Carbon-fiber-reinforced polymer intramedullary nails perform poorly in long-bone surgery. *HSS Journal* 2019 **15** 109–114. (<https://doi.org/10.1007/s11420-018-9634-4>)