



OPEN ACCESS

CASE REPORT

Acute subretinal abscess in *Staphylococcus aureus* septicaemia with endophthalmitis showcased by multimodal retinal imaging and with 2-year follow-up

Rita Prajapati,¹ Pippa Newton,² Sameena Ahmad,³ Simon Kelly¹

¹Department of Ophthalmology, Royal Bolton Hospital NHS Foundation Trust, Bolton, UK

²Department of Infectious Diseases, Manchester University NHS Foundation Trust, Manchester, UK

³Department of Sexual Medicine, Manchester University NHS Foundation Trust, Manchester, UK

Correspondence to

Simon Kelly, simon.kelly@boltonft.nhs.uk

Accepted 23 October 2018

SUMMARY

A middle-aged man presented to emergency services with central vision loss in the setting of flu-like illness with fever. A striking subfoveal abscess was observed in the right fundus. Focal acute chorioretinal inflammation was noted in the asymptomatic fellow eye. *Staphylococcus aureus* septicaemia was subsequently diagnosed. He presented with undiagnosed HIV infection and latent syphilis. Serial high-definition multimodal retinal imaging showcased resolution of the dome-shaped subretinal abscess following treatment with intravenous flucloxacillin. A chorioretinal scar swiftly replaced the subfoveal abscess. Peripheral right vision and full left vision was retained. Vision loss due to endogenous endophthalmitis in systemic sepsis is an emergency requiring prompt multidisciplinary care. Sight and life are at risk—thus this is not a diagnosis to miss! Early recognition is paramount to health and in retaining vision. We briefly review relevant literature and portray how multimodal imaging guided response to treatment of acute subretinal abscess.

BACKGROUND

Endogenous endophthalmitis (EE)—also termed metastatic endophthalmitis—is ocular inflammation resulting from haematogenous spread of an infectious agent into the eye and is less frequent than exogenous endophthalmitis. The latter follows direct inoculation after ocular surgery or trauma. Endogenous bacterial endophthalmitis (EBE) is a rare sight-threatening emergency and may manifest during life-threatening systemic sepsis. The foci of primary infection is often in the lung, liver, endocardium or urinary tract.¹ The British Ophthalmic Surveillance Unit (BOSU) study recently estimated the incidence of EE in the UK to be at least 1 case per million population per year.² Jackson *et al* in a systematic review opined that prognosis of EBE largely depends on prompt recognition and treatment and further observed that 33% of reported patients had delayed diagnosis or were misdiagnosed.¹ Furthermore, few eyes in that analysis recovered good vision and some were enucleated or eviscerated.¹ Blurred vision and floaters are frequent presenting complaints, and clinical findings have largely been centred on intraocular inflammation. Where a view of the fundus is possible retinal haemorrhages, cotton wool spots, chorioretinitis and on occasion subretinal abscesses

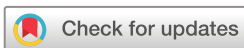may be identified.^{1–3} Such subretinal abscesses are infrequent in EBE.^{2,4}

Individuals at greatest risk of EE include immunocompromised patients; including those on immunosuppressive therapy or HIV, patients with prolonged indwelling devices/catheters and those with underlying systemic comorbidities such as diabetes.^{1–4}

EBE is thought to have become less frequent since the advent of aggressive treatment of bacterial sepsis. Gram-positive organisms such as *Staphylococcus aureus* and streptococci are bacteria most frequently responsible for EBE in the Western world.¹ Sadiq *et al* have suggested guidelines for the treatment of metastatic EE.⁵

While ophthalmic signs and visual symptoms in EE are well recognised, there are few reports of optical coherence tomography (OCT) in EBE during the acute phase as such patients are often too unwell for such imaging. Recent case reports have highlighted the utility of OCT imaging in EE with systemic infection from fungi and from yeast.^{6–11}

S. aureus bacteraemia (SAB) is an important cause of morbidity and mortality and has been extensively reviewed by others.¹² When SAB is associated with endophthalmitis, it is a cause for concern because it may be difficult to diagnose and challenging to manage. Four of the 15 patients with endophthalmitis associated with SAB died within 12 weeks after onset of SAB in a large single centre prospective study in South Korea.¹³ Subretinal abscesses have been described in association with SAB following spread from various primary sites of infection such as from vertebral osteomyelitis.¹⁴ Fortun *et al* recently described 11 eyes of 7 patients with EBE with subretinal abscesses secondary to methicillin resistant *Staphylococcus aureus* (MRSA) bacteraemia and provided publication of one OCT image in that case series.⁴ Kansal *et al* also provided an OCT image in a case report of EBE secondary to axillary phlegmon.¹⁵ Enhanced depth imaging OCT (EDI-OCT) has also recently also been used to diagnose choroidal lesions suspected to be due to bacterial sepsis.¹⁶ In the BOSU study, there were 4 reports of retinal abscess in the 62 cases of EE but the authors do not state if these occurred in fungal or bacterial EE infections or provide details of OCT imaging.² As there have been very few reports of subretinal abscess studied with OCT or multimodal imaging in acute EE and a scarcity in EBE, we present such



© BMJ Publishing Group Limited 2018. Re-use permitted under CC BY-NC. No commercial re-use. See rights and permissions. Published by BMJ.

To cite: Prajapati R, Newton P, Ahmad S, *et al*. *BMJ Case Rep* 2018;**11**:e227288. doi:10.1136/bcr-2018-227288

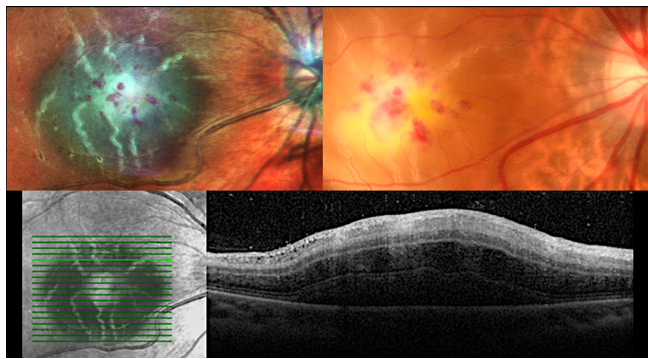


Figure 1 Baseline visit, right eye. A striking subretinal abscess involves the fovea. Multicolour and colour fundus images on top panel. Linked near-infrared and OCT on lower panel. OCT, optical coherence tomography.

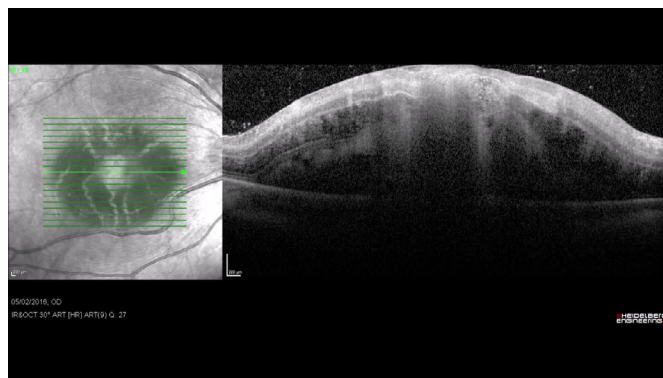
a case and where the striking multimodal images guided patient care during life-threatening sepsis.

CASE PRESENTATION

A middle-aged man presented with a 1-day history of painless loss of right central vision. He had felt unwell for several days prior with dry cough, flu-like illness and fevers. There was no medical or ophthalmic history of note bar moderate myopia. He had been self-medicating with over the counter ibuprofen and co-codamol. He was a non-smoker and drank occasional alcohol. On further questioning, he was a male who had sex with men and had previously had unprotected sex. He had also experienced occupational needle-stick injuries and had never had a HIV test. There was no history of recreational drug use.

Visual acuity; hand movements only right eye and 6/6 Snellen left eye. Anterior ocular segment examination was unremarkable bar sluggish pupils that were poor to dilate. Imaging was undertaken on white light colour fundus camera and multicolour confocal scanning laser ophthalmoscopy with linked OCT (Spectralis Heidelberg Instruments, Germany). Digital callipers on the instrument were used to measure retinal lesions. Visual field testing; right central scotoma and left full field of vision.

An area of white-yellow chorioretinal inflammation with elevation was apparent at the right fovea with retinal haemorrhage. There was mild vitritis. The OCT image showed neurosensory retina was elevated over a dome-shaped subretinal mass of area 18 mm² at retinal surface, apical height 1370 µm above Bruch's membrane (figure 1, video 1). White centred retinal



Video 1 Baseline visit, right eye. Macular cube video of linked near-infrared (left side of screen) and OCT (right side of screen) images on presentation. OCT, optical coherence tomography.

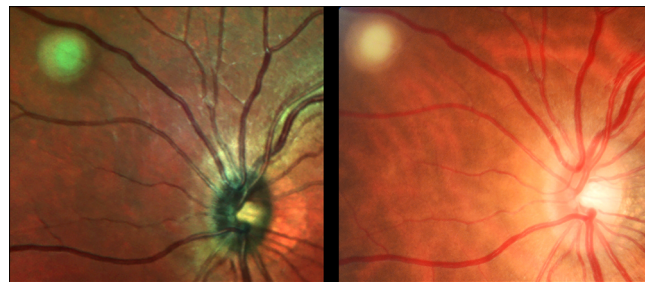


Figure 2 Baseline; left eye. Multicolour and colour fundus images show chorioretinal inflammation in nasal aspect of left fundus on presentation.

haemorrhages—also known as Roth's spot—was observed in right mid-peripheral posterior pole. A fluffy edged circular area of acute chorioretinal inflammation (diameter 1150 µm) without detectable vitritis was noted in the nasal retina of the asymptomatic left eye (figure 2). A diagnosis of toxoplasmosis was initially suspected in view of the fundal findings.

That evening, he became more unwell and was seen by the Infectious Diseases Team on call. He was more drowsy, lethargic and had poor oral intake. He had passed little urine during the day. His observations on presentation revealed a fever of 40°C, pulse 134 bpm and his blood pressure was 162/98. Examination revealed cervical lymphadenopathy and clinical dehydration. He was mildly confused and there were no features of meningism. Chest was clear on auscultation and heart sounds were normal with no peripheral stigmata evidence of endocarditis. Abdominal examination revealed an enlarged liver and palpable splenic tip. Hepatosplenomegaly was later confirmed on ultrasound.

INVESTIGATIONS

Initial laboratory investigations revealed elevated C reactive protein 148 mg/L; (normal <5); low haemoglobin (8.5 g/dL; normal 13.0–18.0), reduced lymphocytes in the setting of a normal white cell count (0.78 g/Lx10⁹/L; normal 1.5–4.0 and 8.5x10⁹/L; normal 4–11, respectively); low platelets (130x10⁹/L; normal 150–400) and stage 4 acute kidney injury (AKI) urea 21.5; (normal 2.5–7.8) creatinine 314 µmol/L; (normal 60–120) with estimated glomerular filtration rate (corrected for ethnicity) (eGFR) 19 mL/min/1.73 m². Blood lactate level was normal (2.1 mmol/L) and serum bicarbonate was slightly low (20 mmol/L; normal 22–29). Blood film revealed red cell fragments consistent with early features of disseminated intravascular coagulation (DIC). The activated partial thromboplastin time was raised at 42.6 s (range 24.7–36.1). Liver function tests were normal except for albumin (18 g/L; normal 35–50), globulin (49 g/L; normal 25–42) and aspartate aminotransferase (87 IU/L; normal 3–34). The creatine kinase level was raised (625 IU/L; <200).

DIFFERENTIAL DIAGNOSIS

Toxoplasmosis in a patient with suspected immunosuppression was the initial working diagnosis. He was also treated for presumed sepsis in addition to the management of his AKI. Immediate antimicrobial therapy was commenced with clindamycin (intravenous 600 mg four times a day), calcium folinate (orally 15 mg once a day), pyrimethamine (200 mg orally, then 75 mg once a day) and meropenem (intravenous 2 g two times a day).

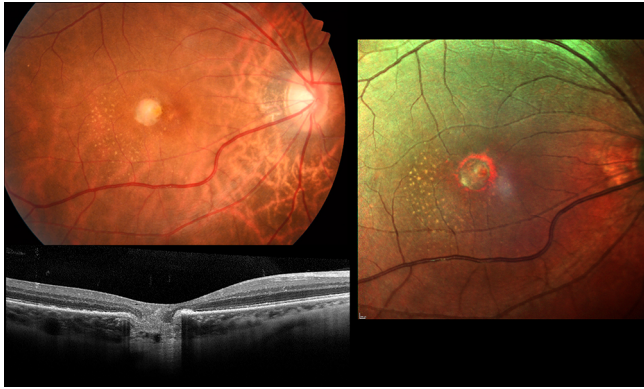


Figure 3 Day 30; right eye. Regression of the subretinal abscess into atrophic scar involving the fovea is by then apparent. Exudates are seen temporally. Colour fundus, multicolour, and optical coherence tomography images

TREATMENT

Blood cultures grew methicillin sensitive *S. aureus* (MSSA) and high-dose intravenous flucloxacillin was commenced (2 g four times a day). Intravenous ganciclovir (1.25 mg/kg/day, standard dose reduced according to eGFR) was also given in case of cytomegalovirus (CMV) retinitis. His blood CMV viral load later came back at 500 copies/mL, just at the limit of sensitivity for the assay and his blood cryptococcal antigen was negative. These findings, together with subsequent ophthalmology review, led us to believe that the fundus lesion was not CMV or cryptococcal related and ganciclovir therapy was stopped.

OUTCOME AND FOLLOW-UP

The bacteraemia was quickly controlled and blood cultures 2 days after admission and all subsequent cultures were negative. Meropenem was continued for 10 days in case of a central nervous system infection. CT and MRI brain imaging normal. A lumbar puncture was initially delayed due to concerns of early DIC, but when performed on day 7 of admission, was sterile (no bacterial or fungal or mycobacterial growth). HIV antibody test positive and avidity testing was consistent with an established infection. HIV viral load 1.14 ((log 6.06) copies/mL) and CD4 count was 12 cells/mm³ (normal range 300–1400 cells/mm³), indicating significant immunosuppression. He was informed of HIV diagnosis and commenced on *Pneumocystis jirovecii* pneumonia (Dapsone, then was switched to Atovaquone), and *Mycobacterium avium* complex prophylaxis (azithromycin 1.25 g/

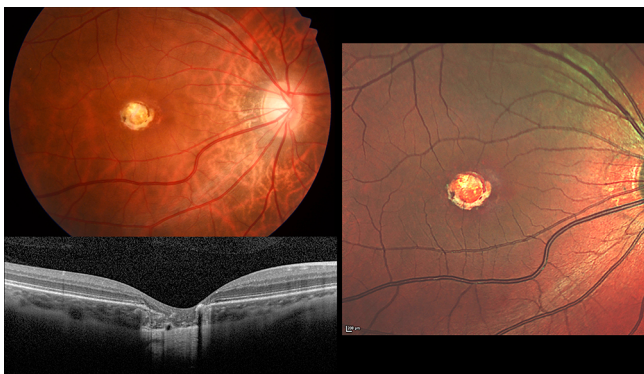


Figure 4 Year 2 visit; right eye. Atrophic scar involving the fovea. Exudates previously seen temporally are no longer apparent. Colour fundus, multicolour, and optical coherence tomography images.

once a week). He started antiretroviral therapy with raltegravir, abacavir and lamivudine (dosed according to eGFR) around 2 weeks postpresentation and has had a good virological and immunological response to therapy. His latest HIV viral load is <50 copies/mL and his CD4 count was 267 cells/mm³ (normal range 300–1400 cells/mm³). Syphilis serology was consistent with latent disease (*Treponema pallidum* particle agglutination assay titre 1 in 320; RPR, rapid plasma reagin negative) and there was no serological evidence of human T-lymphotropic virus infection. *Toxoplasma* IgG antibody positive and IgM negative, indicating prior *Toxoplasma* infection. Quantiferon-tuberculosis (TB) Gold test was negative consistent with no prior exposure to TB and there was evidence of prior varicella-zoster infection. He had active hepatitis C infection (genotype 1; viral load 2.18 million IU/mL).

His AKI on admission was multifactorial in nature with incipient acute tubular necrosis, recent non-steroidal anti-inflammatory drug (NSAIDs) usage, glomerulonephritis secondary to sepsis or hepatitis C infection and possible HIV-associated nephropathy all being potential aetiological factors. The NSAIDs were stopped and he was rehydrated with intravenous fluids. His urine contained red and white blood cells and was negative for microbial culture. His serum creatinine peaked to 361 µmol/L (normal 62–124) on the second day of admission but there was no evidence of hyperkalaemia or profound acidosis and he did not require renal replacement therapy. He did develop nephrotic syndrome (urine protein was 5.67 g/L) and later during his admission developed significant pitting peripheral oedema to waist level and hypertension. A furosemide infusion was commenced and once his renal function had improved he was commenced on an ACE inhibitor. He remained under regular review by the renal team and a decision was made not to undertake a renal biopsy on the basis of clinical improvement. In view of his nephrotic syndrome, he was commenced on low-dose prophylactic clexane on day 5 of admission and this was continued for a duration of around 2 months. On discharge, his creatinine had improved to 170 µmol/L (normal 62–124; eGFR was 40 mL/min/1.73 m² corrected for ethnicity) and at time of last follow-up (27 months postpresentation) his creatinine was 92 µmol/L (normal 62–124; eGFR was 84 mL/min/1.73 m², corrected for ethnicity).

The source for the bacteraemia was not found. He developed a painful lesion on his left index finger on day 5 postpresentation raising the possibility of an embolic source. A transthoracic and transoesophageal echocardiogram did not reveal any vegetations on his cardiac valves. An incidental patent foramen ovale was detected. CT thorax scan showed scattered ill-defined pulmonary nodules, the largest measuring 1.2 cm in diameter. One pulmonary nodule contained a tiny central cavity. The lesions were thought to be infective in aetiology and septic emboli was in the differential diagnosis. It was not possible to determine whether there were any renal infarcts as a non-contrast scan was performed in view of his AKI. His illness may have been an initial viral infection, such as influenza, complicated by a secondary bacterial infection (MSSA). Unfortunately, respiratory viral throat and nasal swabs were not taken on presentation so it is not possible to exclude such infection.

For the first 2 weeks, the patient was too unwell to attend for slit lamp examination or retinal imaging. Bedside ophthalmology examinations were undertaken on a weekly basis on the ward by two experienced ophthalmologists. Intravitreal antibiotics were withheld as it was deemed the patient's funduscopy signs were responding to systemic antibiotic treatment. Intravitreal sampling for microbiology examination was not undertaken

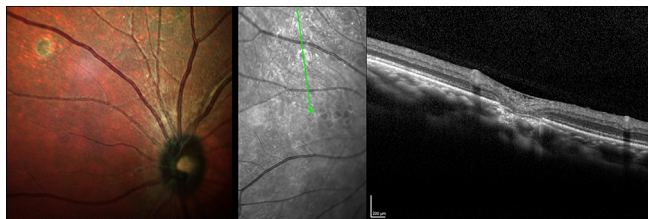


Figure 5 Year 2 visit: left eye. Small atrophic scar in nasal retina is apparent. Multicolour image left panel. Near-red reflectance image with linked OCT on right panel. OCT, optical coherence tomography.

for the same reason and because of the practicalities of so doing during critical illness.

The patient improved over several weeks and discharged home on day 28 on outpatient parenteral antimicrobial therapy (OPAT) to complete a 6-week course of intravenous flucloxacillin. At the time of OPAT completion inflammatory markers were normal. The ophthalmic working diagnosis was revised to bacterial subretinal abscess when the severity of systemic sepsis was better understood in the context of the multimodal images and negative *Toxoplasma* IgM serology. The dome-shaped elevation of the right fovea from the underlying abscess was observed to reduce by ophthalmoscopy undertaken the bedside. Repeat multimodal imaging was undertaken at day 30 by which time the former foveal abscess was replaced by full thickness chorioretinal atrophic central circular scar (diameter 1 mm) with surrounding intraretinal exudates (figure 3). These exudates later disappeared. At 2 years follow-up, a right foveal chorioretinal scar remains (figure 4). The lesion in left nasal retina resolved into a scar without visual impairment (figure 5). Final visual acuity is 6/60 right and 6/6 left eye. The right central visual field defect stabilised. The right central scotoma persists at follow-up unchanged in size from that at presentation. The left field of vision is full and was not unaffected.

DISCUSSION

This case highlights the complexities of diagnosis and management of acute vision loss in severe sepsis and draws attention to the need for multidisciplinary involvement and aggressive and prolonged intravenous antibiotic treatment of *S. aureus* septicaemia. When visual symptoms are present in the setting of systemic sepsis, urgent ophthalmic consultation is advised. EBE is an ophthalmic emergency, sight and life are at risk. When a view of the fundus is possible, multimodal retinal imaging may be of merit if swiftly undertaken—where clinically possible—to refine the diagnosis and guide response of fundus lesion size to antimicrobial treatment. Importantly the patient's condition may deteriorate requiring high dependency care and precluding such ophthalmic imaging and or slit-lamp biomicroscopy. Furthermore, the fundus view becomes obscured once significant vitritis develops. In such circumstances, binocular indirect ophthalmoscopy (BIO) is often only practicable. BIO examinations are observer dependent and documentation is subjective. Modern retinal imaging allows precise digital mapping of lesions by retinal layers and thus facilitates serial objective measurement and change analysis. Our patient presented early to ophthalmic services as the subfoveal location of the abscess caused early symptoms. The ophthalmoscopy findings of subretinal abscess, Roth's spots and bilateral involvement in the setting of fever heralded systemic septic emboli. The sexual history raised the suspicion of immunocompromise from undiagnosed HIV infection. Early multimodal imaging

allowed better appreciation of tissues involved in the subretinal abscess. The acute OCT findings in our patient were similar to the only two other reported cases of bacterial subretinal abscess we are aware of.^{4 15} Of interest Salvetti *et al* described EDI-OCT imaging in a patient a choroidal abscess in the setting of suspected sepsis.¹⁶

Thankfully, our patient with confirmed severe sepsis together with early features of DIC, multiple septic emboli and profound immunosuppression, demonstrated a pleasing response to intravenous treatment without the need for intravitreal antibiotics. This suggests a therapeutic level of systemic antibiotic reached the subretinal space and as was also reported in a single patient in the case series by Fortun *et al* that was attended to prior to development of significant vitritis.⁴ Such serial monitoring assisted in sepsis management in gauging response of the abscess to antimicrobial therapy and facilitated telemedicine consultation with tertiary ophthalmic specialist uveitis care. This case also highlighted a number of challenges including the decision of when to anticoagulate in view of features of early DIC and nephrotic syndrome through careful analysis of risk and benefit and communication between the different teams.

The presenting large size and location (subfoveal) in right eye of our patient was likely ab initio to result in a poor prognosis for right central visual acuity. Despite the loss of right visual acuity it is pleasing that the right visual field was retained with only a small central scotoma persisting and which did not enlarge from that plotted on perimetry on presentation. The patient was able to return to employment and to satisfy legal requirements for motoring.

Learning points

- ▶ Prompt diagnosis and aggressive rapid management of endogenous bacterial endophthalmitis is necessary. Life and sight are at risk.
- ▶ Ophthalmologist should beware of systemic sepsis. Risk factors should be asked for.
- ▶ Extensive examination is essential in identifying source of infection of unknown origin and requires multidisciplinary approach with good communication between teams.
- ▶ Multimodal retinal imaging provides exceptional detail of retinal microstructure and is of merit in mapping antimicrobial treatment response in retinal infection.

Acknowledgements We thank NP Jones, Manchester Royal Eye Hospital for clinical care and comments on this manuscript. We thank Jenny O'Connell, Royal Bolton Hospital for clinical imaging.

Contributors RP, PN, SA and SPK were involved in clinical care of the patient. RP and SPK: review and synthesis of literature, figures, data collection, data interpretation, writing up paper, proof reading, revision and final approval of version. RP, PN, SA and SPK were involved in revising the manuscript critically for important intellectual content. Final approval of the version published has been agreed by RP, PN, SA and SPK.

Funding The authors have not declared a specific grant for this research from any funding agency in the public, commercial or not-for-profit sectors.

Competing interests None declared.

Patient consent Obtained.

Provenance and peer review Not commissioned; externally peer reviewed.

Open access This is an open access article distributed in accordance with the Creative Commons Attribution Non Commercial (CC BY-NC 4.0) license, which permits others to distribute, remix, adapt, build upon this work non-commercially, and license their derivative works on different terms, provided the original work

is properly cited and the use is non-commercial. See: <http://creativecommons.org/licenses/by-nc/4.0/>

REFERENCES

- 1 Jackson TL, Paraskevopoulos T, Georgalas I. Systematic review of 342 cases of endogenous bacterial endophthalmitis. *Surv Ophthalmol* 2014;59:627–35.
- 2 Maling S, King C, Davies N. A British Ophthalmological Surveillance Unit Study on metastatic endogenous endophthalmitis. *Eye* 2018;32:743–8.
- 3 Nishida T, Ishida K, Niwa Y, et al. An eleven-year retrospective study of endogenous bacterial endophthalmitis. *J Ophthalmol* 2015;2015:1–11.
- 4 Fortun J, Modi YS, Bessette A, et al. Clinical features and management of subretinal abscesses secondary to methicillin-resistant *Staphylococcus aureus* endogenous endophthalmitis. *Ophthalmic Surg Lasers Imaging Retina* 2017;48:134–42.
- 5 Sadiq MA, Hassan M, Agarwal A, et al. Endogenous endophthalmitis: diagnosis, management, and prognosis. *J Ophthalmic Inflamm Infect* 2015;5:32.
- 6 Stephens JD, Adam MK, Todorich B, et al. Optical coherence tomography findings in endogenous fungal chorioretinitis, retinitis, and endophthalmitis. *Ophthalmic Surg Lasers Imaging Retina* 2017;48:894–901.
- 7 Rodrigues IA, Jackson TL. A high-definition view of endogenous fungal endophthalmitis. *Lancet Infect Dis* 2014;14:358.
- 8 Adam CR, Sigler EJ. Multimodal imaging findings in endogenous *Aspergillus* endophthalmitis. *Retina* 2014;34:1914–5.
- 9 Lavine JA, Mititelu M. Multimodal imaging of refractory *Candida* chorioretinitis progressing to endogenous endophthalmitis. *J Ophthalmic Inflamm Infect* 2015;5:24.
- 10 Amphornphruet A, Silpa-Archa S, Preble JM, et al. Endogenous cryptococcal endophthalmitis in immunocompetent host: case report and review of multimodal imaging findings and treatment. *Ocul Immunol Inflamm* 2018;26:518–22.
- 11 Invernizzi A, Symes R, Miserocchi E, et al. Spectral domain optical coherence tomography findings in endogenous candida endophthalmitis and their clinical relevance. *Retina* 2018;38:1011–8.
- 12 Tong SY, Davis JS, Eichenberger E, et al. *Staphylococcus aureus* infections: epidemiology, pathophysiology, clinical manifestations, and management. *Clin Microbiol Rev* 2015;28:603–61.
- 13 Jung J, Lee J, Yu SN, et al. Incidence and risk factors of ocular infection caused by *Staphylococcus aureus* bacteremia. *Antimicrob Agents Chemother* 2016;60:2012–7.
- 14 Steeples LR, Jones NP. Staphylococcal endogenous endophthalmitis in association with pyogenic vertebral osteomyelitis. *Eye* 2016;30:152–5.
- 15 Kansal V, Rahimy E, Garg S, et al. Endogenous methicillin-resistant *Staphylococcus aureus* endophthalmitis secondary to axillary phlegmon: a case report. *Can J Ophthalmol* 2017;52:e97–e99.
- 16 Salvetti AP, Pellegrini M, Bottoni F, et al. Endogenous bacterial endophthalmitis masquerading as an intraocular tumor. *Saudi J Ophthalmol* 2016;30:71–4.

Copyright 2018 BMJ Publishing Group. All rights reserved. For permission to reuse any of this content visit <https://www.bmj.com/company/products-services/rights-and-licensing/permissions/>
BMJ Case Report Fellows may re-use this article for personal use and teaching without any further permission.

Become a Fellow of BMJ Case Reports today and you can:

- ▶ Submit as many cases as you like
- ▶ Enjoy fast sympathetic peer review and rapid publication of accepted articles
- ▶ Access all the published articles
- ▶ Re-use any of the published material for personal use and teaching without further permission

For information on Institutional Fellowships contact consortiasales@bmjgroup.com

Visit casereports.bmj.com for more articles like this and to become a Fellow