

# Early cyclosporin A treatment retards axonal degeneration in an experimental peripheral nerve injection injury model

Ibrahim Erkutlu<sup>1</sup>, Mehmet Alptekin<sup>1</sup>, Sirma Geyik<sup>2\*</sup>, Abidin Murat Geyik<sup>3</sup>, Inan Gezgin<sup>4</sup>, Abdulvahap Gök<sup>1</sup>

1 Department of Neurosurgery, Faculty of Medicine, University of Gaziantep, Gaziantep, Turkey

2 Department of Neurology, Faculty of Medicine, University of Gaziantep, Gaziantep, Turkey

3 Department of Neurosurgery, Sanko University, Gaziantep, Turkey

4 Department of Neurosurgery, Private Park Hospital, Adiyaman, Turkey

## \*Correspondence to:

Sirma Geyik, M.D.,  
drsirmageyik@hotmail.com.

doi:10.4103/1673-5374.152381

http://www.nrronline.org/

Accepted: 2014-11-22

## Abstract

Injury to peripheral nerves during injections of therapeutic agents such as penicillin G potassium is common in developing countries. It has been shown that cyclosporin A, a powerful immunosuppressive agent, can retard Wallerian degeneration after peripheral nerve crush injury. However, few studies are reported on the effects of cyclosporin A on peripheral nerve drug injection injury. This study aimed to assess the time-dependent efficacy of cyclosporine-A as an immunosuppressant therapy in an experimental rat nerve injection injury model established by penicillin G potassium injection. The rats were randomly divided into three groups based on the length of time after nerve injury induced by cyclosporine-A administration (30 minutes, 8 or 24 hours). The compound muscle action potentials were recorded pre-injury, early post-injury (within 1 hour) and 4 weeks after injury and compared statistically. Tissue samples were taken from each animal for histological analysis. Compared to the control group, a significant improvement of the compound muscle action potential amplitude value was observed only when cyclosporine-A was administered within 30 minutes of the injection injury ( $P < 0.05$ ); at 8 or 24 hours after cyclosporine-A administration, compound muscle action potential amplitude was not changed compared with the control group. Thus, early immunosuppressant drug therapy may be a good alternative neuroprotective therapy option in experimental nerve injection injury induced by penicillin G potassium injection.

**Key Words:** nerve regeneration; peripheral nerve injury; injection injury; cyclosporine A; penicillin G potassium; Wallerian degeneration; neuroelectrophysiology; neural regeneration

Erkutlu I, Alptekin M, Geyik S, Geyik AM, Gezgin I, Gök A (2015) Early cyclosporin A treatment retards axonal degeneration in an experimental peripheral nerve injection injury model. *Neural Regen Res* 10(2):266-270.

## Introduction

Surgical and pharmacological therapeutic approaches for the treatment of nerve injury caused by drug injection have been studied since the 1920s (Matson, 1950; Kobayashi et al., 1997; Kaptan et al., 2014) and the clinical presentation of drug injection-caused nerve injury has been well described (Maqbool et al., 2009). Until the mid-1980s, the pathophysiology of drug injection-caused nerve injury remained obscure, and even now, is controversial. The postulated mechanisms underlying drug injection-caused nerve injury include direct needle trauma, secondary constriction by scarring, extrafascicular or intrafascicular injection of agent, and direct nerve fiber damage by neurotoxic chemicals in the injected agent. Nerve injury leads to Wallerian degeneration and includes the recruitment of macrophages and the phagocytosis of myelin and remnants of axons. Neurological sequel can range from minor transient sensory disturbance to severe sensory disturbance and motor paralysis with poor recovery (Gentili et al., 1996; Taskinen and

Roytta, 2000).

The current therapy modalities of nerve injury following intramuscular drug injection range from a conservative approach to immediate operative exposure and irrigation, and have included early neurolysis and delayed exploration with neurolysis or resection. However, some experimental studies related to injection injuries have added to our understanding of the pathophysiology of this important medico-legal problem (Hudson, 1984; Terzis, 1987; Steinfeldt et al., 2010).

The immunosuppressive agent cyclosporin A (CsA) has increased the success rate of organ transplantation (Mackinnon and Hudson, 1992). Additional studies have investigated its use in peripheral nerve allografting. In these studies, authors reported that there were excellent nerve regenerations in autograft and allograft applications under immunosuppressive effect of CsA (Bain et al., 1988; Mohammadi et al., 2014). However, its neuroprotective actions are not well understood (Wang et al., 1997; Kaminska et al., 2004). Here, we performed electrophysiological and histopathological studies

to investigate the time-dependent efficacy of CsA in a rat model of penicillin G potassium injection-caused peripheral nerve injury.

## Materials and Methods

### Study groups and experimental protocol

Twenty male Wistar rats, weighing 250–300 g, were obtained from the Animal Laboratory, University of Gaziantep, Turkey and included in this study. The experimental protocol was reviewed and approved by the Ethics Committee for Animal Experiments of the University of Gaziantep, Turkey. The rats were exposed to a 12-hour light-dark cycle and were provided access to standard rat chow *ad libitum*.

The rats were anesthetized by an intraperitoneal injection of Ketamine HCl 50 mg/kg (Ketalar flakon 50 mg/mL, Pfizer, Istanbul, Turkey). After fixation on the operating table, all of the surgical procedures were conducted under sterile conditions and the right sciatic nerves were exposed under loupe magnification ( $\times 4$ ). A longitudinal incision was made in the upper to mid thigh, and a 1.5-cm length of the right sciatic nerve was isolated by blunt dissection along a fascial plane between the gluteus and femoral musculature. Penicillin G potassium (0.3 mL, 150,000 IU) was applied to the nerve at mid thigh level (Penicillin G flakon 1,000,000 IU/2 mL, Ibrahim Ethem Ulugay, Istanbul, Turkey). A sterile 6/0 silk suture was tied through the perineural muscle tissue to mark the injured site.

The 20 rats were randomly and evenly divided into three CsA-treated groups and a control group. In the CsA-treated groups, 20 mg/kg CsA (Sigma-Aldrich, Chemie GmbH, Germany) was intraperitoneally administered at 30 minutes, 8 and 24 hours after sciatic nerve injury (CsA-treated-30 minutes, -8 hours, and -24 hours groups, respectively). In the control group, CsA administration was omitted. In the three CsA-treated groups, CsA was used as a management therapy (10 mg/kg) by intraperitoneal route once per day for 3 days. All rats received an injection of 20 mg/kg Ceftriaxone (Rocephin flakon 0.5 g, Roche, Istanbul, Turkey) 30 minutes before the surgical procedure and for 3 days after surgery to prevent infection. The nerve

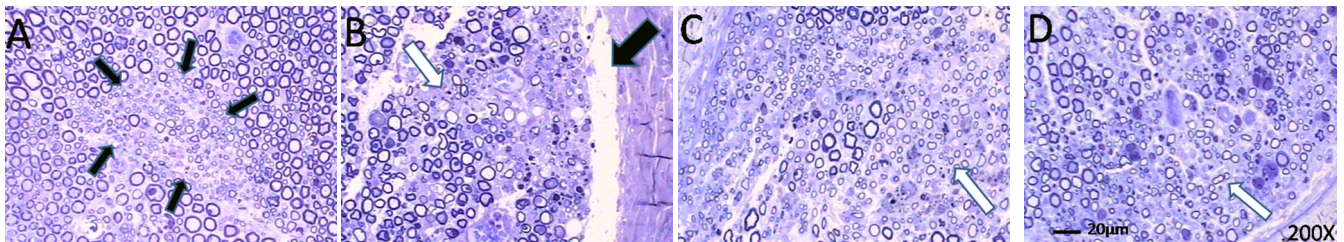
biopsies were obtained at 4 weeks after nerve injection injury. Prior to the biopsy, the rats were examined for signs of hind limb weakness. The rats were anesthetized using an intraperitoneal injection of Ketamine HCl (50 mg/kg). The sciatic nerves were exposed surgically and any macroscopic changes which can be seen by direct vision such as adhesion, swelling or thickening at the injury site and along the length of the nerve, were recorded. For each rat, a 10-mm length of the nerve including the site of injection and equal-distance proximally and distally was biopsied. The nerve samples were fixed in a 10% solution of formaldehyde and processed for light microscopy (Olympus Bx 50 light microscope, Tokyo, Japan). Samples were taken and embedded in paraffin; sections of 5  $\mu$ m thick were separated with the help of a microtome. Samples were then stained with toluidine blue (Sigma, St. Louis, MO, USA). After staining, sections were evaluated under  $\times 40$ ,  $\times 200$  and  $\times 400$  magnifications in terms of gross cellular and structural changes within the nerve (Malysz et al., 2011).

### Electrophysiological recordings

The compound muscle action potential (CMAP) values were measured using a Medtronic Keypoint® Version 3.0 EMG device (Medtronic Company, Minneapolis, MN, USA). The stimulus was given with a bipolar insulated stimulator. One silver electrode was placed on dry skin of the tail as a ground electrode, and the recording electrode was placed on the gastrocnemius muscle surface. A 5–10 mA stimulus was applied to a point just above the level of the sciatic nerve injury (proximal to the injury region). The duration of the stimulus was 0.2 ms, and the CMAP values (amplitude, latency, area under the curve, and duration) were recorded using distal silver electrodes (Table 1). CMAP values were measured just before injury, 1 hour after injury (early post-injury) and 4 weeks after injury (after treatment).

### Statistical analysis

Because the measurement variables do not meet the normality assumptions, the Kruskal-Wallis one-way analysis of variance was used to compare the variable measurements among the groups. After that, differences in values between



**Figure 1** Effect of cyclosporin A (CsA) on axonal degeneration in sciatic nerves injured with penicillin G potassium at 4 weeks post-injury (Toluidine blue,  $\times 200$ ).

In the CsA-treated-30 minutes (A), -8 hours (B), and -24 hours (C) groups, CsA was administered at 30 minutes, 8 and 24 hours after penicillin G potassium injection-caused injury respectively, while in the control group (D), CsA administration was omitted. In the CsA-treated-30 minutes group, limited and localized degeneration (small black arrows) was observed in all rats compared to CsA-treated-8 hours, -24 hours and control groups. In the CsA-treated-8 hours, -24 hours and control groups, diffuse degeneration and injury patterns, small regeneration clusters, subepineurial tears (thick black arrow in B) and Schwann cell wastes (white arrows in B, C and D) were seen and the changes in morphology were similar.

**Table 1** The values of CMAP in four groups

		CsA-treated-30 minutes	CsA-treated-8 hours	CsA-treated-24 hours	Control
Amplitude (mV)	Pre-injury	61.04±14.03	35.72±3.41	47.28±23.18	50.84±11.03
	Post-injury	20.94±8.24*	20.82±4.42*	22.62±11.46*	25.34±6.92*
	After treatment	39.90±7.42 <sup>#</sup>	21.88±6.34	34.42±14.03	26.62±9.33
Latency (ms)	Pre-injury	1.00±0.13	0.79±0.18	1.03±0.18	1.00±1.17
	Post-injury	1.13±0.17	1.03±0.21	1.20±0.13	1.03±0.14
	After treatment	0.99±0.10	1.06±0.19	0.96±0.08	0.96±0.14
Area under the curve (mV.ms)	Pre-injury	121.94±57.96	64.96±20.10	77.80±42.42	86.68±16.77
	Post-injury	37.72±24.85	37.50±9.76	35.60±20.78	51.62±14.98
	After treatment	64.38±11.94	28.96±11.60	50.26±26.86	43.50±19.34
Duration (ms)	Pre-injury	11.70±9.36	5.98±1.12	5.58±0.50	5.84±0.43
	Post-injury	5.38±1.83	6.02±1.53	5.16±0.32	6.38±1.98
	After treatment	5.28±1.04	5.76±1.07	4.82±0.37	5.74±1.39

The data are expressed as the mean ± SD. \* $P < 0.05$ , vs. pre-injury; <sup>#</sup> $P < 0.05$ , vs. post-injury (Kruskal-Wallis one-way analysis of variance followed by the Mann-Whitney  $U$  test). There were five rats in each group. CMAP: Compound muscle action potential; CsA: cyclosporin A.

groups were analyzed with the Mann-Whitney  $U$  test. Both tests were performed using IBM SPSS Statistics for Windows, Version 20 (IBM Corp., Armonk, NY, USA). The data were expressed as the mean ± SD. A value of  $P < 0.05$  was considered statistically significant.

## Results

### Effect of CsA on electrophysiological changes after sciatic nerve injection injury

The results of the electrophysiological investigation are shown in **Table 1**. After sciatic nerve injection injury, the mean values of the CMAP amplitudes were significantly decreased in all four groups compared with the values detected before injury ( $P < 0.05$ ). At 4 weeks after injury (after treatment), significant improvement in the mean value of CMAP amplitude was only observed in the CsA-treated-30 minutes group ( $P < 0.05$ ). In addition, in each group, the latency and area under the slope of the CMAP values post-injury and post-treatment were not significantly different from that measured before injury ( $P > 0.05$ ).

### Effect of CsA on nerve degeneration after sciatic nerve injection injury

The histopathological study of the sciatic nerves demonstrated focal and limited Wallerian degeneration with a more pronounced axonal regeneration pattern in the CsA-treated-30 minutes group compared with the other groups. All of the myelinated axons in the sciatic nerves from the CsA-treated-30 minutes group had clear centers and were evenly distributed throughout the nerve bundle except for the lesion area (**Figure 1A**). In the CsA-treated-8 hours and CsA-treated-24 hours groups, the histopathological findings were morphologically similar to those in the control group. In the CsA-treated-8 hours and CsA-treated-24 hours groups, sections showed a large number of diffuse axonal degeneration patterns, regeneration clusters, subepineurial tears and Schwann cell debris. Furthermore, many myelin sheaths had collapsed in the sciatic nerve of the CsA-treated-8 hours, CsA-treated-24 hours and control groups. The collapsed

axons in these groups were not evenly distributed. The collapsed and intact axons of these groups were separated by larger interstitial spaces (**Figure 1B–D**). The pathological severity appeared to increase with the order of CsA-treated-30 minutes, -8 hours, -24 hours and control groups (**Figure 1A–D**).

## Discussion

Injection injury to the peripheral nerves remains an important medicolegal problem in developing countries. Therefore, we selected penicillin G potassium, one of the most widely used therapeutic agents in treating infectious diseases in developing countries, for use in this study (Matson, 1950; Gentili et al., 1996). Injection-induced nerve damage might be due to both the neurotoxic effect of the agent injected and the mechanical damage that causes distortion of the blood-nerve barrier (Ong et al., 2011). Because of the insufficiencies of the possible surgical and medical treatment modalities for this type of injury, an alternative approach aimed at decreasing the process of nerve degeneration is desirable. Therefore, we investigated the potential neuroprotective effects of an immunosuppressant drug on the peripheral nervous system in an injection injury model.

Damage to the peripheral nerves is followed by degeneration and regeneration phases in early (1–6 hours), rapid (1–3 days), and fast (7–28 days) post-injury periods. The early degenerative changes, such as the worsening of CMAP values, are observed in both proximal and distal parts of the nerve, whereas the axonal disruption and myelin changes start. The morphological findings include degeneration in axons and myelin with swelling of the injury location (Koltzenburg and Bendszus, 2004; Sta et al., 2014). During the rapid degeneration phase, myelin and axonal losses expand distally (Mackinnon et al., 1991; Conforti et al., 2014). The fast degenerative phase is followed by a long-lasting phase of regeneration (7–28 days) in which immunohistochemical, functional and neurophysiological results all suggest the slow extension of nerve fibers in a distal direction (Mackinnon et al., 1991; Li et al., 2001, 2008; Sta et al., 2014).

Currently, there are two mechanisms proposed to produce the rapid Wallerian degeneration in anucleate mammalian axons. One mechanism involves the extensive activation of calcium ( $\text{Ca}^{2+}$ )-dependent pathways, which directly or indirectly affect the degradation of neurofilaments and other proteins necessary for axonal viability. The other potential mechanism is a vigorous phagocytic response by migratory white blood cells (Glass et al., 1994; Sunio and Bittner, 1997). Although  $\text{Ca}^{2+}$  plays a pivotal role in normal neuronal function, excessive amounts are detrimental and have been shown to result in significant neuronal loss. Mitochondria are believed to play a key role in this process by sequestering and releasing  $\text{Ca}^{2+}$  via several mechanisms (Okonkwo and Povlishock, 1999; Sullivan et al., 2000).

The data in the literature regarding the ability of CsA to improve peripheral nerve regeneration are inconsistent (de la Monte et al., 1988; Muramatsu et al., 1995; Meirer et al., 2002; Mohammadi et al., 2014), which we believe reflects the variety of models and testing methods used. Diaz-Ruiz et al. (1999) first demonstrated that early administration of CsA diminished the production of lipid peroxidation in injured spinal cord and also improved functional outcome. CsA administration may also have an effect on mononuclear phagocytes, which play a critical role during Wallerian degeneration by affecting the number of macrophages while also retarding axonal degeneration and subsequent reinnervation (Sunio and Bittner, 1997; Morioka et al., 1999; Taskinen and Roytta, 2000). Meirer et al. (2002) observed that CsA increased nerve regeneration *in vivo* in a dose-dependent manner. Given the associated organotoxic and metabolic problems, authors have reported the necessity of using low doses of cyclosporin, limiting the duration of therapy or choosing topical administration of the drug (Rezzani, 2006; Melnikov et al., 2011). Junior et al. (2008) reported that administration of low dose CsA (5 mg/kg per day subcutaneously) increased fiber density. In addition, it has been reported that intraperitoneal injection of CsA, provided it can pass through the blood-brain barrier, significantly prolongs survival, reduces brain damage, and improves mitochondrial respiration (Uchino et al., 2002; Domanska-Janik et al., 2004; Kaminska et al., 2004). It has been demonstrated that CsA protects both mitochondria and the related axonal shaft (Okonkwo and Povlishock, 1999).

The present investigation has a number of methodological deficiencies that need to be discussed. First, in our experimental setting, we did not use a control group with needle trauma to clarify the injury of the needle alone. An experimental study about nerve injury by needle alone showed that small-diameter cannulae (24 gauge) may be advisable for peripheral nerve blocks to minimize the risk of nerve injury in the case of nerve perforation. In addition, inflammatory responses (but neither axonal nor myelin alterations) were observed in almost all nerve specimen within the 24 G needle group (Steinfeldt et al., 2010). In our study, we used a thinner 26 gauge tuberculin syringe. Second, we could not perform some important investigations such as walking track analysis and electron microscopic

studies because of some technical difficulties and incapacities. However, electrophysiological studies were also used to reduce the histopathological subjectivity or bias that may arise.

Despite these insufficiencies, given that this study is the first reported experiment to use an immunosuppressant agent to improve peripheral nerve injury after drug injection, we believed that findings from this experiment can be useful for the design of future studies. We found that CsA limited the injured area or slowed down the process of destruction in the rat sciatic nerve and improved the CMAP amplitude values, if given at an early period (within 30 minutes of injury) by systemic administration. The mechanism by which CsA produces its axonal regenerative effect is unknown. However, probable mechanisms of CsA include inhibiting white blood cell proliferation and/or differentiation and inhibiting  $\text{Ca}^{2+}$  dependent cell injury.

In summary, the present study confirms the neuroprotective effect of CsA. Furthermore, our results indicate that unknown mechanisms underlie the recovery of nerve injection injury.

**Acknowledgments:** We would like to express our very great appreciation to Prof. Suzan Zorludemir from Department of Pathology, Faculty of Medicine, University of Cukurova, Turkey for her valuable histopathological support on this project. We would also like to thank Prof. Mustafa Yilmaz from Department of Neurology, Faculty of Medicine, University of Gaziantep, Turkey who helped us in handling and using the electrophysiological instruments.

**Author contributions:** IE, AG, MA and AMG conceived and designed the study. IE, SG and IG were responsible for data acquisition. IE, SG and AMG were in charge of data analysis and interpretation and drafted the manuscript. IE and SG were responsible for critical revision of this manuscript. All authors approved the final version of this manuscript.

**Conflicts of interest:** None declared.

## References

- Bain JR, Mackinnon SE, Hudson AR, Falk RE, Falk JA, Hunter DA (1988) The peripheral nerve allograft: an assessment of regeneration across nerve allografts in rats immunosuppressed with cyclosporin A. *Plast Reconstr Surg* 82:1052-1066.
- Conforti L, Gilley J, Coleman MP (2014) Wallerian degeneration: an emerging axon death pathway linking injury and disease. *Nat Rev Neurosci* 15:394-409.
- de la Monte SM, Bour C, Radhakrishnan VV, Jupiter JB, Smith RJ, Hedley-Whyte ET (1988) Effects of cyclosporin A and predegeneration on survival and regeneration of peripheral nerve allografts in rabbits. *Surg Neurol* 29:95-100.
- Diaz-Ruiz A, Rios C, Duarte I, Correa D, Guizar-Sahagun G, Grijalva I, Ibarra A (1999) Cyclosporin-A inhibits lipid peroxidation after spinal cord injury in rats. *Neurosci Lett* 266:61-64.
- Domanska-Janik K, Buzanska L, Dluzniewska J, Kozłowska H, Sarnowska A, Zablocka B (2004) Neuroprotection by cyclosporin A following transient brain ischemia correlates with the inhibition of the early efflux of cytochrome C to cytoplasm. *Brain Res Mol Brain Res* 121:50-59.
- Gentili F, Hudson AR, Midha R (1996) Peripheral nerve injuries: Types, causes, and grading. In: *Neurosurgery*. Vol 3. (Wilkins RH, Rengachary SS, eds), pp3105-3114. New York: McGraw-Hill.

- Glass JD, Schryer BL, Griffin JW (1994) Calcium-mediated degeneration of the axonal cytoskeleton in the Ola mouse. *J Neurochem* 62:2472-2475.
- Hudson AR (1984) Nerve injection injuries. *Clin Plast Surg* 11:27-30.
- Junior P, Ferreira M, Nakamoto H, Milcheski D, Filho AC (2008) Influence of immunosuppression on nerve regeneration using allografts: an experimental study on rats. *Acta Ortop Bras* 16:41-44.
- Kaminska B, Gaweda-Walerych K, Zawadzka M (2004) Molecular mechanisms of neuroprotective action of immunosuppressants--facts and hypotheses. *J Cell Mol Med* 8:45-58.
- Kaptan H, Kasimcan O, Ayaz M, Bozdogan O, Karabagli H (2014) Controlled trial of efficacy of dexamethasone in sciatic nerve crush injury in rats. *J Neur Sci (Turkish)* 31:126-135.
- Kobayashi J, Mackinnon SE, Langer JC, Hertl MC, Hunter DA, Tarasidis G (1997) The effect of ammonium sulfate injection on peripheral nerve. *J Reconstr Microsurg* 13:389-396.
- Koltzenburg M, Bendszus M (2004) Imaging of peripheral nerve lesions. *Curr Opin Neurol* 17:621-626.
- Li PA, He QP, Siesjo BK (2001) Effects of intracarotid arterial injection of cyclosporin A and spontaneous hypothermia on brain damage incurred after a long period of global ischemia. *Brain Res* 890:306-313.
- Li X, Shen J, Chen J, Wang X, Liu Q, Liang B (2008) Magnetic resonance imaging evaluation of acute crush injury of rabbit sciatic nerve: correlation with histology. *Can Assoc Radiol J* 59:123-130.
- Mackinnon SE, Hudson AR (1992) Clinical application of peripheral nerve transplantation. *Plast Reconstr Surg* 90:695-699.
- Mackinnon SE, Dellon AL, O'Brien JP (1991) Changes in nerve fiber numbers distal to a nerve repair in the rat sciatic nerve model. *Muscle Nerve* 14:1116-1122.
- Malysz T, Ilha J, Nascimento PS, De Angelis K, Schaan BD, Achaval M (2011) Beneficial effects of treadmill training in experimental diabetic nerve regeneration. *Clinics (Sao Paulo)* 65:1329-1337.
- Maqbool W, Sheikh S, Ahmed A (2009) Clinical, electrophysiological, and prognostic study of postinjection sciatic nerve injury: An avoidable cause of loss of limb in the peripheral medical service. *Ann Indian Acad Neurol* 12:116-119.
- Matson DD (1950) Early neurolysis in the treatment of injury of the peripheral nerves due to faulty injection of antibiotics. *N Engl J Med* 242:973-975.
- Meirer R, Babucco O, Unsal M, Nair DR, Gurunluoglu R, Skugor B, Meirer B, Siemionow M (2002) Effect of chronic cyclosporine administration on peripheral nerve regeneration: a dose-response study. *Ann Plast Surg* 49:96-103.
- Melnikov S, Mayan H, Uchida S, Holtzman EJ, Farfel Z (2011) Cyclosporine metabolic side effects: association with the WNK4 system. *Eur J Clin Invest* 41:1113-1120.
- Mohammadi R, Heydarian H, Amini K (2014) Effect of local administration of cyclosporine A on peripheral nerve regeneration in a rat sciatic nerve transection model. *Chin J Traumatol* 17:12-18.
- Morioka M, Hamada J, Ushio Y, Miyamoto E (1999) Potential role of calcineurin for brain ischemia and traumatic injury. *Prog Neurobiol* 58:1-30.
- Muramatsu K, Doi K, Kawai S (1995) Nerve regenerating effect of short-course administration of cyclosporine after fresh peripheral nerve allotransplantation in the rat: comparison of nerve regeneration using different forms of donor nerve allografts. *Microsurgery* 16:496-504.
- Okonkwo DO, Povlishock JT (1999) An intrathecal bolus of cyclosporin A before injury preserves mitochondrial integrity and attenuates axonal disruption in traumatic brain injury. *J Cereb Blood Flow Metab* 19:443-451.
- Ong MJ, Lim GH, Kei PL (2011) Iatrogenic sciatic nerve injury secondary to intramuscular injection. *Singapore Med J* 53:551-554; quiz 555.
- Rezzani R (2006) Exploring cyclosporine A-side effects and the protective role-played by antioxidants: the morphological and immunohistochemical studies. *Histol Histopathol* 21:301-316.
- Sta M, Cappaert NL, Ramekers D, Baas F, Wadman WJ (2014) The functional and morphological characteristics of sciatic nerve degeneration and regeneration after crush injury in rats. *J Neurosci Methods* 222:189-198.
- Steinfeldt T, Nimphius W, Werner T, Vassiliou T, Kill C, Karakas E, Wulf H, Graf J (2010) Nerve injury by needle nerve perforation in regional anaesthesia: does size matter? *Br J Anaesth* 104:245-253.
- Sullivan PG, Thompson M, Scheff SW (2000) Continuous infusion of cyclosporin A postinjury significantly ameliorates cortical damage following traumatic brain injury. *Exp Neurol* 161:631-637.
- Sunio A, Bittner GD (1997) Cyclosporin A retards the wallerian degeneration of peripheral mammalian axons. *Exp Neurol* 146:46-56.
- Taskinen HS, Roytta M (2000) Cyclosporin A affects axons and macrophages during Wallerian degeneration. *J Neurotrauma* 17:431-440.
- Terzis K (1987) Nerve Injection Injuries. In: *Microreconstruction of Nerve Injuries*, pp173-180: W.B.Saunders Company.
- Uchino H, Minamikawa-Tachino R, Kristian T, Perkins G, Narazaki M, Siesjo BK, Shibasaki F (2002) Differential neuroprotection by cyclosporin A and FK506 following ischemia corresponds with differing abilities to inhibit calcineurin and the mitochondrial permeability transition. *Neurobiol Dis* 10:219-233.
- Wang MS, Zeleny-Pooley M, Gold BG (1997) Comparative dose-dependence study of FK506 and cyclosporin A on the rate of axonal regeneration in the rat sciatic nerve. *J Pharmacol Exp Ther* 282:1084-1093.
- Wilkins R, Rengachary, SS (1996) Peripheral Nerve Injuries: Types, causes, and grading. In: *Nerosurgery*, 2 Edition, pp3113-3114: McGraw Hill.

Copyedited by Calliari A, Karabagli H, Li CH, Song LP, Zhao M