



ENDOSCOPIC SNAPSHOT

Duodenal Variceal Bleeding Successfully Treated by Endoscopic N-butyl-2-cyanoacrylate Injection



Tratamento Bem-sucedido de Hemorragia Variceal Duodenal por Injecção Endoscópica de N-butil-2-cianoacrilato

Mariana Costa*, Gonçalo Ramos

Gastroenterology Department, Centro Hospitalar de Lisboa Central, Lisbon, Portugal

Received 29 March 2015; accepted 31 March 2015
Available online 5 May 2015

KEYWORDS

Duodenum;
Enbucrilate;
Gastrointestinal Hemorrhage;
Hemostasis, Endoscopic

PALAVRAS-CHAVE

Duodeno;
Embucrilato;
Hemorragia Gastrointestinal;
Hemostase Endoscópica

Gastroesophageal variceal bleeding is the most common cause of upper gastrointestinal bleeding in patients with liver cirrhosis. In contrast, duodenal varices are rare and their potential to bleed is low. However, when it occurs, it can be fatal – mortality rate of 35–40%.¹ Although the recognition of ectopic varices has long been described,

therapeutic procedures have not yet been established for bleeding from duodenal varices. Endoscopic band ligation, sclerotherapy, transjugular intrahepatic portosystemic shunt, balloon-occluded retrograde transvenous obliteration, and resection of a segment of bleeding site have been used for treatment.^{2–5}

We present a case of a 48-year-old man with a known history of liver cirrhosis secondary to chronic hepatitis C infection. He was admitted in emergency department due to hematemesis and melena for 24 h. He was hemodynamically stable, and had a hemoglobin level of 7.1 g/dL. The patient was treated with intravenous (IV) pantoprazole, IV octreotide and IV ceftriaxone. Emergency esophagogastroduodenoscopy revealed small esophageal varices without stigmata of hemorrhage. Apart from mild portal gastropathy, no other gastric lesions suggestive of bleeding were noted. Finally, a duodenal varix with a fibrin plug at the second portion, approximately 1 cm in diameter, was found (Fig. 1). N-butyl-2-cyanoacrylate (histoacryl) was injected to the duodenal varix, and bleeding was successfully controlled. Subsequently, the patient remained hemodynamically stable, with no recurrent bleeding. Six months later, a follow-up endoscopy showed large esophageal varices, which were treated with endoscopic band ligation, and severe hypertensive gastropathy. There were not any signs of duodenal varices (Fig. 2).

* Corresponding author.

E-mail address: mariananunocosta@gmail.com (M. Costa).

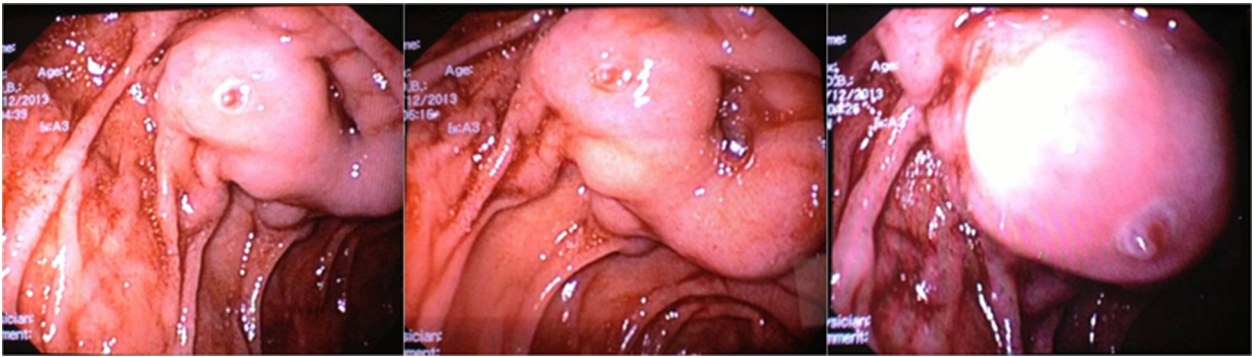


Figure 1 Duodenal varix with a fibrin plug at the second portion of duodenum.

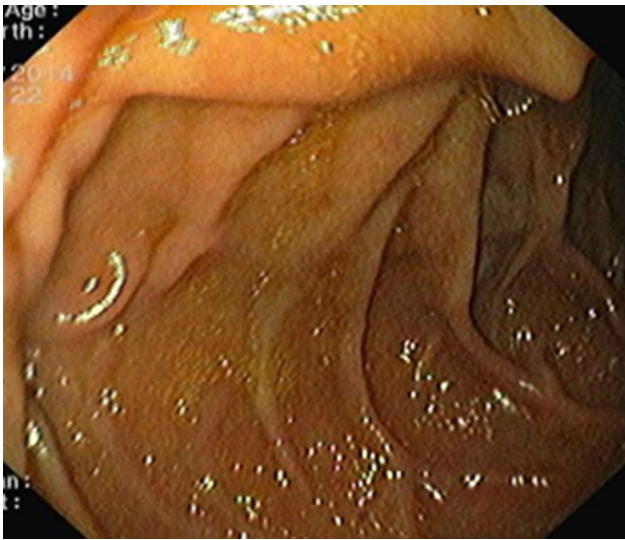


Figure 2 Follow-up endoscopy showed no signs of duodenal varices.

Ethical disclosures

Protection of human and animal subjects. The authors declare that no experiments were performed on humans or animals for this study.

Confidentiality of data. The authors declare that they have followed the protocols of their work center on the publication of patient data

Right to privacy and informed consent. The authors declare that no patient data appear in this article.

Conflicts of interest

The authors have no conflicts of interest to declare.

References

1. Khouqeer F, Morrow C, Jordan P. Duodenal varices as a cause of massive upper gastrointestinal bleeding. *Surgery*. 1987;102:548–52.
2. Matsui S, Kudo M, Ichikawa T, Okada M, Miyabe Y. The clinical characteristics, endoscopic treatment, and prognosis for patients presenting with duodenal varices. *Hepatogastroenterology*. 2008;55:959–62.
3. Tan NC, Ibrahim S, Tay KH. Successful management of a bleeding duodenal varix by endoscopic banding. *Singap Med J*. 2005;46:723–5.
4. Seo YS, Kwon YD, Park S, Keum B, Park BJ, Kim YS, et al. Complete eradication of duodenal varices after endoscopic injection sclerotherapy with ethanolamine oleate: a case report. *Gastrointest Endosc*. 2008;67:759–62.
5. Kochar N, Tripathi D, McAvoy NC, Ireland H, Redhead DN, Hayes PC. Bleeding ectopic varices in cirrhosis: the role of transjugular intrahepatic portosystemic stent shunts. *Aliment Pharmacol Ther*. 2008;28:294–303.