

Combined pulsed-dye laser and medical therapy for treatment of cutaneous sarcoidosis lesions: a case report

Journal of International Medical Research
49(3) 1–5

© The Author(s) 2021

Article reuse guidelines:

sagepub.com/journals-permissions

DOI: 10.1177/0300060521997745

journals.sagepub.com/home/imr



Wenxin Dong, Caixia Li, Yu Shi and
Wei Zhang 

Abstract

Sarcoidosis is a systemic granulomatous disease of unknown etiology that most frequently occurs in the lungs. However, cutaneous lesions are often the primary sign. Cutaneous sarcoidosis is difficult to treat, although different therapies have been applied. We herein report a case in which cutaneous sarcoidosis was treated with pulsed-dye laser (PDL) therapy along with oral administration of acitretin and hydroxychloroquine; no topical medications were applied. All patient details are de-identified. The treatment areas gradually improved after several courses of PDL therapy. This case illustrates that PDL therapy can serve as an auxiliary treatment for cutaneous sarcoidosis.

Keywords

Granulomatous disease, cutaneous sarcoidosis, laser therapy, pulsed-dye laser, auxiliary treatment, case report

Date received: 20 January 2021; accepted: 2 February 2021

Introduction

Sarcoidosis is a systemic granulomatous disease of unknown etiology that most frequently occurs in the lungs. However, cutaneous lesions, which are present in approximately 10% to 30% of affected patients, are often the primary sign.^{1,2}

Department of Medical Cosmetic Center, Shanghai Skin Disease Hospital, Shanghai, China

Corresponding author:

Wei Zhang, Department of Medical Cosmetic Center, Shanghai Skin Disease Hospital, No. 1278 Baode Road, Shanghai 200443, China.

Email: zwassist@163.com



Creative Commons Non Commercial CC BY-NC: This article is distributed under the terms of the Creative Commons Attribution-NonCommercial 4.0 License (<https://creativecommons.org/licenses/by-nc/4.0/>) which permits non-commercial use, reproduction and distribution of the work without further permission provided the original work is attributed as specified on the SAGE and Open Access pages (<https://us.sagepub.com/en-us/nam/open-access-at-sage>).

Cutaneous sarcoidosis has various clinical manifestations, such as papules and plaques. Regardless of the clinical presentation, non-caseating granulomas are the most characteristic histologic manifestation. Cutaneous sarcoidosis remains difficult to treat, although different therapies have been applied. We herein report a case in which cutaneous sarcoidosis was improved by pulsed-dye laser (PDL) therapy.

Case report

In December 2018, a 46-year-old Asian woman presented for a consultation regarding left facial lesions (Figure 1(a)), which had been gradually increasing in size for more than 7 years. Symptoms such as pain and pruritus were absent.

The patient had visited several hospitals. Laboratory test results were normal, and a T-SPOT.TB test was negative. Chest computed tomography showed no evidence of organ involvement. Pulmonary function tests and electrocardiograms were normal. Repeated histopathological examinations

suggested a noncaseating granulomatous disease, and acid-fast staining was negative. Furthermore, polymerase chain reaction analysis detected no *Mycobacterium tuberculosis* DNA in the tissues.

The patient had been diagnosed with cutaneous sarcoidosis. She was treated with oral acitretin, compound glycyrrhizin, and thalidomide and topical pimecrolimus. However, no improvement was obtained, and the lesions continued to grow.

In our hospital, another lesion biopsy was taken for further diagnosis. Microscopic examination showed granulomas composed of epithelioid cells (Figure 2). This histologic pattern of sarcoidosis was similar to her previous pathologic findings. Considering the results of all auxiliary examinations to date, we made the same diagnosis of cutaneous sarcoidosis because there was no obvious evidence of infection or systemic involvement. The treatment regimen included oral administration of acitretin (10 mg per day) and hydroxychloroquine (200 mg twice a day) along with PDL therapy. The lesions were treated with PDL therapy at 14 J/cm²

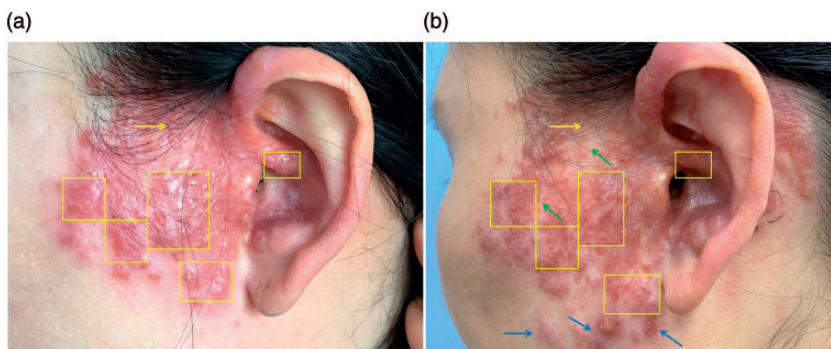


Figure 1. Clinical photographs before and after the treatment. (a) Initial findings. The main lesion was a red plaque with an approximate size of 8 × 8 cm anterior to the left ear and involving the auricle. Telangiectasia was visible in the middle of the plaque, surrounded by several papules and nodules. (b) Findings 15 months post-treatment. The plaque was thinned (which was more obvious in the marked yellow rectangular regions) after the use of oral acitretin and hydroxychloroquine and 10 pulsed-dye laser therapy sessions. These changes were more clearly visible in the central lesion, where several tiny islands of normal skin had appeared (green arrows). Telangiectasia was less obvious (yellow arrow). However, some small papules had emerged in the periphery (blue arrows).

(595 nm, 6 ms, 7 mm) at 1- to 2-month intervals. Fifteen months later, the treated area showed improvement after 10 PDL therapy sessions (Figure 1(b)). The plaque was thinner than at the beginning of the treatment and was more visible in the central area of the lesion. Moreover, several tiny islands of normal skin had appeared. Telangiectasia was less obvious than at baseline. However, small emerging papules continued to develop in the periphery.

Discussion

PDL therapy is mainly applied to treat vascular dermatoses based on the principle of

selective photothermolysis to destroy vessels. Nevertheless, several reports have described extensive use of PDL therapy in patients with lupus erythematosus,³⁻⁵ hypertrophic scars,⁶⁻⁸ and keloids.^{6,8,9} The mechanisms likely underlying the action of PDL therapy include stimulation of immunomodulatory processes,⁸ downregulation of connective tissue growth factor expression,¹⁰ and hypoxemia leading to alterations in local collagen production and increases in matrix metalloproteinases.¹¹ Therefore, these factors may represent targets for PDL therapy in patients with cutaneous sarcoidosis. In addition, various studies have suggested that angiogenic and

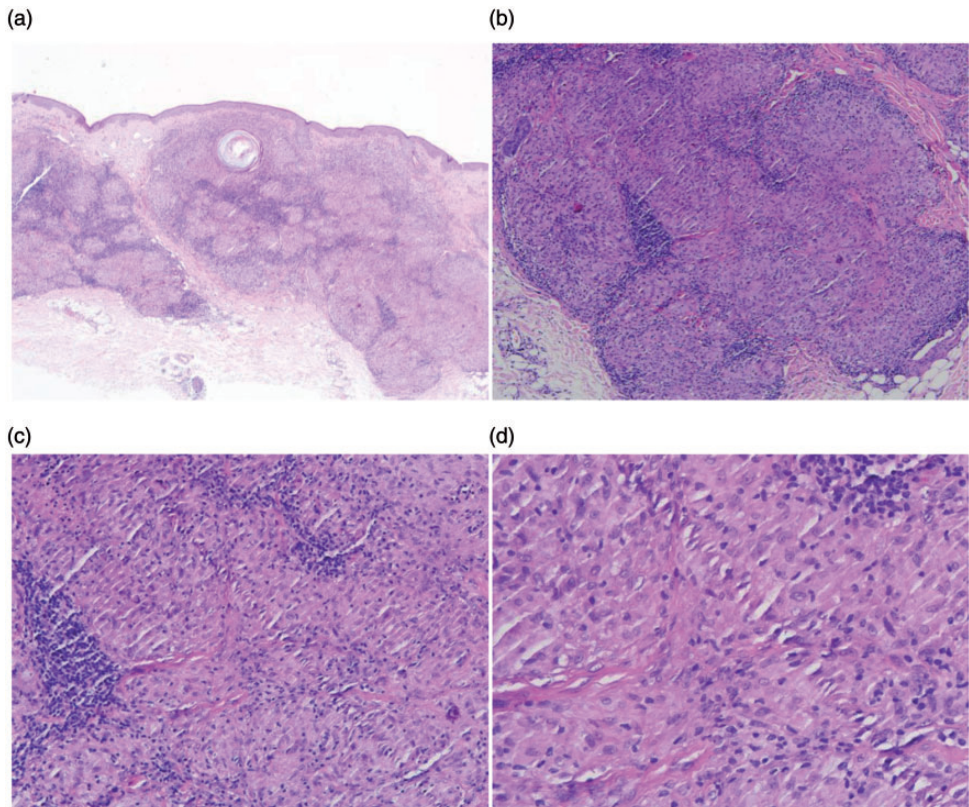


Figure 2. Histologic findings (hematoxylin and eosin staining). The epidermis was generally normal. Granulomas composed of epithelioid cells and surrounded by lymphocyte-dominant inflammation were present in the dermis. Multinucleated giant cells were also visible.

angiostatic factors contribute to the pathogenesis of sarcoidosis,^{12–14} further emphasizing the value and significance of PDL therapy in the treatment of cutaneous sarcoidosis.

A case of cutaneous sarcoidosis successfully treated with PDL therapy alone was reported by Roos et al.¹⁵ Although the patient subsequently developed disease involvement in the right calf and eyes that was eventually eliminated by systemic steroids, she remained free of skin lesions after the steroids were discontinued. Our case is similar in that improvements were achieved only in the areas treated with PDL therapy. Although oral anti-inflammatory medications were simultaneously administered, lesions continued to develop in the periphery. We considered that the patient's disease condition was in a progressive stage despite the lack of evidence of systemic involvement. In fact, glucocorticoid therapy was preferred for better control but was refused by the patient. Therefore, we could only provide relatively conservative treatment involving oral acitretin and hydroxychloroquine along with PDL therapy. Meanwhile, regular reevaluation by chest computed tomography and related laboratory tests was necessary to monitor for systemic involvement.

As in the previous report by Roos et al.,¹⁵ our case reveals the potential clinical value of PDL therapy in the treatment of cutaneous sarcoidosis. Large-sample randomized controlled trials are required to investigate the application of this therapy and elucidate the precise underlying mechanisms of action.

Ethics approval and consent to participate

The patient provided written informed consent for biopsy, treatment, and publication of this report. This case report was written according to the CARE Guidelines. Ethics committee/

review board approval was not needed because of the nature of this study (case report).

Declaration of conflicting interest

The authors declare that there is no conflict of interest.

Funding

This research received no specific grant from any funding agency in the public, commercial, or not-for-profit sectors.

Authors' contributions

WD: manuscript drafting and laser operation.

CL: manuscript revision.

YS: laser operation.


WZ: study design and critical revision of the manuscript.

All authors have read and approved the manuscript.

Availability of data and materials

The datasets used and/or analyzed during the current study are available from the corresponding author on reasonable request.

ORCID iD

Wei Zhang  <https://orcid.org/0000-0002-5497-9926>

References

1. Valeyre D, Prasse A, Nunes H, et al. Sarcoidosis. *Lancet* 2014; 383: 1155–1167.
2. Baughman RP, Teirstein AS, Judson MA, et al. Clinical characteristics of patients in a case control study of sarcoidosis. *Am J Respir Crit Care Med* 2001; 164: 1885–1889.
3. Erceg A, Bovenschen HJ, Van De Kerkhof PC, et al. Efficacy and safety of pulsed dye laser treatment for cutaneous discoid lupus erythematosus. *J Am Acad Dermatol* 2009; 60: 626–632.
4. Ekback MP and Troilius A. Laser therapy for refractory discoid lupus erythematosus when everything else has failed. *J Cosmet Laser Ther* 2013; 15: 260–265.
5. Rerknimitr P, Tekacharin N, Panchaprateep R, et al. Pulsed-dye laser as an adjuvant

- treatment for discoid lupus erythematosus: a randomized, controlled trial. *J Dermatolog Treat* 2019; 30: 81–86.
6. Gauglitz GG. Management of keloids and hypertrophic scars: current and emerging options. *Clin Cosmet Investig Dermatol* 2013; 6: 103–114.
 7. Vrijman C, Van Drooge AM, Limpens J, et al. Laser and intense pulsed light therapy for the treatment of hypertrophic scars: a systematic review. *Br J Dermatol* 2011; 165: 934–942.
 8. Karsai S, Roos S, Hammes S, et al. Pulsed dye laser: what's new in non-vascular lesions? *J Eur Acad Dermatol Venereol* 2007; 21: 877–890.
 9. Wolfram D, Tzankov A, Püzl P, et al. Scars and keloids—review of their pathophysiology, risk factors, and therapeutic management. *Dermatol Surg* 2009; 35: 171–181.
 10. Yang Q, Ma Y, Zhu R, et al. The effect of flashlamp pulsed dye laser on the expression of connective tissue growth factor in keloids. *Lasers Surg Med* 2012; 44: 377–383.
 11. Mokos ZB, Jovic A, Grgurevic L, et al. Current therapeutic approach to hypertrophic scars. *Front Med (Lausanne)* 2017; 4: 83.
 12. Lazarus A. Sarcoidosis: epidemiology, etiology, pathogenesis, and genetics. *Dis Mon* 2009; 55: 649–660.
 13. Thomas KW and Hunninghake GW. Sarcoidosis. *JAMA* 2003, 289: 3300–3303.
 14. Tzouvelekis A, Ntoliou P, Karameris A, et al. Expression of hypoxia-inducible factor (HIF)-1 α -vascular endothelial growth factor (VEGF)-inhibitory growth factor (ING)-4-axis in sarcoidosis patients. *BMC Res Notes* 2012; 5: 654.
 15. Roos S, Raulin C, Ockenfels HM, et al. Successful treatment of cutaneous sarcoidosis lesions with the flashlamp pumped pulsed dye laser: a case report. *Dermatol Surg* 2009; 35: 1139–1140.