

Multidirectional Instability Accompanying an Inferior Labral Cyst

Chang-Yun Moon, MD, Jong-Hun Ji, MD, Sung-Jae Kim, MD*

Department of Orthopedic Surgery, Daejeon St. Mary's Hospital, The Catholic University College of Medicine, Daejeon,

*Department of Orthopedic Surgery, Yonsei University College of Medicine, Seoul, Korea

Paralabral cyst of the shoulder joint can be observed in 2% to 4% of the general population, particularly in men during the third and fourth decade. On average, these cysts measure 10 mm to 20 mm in diameter and are located preferentially on the postero-superior aspect of the glenoid. The MRI has increased the frequency of the diagnosis of paralabral cysts of the shoulder joint. Paralabral cysts of the shoulder joint usually develop in the proximity of the labrum. The relationship between shoulder instability and labral tears is well known, however, the association of shoulder instability with a paralabral cyst is rare. Shoulder instability may cause labral injury or labral injury may cause shoulder instability, and then injured tear develops paralabral cyst. In our patient, the inferior paralabral cyst may be associated with inferior labral tears and instability MRI.

Keywords: Shoulder, Instability, Inferior labral cyst

The widespread use of MRI has increased the frequency of diagnosing paralabral cysts of the shoulder joint. Paralabral cysts of the shoulder joint usually develop in the proximity of the labrum. The underlying cause of paralabral cysts has not yet been identified. We treated a case with a paralabral cyst of the shoulder, and this lesion was associated with an inferior labral tear and multidirectional instability.

CASE REPORT

A 20-year-old man had a history of multiple subluxation/dislocation episodes of the shoulder joint for several years and he could voluntarily dislocate his shoulder. Six months ago, his shoulder pain increased after strenuous exercise. He had full range of motion of the shoulder joint. The physical examination showed the sulcus sign (grade 2), a positive anterior drawer test (grade 2) and a positive posterior drawer test (grade 2). The anterior and posterior

apprehension test was also positive.

Preoperatively, the Rowe score was 35 and the American Shoulder and Elbow Surgeons (ASES)/ University of California, Los Angeles (UCLA) score was 80 and 25 respectively. The simple radiologic findings showed no bony abnormalities. MRI of the left shoulder demonstrated a multiseptated cyst in the inferior aspect of the glenoid neck and a suspected labral tear (arrows) (Fig. 1). The electromyogram findings showed non-specific findings. We initially recommend physical therapy such as stretching and strengthening exercise. However, his symptoms were not improved after 6 months of rehabilitation.

Arthroscopic Findings

The patient was placed in the lateral decubitus position with longitudinal traction of the affected upper limb and he was given general anesthesia. An arthroscope was inserted through a posterior portal, and the intra-articular lesions were examined. The drive-through sign was seen in the glenohumeral joint. The biceps tendon and rotator cuff tendon were intact. The arthroscopic findings showed a 2 × 1 cm sized multilobulated cyst on the inferior labrum from 6 o'clock to 7 o'clock (Fig. 2). A whitish colored cystic sac was found and then mucinous fluid was noted after

Received July 31, 2008; Accepted December 15, 2008

Correspondence to: Chang-Yun Moon, MD

Department of Orthopaedic Surgery, Daejeon St. Mary's Hospital, Dae-hung-dong, Jung-gu, Daejeon 301-723, Korea

Tel: +82-42-220-9530, Fax: +82-42-221-0429

E-mail: osmcy@naver.com

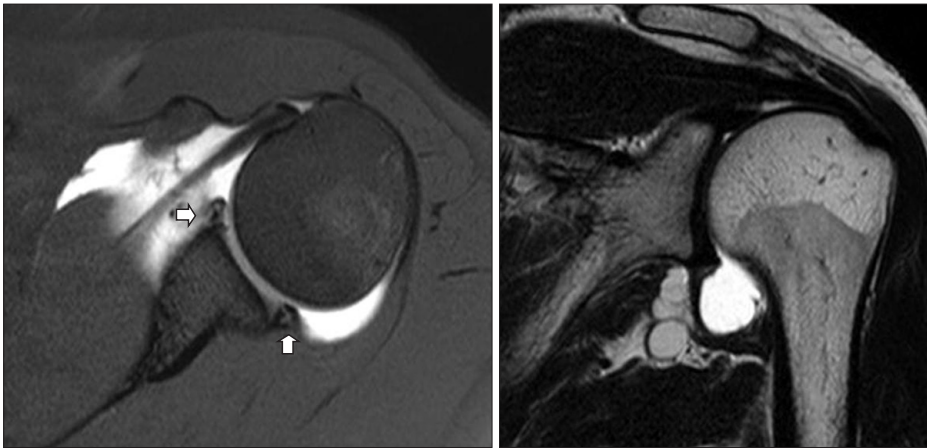


Fig. 1. MRI of the left shoulder demonstrates a multiseptated cyst at the inferior aspect of the glenoid neck and a suspected labral tear (arrows).

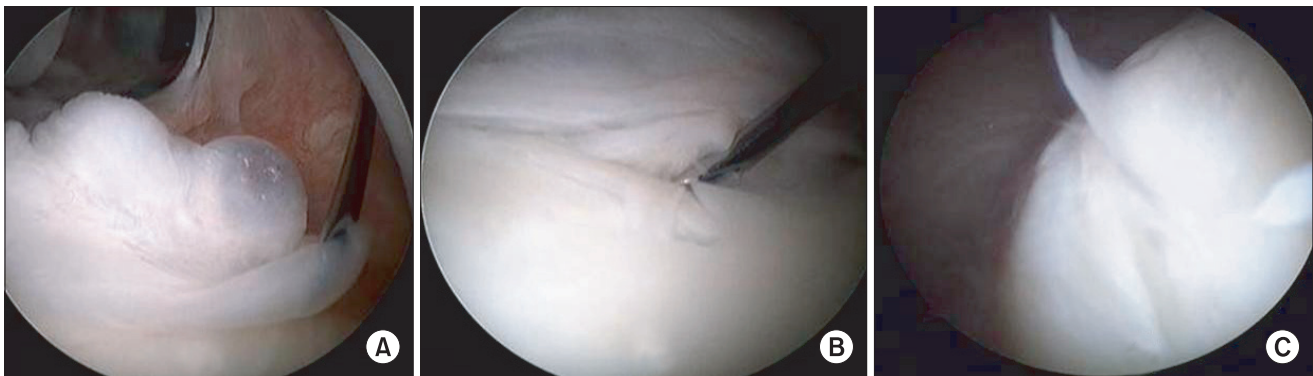


Fig. 2. The arthroscopic findings showed a 2 × 1 cm multilobulated cyst at the antero-inferior labrum from 4 o'clock to 6 o'clock, and the cyst was filled with mucinous fluid (A) Incomplete detachment of the inferior labrum and a marginal crack could be detected (B) but complete detachment of the postero-inferior labrum was confirmed with a probe.

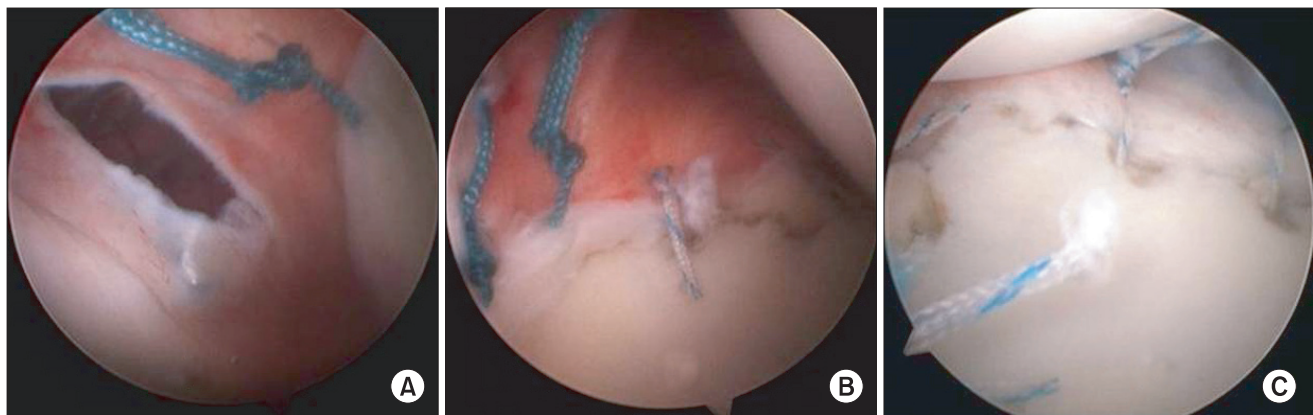

Fig. 3. The arthroscopic photograph shows complete suturing of the capsular plication (A), the antero-inferior labral repair (B), and the postero-inferior labral repair (C).

piercing the sac with a spinal needle. The remnant of the synovial sac was decompressed and debrided with an arthroscopic shaver. A punch biopsy of the synovial sac was performed. The arthroscopic findings showed a 2 × 1 cm multilobulated cyst at the antero-inferior labrum from

4 o'clock to 6 o'clock, and the cyst was filled with mucinous fluid (Fig. 2A). Seemingly, incomplete detachment of the inferior labrum and a marginal crack could be detected (Fig. 2B), but complete detachment of the postero-inferior labrum was confirmed with a probe (Fig. 2C).

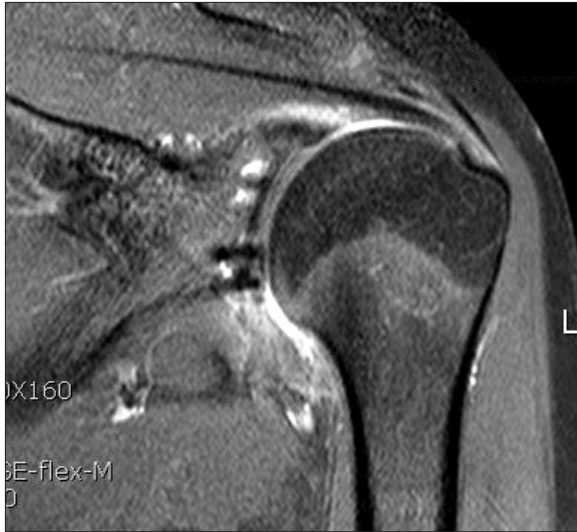

Fig. 4. The previously noted cyst is no longer seen on the postoperative follow-up MRI.

We debrided and detached the labral tear site completely and then arthroscopic anterior and posterior labroplasty was done with suture anchors (Smith & Nephew, Andover, MA, USA). Three anchors were initially used and these were inserted into the postero-inferior glenoid and then the posterior labral repair was done (Fig. 3A) Two more anchors were inserted into the antero-inferior glenoid and then labroplasty was done (Fig. 3B). Also, the capsular defect produced by the excisional procedure was repaired with #2 ethibond (Fig. 3C). Finally, inferior capsular plication and rotator interval closure were done with # 2.0 polydioxane sutures to augment the capsular redundancy. The drive-through sign disappeared after the operation. Pendulum exercise was started on postoperative one day. During the following six weeks, passive range of motion was continued and we kept the abduction brace on his shoulder. After six weeks, we started strengthening exercise for the rotator cuff muscles and the scapular stabilizing muscles. At postoperative 2 years, the patient has had pain-free shoulder motion and no further dislocation. Physical examination showed the sulcus sign (grade 1+), an anterior drawer test of grade 1+, a posterior drawer test of grade 1+ and a negative apprehension test. At the last follow-up, the Rowe score was 85 and the ASES/UCLA score was 98.5 and 33, respectively. The follow-up MRI showed complete resolution of the inferior paralabral cyst (Fig. 4).

DISCUSSION

Shoulder instability is divided voluntary and involuntary

instability. For the case of involuntary instability, surgical treatment is necessary, but for the case of voluntary instability, the surgical indications should be strict because of secondary compensation such as military issues and the occupational worker's gain. If there is a pathologic condition such as labral tear, cyst and/or rotator cuff injury, then surgical treatment should be considered.

A paralabral cyst of the shoulder joint can be observed in 2% to 4% of the general population, and particularly in men during the third and fourth decades. On average, these cysts measure 10 mm to 20 mm in diameter and they are preferentially located on the postero-superior aspect of the glenoid.¹⁾

The cysts may or not be observed to communicate with a labral tear. Westerheide et al.²⁾ and Westerheide and Karzel³⁾ advocated that labral pathology was the main cause of periarticular cysts. On the contrary, Piatt et al.⁴⁾ reported that paralabral cysts spontaneously resolved in 2 patients, as assessed on MRI. Youm et al.⁵⁾ reported that repair of a labral tear, without cyst excision, resulted in successful outcomes for all 10 patients who had spinoglenoid cysts associated with superior labral tears. They advocated that the treatment given for intra-articular disease was the key component of the surgical management.

The symptoms of a paralabral cyst may be the result of rotator cuff disease, labral disease, entrapment syndrome from compression of the suprascapular nerve, instability or a combination of these conditions.^{1,4,6,7)} The most common complication is the suprascapular nerve entrapment syndrome, which leads to pain and supraspinatus and/or infraspinatus atrophy. In the shoulder, a labral tear can cause mechanical symptoms and instability symptoms. The English medical literature shows only 3 reports of the paralabral cyst of the shoulder associated with glenohumeral instability.⁸⁻¹⁰⁾ Our current report is a rare case of inferior paralabral cyst combined with multidirectional instability. The previous reports only describe anterior, posterior and superior paralabral cyst with shoulder instability. Ferrick and Marzo⁹⁾ reported that suprascapular entrapment neuropathy with ganglion is related to posterior shoulder instability. Dietz et al.⁸⁾ reported that anterior-inferior labral cyst with an anterior labral tear was related with non-traumatic shoulder instability, and Yukata et al.¹⁰⁾ also reported that paralabral cyst of the shoulder was associated with recurrent anterior dislocation. Tirman et al.¹¹⁾ reported that labral cysts may be an indicator of labrocapsular injury and instability, and so taking a careful history and a thorough physical examination to detect instability should

be considered. In that report, the physical examination showed glenohumeral instability in the direction of the labral tear and a cystic-appearing mass in 11 patients (11/20, 55%); the instability pattern was multidirectional in three patients and unidirectional in eight patients. Our case was an inferior paralabral cyst with an inferior labral tear. We performed inferior labroplasty combined with rotator interval closure. This cyst was just nearby the axillary nerve, but the postoperative deltoid function was unaffected. So, we suspected that repetitive microtrauma was the main cause of the inferior labral tear and the paralabral cyst. The relationship between shoulder instability and labral tears is well known, yet the association of shoulder instability with a paralabral cyst is

rare. We considered that there was the cyclic correlation of shoulder instability, labral tear and paralabral cyst. In the future, we will study the direct relationship between shoulder instability and paralabral cyst.

Shoulder instability may cause labral injury, or labral injury may cause shoulder instability, and then the injured tear labrum develops a paralabral cyst. In our patient, the inferior paralabral cysts may have been associated with inferior labral tears and instability.

CONFLICT OF INTEREST

No potential conflict of interest relevant to this article was reported.

REFERENCES

1. Gartsman GM. Shoulder arthroscopy. Philadelphia: WB Saunders; 2003. 162-8.
2. Westerheide KJ, Dopirak RM, Karzel RP, Snyder SJ. Suprascapular nerve palsy secondary to spinoglenoid cysts: results of arthroscopic treatment. *Arthroscopy*. 2006;22(7): 721-7.
3. Westerheide KJ, Karzel RP. Ganglion cysts of the shoulder: technique of arthroscopic decompression and fixation of associated type II superior labral anterior to posterior lesions. *Orthop Clin North Am*. 2003;34(4):521-8.
4. Piatt BE, Hawkins RJ, Fritz RC, Ho CP, Wolf E, Schickendantz M. Clinical evaluation and treatment of spinoglenoid notch ganglion cysts. *J Shoulder Elbow Surg*. 2002;11(6): 600-4.
5. Youm T, Matthews PV, El Attrache NS. Treatment of patients with spinoglenoid cysts associated with superior labral tears without cyst aspiration, debridement, or excision. *Arthroscopy*. 2006;22(5):548-52.
6. Drez D Jr. Suprascapular neuropathy in the differential diagnosis of rotator cuff injuries. *Am J Sports Med*. 1976; 4(2):43-5.
7. Fritz RC, Helms CA, Steinbach LS, Genant HK. Suprascapular nerve entrapment: evaluation with MR imaging. *Radiology*. 1992;182(2):437-44.
8. Dietz SO, Lichtenberg S, Habermeyer P. Non-traumatic shoulder instability in an athletic patient with a periglenoid cyst and a glenoid labral tear. *Acta Orthop Belg*. 2003; 69(4):373-6.
9. Ferrick MR, Marzo JM. Ganglion cyst of the shoulder associated with a glenoid labral tear and symptomatic glenohumeral instability: a case report. *Am J Sports Med*. 1997; 25(5):717-9.
10. Yukata K, Imada K, Yoshizumi Y, Tamano K, Hosokawa S, Nakaima N. Intra-articular ganglion cyst (paralabral cyst) of the shoulder associated with recurrent anterior dislocation: a case report. *J Shoulder Elbow Surg*. 2002;11(1):95-7.
11. Tirman PF, Feller JF, Janzen DL, Peterfy CG, Bergman AG. Association of glenoid labral cysts with labral tears and glenohumeral instability: radiologic findings and clinical significance. *Radiology*. 1994;190(3):653-8.