


ORIGINAL RESEARCH

Intracordal injection therapy for vocal fold scarring: Steroid versus basic fibroblast growth factor

Miki Nozawa MD^{1,2} | Satoka Takahashi MD^{1,2} | Takeharu Kanazawa MD, PhD^{1,2}  | Kazuya Kurakami MD, PhD^{2,3} | Tomohiro Hasegawa MD² | Mayu Hirosaki MD² | Manami Kamitomai MD² | Daigo Komazawa MD^{2,4} | Ujimoto Konomi MD, PhD^{2,5} | Makoto Ito MD, PhD¹ | Yusuke Watanabe MD²

¹Division of Laryngeal Surgery, Department of Otolaryngology-Head and Neck Surgery, School of Medicine, Jichi Medical University, Shimotsuke, Japan

²Tokyo Voice Center, International University of Health and Welfare, Tokyo, Japan

³Department of Otolaryngology-Head and Neck Surgery, Yamagata University, Faculty of Medicine, Yamagata, Japan

⁴AKASAKA Voice Health Center, Tokyo, Japan

⁵Voice and Dizziness Clinic Futakotamagawa Otolaryngology, Tokyo, Japan

Correspondence

Takeharu Kanazawa, Division of Laryngeal Surgery, Department of Otolaryngology-Head and Neck Surgery, School of Medicine, Jichi Medical University, Shimotsuke 329-0498, Japan.

Email: kanatake@omiya.jichi.ac.jp

Funding information

Tokyo Voice Center at the International University of Health and Welfare; Division of Laryngeal Surgery, Department of Otolaryngology, at the Jichi Medical University

Abstract

Objectives: Vocal fold scarring is caused by replacement of vocal fold mucosa with fibrous tissue due to repeated inflammation or trauma. It can lead to severe dysphonia. It is currently treated conservatively and with phonosurgery and intracordal injections. Intracordal injection of steroid or basic fibroblast growth factor (bFGF) has been recently found to be useful for treating vocal fold scarring that does not respond to voice therapy.

Methods: This retrospective study involved the administration of steroid injection and bFGF injection bilaterally under local anesthesia in 16 patients each. Laboratory measurements of voice parameters were performed before and 3–6 months after injection.

Results: In the steroid injection group, the Voice Handicap Index (VHI) score significantly improved from 57.1 to 40.5, total Grade, Roughness, Breathiness, Asthenia, Strain (tGRBAS) score significantly improved from 4.2 to 2.6, and mean speech fundamental frequency (SFF) increased from 192.5 to 211.4 dB, but there was no improvement in maximum phonation time (MPT) and mean airflow rate (MFR). In the bFGF injection group, significant improvements in the VHI score (from 53.3 to 35.7), MPT (from 16.9 to 21.8 s) and MFR (from 314.6 to 210.5 ml/s) were seen; however, the tGRBAS score did not improve. In addition, the SFF significantly decreased from 178.1 to 160.5 Hz.

Conclusion: These results suggest that both steroid and bFGF injections are effective for treating vocal fold scarring, with steroids improving voice quality and bFGF improving glottic closure, thereby contributing to improvements in VHI scores.

Level of Evidence: 4.

KEYWORDS

bFGF, intracordal injection therapy, office surgery, steroids, vocal fold scarring

Miki Nozawa and Satoka Takahashi contributed equally to this study and are designated as co-first authors.

This is an open access article under the terms of the [Creative Commons Attribution-NonCommercial-NoDerivs](https://creativecommons.org/licenses/by-nc-nd/4.0/) License, which permits use and distribution in any medium, provided the original work is properly cited, the use is non-commercial and no modifications or adaptations are made.

© 2022 The Authors. *Laryngoscope Investigative Otolaryngology* published by Wiley Periodicals LLC on behalf of The Triological Society.

1 | INTRODUCTION

Vocal fold scarring is caused by inflammation, surgical trauma, and congenital lesions. It results in dysphonia and impaired communication.¹ Histologically, it is characterized by disorganized collagen and elastin bundles with loss of important extracellular matrix constituents, resulting in vocal fold hardening, suppression of mucosal vibrations, and an increase in the glottal gap.^{2,3} Its treatment is mainly conservative (voice therapy), although the microflap technique and laryngeal framework surgery are sometimes performed.^{3,4}

Conservative treatment is minimally invasive but has a long treatment period and unestablished protocol; therefore, there remains room for further study.⁵ Scar removal and fascial grafting through vocal fold surgery, although reportedly effective,^{3,6} are not widely performed because they require general anesthesia and involve advanced surgical techniques. Intracordal drug injection is an intermediate approach between conservative treatment and surgery. Intracordal injection of several materials, including atelocollagen,⁷ autologous fat,⁸ and calcium hydroxylapatite,⁹ is currently used to treat dysphonia. Steroid injection is widely used to treat benign vocal fold lesions, including vocal fold scarring.¹⁰⁻¹³ Steroid injection alters cytokine secretion, which could decrease fibrosis, thereby improving the vibratory ability of the vocal folds.^{11,14} Steroid injection immediately following trauma reportedly causes decreased collagen deposition, leading to decreased fibrosis.¹⁵ Steroid injection has been found to reduce rigidity¹⁶ and vocal strain and improve vibration in patients with vocal fold scarring,¹⁷ and they can be used to soften the scarred vocal fold in patients with hypertrophic vocal fold scars.

Recent advances in molecular biology have led to the development of tissue engineering techniques that use growth factors, cells, and scaffolding. In particular, growth factor injection is relatively simple and has been applied in several fields. Basic fibroblast growth factor (bFGF) is among the most commonly used growth factors and is already being used to treat various vocal fold lesions.¹⁸⁻²¹ However, few studies have investigated the therapeutic effects of bFGF on phonological function in patients with vocal fold scarring.¹⁸ bFGF administration can stimulate fibroblast proliferation and promote synthesis of extracellular matrix, leading to increased hyaluronic acid and matrix metalloproteinase production and reduced collagen deposition, thereby increasing the thickness of the superficial lamina propria (SLP).^{22,23} At our institution, good outcomes have been achieved using bFGF injection in patients with vocal fold paralysis,¹⁹ vocal fold atrophy,²¹ and vocal fold sulcus.²⁰ This has led to the use of bFGF to treat vocal fold scarring. However, the drug to be used remains to be elucidated, and the improvement of dysphonia would differ depending on the drug used due to differences in mechanisms of action. Histological studies using animal models have demonstrated that steroid²⁴ and bFGF injections^{25,26} have different effects on scarred vocal folds. Furthermore, in our preliminary study, glottic insufficiency on laryngeal stroboscopy did not noticeably reduce after steroid injection, but after bFGF injection, vocal cords were thickened and glottic insufficiency was clearly reduced. The purpose of this study was to

retrospectively examine the effects of intracordal injections performed to treat vocal fold scarring and compare the improvements in phonological outcomes between steroid and bFGF injections. We ultimately aim to determine an effective treatment for vocal fold scarring and ascertain its characteristics.

2 | MATERIALS AND METHODS

2.1 | Study participants

This study was approved by the Institutional Review Board of the International University of Health and Welfare (14-S-3). Before injection, written informed consent was obtained from all patients. We enrolled 32 patients who underwent intracordal vocal fold injection at the International University of Health and Welfare Tokyo Voice Center and underwent laboratory measurements of voice parameters before and 3–6 months after injection, as confirmed using medical records. None of the participants had a previous history of intracordal injection, and they were divided into an steroid injection and a bFGF injection group, with each group comprising 16 patients.

2.2 | Study outcomes

The primary study outcome was the Voice Handicap Index (VHI) score, which was used to determine the therapeutic effects of the injections. The secondary outcomes were laboratory measurements of voice parameters, which were used to elucidate the indications for these therapies.

2.3 | Injection procedure

We used a triamcinolone acetonide with a depot solution to prolong the development period (KENACORT-A; Bristol-Myers Squibb K.K.) or human recombinant bFGF (Fiblast; Kaken Pharmaceutical Company, Ltd.). The KENACORT-A or bFGF was injected bilaterally under local anesthesia. The pharynx and larynx were completely anesthetized with 4% lidocaine. Under transnasal fiberoptic laryngeal monitoring, 3 mg of triamcinolone acetonide dissolved in 0.3 ml of depot solution per side or 50 µg of bFGF (in 0.5 ml of saline) was injected into and spread onto the SLP using a 23-gauge injection needle (Varixer; TOP Corp.). The doses of triamcinolone acetonide or bFGF were determined according to the manufacturer's instructions and previous studies.^{13,18} To detect possible allergic reactions, the vocal folds were checked using a fiberscope 1 h after injection. Participants were instructed to rest their voices on the day of the injection but were allowed to use their voices from the following day onwards according to our previously reported injection protocol.

2.4 | Laboratory measurements of voice parameters

Phonological outcomes, maximum phonation time (MPT), mean airflow rate (MFR), pitch range (PR), jitter, shimmer, speech fundamental frequency (SFF), and noise-to-harmonic ratio (NHR) were evaluated and the Japanese version of the VHI²⁷ was administered at 3–6 months after injection. MFR was determined using a Phonatory Function Analyzer (PS-77E; Nagashima Medical Instruments Company, Ltd.). Jitter, shimmer, SFF, and NHR were measured using a computerized speech lab device (Model 4500; KayPENTAX). PR was assessed using an objective method with a pitch meter and keyboard. All evaluations were performed by skilled speech-language-hearing therapists.

2.5 | Statistical analysis

Differences between the means of preinjection and postinjection values were analyzed using the Wilcoxon matched-pair signed-rank test. The analysis was performed using Statistical Package for the Social Sciences statistical software (version 19.0). Statistical significance was set at $p < .01$ or $p < .05$.

3 | RESULTS

3.1 | Patient characteristics

The steroid injection group comprised 2 men and 14 women, with a mean age of 45.1 years (range: 23–67 years). Nine, five, and two patients had bilateral surgical trauma to the vocal folds, unilateral trauma, and inflammatory scarring, respectively. The primary diseases were Reinke's edema, nodules, cysts, polyps, and chondritis in six, four, two, two, and two patients, respectively (Table 1). All patients had experienced persistent dysphonia, which was not improved after 2–3 months of conservative treatments such as voice hygiene, voice rehabilitation, or medication. The bFGF injection group comprised 11 men and 5 women, with a mean age of 55.6 years (range: 31–75 years). Six, eight, and two patients had bilateral surgical trauma to the vocal folds, unilateral trauma, and inflammatory scarring, respectively. The primary diseases were cysts in five patients, Reinke's edema in four patients, chondritis in two patients, and nodules, polyp, laryngeal amyloidosis, laryngeal granuloma, and sulcus vocalis in one patient each (Table 2). Vocal fold scarring was diagnosed by two or three independent phonosurgeons based on a clinical history of laryngeal microsurgery and pretreatment stroboscopic findings of changes in glottal configuration, vocal fold edge linearity, vocal fold vibration amplitude, mucosal wave excursion, and periodicity.

3.2 | Adverse events

In both groups, no patient experienced allergic reactions or severe adverse effects such as muscle atrophy. Most of the patients in the

TABLE 1 Characteristics of the patients in the steroid injection group

	Sex	Age	Surgical trauma	Primary disease
1	F	49	Bilateral	Vocal fold nodule
2	F	45	Unilateral	Vocal fold polyp
3	F	48	N/A	Chondritis
4	F	45	Bilateral	Reinke's edema
5	F	36	Bilateral	Reinke's edema
6	F	62	Bilateral	Reinke's edema
7	M	44	Unilateral	Vocal fold cyst
8	F	51	Unilateral	Vocal fold cyst
9	F	41	Bilateral	Reinke's edema
10	F	43	Bilateral	Reinke's edema
11	F	39	Bilateral	Vocal fold nodule
12	F	45	Bilateral	Reinke's edema
13	F	23	Bilateral	Vocal fold nodules
14	F	39	Unilateral	Vocal fold polyp
15	F	44	N/A	Chondritis
16	M	67	Unilateral	Vocal fold nodules

Abbreviation: N/A, not applicable.

TABLE 2 Characteristics of the patients in the bFGF injection group

	Sex	Age	Surgical trauma	Primary disease
1	F	35	Unilateral	Laryngeal amyloidosis
2	M	73	Unilateral	Vocal fold polyp
3	M	60	Bilateral	Reinke's edema
4	M	65	N/A	Chondritis
5	M	71	Unilateral	Vocal fold cyst
6	M	75	Unilateral	Vocal fold cyst
7	F	31	Unilateral	Vocal fold cyst
8	M	51	Bilateral	Reinke's edema
9	M	75	Bilateral	Reinke's edema
10	M	76	Bilateral	Reinke's edema
11	F	41	Unilateral	Vocal fold cyst
12	F	29	Unilateral	Vocal fold cyst
13	M	40	Unilateral	Laryngeal granuloma
14	M	66	Bilateral	Vocal fold nodules
15	F	30	Bilateral	Sulcus vocalis
16	M	71	N/A	Chondritis

Abbreviations: bFGF, basic fibroblast growth factor; N/A, not applicable.

steroid injection group experienced vocal fold hyperemia and/or hematoma for a couple of weeks, but they recovered within a month. Some patients in the bFGF injection group experienced severe hoarseness associated with transient hyperemia, but they recovered completely.

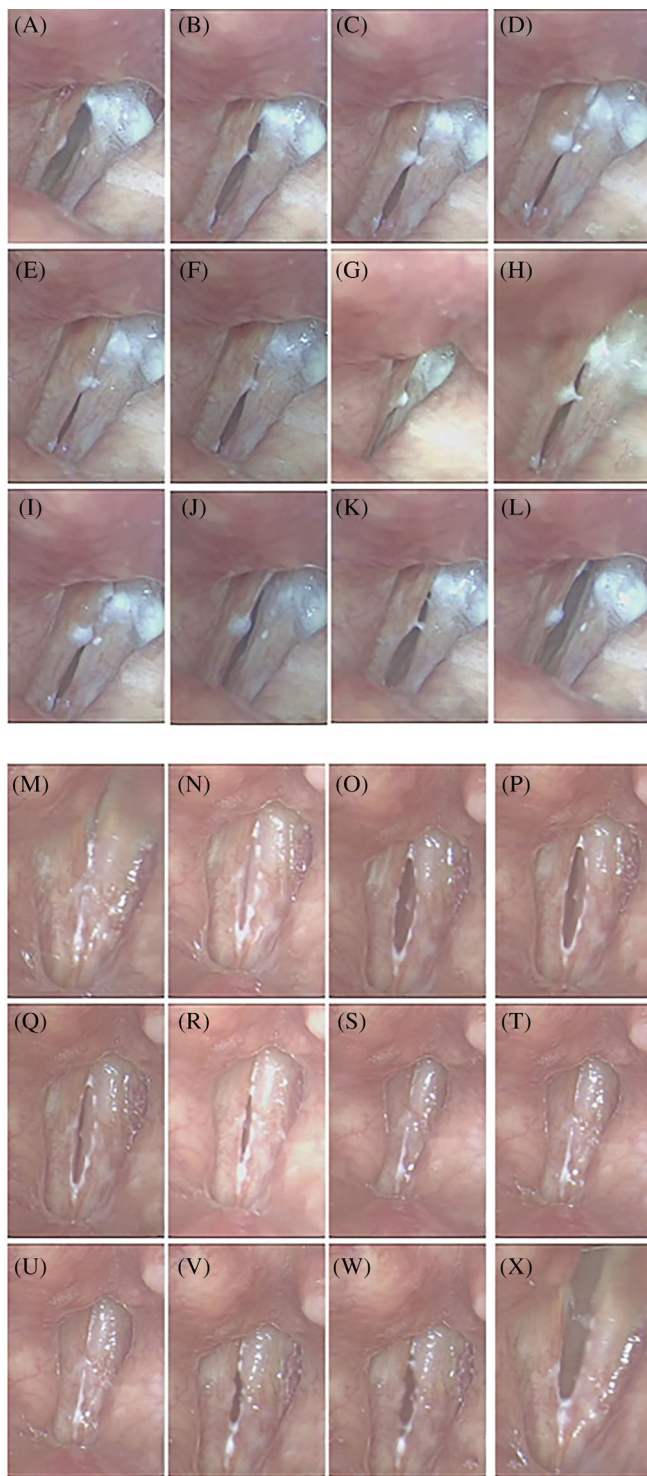


FIGURE 1 Stroboscopic vocal fold examination findings of a representative patient who received steroid injection. The patient, a 66-year-old man, presented with severe dysphonia. Preinjection stroboscopy images show vocal fold scarring following vocal fold surgery with a CO₂ laser for leukoplakia (A–L); the free edges of the vocal folds are irregular and stiff, and there is glottic insufficiency and decreased vibration. Three months after steroid injection, the patient's voice quality has improved. Stroboscopy images show reduced vocal fold stiffness and glottic insufficiency and improved vocal fold vibration (M–X)

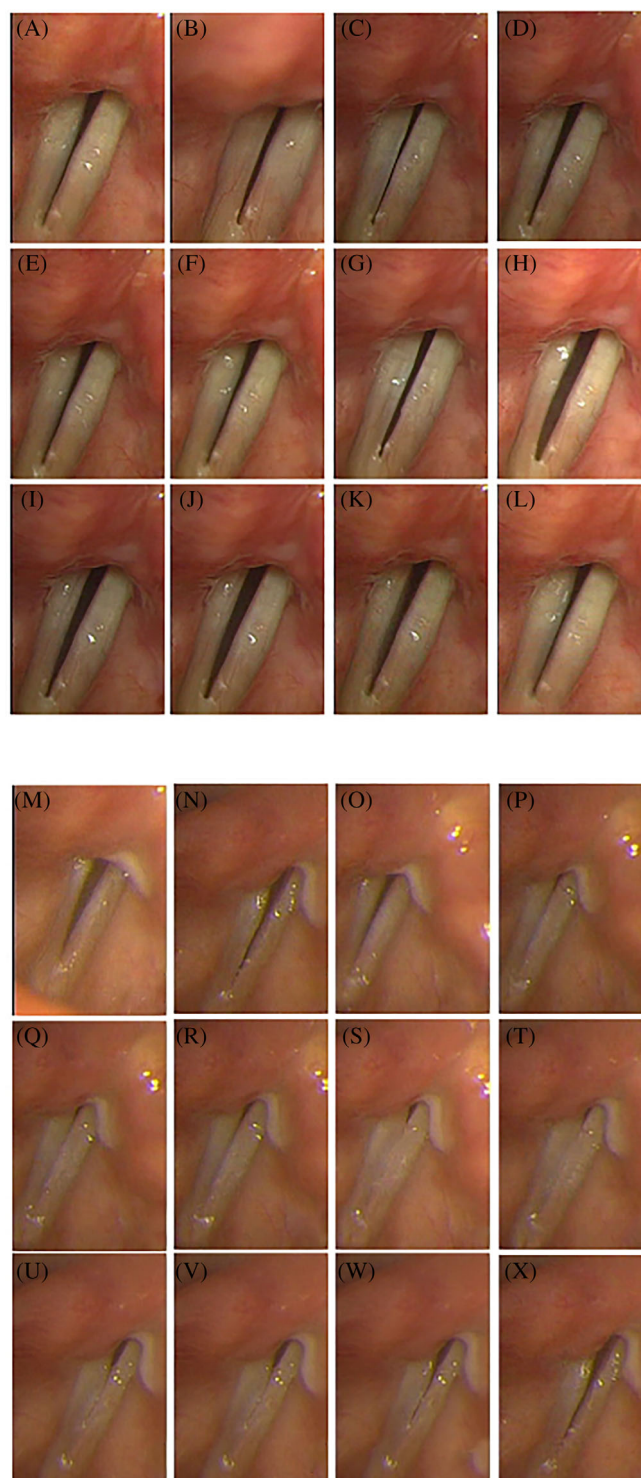


FIGURE 2 Stroboscopic vocal fold examination findings of a representative patient who received basic fibroblast growth factor injection. The patient, a 62-year-old woman, presented with severe dysphonia. Preinjection stroboscopy images show vocal fold scarring and contralateral reactive swelling following vocal fold surgery for a left vocal cyst (A–L); the free edges of the vocal folds are sharp but stiff, and there is glottic insufficiency and decreased vibration. Three months after basic fibroblast growth factor injection, the patient's maximum phonation time and maximum airflow rate significantly improved. Stroboscopy images show thickened vocal folds, reduced glottic insufficiency, and improved vocal fold vibration (M–X)

3.3 | Representative cases of steroid and bFGF injection

Steroid injection: Figure 1 shows the stroboscopic findings of a representative patient who received steroid injection. The patient, a 66-year-old man, presented with severe dysphonia. Preinjection stroboscopy revealed vocal fold scarring following vocal fold surgery with a CO₂ laser (Figure 1A–L); the free edges of the vocal folds were irregular and stiff, and there was glottic insufficiency and decreased vibration. Three months after steroid injection, the patient's voice quality improved. Stroboscopy revealed reduced vocal fold stiffness and glottic insufficiency and improved vocal fold vibration (Figure 1M–X).

bFGF injection: Figure 2 shows the stroboscopic findings of a representative patient who was treated with bFGF injection. The patient, a 62-year-old woman, presented with severe dysphonia. Preinjection stroboscopy revealed vocal fold scarring and contralateral reactive swelling following laryngeal microsurgery (Figure 2A–L); the free edges of the vocal folds were sharp but stiff, and there was glottic insufficiency and decreased vibration. Three months after bFGF injection, the MPT and MFR significantly improved. Stroboscopy revealed thickened vocal folds, reduced glottic insufficiency, and improved vocal fold vibration (Figure 2M–X).

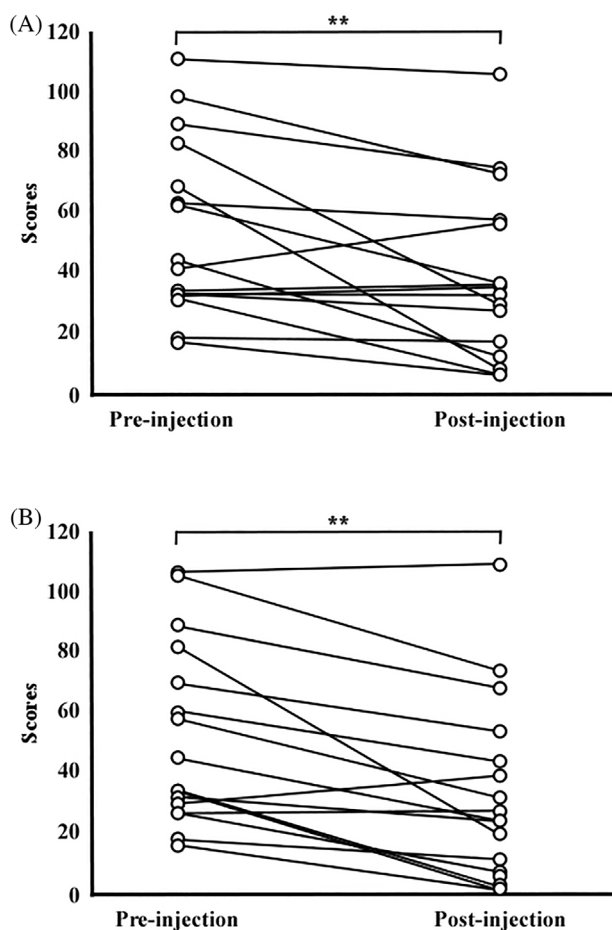


FIGURE 3 Changes in Voice Handicap Index score following steroid or basic fibroblast growth factor injection. (A) Steroid injection. (B) Basic fibroblast growth factor injection. ** $p < .01$

3.4 | Postinjection improvements in VHI scores

The VHI score improved in 14 patients in the steroid injection group. The mean VHI score in this group significantly improved, from 57.1 at preinjection to 40.5 at postinjection (Figure 3A). The VHI score improved in 12 of 15 patients in the bFGF injection group at postinjection compared with preinjection. The mean VHI score in this group significantly improved, from 53.3 at preinjection to 35.7 at postinjection (Figure 3B).

3.5 | Postinjection improvements in voice quality assessed using the Grade, Roughness, Breathiness, Asthenia, Strain scale

Voice quality was assessed using the Grade, Roughness, Breathiness, Asthenia, Strain (GRBAS) scale, which is a psychoacoustic measure of voice quality. The total GRBAS score, that is, the sum of the scores of each GRBAS subscale (tGRBAS score), showed a decrease in 10 patients in the steroid injection group at postinjection compared

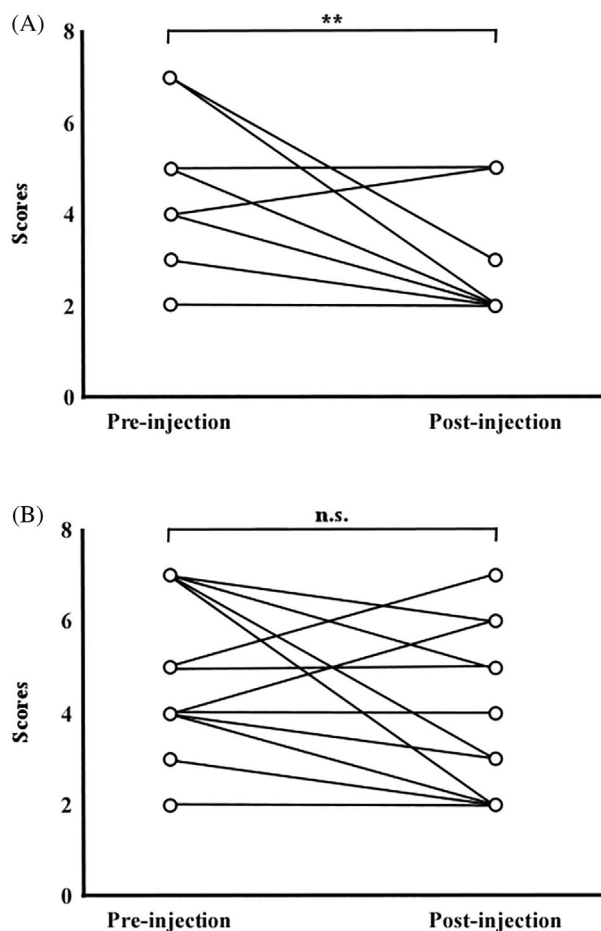


FIGURE 4 Changes in total Grade, Roughness, Breathiness, Asthenia, Strain scale score following steroid or basic fibroblast growth factor injection. (A) Steroid injection. (B) Basic fibroblast growth factor injection. ns, no significant difference. ** $p < .01$

with preinjection. The mean value in this group significantly decreased from 4.2 at preinjection to 2.9 at postinjection (Figure 4A). In terms of GRBAS subscales, the G subscale and B subscale scores significantly improved, from 1.56 (standard deviation [SD]: 0.51) to 1.12 (SD: 0.34) and from 1.19 (SD: 0.75) to 0.56 (SD: 0.51), respectively, but no significant difference was observed in other subscales. The tGRBAS score decreased in nine patients in the bFGF injection group at postinjection compared with preinjection. However, no significant difference was observed between the preinjection and postinjection total or subscale scores in this group (Figure 4B).

3.6 | Postinjection improvements in laboratory measurements of voice parameters

Aerodynamic parameters: The MPT was prolonged in nine patients in the steroid injection group at postinjection compared with preinjection. The mean MPT in this group was 13.1 s at preinjection and 14.0 at postinjection, with no significant difference observed (Figure 5A). The MPT was prolonged in 14 patients in the bFGF injection group at postinjection compared with preinjection. The mean

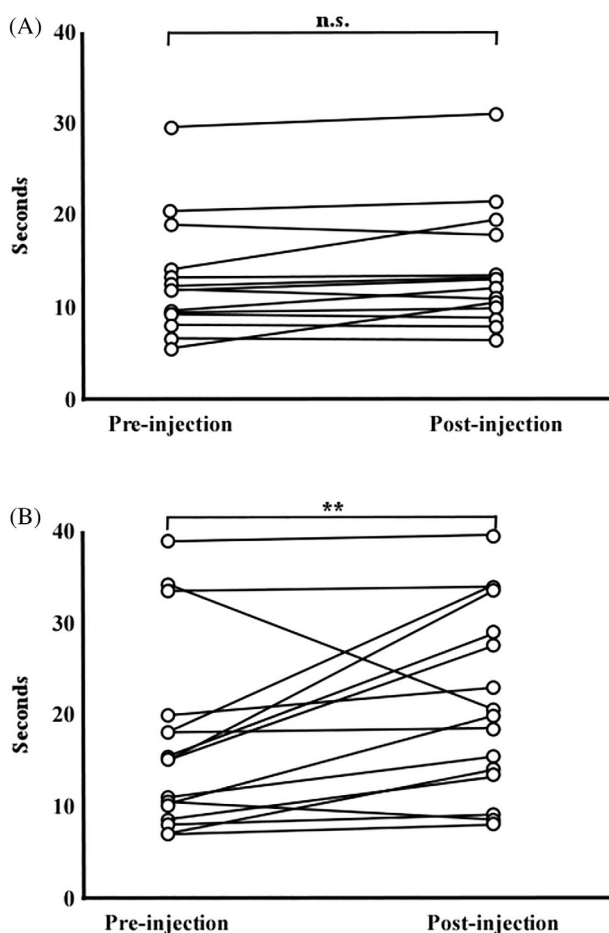


FIGURE 5 Changes in maximum phonation time following steroid or basic fibroblast growth factor injection. (A) Steroid injection. (B) Basic fibroblast growth factor injection. ns, no significant difference. $**p < .01$

MPT in this group was significantly prolonged, from 16.9 s at preinjection to 21.8 s at postinjection (Figure 5B). The MFR decreased in 10 patients in the steroid injection group at postinjection compared with preinjection. The mean MFR in this group was 277.8 ml/s at preinjection and 269.5 ml/s at postinjection, with no significant difference observed (Figure 6A). The MFR decreased in 15 patients in the bFGF injection group at postinjection compared with preinjection. The mean MFR significantly decreased in this group, from 314.6 ml/s at preinjection to 210.5 ml/s at postinjection (Figure 6B).

Acoustic parameters: The SFF increased in 11 patients in the steroid injection group at postinjection compared with preinjection. The mean SFF significantly increased in this group, from 192.5 Hz at preinjection to 211.4 Hz at postinjection (Figure 7A). The SFF decreased in 14 patients in the bFGF injection group at postinjection compared with preinjection. The mean SFF significantly decreased in this group, from 178.0 Hz at preinjection to 160.5 Hz at postinjection (Figure 7B). The PR expanded in 9 and contracted in 7 of the 16 patients in the steroid injection group. However, no significant difference was observed between the preinjection and postinjection values in this group (Figure 7A). In contrast, the PR expanded in all

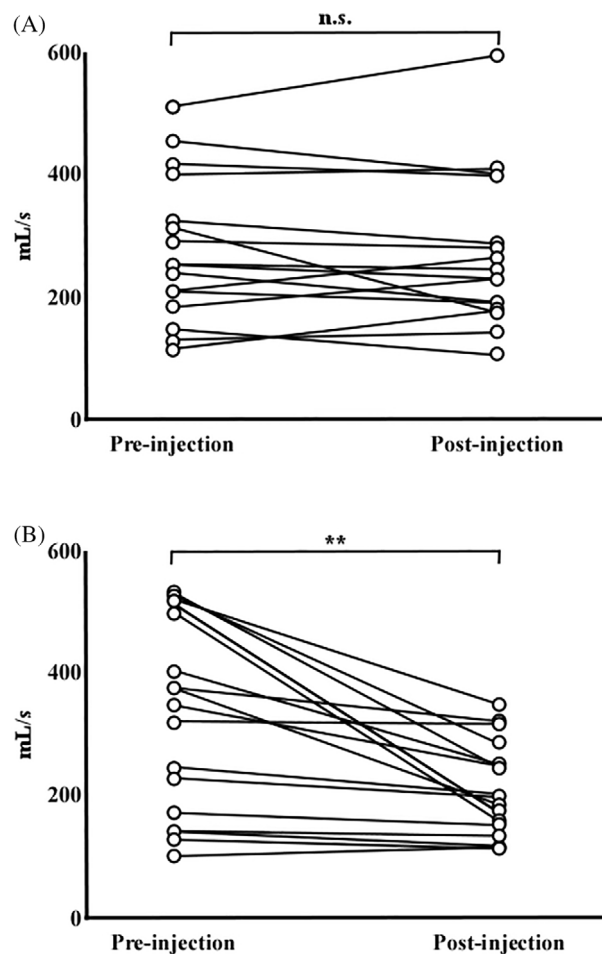


FIGURE 6 Changes in mean flow rate following steroid or basic fibroblast growth factor injection. (A) Steroid injection. (B) Basic fibroblast growth factor injection. ns, no significant difference. $**p < .01$

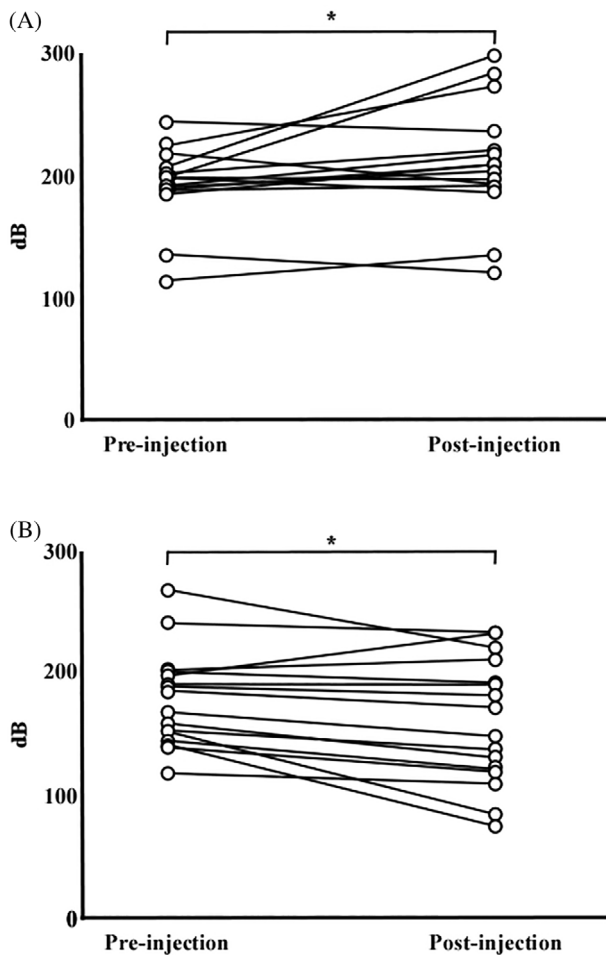


FIGURE 7 Changes in speech fundamental frequency following steroid or basic fibroblast growth factor injection. (A) Steroid injection. (B) Basic fibroblast growth factor injection. * $p < .05$

patients in the bFGF injection group (Figure 8A), and the mean PR significantly decreased from 29.0 ST at preinjection to 33.4 ST at postinjection (Figure 8B). Preinjection and postinjection jitter, shimmer, and NHR showed no difference in both groups.

4 | DISCUSSION

Vocal fold scarring results from damage to the SLP and is associated with increased stiffness and decreased mobility of the vocal fold mucosa.³ Human vocal folds have an extremely complicated three-layered structure,³ and the treatment of vocal fold scarring, in which this structure is disrupted, is an unsolved problem. Vocal fold scarring is characterized by disorganization of collagen and elastin bundles, replacement of type III collagen with type I collagen, loss of important extracellular matrix components, and changes in viscoelastic properties due to reduction of hyaluronic acid production.¹¹ These changes result in reduced volume, decreased vocal fold flexibility, and hoarseness due to inadequate glottic closure, which greatly affects patients' quality of life. Vocal fold scarring can be caused by intubation, vocal

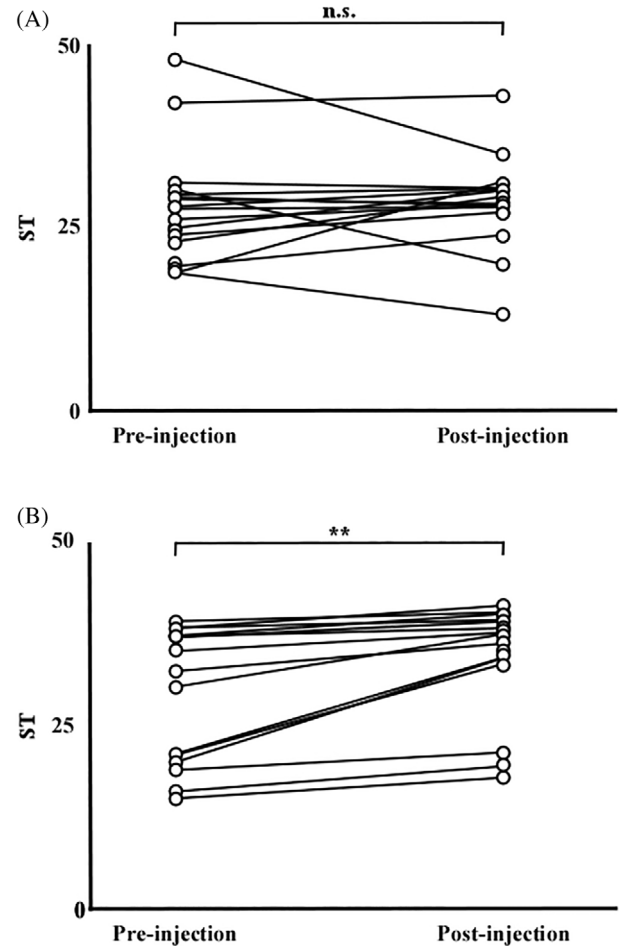


FIGURE 8 Changes in pitch range following steroid or basic fibroblast growth factor injection. (A) Steroid injection. (B) Basic fibroblast growth factor injection. ns, no significant difference. ** $p < .01$

fold surgery, phonotrauma, infection, and other congenital causes,³ with vocal fold surgery being the most common cause. To date, despite the great need for it, no appropriate treatment for vocal fold scarring has been established. Treatment of vocal fold scarring currently involves methods to improve glottic closure and/or rigidity by restoring the disrupted SLP. Conservative treatments such as voice hygiene and voice therapy are widely performed as the first-choice treatment,³ and surgical treatment includes medialization thyroplasty and injection augmentation.^{3,4} Epithelium-freeing techniques, mucosal grafting, fascia grafting and angiolytic laser are also used, but the most optimal among these therapies remains to be determined.³ Therefore, evidence must be accumulated to establish proper therapeutic strategies. While currently available therapies can improve glottic closure, improvement in rigidity through restoration of the disrupted SLP remains to be fully accomplished. When surgical treatment is considered, the least invasive strategy is selected because the results of surgery for vocal fold scarring are difficult to predict. Consequently, drug injection would be preferred over laryngeal framework surgery, which requires a skin incision, or laryngeal microsurgery, which requires general anesthesia.

At our department, intracordal steroid injection has been used for treating vocal fold scarring refractory to voice therapy.¹³ In recent times, the number of patients receiving bFGF injection have been increasing. Both injections have positive effects on vocal fold scarring, but the treatment administered was subjectively chosen according to the judgment of the treating physician and the wishes of the patient, and there were no precise indication criteria. Therefore, we used VHI as the primary outcome and used it to determine the therapeutic effect of these injections and used laboratory measurements of voice parameters as the secondary outcomes to elucidate indication criteria. The therapeutic effects of intracordal steroid injection for benign vocal fold lesions have been reported in many studies, including systematic reviews.^{13,28–30} However, most studies include patients with various lesions, and few focus only on vocal fold scarring. Vocal fold scarring is expected to be more refractory to this regimen than other benign vocal fold lesions.¹³

Young et al. demonstrated that intracordal steroid injection decreased VHI, Glottal Function Index, and GRBAS scores; reduced pronunciation threshold pressure¹⁰; and increased SFF range.¹⁰ The stroboscopic parameters of vocal fold edge, glottal closure, and right mucosal wave also improved after steroid injection.¹⁰ Here, the VHI and tGRBAS scores improved after steroid injection, but the MPT and MFR did not. Thus, steroid injection might result in improved vocal fold rigidity through histological changes in the SLP rather than through a reduction in the glottic gap. The significant increase in SFF further confirms that steroid injection can sufficiently treat vocal fold scarring.

In recent years, new treatments using tissue engineering techniques are gaining attention.³ In vitro and in vivo experiments showed a significant decrease in collagen deposition and increase in *hyaluronic acid production* in both the acute and chronic phases of vocal fold injury following administration of exogenous growth factors, namely, epidermal growth factor, bFGF, transforming growth factor beta 1, and hepatocyte growth factor.³ Furthermore, progress has been made in the therapeutic administration of platelet-rich plasma³¹ and bone marrow-derived autologous stem cells.³² bFGF injection has become a leading treatment for vocal fold atrophy and paralysis.^{18,19,21} The efficacy of bFGF in the treatment of vocal fold scarring and atrophy has been demonstrated in several animal and clinical studies.^{22,23,25,26} In another study, 41 patients with vocal fold scarring were treated with four injections of bFGF and showed improvement in MPT and GRBAS score.²³ Our previous studies have also demonstrated the potential of bFGF as a treatment for vocal fold scarring.¹⁸ These studies concluded that bFGF acts on vocal fold scarring by stimulating fibroblasts to produce HA, *thereby regenerating the SLP*. In this study, improved VHI scores, prolonged MPT, and shortened MFR were observed, but the tGRBAS score, an indicator of voice quality, did not improve. MPT and MFR indicate the glottic insufficiency status. bFGF has been found to improve MPT and MFR in patients with vocal fold paralysis and atrophy with a large insufficiency.^{18,21} Thus, bFGF might mediate a medialization effect related to MPT and MFR by stimulating the SLP and underlying muscle layer and simultaneously improve the vibratory properties of the vocal folds. This

hypothesis might be supported by our finding of a decrease in SFF following bFGF injection.

Although obvious differences in vocal fold vibration between the steroid and bFGF injection groups were not quantified, both steroid and bFGF injections were found to be effective for treating vocal fold scarring in terms of VHI score. Importantly, there were differences in laboratory measurements of voice parameters, which reflected the mechanism of action. Briefly, steroid injection should improve voice quality by thinning the vocal cords and increasing their vibratory properties, which may contribute to the improvement in VHI score. However, there is no prolongation of MPT or decrease in MFR due to the medialization effect of the increased vocal fold volume. In contrast, bFGF injections stimulate fibroblasts in the intrinsic SLP and muscle cells in the larynx, and they increase the vocal fold volume by stimulating cell proliferation and hyaluronic acid production, and inhibiting collagen fiber production, which may contribute to the improvement in VHI scores.

The main strengths of this study are its participants and the drugs used. Most studies on vocal fold scarring involve fewer participants than this study, and we used commercially available drugs. The impact of our findings on therapeutic strategies would therefore be significant.

4.1 | Limitations

This is a retrospective study, and inherent biases could not be eliminated. For example, the backgrounds and disease status of the two groups were not matched, and since the diagnosis of vocal cord scarring is more difficult than for other benign mucosal lesions of the vocal fold, a diagnostic bias is likely to have occurred. However, we demonstrated that bFGF injection is as effective as steroid injection, which is an established treatment for vocal fold scarring, and that the mechanisms underlying the therapeutic effect appear to differ, potentially increasing treatment options for patients. Furthermore, the results from this study can be used as pilot data for safety/efficacy in order to design a future study that includes a control group to evaluate the effect of a short-acting injectable drug. However, our results are supported by those of many previous studies and seem to have some validity. In the future, prospective studies should be conducted to determine the indication criteria and recurrence rate in the long term for steroid or bFGF injections.

5 | CONCLUSION

We investigated the therapeutic effects of steroid injection and bFGF injection in 16 patients each. Laboratory measurements of voice parameters were evaluated before and 3 months postinjection. We found that the VHI and tGRBAS scores significantly improved and SFF increased in the steroid injection group, but there was no improvement in aerodynamic parameters and SFF increased. In the bFGF injection group, the VHI score, MPT, and MFR significantly improved; however, the tGRBAS score did not, and SFF decreased. These results suggest that both steroid and bFGF injections are effective for treating vocal fold scarring, although they act through different mechanisms.

ACKNOWLEDGMENTS

The authors thank the speech-language-hearing therapists from our department—Taisuke Sotome, Nahoko Tashiro, Miyuki Kurihara, Takumi Omae, Yosuke Nakayama, Ayumi Yamamoto, and Ayane Sato—for their support in the data collection and clinical assessments. The authors also thank Editage (www.editage.com) for English language editing. This work was performed at and funded internally by the Division of Laryngeal Surgery, Department of Otolaryngology, at the Jichi Medical University and the Tokyo Voice Center at the International University of Health and Welfare, Tokyo, Japan.

CONFLICT OF INTEREST

The authors declare no conflict of interest.

ORCID

Takeharu Kanazawa  <https://orcid.org/0000-0002-3735-684X>

REFERENCES

- Hantzakos A, Dikkers FG, Giovanni A, et al. Vocal fold scars: a common classification proposal by the American Laryngological Association and European Laryngological Society. *Eur Arch Otorhinolaryngol*. 2019;276(8):2289-2292.
- Allen J. Cause of vocal fold scar. *Curr Opin Otolaryngol Head Neck Surg*. 2010;18(6):475-480.
- Friedrich G, Dikkers FG, Arens C, et al. Vocal fold scars: current concepts and future directions. Consensus report of the Phonosurgery Committee of the European Laryngological Society. *Eur Arch Otorhinolaryngol*. 2013;270(9):2491-2507.
- Medeiros N, Castro MEM, van Lith-Bijl JT, Desuter GRR. A systematic review on surgical treatments for sulcus vocalis and vocal fold scar. *Laryngoscope*. 2022;132(4):822-830.
- Desjardins M, Halstead L, Cooke M, Bonilha HS. A systematic review of voice therapy: what "effectiveness" really implies. *J Voice*. 2017;31(3):392.e13-392.e32.
- Karle WE, Helman SN, Cooper A, Zhang Y, Pitman MJ. Temporalis fascia transplantation for sulcus vocalis and vocal fold scar: long-term outcomes. *Ann Otol Rhinol Laryngol*. 2018;127(4):223-228.
- Kimura M, Nito T, Sakakibara K, Tayama N, Niimi S. Clinical experience with collagen injection of the vocal fold: a study of 155 patients. *Auris Nasus Larynx*. 2008;35(1):67-75.
- van den Broek E, Heijnen BJ, Hendriksma M, et al. Bilateral vocal fold injection with autologous fat in patients with vocal fold atrophy with or without sulcus. *Eur Arch Otorhinolaryngol*. 2019;276(7):2007-2013.
- Zelenik K, Formanek M, Walderova R, Formankova D, Kominek P. Five-year results of vocal fold augmentation using autologous fat or calcium hydroxylapatite. *Eur Arch Otorhinolaryngol*. 2021;278(4):1139-1144.
- Young WG, Hoffman MR, Koszewski IJ, Whited CW, Ruel BN, Dailey SH. Voice outcomes following a single office-based steroid injection for vocal fold scar. *Otolaryngol Head Neck Surg*. 2016;155(5):820-828.
- Mortensen M. Laryngeal steroid injection for vocal fold scar. *Curr Opin Otolaryngol Head Neck Surg*. 2010;18(6):487-491.
- Tateya I. Laryngeal steroid injection. *Curr Opin Otolaryngol Head Neck Surg*. 2009;17(6):424-426.
- Takahashi S, Kanazawa T, Hasegawa T, et al. Comparison of therapeutic effects of steroid injection by benign vocal fold lesion type. *Acta Otolaryngol*. 2021;141(11):1005-1013.
- Carroll LA, Hanasono MM, Mikulec AA, Kita M, Koch RJ. Triamcinolone stimulates bFGF production and inhibits TGF- β 1 production by human dermal fibroblasts. *Dermatol Sur*. 2002;28(8):704-709.
- Campagnolo AM, Tsuji DH, Sennes LU, Imamura R, Saldiva PH. Histologic study of acute vocal fold wound healing after corticosteroid injection in a rabbit model. *Ann Otol Rhinol Laryngol*. 2010;119(2):133-139.
- Bouchayer M, Cornut G. Microsurgery for benign lesions of the vocal folds. *Ear Nose Throat J*. 1988;67(6):446-449.
- Mortensen M, Woo P. Office steroid injections of the larynx. *Laryngoscope*. 2006;116(10):1735-1739.
- Kanazawa T, Komazawa D, Indo K, et al. Single injection of basic fibroblast growth factor to treat severe vocal fold lesions and vocal fold paralysis. *Laryngoscope*. 2015;125(10):E338-E344.
- Kanazawa T, Kurakami K, Kashima K, et al. Injection of basic fibroblast growth factor for unilateral vocal cord paralysis. *Acta Otolaryngol*. 2017;137(9):962-967.
- Takeharu K, Kurakami K, Konomi U, et al. Safety and short-term outcomes of basic fibroblast growth factor injection for sulcus vocalis. *Acta Otolaryngol*. 2018;138(11):1014-1019.
- Okui A, Konomi U, Kanazawa T, et al. Therapeutic efficacy of basic fibroblast growth factor in patients with vocal fold atrophy. *Laryngoscope*. 2020;130(12):2847-2852.
- Ohno T, Hirano S, Rousseau B. Age-associated changes in the expression and deposition of vocal fold collagen and hyaluronan. *Ann Otol Rhinol Laryngol*. 2009;118(10):735-741.
- Hirano S, Sugiyama Y, Kaneko M, Mukudai S, Fuse S, Hashimoto K. Intracordal injection of basic fibroblast growth factor in 100 cases of vocal fold atrophy and scar. *Laryngoscope*. 2021;131(9):2059-2064.
- Yildiz M, Yigit O, Sunter AV, Edizer DT, Dursun N, Okcu O. Effects of intracordal estradiol and dexamethasone injection on wound healing in vocal fold injuries. *J Voice*. 2019;33(5):759-766.
- Suzuki R, Kawai Y, Tsuji T, et al. Prevention of vocal fold scarring by local application of basic fibroblast growth factor in a rat vocal fold injury model. *Laryngoscope*. 2017;127(2):E67-E74.
- Suehiro A, Hirano S, Kishimoto Y, Rousseau B, Nakamura T, Ito J. Treatment of acute vocal fold scar with local injection of basic fibroblast growth factor: a canine study. *Acta Otolaryngol*. 2010;130(7):844-850.
- Sakaguchi Y, Kanazawa T, Okui A, et al. Assessment of dysphonia using the Japanese version of the Voice Handicap Index and determination of cutoff points for screening. *J Voice*. 2020;36(1):144.e1-144.e9.
- Wang CT, Liao LJ, Cheng PW, Lo WC, Lai MS. Intralesional steroid injection for benign vocal fold disorders: a systematic review and meta-analysis. *Laryngoscope*. 2013;123(1):197-203.
- Wu CH, Lo WC, Liao LJ, Kao YC, Wang CT. Vocal fold steroid injection for benign vocal lesions in professional voice users. *J Voice*. 2021;S0892-1997(21)00057-6. doi:10.1016/j.jvoice.2021.02.002
- Wang CT, Lai MS, Cheng PW. Long-term surveillance following intralesional steroid injection for benign vocal fold lesions. *JAMA Otolaryngol Head Neck Surg*. 2017;143(6):589-594.
- Bhatt NK, Gao WZ, Sund LT, Castro ME, O'Dell K, Johns MM 3rd. Platelet-rich plasma for vocal fold scar: a preliminary report of concept. *J Voice*. 2021;S0892-1997(21)00012-6. doi:10.1016/j.jvoice.2020.12.040
- Hertegard S, Nagubothu SR, Malmstrom E, LeBlanc K. Treatment of vocal fold scarring with autologous bone marrow-derived human mesenchymal stromal cells—first phase I/II human clinical study. *Stem Cell Res Ther*. 2020;11(1):128.

How to cite this article: Nozawa M, Takahashi S, Kanazawa T, et al. Intracordal injection therapy for vocal fold scarring: Steroid versus basic fibroblast growth factor. *Laryngoscope Investigative Otolaryngology*. 2022;7(5):1465-1473. doi:10.1002/liv.2.881