

Endoscopic closure of an anastomo-cutaneous fistula: Filling and shielding using polyglycolic acid sheets and fibrin glue with easily deliverable technique



Authors

Hideaki Kawabata, Yuji Okazaki, Naonori Inoue, Yukino Kawakatsu, Misuzu Hitomi, Masatoshi Miyata, Shigehiro Motoi

Institution

Department of Gastroenterology, Kyoto Okamoto Memorial Hospital, Kyoto, Japan

submitted 24.11.2017

accepted after revision 12.2.2018

Bibliography

DOI <https://doi.org/10.1055/a-0584-6669> |
Endoscopy International Open 2018; 06: E994–E997
© Georg Thieme Verlag KG Stuttgart · New York
ISSN 2364-3722

Corresponding author

Hideaki Kawabata, MD, 58 Nishinokuchi, Sayama, Kumiyama-cho, Kuze-gun, Kyoto 613-0034, Japan
Fax: +81774 44 7159
hkawabata@okamoto-hp.or.jp

ABSTRACT

Background and study aims Recently, endoscopic closure of gastrointestinal fistulas using polyglycolic acid (PGA) sheets with fibrin glue (FG) has been attempted. A 70-year-old woman who had undergone pancreaticoduodenectomy for pancreatic cancer suffered from a refractory anastomo-cutaneous fistula at the site of gastro-jejunos-tomy. We attempted endoscopic closure with filling and shielding using PGA sheets and FG. After introducing a guidewire into the fistula, a small piece of PGA sheet was skewered onto the guidewire and then pushed using a tapered catheter over the guidewire and delivered into the fistula. A total of 10 sheets were delivered via the same procedure. Next, the mucosa around the fistula was ablated, and the orifice of the fistula along with the surrounding mu-cosa was shielded with a piece of PGA sheet fixed with he-moclips and FG. After this procedure, the leakage disap-peared and the fistula was undetectable on contrast radio-grams. Endoscopic closure of anastomo-cutaneous fistula with filling and shielding using PGA sheets and FG is an ef-fective, safe, low-invasive treatment, and the filling tech-nique using a guidewire ensures a safe, smooth procedure.

Introduction

Recently, endoscopic treatments of gastrointestinal leaks and fistulas, including endoclippping, stent placement, application of tissue sealants and suturing devices, have been developed, and the effectiveness of such procedures has been reported [1]. Although the most common tissue sealants in clinical use are fibrin glue (FG) and cyanoacrylate [1, 2], endoscopic closure using polyglycolic acid (PGA) sheets with FG have been attempted because of the harmless nature of these sheets and the satisfactory results achieved in various surgical fields [3–9].

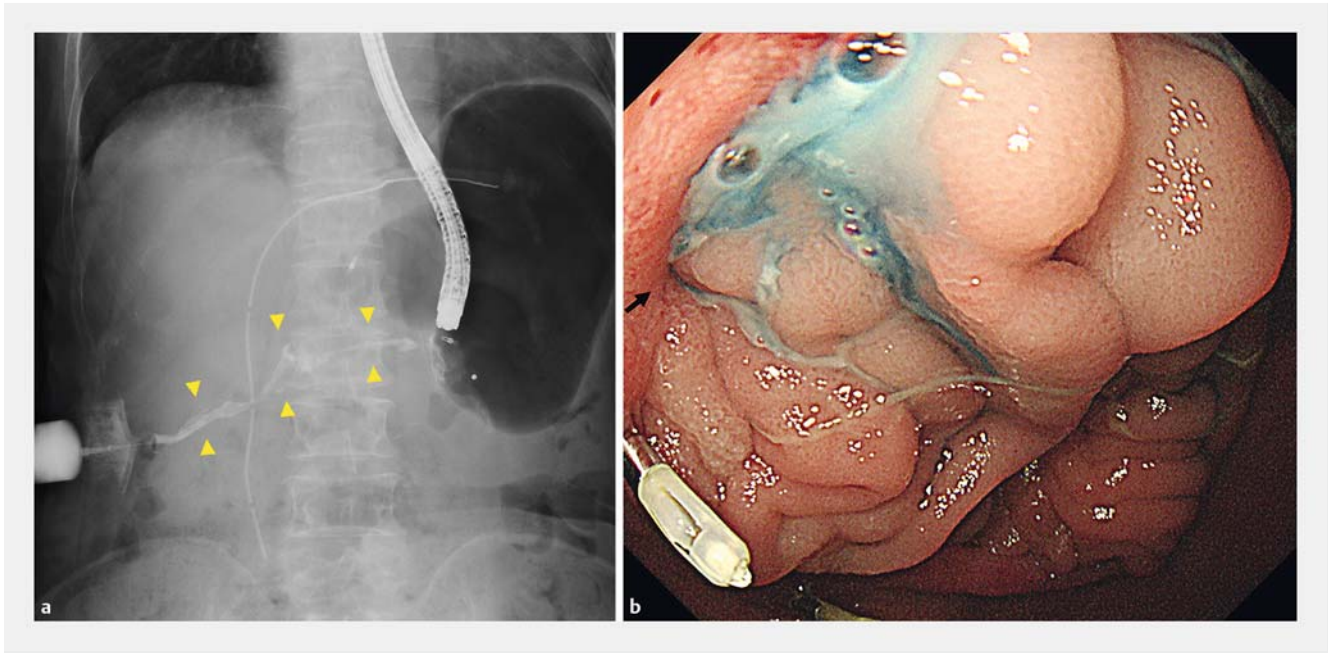
PGA sheets are delivered with biopsy forceps and stuffed into the fistula using a tapered catheter or closed biopsy forceps [4–7]. This procedure should be repeated several times to prevent mesh dislocation, but it can be technically difficult to apply the sheets, and blindly inserting such pushing devices can injure the fistula. Furthermore, only filling the PGA sheets

or additional endoplication with hemoclips after the filling procedure described in previous reports [4–7] may lead to unsuccessful results due to either incomplete closure or position displacement of the filled sheets.

We herein report a case of endoscopic closure of an anasto-mo-cutaneous fistula after gastrojejunos-tomy using polyglyco-lic acid sheets with an easily deliverable technique.

Case report

A 70-year-old woman underwent pancreaticoduodenectomy with modified Child reconstruction for pancreatic head cancer in March 2016. After the operation, the patient suffered ana-stomotic leakage at the site of gastro-jejunos-tomy, and percu-taneous intraperitoneal drainage (PID) was performed. In addition, percutaneous transhepatic cholangiographic drainage (PTCD) was performed for an inflammatory obstructed chole-



► **Fig. 1 a** Contrast imaging performed by introducing a contrast medium through the cutaneous fistula revealed an anastomo-cutaneous fistula (arrowheads). **b** The site of anastomotic leakage was endoscopically confirmed by introducing indigo carmine through the cutaneous fistula (arrow).

dochojejunostomy 4 months after the operation. Computed tomography revealed no recurrent findings, and cytology of drainage from both PID and PTCd was negative for cancer. Contrast imaging performed by introducing a contrast medium through the cutaneous fistula revealed an anastomo-cutaneous fistula (► **Fig. 1a**). The site of anastomotic leakage was endoscopically confirmed by introducing indigo carmine through the cutaneous fistula (► **Fig. 1b**). Because the anastomo-cutaneous fistula was not closed despite conservative management 14 months after operation, we tried endoscopic clip closure and shielding with a PGA sheet (Neoveil; Gunze Medical Division, Kyoto, Japan). However, the fistula was still not completely closed 3 months after starting these endoscopic approaches.

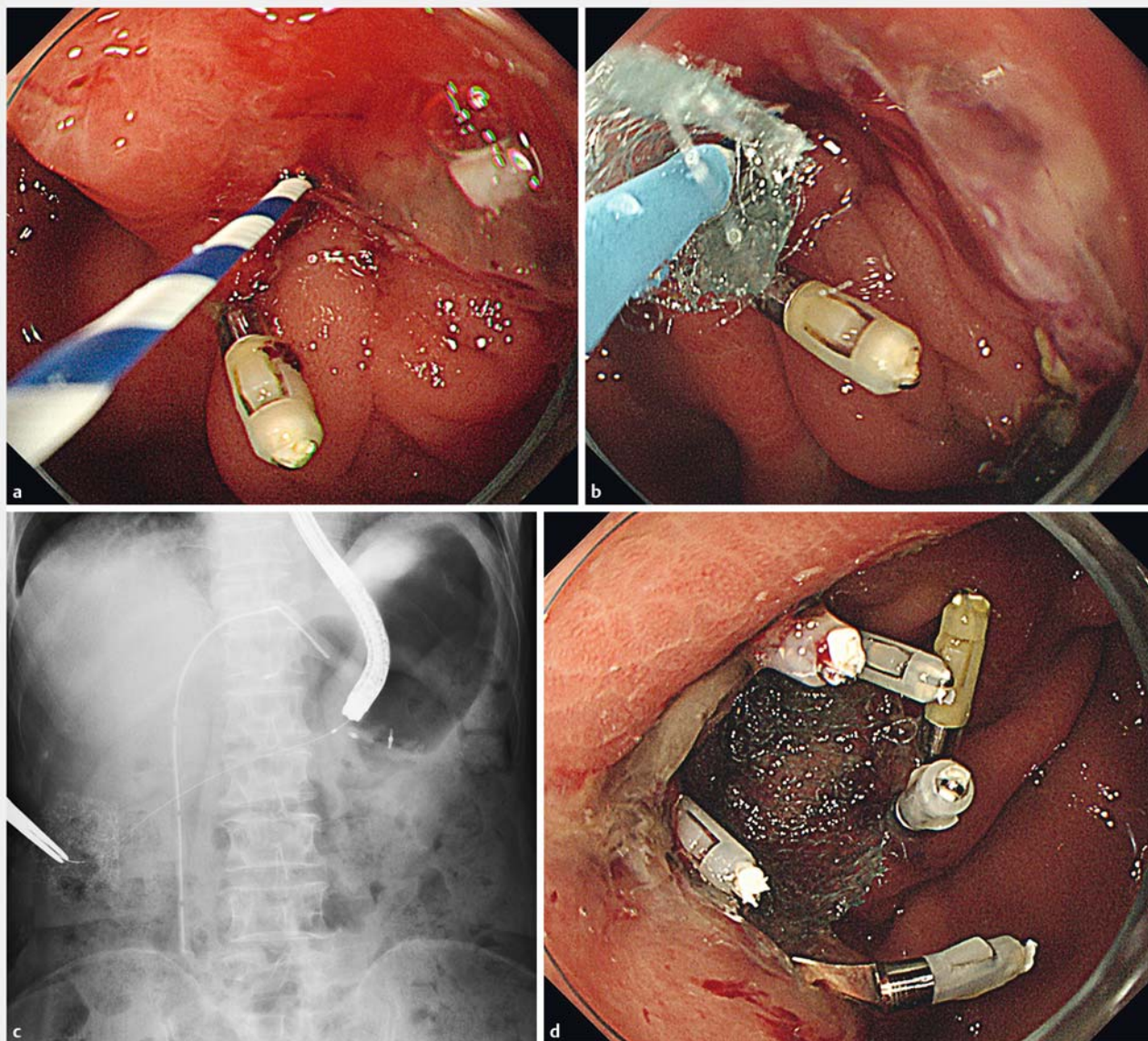
Therefore, we attempted endoscopic closure with filling and shielding using PGA sheets and FG (Beriplast P Combi-Set; CSL Behring Pharma, Tokyo, Japan). After confirming the anastomotic fistula using an endoscope (3.2 mm-wide working channel, GIF-Q260J; Olympus Medical Systems, Tokyo, Japan), a guidewire (0.64 mm in diameter, RAYELISSE; CREATE MEDIC, Kanagawa, Japan) was introduced into the anastomotic fistula at the orifice of the cutaneous fistula with radiologic control (► **Fig. 2a**). A tapered catheter was inserted over the guidewire and the fistula was cleaned with an adequate quantity of saline. Subsequently, a small piece of PGA sheet (10×5 mm) folded in half was skewered onto the guidewire at the center and then pushed using the tapered catheter (MTW; MTW Endoskopie, Wesel, Germany) over the guidewire through the scope channel and delivered into the fistula (► **Fig. 2b**, ► **Fig. 2c**). A total of 10 PGA sheets were delivered via the same procedure and complete closure of the fistula was confirmed by contrast imaging. Next, the mucosa around the fistula was ablated with ar-

gon plasma coagulation. A piece of PGA sheet (20×20 mm) was then applied to the orifice of the fistula along with the surrounding mucosa and delivered with biopsy forceps through the scope channel to shield the fistula; it was fixed with five hemoclips at the edge of the sheet. Finally, FG was sprayed over the entire sheet with an injection needle (► **Fig. 2d**). After this procedure, no complications were observed, and leakage from the cutaneous fistula disappeared. The fistula was undetectable on contrast radiograms, even after pressure injection of contrast medium, at 1 month after the procedure (► **Fig. 3**).

Discussion

We were able to close a refractory anastomo-cutaneous fistula after gastrojejunostomy using PGA sheets and FG. In the current case, shielding using a PGA sheet was accompanied with a filling procedure to prevent deviation of the filled PGA sheets due to peristaltic pressure. Takimoto et al. [8] also reported filling and shielding using PGA sheets and FG to treat postoperative gastric perforation of endoscopic submucosal dissection; however, we found no reports describing the same procedure for treatment of gastrointestinal fistulas. While Nagami et al. [4] successfully used endoclips to gather the mucosa around the fistula after filling the fistula with PGA sheets, such a procedure carries a risk of inducing incomplete closure or position displacement of the filled sheets.

Delivering PGA sheets over the guidewire with the tapered catheter is not only safe but also an easy procedure to repeat. Furthermore, we were able to adjust the filling position based on radiograms and fill the deep site of the fistula with the sheets. We were able to deliver several sheets simultaneously



► **Fig. 2** **a** A guidewire (RAYELISSE; CREATE MEDIC, Kanagawa, Japan) was introduced into the anastomotic fistula. **b, c** A small piece of PGA sheet was skewered onto the guidewire at the center, and then pushed using the tapered catheter (MTW, MTW Endoskopie, Wesel, Germany) over the guidewire and delivered into the fistula. **d** The orifice of the fistula along with the surrounding mucosa was shielded by a piece of PGA sheet fixed with five hemoclips and FG.

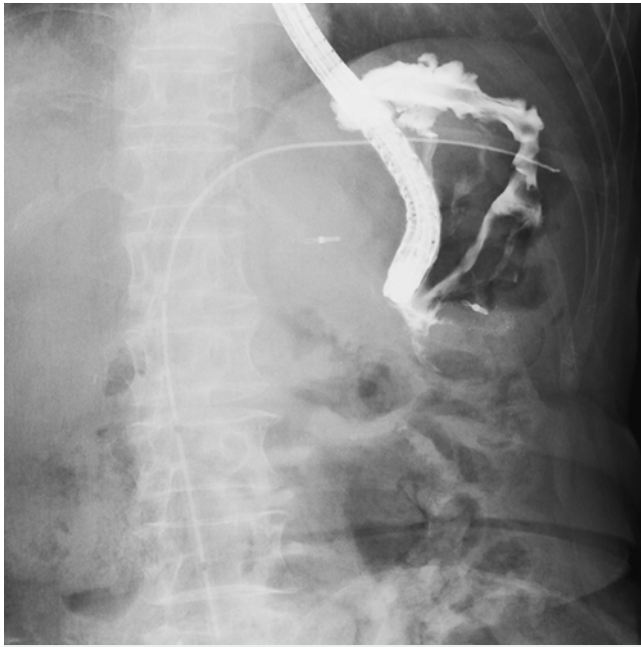
and adjust the size of the sheets depending on the size of the fistula. In case of difficulty of an antegrade approach, the sheets can be delivered retrograde from the downstream side of the fistula. Although careful guidance using a soft guidewire should be performed to avoid fistula injury, moderate mechanical stimulation to the fistula due to guidewire movement might promote formation of granulation tissue after filling the PGA sheets. To our knowledge, this is the first report showing the utility of a guidewire for a filling procedure with PGA sheets.

Although our shielding procedure using a PGA sheet is able to prevent such problems, this procedure is complicated especially when using larger sheets, and can be technically difficult.

An easier shielding method should be developed, such as adoption of a double-operating channel scope.

Conclusion

In conclusion, endoscopic closure of anastomo-cutaneous fistula after gastro-jejunostomy with filling and shielding using PGA sheets and FG is an effective, safe, low-invasive treatment, and the filling technique using a guidewire ensures a safe, smooth procedure.



► **Fig. 3** The fistula was not detectable on contrast radiograms at 1 month after the procedure.

Competing interests

None

References

- [1] Rogalski P, Daniluk J, Baniukiewicz A et al. Endoscopic management of gastrointestinal perforations, leaks and fistulas. *World J Gastroenterol* 2015; 21: 10542–10552
- [2] Han S, Chung H, Park JC et al. Endoscopic Management of Gastrointestinal Leaks and Perforation with PGA Sheets. *Clin Endosc* 2017; 50: 293–296
- [3] Willingham FF, Buscaglia JM. Endoscopic management of gastrointestinal leaks and fistulae. *Clin Gastroenterol and Hepatol* 2015; 13: 1714–1721
- [4] Nagami Y, Shiba M, Tominaga K et al. Endoscopic closure of gastrocutaneous leakage with PGA sheets. *Endoscopy* 2015; 47: (Suppl. 01): UCTN: E455–456
- [5] Takano Y, Yamamura E, Kuroki Y et al. Novel endoscopic treatment for colocutaneous fistula after severe acute pancreatitis: filling with a PGA sheet. *Endoscopy* 2015; 47: (Suppl. 01): E424–E425
- [6] Tsujii Y, Kato M, Shinzaki S et al. PGA sheets for repair of refractory esophageal fistula. *Endoscopy* 2015; 47: (Suppl. 01): E39–E40
- [7] Yamamoto S, Endo S, Minegishi K et al. PGA mesh occlusion for postoperative bronchopleural fistula. *Asian Cardiovasc Thorac Ann* 2015; 23: 931–936
- [8] Takimoto K, Hagiwara A. Filling and shielding for postoperative gastric perforations of endoscopic submucosal dissection using PGA sheets and FG. *Endosc Int Open* 2016; 04: E661–E664
- [9] Shinozaki T, Hayashi R, Ebihara M et al. Mucosal defect repair with a PGA sheet. *Jpn J Clin Oncol* 2013; 43: 33–36