

A case report of immune checkpoint inhibitor nivolumab combined with anti-angiogenesis agent anlotinib for advanced esophageal squamous cell carcinoma

Yong Tang, MD, PhD^a, Zhu'an Ou, MD^a, Zhifang Yao, MD^b, Guibin Qiao, MD, PhD^{c,*}

Abstract

Introduction: The PD-1 inhibitors have shown good response in the treatment for many types of malignant tumors, but as monotherapy for advanced esophageal squamous carcinoma, the objective response rate is low. Here we report a case of the patient with advanced esophageal squamous cell carcinoma (ESCC) showing a completely response to nivolumab combined with a small molecule multi-target tyrosine kinase inhibitor (TKI) anlotinib.

Patient concerns: A 61-year-old male was put under a surgery as the response to the diagnosis of ESCC in March 2014. The post-operative follow-up in March 2018 suggested a recurrence based on imagological findings, and symptoms such as shortness of breath and cough were also observed in October 2018.

Diagnosis: The patient was diagnosed as advanced metastatic ESCC in October 2018.

Interventions: Radical resection and esophagogastrectomy under aortic arch with left thoracotomy was performed in March 2014. As a treatment against the post-surgical recurrence, 4 courses of paclitaxel combined with nedaplatin was administered in April 2018 with an outcome of PR, followed by a combined administration of Nivolumab and anlotinib in November 2018.

Outcomes: Chest CT during a 3-month follow-up revealed the disappearance of all the metastases, and no adverse effect was observed during the treatment.

Conclusion: The combined treatment of nivolumab and anlotinib is likely to be considered as an optional management of advanced ESCC.

Abbreviations: CR = complete response, CT = computed tomography, DFS = disease-free survival, ECOG PS = Eastern Cooperative Oncology Group Performance Status, ESCC = esophageal squamous cell carcinoma, IHC = immunohistochemical, NGS = next-generation sequencing, ORR = objective response rate, OS = overall survival, PD = progressive disease, PFS = progress free survival, PR = partial response, TKI = tyrosine kinase inhibitor, TMB = tumor mutation burden, WES = whole-exome sequencing.

Keywords: advanced esophageal squamous cell carcinoma, anlotinib, nivolumab

Editor: N/A.

Written informed consent for publication of their clinical details and clinical images was obtained from the patients.

The authors have no conflicts of interests to disclose.

^aDepartment of Thoracic Surgery, General Hospital of Southern Theatre Command of PLA, Guangzhou., ^bThe Medical Department, 3D Medicines Inc., Shanghai., ^cDepartment of Thoracic Surgery, Guangdong General Hospital, Guangdong Academy of Medical Sciences, Guangzhou, China.

* Correspondence: Guibin Qiao, Department of Thoracic Surgery, Guangdong General Hospital, Guangdong Academy of Medical Sciences, No. 106 Zhongshan Er Road, Guangzhou 510080, China (e-mail: guibinqiao@126.com).

Copyright © 2019 the Author(s). Published by Wolters Kluwer Health, Inc. This is an open access article distributed under the terms of the Creative Commons Attribution-Non Commercial License 4.0 (CCBY-NC), where it is permissible to download, share, remix, transform, and buildup the work provided it is properly cited. The work cannot be used commercially without permission from the journal.

How to cite this article: Tang Y, Ou Z, Yao Z, Qiao G. A case report of immune checkpoint inhibitor nivolumab combined with anti-angiogenesis agent anlotinib for advanced esophageal squamous cell carcinoma. *Medicine* 2019;98:40 (e17164).

Received: 21 March 2019 / Received in final form: 21 July 2019 / Accepted: 20 August 2019

<http://dx.doi.org/10.1097/MD.00000000000017164>

1. Introduction

According to GLOBOCAN 2018 study just published lately,^[1] there were 572,000 new diagnoses of esophageal cancer in 2018, and another 590,000 people died of esophageal cancer, ranking seventh and sixth, respectively, in all tumors. Both of the prevalence and mortality of esophageal cancer in China rank fifth in the world, accounting for about 55% of the cases worldwide. Based on the newly published 2014 China Cancer Report,^[2] the number of new cases of esophageal cancer is 258,000, including 185,000 males and 72,000 females, with an incidence ranking sixth in China. A total of 193,000 deaths were recorded from esophageal cancer, ranking fourth among all the cases with malignancies. Squamous carcinoma, more commonly seen in Asian and African countries,^[3] accounts for about 90% of esophageal cancer in China.^[4] The 5-year survival rate of esophageal cancer in China is only about 30%,^[5] and even lower in the population in advanced phases, despite of a variety of available management, such as surgery, chemotherapy, and radiotherapy.

Immune checkpoint inhibitors have shown good response in the treatment for a variety of malignant tumors, and even for advanced esophageal carcinoma as part of multi-line treatment, with an objective response rate (ORR) of 10% to 33.3%.^[6-9] As

a small molecule multi-target tyrosine kinase inhibitor (TKI), anlotinib has presented the inhibitory effect against tumor growth and angiogenesis by strongly inhibiting multiple targets such as VEGFR, PDGFR, FGFR, and c-Kit.^[10] Clinically, anlotinib has been proved as an effective posterior line treatment in advanced non-small cell lung cancer (NSCLC) and soft tissue sarcoma.^[11–12] Considering the absence of report on the combined use of the 2 agencies in advanced esophageal, here we report a case who was with advanced esophageal squamous cell carcinoma (ESCC) and showed a complete response (CR) to nivolumab combined with anlotinib.

2. Case description

A 61-year-old male diagnosed as esophageal cancer received radical resection and esophagogastric anastomosis under aortic arch with left thoracotomy in March 2014. The pathology revealed highly to moderately differentiated squamous carcinoma with a pathological staging of IIB (pT3N0M0) and R0 resection. Regular follow-ups were performed to monitor the progress of the disease. Chest computed tomography (CT) scanning on March 20, 2018 showed multiple nodules in lingular segment of the left upper lobe as well as multiple enlarged lymph nodes in the mediastinum, both indicating new metastasis (Fig. 1A). The disease-free survival (DFS) was recorded as 4 years. Paclitaxel combined with nedaplatin was administered for 4 courses starting from April 2018, and the 5 months of follow-up after the chemotherapy revealed an outcome of partial response (PR) (Fig. 1B) as well as a progress free survival (PFS) of 7 months. Another CT examination on October 30, 2018 revealed metastasis as demonstrated by even larger nodules as compared with the previous CT findings in the inferior lingular segment of the left upper lobe, and multiple enlarged lymph nodes in the mediastinum and bilateral hilum. At the same time, patient was with the symptoms, such as shortness of breath and cough. Evaluation was made identifying the treatment outcome as progressive disease (PD) (Fig. 1C) with an Eastern Cooperative Oncology Group performance status (ECOG PS) score of 3. Meanwhile, Biopsy specimens were sent to 3D Medicines for next-generation sequencing (NGS) cancer gene panel (381 genes) test, with the results showing clinically significant mutations in NOTCH1 and TP53. The patient was identified as a case with low tumor mutation burden (TMB) since the TMB was 5.65, lower than that of 81% of the patients with esophageal cancer. Immunohistochemical (IHC) assay using SP263 antibody revealed positive PD-L1 expression in more than 5% of the tumor cells.

With a full informed consent, the patient was administered with nivolumab (3 mg/kg, Q2W) in combination with anlotinib (12 mg, D1–D14, Q3W) starting from November 2018. Chest CT after 1 month of treatment revealed an outcome of PR (Fig. 1D), and ECOG PS score was measured as 1. Three months later the chest CT revealed all the metastases disappeared (Fig. 1E). The patient showed good tolerance, with no adverse effect observed during the treatment. Up to the time of publication, the patient was still in CR and the median PFS had not been reached yet.

3. Discussion and conclusion

So far, there has been an absence of research regarding the clinical use of checkpoint inhibitors combined with anti-angiogenesis agents in the treatment of advanced ESCC. Here we reported for the first time a patient with advanced ESCC and poor physical

status who showed a good response to the combined treatment with nivolumab and anlotinib.

As a multicenter, open-label, single arm phase II study, ATTRACTION-01 explored the effects of nivolumab as a monotherapy for patients with advanced ESCC who failed standard chemotherapy, with a result showing an ORR of 17%, a complete response (CR) of 2%, and an acceptable tolerability.^[6] The 64 evaluable patients had a median overall survival (OS) of 10.8 months, and those with CR or PR showed a good response during a rather long period. Keynote-180 was a phase II study evaluating pembrolizumab for previously treated advanced esophageal or esophagogastric junction carcinoma, particularly squamous carcinoma, which was identified in 52.1% of the patients.^[8] The results revealed an ORR of 9.9%, median OS of 5.8 months, and a 12-month OS of 28%. These studies have demonstrated a rather low effective rate of checkpoint inhibitors as a monotherapy for advanced esophageal cancer despite of a certain level of response.

Assays that measure PD-L1 protein expression by IHC were approved as complementary or companion diagnostics for immune checkpoint inhibitors in some solid tumors.^[13] Recent studies had also confirmed that TMB measured by whole-exome sequencing (WES) or a NGS cancer gene panel was associated with immunotherapy responses.^[14] It is hypothesized that highly mutated tumors are more likely to harbor neoantigens which make them targets of activated immune cells.^[15] The patient was identified as a case with low TMB and PD-L1 expression only in more than 5% of the tumor cells, which might explain the low response to the immunotherapy.

According to IMpower150,^[16] atezolizumab combined with bevacizumab, paclitaxel and carboplatin showed a significant PFS benefit in non-squamous NSCLC patients when compared with the combination of bevacizumab, paclitaxel, and carboplatin. However, there was no difference in the response rate between atezolizumab + paclitaxel + carboplatin group and bevacizumab + paclitaxel + carboplatin group. These findings suggest that the anti-angiogenic drug (bevacizumab) has an immunomodulatory effect and can enhance the immune efficacy of atezolizumab. Studies with regard to advanced liver cancer have also shown that immuncheckpoint inhibitors combined with anti-angiogenesis agents are more effective than monotherapy. According to a previous study, SHR-1210, a PD-1 inhibitor, when combined with the small molecule anti-angiogenesis inhibitor apatinib, can achieve an ORR of 50% in patients with advanced hepatocellular carcinoma.^[17] Combined use of atezolizumab and bevacizumab for advanced hepatocellular carcinoma also contributed to an ORR of 32% and a median PFS of 14.9 months.^[18]

Anlotinib can inhibit substrate phosphorylation and signal transduction by competing with ATP for the binding sites on VEGFR/PDGFR/FGFR/c-kit, therefore exhibits an effect of inhibiting tumor angiogenesis and tumor growth.^[10] In the case, immune-checkpoint inhibitor nivolumab in combination with anti-angiogenesis agent anlotinib was employed for the first time as a second-line treatment for advanced ESCC. Improvement on physical condition of the patient was observed even after 1 course of combined treatment, in contrast to the ECOG PS score of 3 before the treatment. The study revealed an outcome of CR by imaging examinations after 3 months of treatment, as well as a good tolerance without significant adverse reactions, suggesting that the combined treatment of nivolumab and anlotinib is likely to be an option for advanced ESCC.

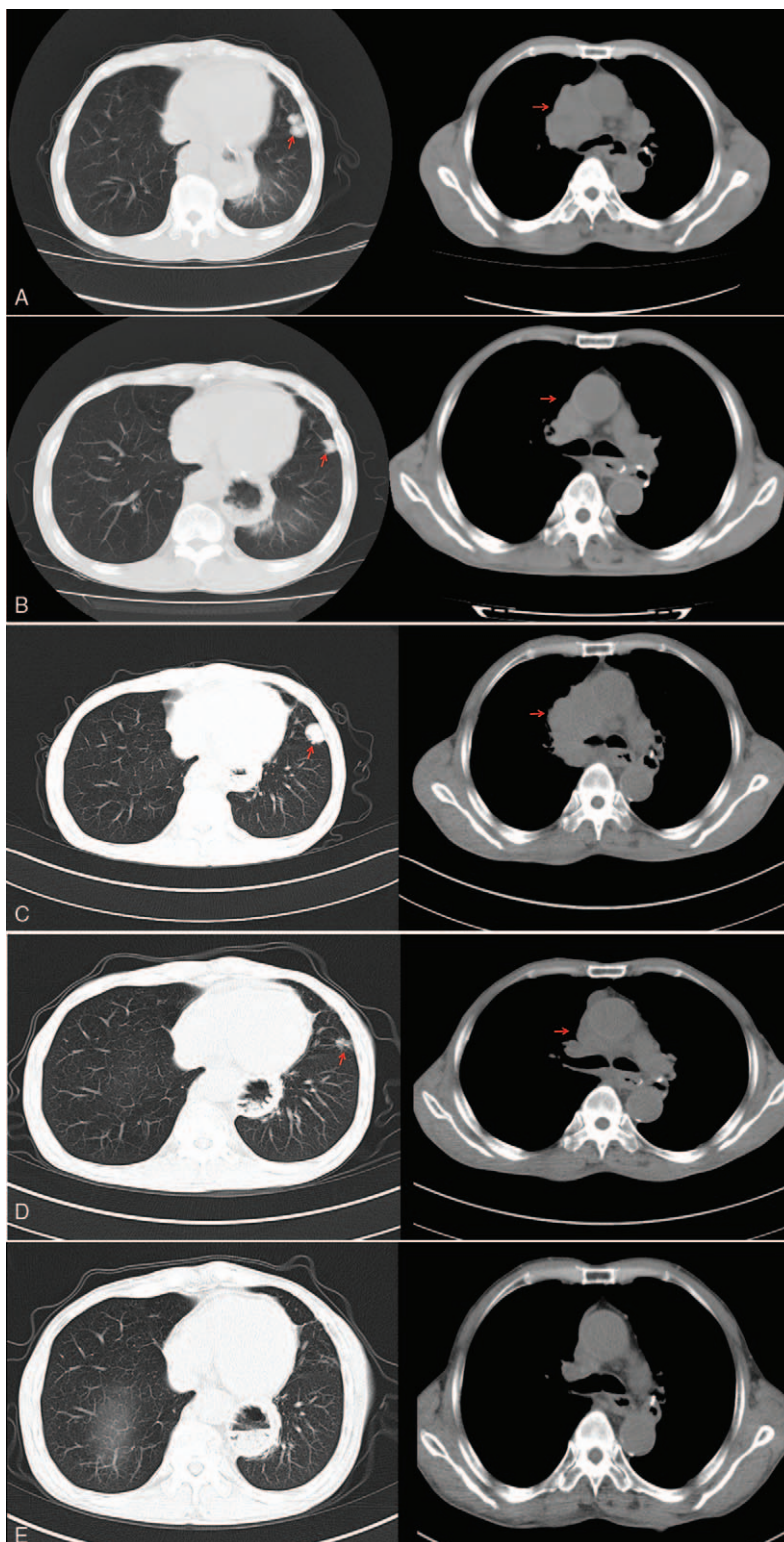


Figure 1. A. Chest CT scanning on March 20, 2018 revealed metastasis in left upper lung and mediastinal lymph nodes. B. Patient was followed by 4 courses of chemotherapy with paclitaxel and nedaplatin starting from April 2018. CT examination on June 5, 2018 indicating shrink of the nodules in the left upper lung, supported an outcome evaluation of PR on the chemotherapy. C. Chest CT on October 30, 2018 indicated metastasis as demonstrated by enlarged nodules in the inferior lingual segment of the left upper lobe compared with the previous CT findings, multiple enlarged lymph nodes in mediastinum and bilateral hilum suggested metastasis. D. Chest CT on December 11, 2018 indicated a significant shrink in pulmonary metastasis and mediastinal lymph nodes after 1 month of treatment with nivolumab and anlotinib. E. Chest CT on March 5, 2019 indicated the pulmonary metastasis and mediastinal lymph nodes disappeared completely. CT = Computed tomography.

Author contributions

Conceptualization: Yong Tang.

Data curation: Yong Tang, Zhu'an Ou.

Writing – original draft: Zhifang Yao.

Writing – review & editing: Zhifang Yao, Guibin Qiao.

Guibin Qiao orcid: 0000-0001-9200-9317.

References

- [1] Bray F, Ferlay J, Soerjomataram I, et al. Global cancer statistics 2018: GLOBOCAN estimates of incidence and mortality worldwide for 36 cancers in 185 countries. *CA Cancer J Clin* 2018;68:394–424.
- [2] Chen W, Sun K, Zheng R, et al. Cancer incidence and mortality in China, 2014. *Chin J Cancer Res* 2018;30:1–2.
- [3] Arnold M, Soerjomataram I, Ferlay J, et al. Global incidence of oesophageal cancer by histological subtype in 2012. *Gut* 2015;64:381–7.
- [4] Yang Z, Zeng H, Xia R, et al. Annual cost of illness of stomach and esophageal cancer patients in urban and rural areas in China: a multi-center study. *Chin J Cancer Res* 2018;30:439–48.
- [5] Zeng H, Chen W, Zheng R, et al. Changing cancer survival in China during 2003–15: a pooled analysis of 17 population-based cancer registries. *Lancet Global Health* 2018;6:e555.
- [6] Kudo T, Hamamoto Y, Kato K, et al. Nivolumab treatment for oesophageal squamous-cell carcinoma: an open-label, multicentre, phase 2 trial. *Lancet Oncol* 2017;18:631–9.
- [7] Doi T, Piha-Paul SA, Jalal SI, et al. Safety and antitumor activity of the anti-programmed death-1 antibody pembrolizumab in patients with advanced esophageal carcinoma. *J Clin Oncol* 2018;36:61–7.
- [8] Shah MA, Kojima T, Hochhauser D, et al. Efficacy and safety of pembrolizumab for heavily pretreated patients with advanced, metastatic adenocarcinoma or squamous cell carcinoma of the esophagus: the phase 2 KEYNOTE-180 study. *JAMA Oncol* 2019;5:546–50.
- [9] Huang J, Xu B, Mo H, et al. Safety, activity, and biomarkers of SHR-1210, an anti-PD-1 antibody, for patients with advanced esophageal carcinoma. *Clin Cancer Res* 2018;24:1296–304.
- [10] Lin B, Song X, Yang D, et al. Anlotinib inhibits angiogenesis via suppressing the activation of VEGFR2, PDGFR β and FGFR1. *Gene* 2018;654:77–86.
- [11] Han B, Li K, Wang Q, et al. Effect of anlotinib as a third-line or further treatment on overall survival of patients with advanced non-small cell lung cancer: the ALTER 0303 phase 3 randomized clinical trial. *JAMA Oncol* 2018;4:1569–75.
- [12] Chi Y, Fang Z, Hong X, et al. Safety and efficacy of anlotinib, a multikinase angiogenesis inhibitor, in patients with refractory metastatic soft-tissue sarcoma. *Clin Cancer Res* 2018;24:5233–8.
- [13] Topalian SL, Taube JM, Anders RA, et al. Mechanism-driven biomarkers to guide immune checkpoint blockade in cancer therapy. *Nat Rev Cancer* 2016;16:275–87.
- [14] Wang Z, Duan J, Cai S, et al. Assessment of blood tumor mutational burden as a potential biomarker for immunotherapy in patients with non-small cell lung cancer with use of a next-generation sequencing cancer gene panel. *JAMA Oncol* 2019;5:696–702.
- [15] Schumacher TN, Schreiber RD. Neoantigens in cancer immunotherapy. *Science* 2015;348:69–74.
- [16] Socinski MA, Jotte RM, Cappuzzo F, et al. Atezolizumab for first-line treatment of metastatic nonsquamous NSCLC. *N Engl J Med* 2018;378:2288–301.
- [17] Xu JM, Zhang Y, Jia R, et al. Anti-PD-1 antibody SHR-1210 combined with apatinib for advanced hepatocellular carcinoma, gastric or esophagogastric junction cancer: an open-label, dose escalation and expansion study. *Clin Cancer Res* 2019;25:515–23.
- [18] Pishvaian MJ, Lee MS, Ryoo B, et al. Updated safety and clinical activity results from a Phase Ib study of atezolizumab + bevacizumab in hepatocellular carcinoma. *Annals Oncol* 2018;29(suppl_8):mdy424.028.