



Case Report

Modified Swenson-like pull-through with temporary stump for redo pull-through after failed Transanal Endorectal Pull-through

Zikrul Haikal, MD^{a,*}, Qisthinadia H. Setiadi, MD^b, Sunanto Sunanto, MD^b and Idyatul Hasanah, MN^c

^a Surgery Department, Faculty of Medicine, Universitas Mataram, Mataram, Indonesia

^b Pediatric Surgery Division, Surgery Department, West Nusa Tenggara Province General Hospital, Mataram, Indonesia

^c Nursing Department, Faculty of Health Sciences, Universitas Nahdlatul Wathan, Mataram, Indonesia

Received 2 April 2021; revised 8 September 2021; accepted 14 September 2021; Available online 9 November 2021



المخلص

مرض هيرشسبرونغ هو شذوذ خلقي في الجزء البعيد من الجهاز الهضمي، ويتميز بغياب الخلايا العقدية العصبية في الضفيرة العظمية المعوية وتحت المخاطية، مما يتسبب في تراكم البراز في الجزء القريب. يعتبر تفكك مفاغرة القولون أحد مضاعفات جراحة السحب داخل المستقيم عبر الشرج (تبيب). تبلغ هذه الورقة عن حالة مرض هيرشسبرونغ في فتاة تبلغ من العمر ست سنوات عانت من إفراز تفاعل بعد خضوعها لجراحة تبيب. بسبب تفكك التفاعل بعد جراحة تبيب، أجرينا عملية سحب متكررة باستخدام طريقة شبيهة بسوينسون باستخدام جذع مؤقت. يتم الاحتفاظ بالجذع لمدة أسبوعين، ثم يتم إزالتها في التقييم طويل الأمد، كانت هناك وظيفة هضمية طبيعية، ولا سلس بول، ونتائج شرجية ممتازة. يمكن أن تكون طريقة السحب المعدلة التي تشبه سوينسون مع جذوعها المؤقتة تقنية جراحية بديلة لإعادة السحب بعد فشل جراحة تبيب، مع نتائج مرضية.

الكلمات المفتاحية: مرض هيرشسبرونغ؛ جراحة السحب داخل المستقيم عبر الشرج؛ سحب مثل سوينسون؛ إعادة القيام بالسحب؛ جذع مؤقت

Abstract

Hirschsprung's disease is a congenital anomaly in the distal part of the gastrointestinal tract, characterised by the absence of neuronal ganglion cells in the myenteric and submucosal plexus, causing the accumulation of faeces in the proximal portion. Dehiscence of coloanal

anastomosis is one of the complications of Transanal Endorectal Pull-through (TEPT) surgery. This paper reports a case of Hirschsprung's disease in a six-year-old girl who experienced anastomotic dehiscence after undergoing TEPT. Due to post-TEPT anastomotic dehiscence, we performed a re-do pull-through with the modified Swenson-like method using a temporary stump. The stump is maintained for two weeks, then removed. On long-term evaluation, there was normal digestive function, no incontinence, and an excellent anal outcome. The modified Swenson-like pull-through with temporary stumps can be an alternative surgical technique for re-do pull-through after failed TEPT, with satisfactory results.

Keywords: Hirschsprung's disease; Re-do pull-through; Swenson-like pull-through; Temporary stump; Transanal Endorectal Pull-through

© 2021 Taibah University.

Production and hosting by Elsevier Ltd. This is an open access article under the CC BY-NC-ND license (<http://creativecommons.org/licenses/by-nc-nd/4.0/>).

Introduction

Hirschsprung's disease is a congenital abnormality in the distal portion of the gastrointestinal tract, characterised by the absence of neuronal ganglion cells in the myenteric and submucosal plexus.^{1,2} This causes the accumulation of faeces in the proximal part.² Generally, the chief complaint of patients is prolonged constipation; sometimes, patients present with acute bowel obstruction.^{2,3}

* Corresponding address: Faculty of Medicine, Universitas Mataram, Jl. Pemuda No. 37 Mataram, 83126, Indonesia.

E-mail: zikrulhaikal@gmail.com (Z. Haikal)

Peer review under responsibility of Taibah University.



The incidence of Hirschsprung's disease ranges from 1 to 2 per 10,000 live births.⁴⁻⁶ Short-segment Hirschsprung's disease, in which the aganglionic segment is confined to the rectum and rectosigmoid, is the most common type, accounting for more than 80% of the total cases.^{3,7} Hirschsprung's disease incidence in males is two to four times higher than in females.⁴⁻⁶

The definitive therapy for Hirschsprung's disease is surgery to resect the aganglionic segment, including the transition zone, and bring the ganglionic colon downward to the dentate line while maintaining anal sphincter function.^{2,3}

There are various commonly known recent surgical methods to treat Hirschsprung's disease. The most widely recognised are the Swenson, Duhamel, and Soave procedures.³ Transanal Endorectal Pull-through (TEPT) is currently the leading pull-through procedure. One of the complications that can occur after TEPT is coloanal anastomosis dehiscence, and operative management of this condition remains a challenge.

In this paper, we report our experience of the management of coloanal anastomosis dehiscence after TEPT surgery using a Swenson-like pull-through procedure followed by the maintenance of a temporary stump.

Case report

A six-year-old girl came to the Paediatric Surgical Outpatient Polyclinic with the complaint of difficulty defecating since the age of four years. The patient had a bowel movement usually once a week. On physical examination, there was no abdominal distension or darm contour; however, faecaloma was palpable. Laboratory studies showed promising results. There was no anaemia or impaired coagulation function. Thyroid hormone examination also showed normal results, which ruled out the possibility of constipation due to hypothyroidism. There were no signs suggestive of diabetes or other systemic diseases. The contrast enema (CE) showed a short-segment Hirschsprung's appearance (Figure 1). A full-

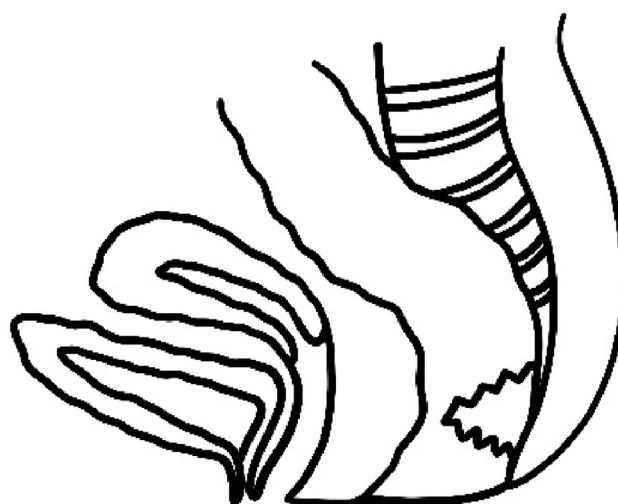

Figure 2: Dehiscence in the posterior side of the coloanal anastomosis.

thickness rectal biopsy was performed, and there was no ganglion found on histopathological examination.

After preoperative preparation, a definitive treatment was performed with Transanal Endorectal Pull-through (TEPT) surgery. The postoperative laboratory evaluation showed promising results. There were no signs of bleeding immediately after surgery. The rectal tube was postoperatively maintained for three days. After the procedure, the patient maintained took nothing by mouth for 24 h, followed by a gradual diet. Intravenous ceftriaxone 100 mg/kg/day was administered preoperatively up to five days postoperative. In addition, intravenous metronidazole at 10 mg/kg was given three times per day for five postoperative days. Postoperative pain was managed with intravenous paracetamol. Subsequent to an evaluation five days after surgery, the patient was discharged. Before discharge, an early postoperative

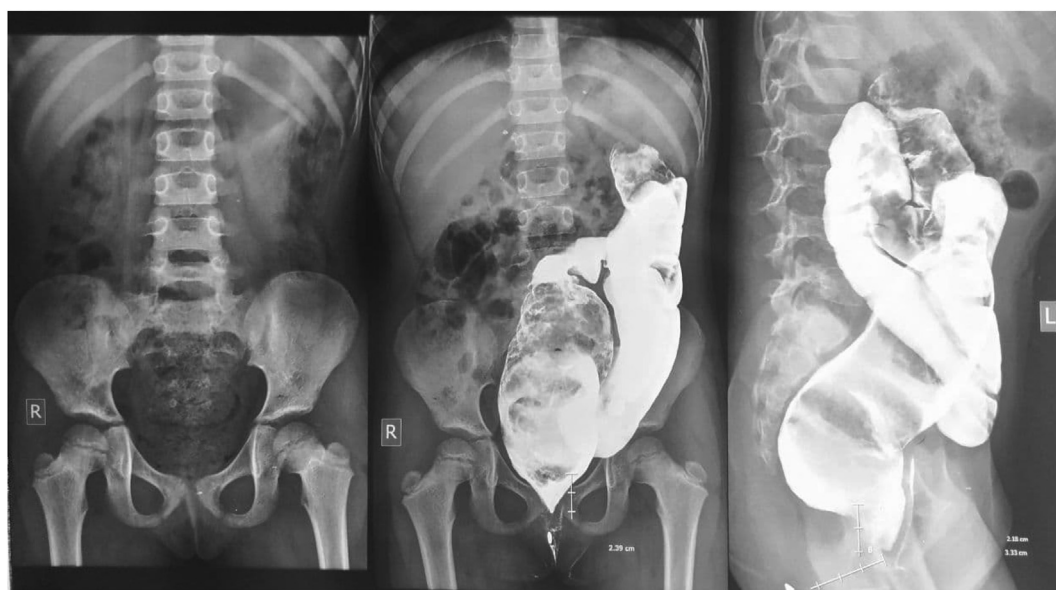

Figure 1: Preoperative contrast enema showing colonic dilatation proximal to the aganglionic colon.

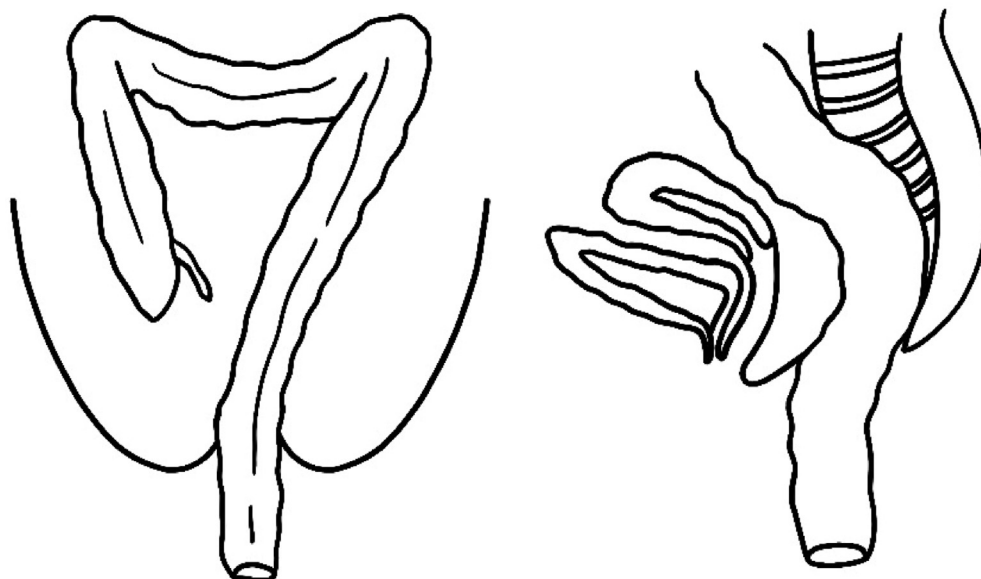



Figure 3: Temporary stump.

evaluation showed good defecation function, no abdominal distension, and no complications during post-TEPT treatment. Oral antibiotics and analgesics were given as a home medication for one week. The parents were advised not to perform any procedures/manoeuvres on the anus.

On postoperative day 11, the patient came to the Pediatric Surgery Outpatient Clinic, complaining of defecation mixed with bloody mucus and abdominal pain, especially in the lower middle quadrant. On physical examination, there was distended abdominal tenderness and muscular defences,

especially in the suprapubic region. A digital rectal examination found that the coloanal anastomotic was dehiscenced on the posterior side. Mucus and blood were observed on the gloves. A plain abdominal radiograph showed the appearance of a pneumoperitoneum, whereas laboratory studies showed mild anaemia, a mild increase in white blood cell count, and coagulation function within the normal range.

The patient then underwent an emergency exploratory laparotomy. There was bowel retraction leading to dehiscence in the posterior side of the coloanal anastomosis

(Figure 2). All coloanal anastomoses were removed, and the distal residual rectum was carefully resected to the proximal dentate line without leaving a muscle cuff in the previous operation, as in Swenson's procedure. The proximal punctum was released, then a re-pull-through was performed through the canal created during the first operation. The proximal bowel then passed through the anus to be used as a temporary stump (Figure 3). It would be complicated to re-do the pull-through in the future if the canal created in the previous operation was closed.

The stump colon was maintained for approximately two weeks, and then an operation was conducted again to remove it to the extent of the previous coloanal anastomosis. The coloanal anastomosis was performed using a 3-0 multifilament absorbable suture thread.

The patient was admitted for eight days after removing the stump and showed no symptoms of constipation or other complications. The patient was then allowed to be discharged from the hospital.

In long-term evaluation, there was normal digestive function, no incontinence, and an excellent anal outcome. The patient continued to undergo anal dilation using Hegar dilators for approximately six months after the last surgery.

Discussion

Since De la Torre first introduced it in 1998,⁸ TEPT has become the leading definitive surgical procedure for Hirschsprung's disease. Various modifications have been made to achieve the best results; however, despite significant advances in surgical techniques, complications remain common after pull-through surgery. One of the early postoperative complications of TEPT is dehiscence of a coloanal anastomosis. The incidence of anastomotic dehiscence after TEPT varies from 1.5% to 24%.^{9,10} In our case, constipation that occurred after surgery resulted in the accumulation of faecal material and triggered a retraction. This could occur if the mucosa is damaged during dissection, when there is a proximal retraction of the anastomotic, or when the blood supply is inadequate to the pull-through segment. The risk of anastomotic dehiscence is associated with anastomotic ischemia. Problems with poor blood flow can be caused by an anastomotic that is too tense.¹⁰

Anastomotic dehiscence usually occurs in patients who are diagnosed late with Hirschsprung's disease.¹¹ In a study conducted by Peng et al. (2018) on 213 patients who underwent the pull-through procedure due to Hirschsprung's disease, five (1.9%) patients experienced anastomotic dehiscence with a mean onset of seven days after the pull-through procedure and an average age of 6.8 years.¹² This is consistent with our case, in which the patient was diagnosed with Hirschsprung's disease after six years of age.

As previously mentioned, dehiscence generally occurs in patients diagnosed late and undergo surgery at the age of more than three years. Anastomosis dehiscence is associated with a moderately severely dilated colon in patients diagnosed late with Hirschsprung's disease. The proximal portion of the highly dilated aganglionic colon makes surgery difficult, especially in surgical procedures that use a transanal approach. All of these factors can cause inadequate

haemostasis, which ultimately leads to postoperative hematoma formation.¹²

In suturing with anastomotic dehiscence, the previously pulled-through colon is fragile and easily torn due to inflammation.¹² To overcome the complications of anastomotic dehiscence in our patient, we performed a re-do pull-through with a modified Swenson-like method by passing the colon through the anus and using it as a temporary stump.

Temporary colostomy or ileostomy in Hirschsprung's disease patients is performed to protect the anastomosis from the risk of leakage, fistula, or infection. In this case, the stump was maintained for two weeks, then removed. It functioned as a perineal stoma to prevent dehiscence in the anastomosis. Bio-adhesion between the colon and the surrounding tissue is expected to prevent retraction and dehiscence after re-anastomosis.

However, there is also a risk of dehydration, electrolyte imbalance, and patient discomfort as well as a psychological impact and inhibition of daily healthy activities.^{13,14} A case report study conducted by Handaya et al. argued that the use of a temporary coloanal stump is safe and has advantages over colostomy because it can avoid colostomy-related complications. In addition, the use of a coloanal stump shows a faster recovery time, reduces the risk of retraction, and optimises postoperative defecation function.¹⁴

Long-term evaluation needs to be performed postoperatively to monitor any complications, such as constipation or incontinence. Nearly 10% of patients require repeat surgery to treat complications of constipation and postoperative incontinence.² The long-term evaluation of our patient showed promising results, normal digestive function, no incontinence, and a good anal outcome.

The limitation of this study is that it is a case report of a single patient; therefore, the level of effectiveness cannot be determined. Further studies with a larger sample may be required.

Conclusion

The modified Swenson-like pull-through method with a temporary stump can be an alternative surgical technique for re-do pull-through in paediatric patients after failed TEPT, with a satisfactory outcome.

Source of funding

This study did not receive any specific grant from funding agencies in the public, commercial, or not-for-profit sectors.

Conflict of interest

The authors have no conflict of interest to declare.

Ethical approval

Consent for publication was obtained from the patient's parents. We endeavoured to remove any information that could identify the patient. To the best of our knowledge, this case report does not have any ethical issue.

Authors' contributions

ZH and QHS drafted the manuscript, S and ZH performed the surgical procedure, QHS collected the data, and ZH and IH critically revised the manuscript for important intellectual content. All authors have critically reviewed and approved the final draft and are responsible for the content and similarity index of the manuscript.

Acknowledgment

We wish to thank all those who helped in the preparation of this manuscript, especially the patients and their families who were willing to provide information related to the case.

References

- Martucciello G, Ceccherini I, Lerone M, Jasonni V. Pathogenesis of Hirschsprung's disease. *J Pediatr Surg* 2000 Jul 1; 35(7): 1017–1025.
- Chhabra S, Harwood R, Kenny SE. Hirschsprung's disease. *Surgery (United Kingdom)* 2019; 37: 640–645. Elsevier Ltd.
- Langer JC, Levitt MA. Hirschsprung disease. *Curr Treat Options Pediatr* 2020; 6: 128–139. Springer.
- Goldberg EL. An epidemiological study of Hirschsprung's disease. *Int J Epidemiol* 1984 Dec 1; 13(4): 479–485.
- Russell MB, Russell CA, Niebuhr E. An epidemiological study of Hirschsprung's disease and additional anomalies. *Acta Paediatr* 1994 Jan 1; 83(1): 68–71.
- Best KE, Addor M-C, Arriola L, Balku E, Barisic I, Bianchi F, et al. Hirschsprung's disease prevalence in Europe: a register based study. *Birth Defects Res Part A Clin Mol Teratol* 2014 Sep 1; 100(9): 695–702.
- Doodnath R, Puri P. A systematic review and meta-analysis of Hirschsprung's disease presenting after childhood. *Pediatr Surg Int* 2010 Nov 20; 26(11): 1107–1110.
- De La Torre-Mondragón L, Ortega-Salgado JA. Transanal endorectal pull-through for Hirschsprung's disease. *J Pediatr Surg* 1998; 33(8): 1283–1286.
- Pratap A, Gupta DK, Shakya VC, Adhikary S, Tiwari A, Shrestha P, et al. Analysis of problems, complications, avoidance and management with transanal pull-through for Hirschsprung disease. *J Pediatr Surg* 2007 Nov 1; 42(11): 1869–1876.
- Jester I, Holland-Cunz S, Loff S, Hosie S, Reinshagen K, Wirth H, et al. Transanal pull-through procedure for Hirschsprung's disease: a 5-year experience. *Eur J Pediatr Surg* 2009 Apr 17; 19(2): 68–71.
- Levitt MA, Hamrick MC, Eradi B, Bischoff A, Hall J, Peña A. Transanal, full-thickness, Swenson-like approach for Hirschsprung disease. *J Pediatr Surg* 2013 Nov 1; 48(11): 2289–2295.
- Peng C-H, Chen Y-J, Pang W-B, Zhang T-C, Wang Z-M, Wu D-Y, et al. STROBE-anastomotic leakage after pull-through procedure for Hirschsprung disease. *Medicine* 2018 Nov 1; 97(46):e13140.
- Mao Y Zhong, Tang S Tao, Li S. Duhamel operation vs. transanal endorectal pull-through procedure for Hirschsprung disease: a systematic review and meta-analysis. *J Pediatr Surg* 2018 Sep 1; 53(9): 1710–1715.
- Handaya AY, Fauzi AR, Andrew J, Hanif AS. Modified Duhamel with lateral anal sphincterotomy and coloanal stump for adult Hirschsprung's disease: a case series. *Int J Surg Case Rep* 2020; 77: 174–177. Elsevier Ltd.

How to cite this article: Haikal Z, Setiadi QH, Sunanto S, Hasanah I. Modified Swenson-like pull-through with temporary stump for redo pull-through after failed Transanal Endorectal Pull-through. *J Taibah Univ Med Sc* 2022;17(1):150–154.