

# Identification of intestinal abnormalities in patients with active pulmonary tuberculosis using small bowel capsule endoscopy



## Authors

Miwako Saitou<sup>1</sup>, Daiki Nemoto<sup>2</sup>, Kenichi Utano<sup>2</sup>, Tomoko Suzuki<sup>1</sup>, Alan Kawarai Lefor<sup>3</sup>, Kazutomo Togashi<sup>2</sup>, Katsunao Niitsuma<sup>1</sup>

## Institutions

- 1 Departments of Infectious Disease and Pulmonary Medicine, Aizu Medical Center, Fukushima Medical University, Fukushima, Japan
- 2 Department of Coloproctology, Aizu Medical Center, Fukushima Medical University, Fukushima, Japan
- 3 Department of Surgery, Jichi Medical University, Tochigi, Japan

submitted 21.3.2018

accepted after revision 30.3.2018

## Bibliography

DOI <https://doi.org/10.1055/a-0655-2086> |  
Endoscopy International Open 2018; 06: E1103–E1108  
© Georg Thieme Verlag KG Stuttgart · New York  
ISSN 2364-3722

## Corresponding author

Kazutomo Togashi, MD, PhD, Department of  
Coloproctology, Aizu Medical Center, Fukushima Medical  
University, 21-2 Maeda, Tanisawa, Kawahigashi,  
Aizuwakamatsu, Fukushima 969-3492, JAPAN  
Fax: +81-242-75-2568  
[togashik@fmu.ac.jp](mailto:togashik@fmu.ac.jp)

## ABSTRACT

**Background and study aims** *Mycobacterium tuberculosis* is often detected in the feces of patients with active pulmonary tuberculosis. However, no study has examined the small intestine using small bowel capsule endoscopy (SBCE). This study aimed to investigate intestinal abnormalities in patients with active pulmonary tuberculosis.

**Patients and methods** SBCE was performed in sputum/feces smear-positive pulmonary tuberculosis patients. From December 2013 to November 2016, 15 patients were enrolled from a dedicated tuberculous ward. The primary outcome was intestinal abnormalities identified by SBCE.

**Results** Fourteen patients (median age 81 years, range 29–91; 3 female) underwent SBCE to the terminal ileum. The video was not recorded for one patient who was excluded from the analysis. Intestinal lesions, including 5 annular ulcers in 4 patients, were observed in 64% (9/14). In subgroup analysis, prevalence tended to be higher in patients undergoing SBCE within 1 month of anti-tuberculous therapy ( $P=0.051$ ). Distribution of small intestinal lesions tended to be distal. Four of five annular ulcers were located close to the ileocecal valve.

**Conclusion** Prevalence of intestinal lesions in patients with pulmonary tuberculosis is higher than expected before (UMIN 000017292)

## Introduction

In the first half of the 20<sup>th</sup> century, intestinal tuberculosis was recognized as the most common complication of active pulmonary tuberculosis. Enteric involvement was found in most patients with pulmonary tuberculosis in autopsy and radiologic series [1,2]. With widespread use of antituberculous chemotherapy, incidence of intestinal tuberculosis diminished sharply, and it is now rarely seen and considered an uncommon complication of pulmonary tuberculosis [1]. According to autopsy study in Japan, prevalence of gastrointestinal tuberculosis with history of pulmonary tuberculosis was 1.6% [3]. How-

ever, *Mycobacterium tuberculosis* (MTB) is detected with high frequency in feces of patients with pulmonary tuberculosis [4]. Some patients with tuberculosis have had bowel perforations while receiving anti-tuberculous therapy [5,6].

Small bowel capsule endoscopy (SBCE) allows noninvasive evaluation of the small intestine [7]. In previous reports on patients with intestinal tuberculosis, SBCE was able to clearly depict lesions in the jejunum and ileum [8,9]. However, there are only single case or small case series reports of intestinal tuberculosis in patients with gastrointestinal symptoms. So far, no study has examined the entire small intestine in patients with active pulmonary tuberculosis, regardless of gastrointestinal

manifestations. The aim of this study was to investigate intestinal abnormalities in patients with active pulmonary tuberculosis using SBCE.

## Patients and methods

### Study design/setting

The study protocol followed ethical guidelines of the Helsinki Declaration and was approved by the Institutional Review Board of Fukushima Medical University. The study protocol was registered in the University Hospital Medical Information Network (UMIN000017292) on December 1, 2013. Written informed consent was obtained from all patients. The STROBE (Strengthening the Reporting of Observational Studies in Epidemiology) guidelines were followed in reporting this study.

### Patients

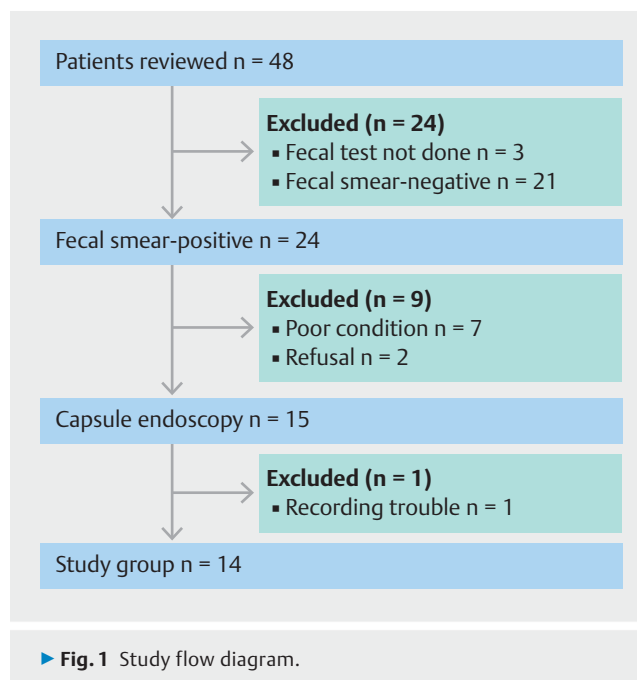
From December 2013 to November 2016, patients referred to Aizu Medical Center with pulmonary tuberculosis who were sputum smear-positive for acid-fast bacilli were enrolled by a pulmonary medicine specialist (MS). The hospital has a ward dedicated to care of patients with tuberculosis, available in this district with approximately 300,000 residents. At time of hospital admission, candidates for this study underwent fecal smear testing for acid-fast bacilli, and fecal smear-negative patients were excluded.

### Capsule endoscopy

Capsule endoscopes (PillCam SB2 or SB3, Given Imaging Ltd., Yokneam, Israel) were used to image the small bowel. Prior to SBCE examination, abdominal computed tomography (CT) scan was performed to evaluate for risk of capsule retention, instead of enterography or enteroclysis [10]. If intestinal obstruction was suspected on CT scan findings, patency capsule examination was used. On the day prior to the examination, patients took 10 mL of sodium picosulfate hydrate before bed, followed by an overnight fast. On the day of the study, patients drank 0.9 L of magnesium citrate 1 hour before capsule ingestion. All generated SBCE videos were separately reviewed by two experienced gastroenterologists (DN, KU), blinded to the patients' background but aware that the patients had pulmonary tuberculosis with sputum smear-positive for acid-fast bacilli, due to the study protocol. Both gastroenterologists interpreted more than 50 clinical SBCE examinations after completing an educational program provided by the Japanese Association for Capsule Endoscopy. Disagreement between raters was reassessed after discussion. Bowel cleansing level was evaluated using a four-point qualitative scale (poor, fair, good, excellent) [11]; "good" and "excellent" were considered adequate.

### Outcome measurements

The primary endpoint was identification of an intestinal abnormality identified by SBCE. In this study, intestinal abnormalities were limited to ulcers or erosions. Any subtle changes, e.g., slight erythema, were not included. The secondary endpoint was distribution of abnormalities. Subgroup analyses using age, body mass index, positive degree of sputum smear [12],



gastrointestinal symptoms, use of corticosteroids or immunosuppressants, long-term use of nonsteroidal anti-inflammatory drugs (NSAIDs) and time interval after antituberculous therapy were also performed.

### Statistical analysis

Descriptive data were generated for all variables regarding capsule endoscopy. As a pilot study to guide future research, the sample size was arbitrary. In subgroup analyses, Fisher's exact test or chi-square test was used for comparison.

## Results

### Patients

Antituberculous chemotherapy was started at time of hospital admission. All patients were confirmed as having MTB by genetic testing. After confirming fecal smear-positive for acid-fast bacilli as well as absence of intestinal obstruction on CT scan findings, a total of 15 patients underwent SBCE. No patient underwent patency capsule examination for suspicion of intestinal obstruction. Video recording failed in one patient who was excluded from the analysis (► Fig. 1). In chronological order, the backgrounds of the 14 patients included are shown in ► Table 1. There were trends toward male gender, old age and low body mass index. Six patients presented with gastrointestinal symptoms, including abdominal pain, diarrhea and altered bowel habits. Two patients were given corticosteroids and immunosuppressants due to dermatomyositis or rheumatoid arthritis, and one of these two patients regularly took NSAIDs. Three other patients also took NSAIDs for 1 month or longer. Three (No. 2, 5, 6) of the initial six patients underwent colonoscopy during the smear-positive period, and only one patient (No. 2) had abnormal findings at the ileocecal valve. The terminal ileum of the patient was unable to be observed

► **Table 1** Patient demographics.

| No. | Gender | Age | BMI  | Degree of sputum smear <sup>1</sup> | Gastrointestinal tract symptoms <sup>2</sup> | Use of corticosteroid/IM | Long-term use of NSAIDs | Interval after antituberculous therapy |
|-----|--------|-----|------|-------------------------------------|--|--------------------------|-------------------------|--|
| 1   | M      | 83  | 20.3 | 1+                                  | –  | –                        | –                       | 98 days                                |
| 2   | M      | 61  | 13.4 | 3+                                  | +  | +                        | +                       | 25 days                                |
| 3   | M      | 66  | 16.0 | 3+                                  | +  | –                        | –                       | 194 days                               |
| 4   | F      | 46  | 19.2 | 3+                                  | –  | –                        | –                       | 4 days                                 |
| 5   | M      | 83  | 17.2 | 3+                                  | –  | –                        | +                       | 48 days                                |
| 6   | M      | 85  | 21.6 | 1+                                  | +  | –                        | –                       | 57 days                                |
| 7   | M      | 91  | 23.5 | 2+                                  | –  | –                        | –                       | 6 days                                 |
| 8   | M      | 53  | 15.2 | 3+                                  | –  | –                        | –                       | 9 days                                 |
| 9   | M      | 92  | 18.8 | 2+                                  | +  | –                        | +                       | 7 days                                 |
| 10  | M      | 53  | 21.3 | 2+                                  | +  | –                        | –                       | 7 days                                 |
| 11  | M      | 79  | n/a  | 3+                                  | –  | +                        | –                       | 11 days                                |
| 12  | F      | 85  | 22.4 | 3+                                  | –  | –                        | –                       | 11 days                                |
| 13  | M      | 29  | 22.6 | 2+                                  | –  | –                        | –                       | 15 days                                |
| 14  | F      | 86  | 18.1 | 3+                                  | +  | –                        | +                       | 11 days                                |

BMI, body mass index calculated by height, m/(weight, kg)<sup>2</sup>; IM, immunosuppressant; NSAID, nonsteroidal anti-inflammatory drug; n/a, not available

<sup>1</sup> According to Reference 12

<sup>2</sup> Including abdominal pain and altered bowel habits

due to the destructive appearance at the valve with severe stenosis, but SBCE successfully identified an annular ulcer at the terminal ileum. Following this, no patients underwent colonoscopy. Ten patients underwent SBCE within a month after starting antituberculous therapy, while four underwent SBCE more than 1 month later because of critical tuberculous disease. One patient (No. 2) underwent ileocecal resection due to a perforated lesion 2 months after SBCE. Histology of the resected specimen showed granulomatous inflammation with caseous necrosis, suggesting tuberculous disease.

### SBCE procedure

Twelve of 14 capsules reached the colon within the duration of battery life, but two reached the ileum with active battery power and stopped sending data after the battery lost power. Median small intestine transit time (n=12) was 4 hours 27 minutes (range 2h 23min to 12h 28min). Bowel cleansing was adequate in 93% (13/14) of patients. There were no complications associated with the SBCE examinations.

### SBCE findings, patient-based

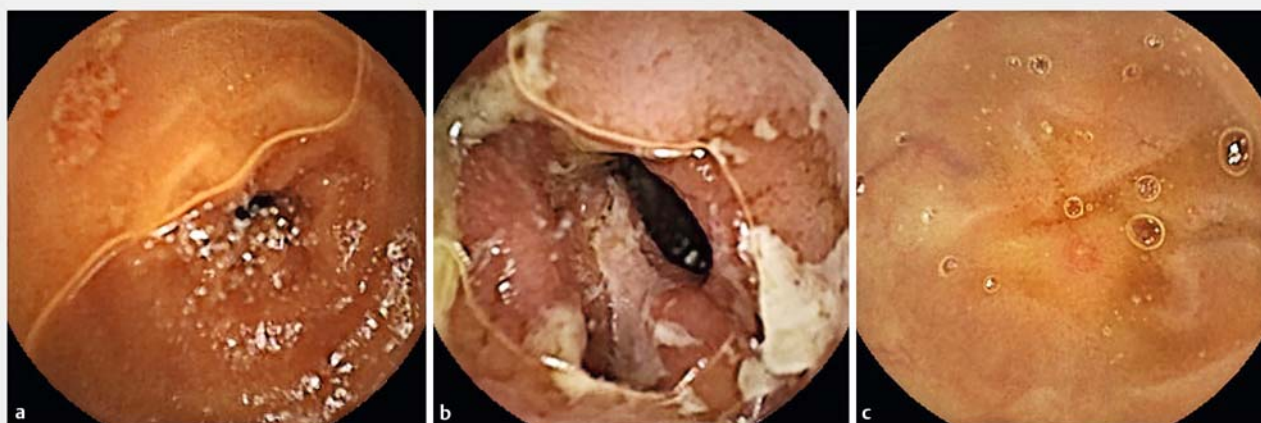Of 14 patients, nine (64%) had ulcers, accompanied by erosions in two (► **Table 2**). Five of nine patients with ulcers had annular ulcers, and one patient had two annular ulcers. Of seven patients with multiple lesions, six had multiple ulcers only and one had an “ulcer plus erosion.” Three of five patients with annular ulcers had wall thickening of the terminal ileum on abdominal CT scan images. Examples of an ulcer, an annular ulcer and an erosion are shown in ► **Fig. 2a**, ► **Fig. 2b** and

► **Table 2** Findings from small bowel capsule endoscopy.

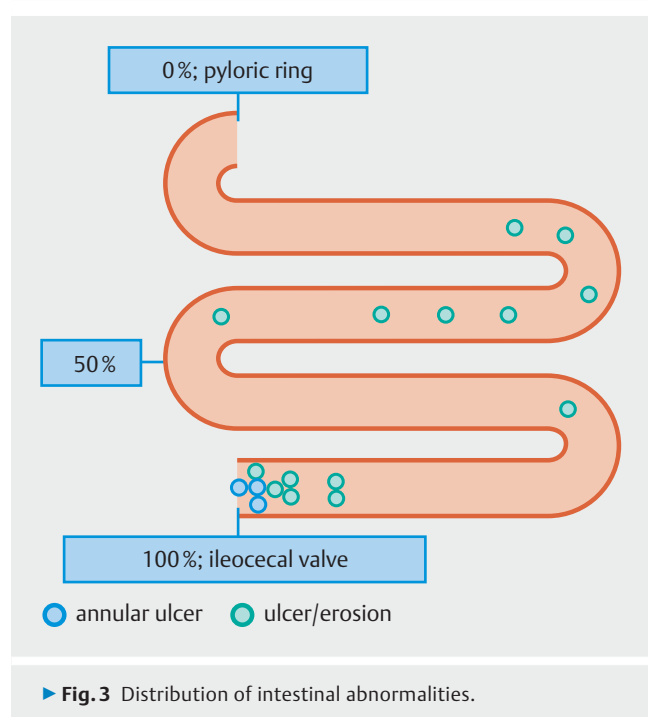
| Lesion                                  | n=14                 |
|---|----------------------|
| None                                    | 5 (36%)              |
| Present                                 | 9 (64%)              |
| ▪ erosion                               | 2 (14%)              |
| ▪ ulcer                                 | 9 (64%) <sup>1</sup> |
| Multiplicity                            | 7 (50%)              |
| <sup>1</sup> including 5 annular ulcers |                      |

► **Fig. 2c**. In subgroup analysis using the finding of an abnormal SBCE as a factor, there was a tendency in patients undergoing the study within 1 month after antituberculous therapy ( $\leq 1$  month: 8/10, 80%;  $> 1$  month: 1/4, 25%;  $P=0.095$ ). In subgroup analysis using presence of an annular ulcer as a factor, there was a tendency toward presence of gastrointestinal symptoms ( $P=0.091$ ), use of corticosteroids or immunosuppressants ( $P=0.11$ ), and long-term use of NSAIDs ( $P=0.095$ ). There were no specific trends in other subgroup analyses.

A total of 25 lesions in nine patients were depicted but eight lesions in two incomplete SBCE patients were excluded from the analysis of the distribution. A total of 17 lesions in seven patients were distributed throughout the entire small intestine (► **Fig. 3**). The majority of lesions were located in the distal small intestine. All three annular ulcers were located close to



► **Fig. 2** Intestinal abnormalities. **a** Ulcer. **b** Annular ulcer. **c** Erosion.



the ileocecal valve. Based on a localization system for capsule endoscopy, two annular ulcers in patients who had incomplete SBCE studies were located in the distal small intestine. Three months later, three patients underwent repeat SBCE. Two showed resolution of ulcerated lesions while new annular ulcers were found in one patient.

## Discussion

This study using SBCE imaging of the small intestine demonstrates that prevalence of intestinal lesions in sputum/fecal smear-positive patients with pulmonary tuberculosis was as high as 60%. Excluding four patients who underwent SBCE >1 month after antituberculous therapy, this prevalence

reached 80%, a much higher percentage than expected before. Four of nine patients with intestinal lesions had no gastrointestinal manifestations, suggesting that gastrointestinal symptoms may not always suggest presence of intestinal tuberculous lesion in patients with active pulmonary tuberculosis. Ingested MTB can be detected in gastric fluid. These organisms can survive in the gastrointestinal tract and be excreted in the stool [4, 13]. In the current study, indeed, MTB was observed in all fecal specimens. A previous study reported that MTB grew in 14.9% of sputum and 9.7% of fecal specimens in pulmonary tuberculosis patients [4]. The surviving MTB may cause infectious lesions in the intestine.

In the five patients with active pulmonary tuberculosis, however, no intestinal abnormalities were observed, even using SBCE. Of these patients, three underwent SBCE studies 1 month or more after antituberculous therapy started, while two patients who underwent SBCE within 2 weeks (4 and 9 days) were relatively young (46 y female, 53 y male). Age might be a pivotal factor related to incidence of intestinal lesions.

Most of the lesions were located in the distal small intestine, and all annular ulcers were found in the terminal ileum. These observations are consistent with previous reports using enteroscopy or enterography performed on patients with intestinal tuberculosis [1]. This may be attributed to the apparent affinity of MTB for lymphoid tissue and area of physiologic stasis [1]. In patients suspicious for intestinal tuberculosis, the initial test should be colonoscopy to assess the terminal ileum. Considering active tuberculous disease with possible dissemination, however, CT scan may be an alternative to colonoscopy because abnormal findings such as wall thickening of the terminal ileum on CT scan were seen in three of five patients with annular ulcers in this study.

There are acknowledged limitations to this study. First, the generalizability of these findings may be limited, as it was a single-center study with only 14 patients. Second, SBCE images may appear as multiple lesions when there is only a single lesion because the capsule moves to and fro in the small intestine. The multiplicity of intestinal lesions may be lower than suggested

**► Table 3** Rates of abnormal SBCE findings by factor.

| Factor                                       | Abnormal SBCE findings | P value | Presence of annular ulcer | P value |
|--|------------------------|---------|---------------------------|---------|
| Age  |                        |         |                           |         |
| ▪ <65 years                                  | 60 % (3/5)             | 1.00    | 40 % (2/5)                | 1.00    |
| ▪ ≥65 years                                  | 67 % (6/9)             |         | 33 % (3/9)                |         |
| Body mass index <sup>1</sup>                 |                        |         |                           |         |
| ▪ <18.5 (emaciation)                         | 40 % (2/5)             | 0.29    | 40 % (2/5)                | 1.00    |
| ▪ ≥18.5 (ordinary or obese)                  | 75 % (6/8)             |         | 25 % (2/8)                |         |
| Positive degree of sputum smear <sup>2</sup> |                        |         |                           |         |
| ▪ 1 +  | 50 % (1/2)             | 0.21    | 0 % (0/2)                 | 0.48    |
| ▪ 2 +  | 100 % (4/4)            |         | 50 % (2/4)                |         |
| ▪ 3 +  | 50 % (4/8)             |         | 38 % (3/8)                |         |
| Gastrointestinal symptoms <sup>3</sup>       |                        |         |                           |         |
| ▪ Present                                    | 83 % (5/6)             | 0.30    | 67 % (4/6)                | 0.091   |
| ▪ Absent                                     | 50 % (4/8)             |         | 13 % (1/8)                |         |
| Use of corticosteroids or immunosuppressants |                        |         |                           |         |
| ▪ Present                                    | 100 % (2/2)            | 0.51    | 100 % (2/2)               | 0.11    |
| ▪ Absent                                     | 58 % (7/12)            |         | 25 % (3/12)               |         |
| Long-term use of NSAIDs                      |                        |         |                           |         |
| ▪ Present                                    | 75 % (3/4)             | 1.00    | 75 % (3/4)                | 0.095   |
| ▪ Absent                                     | 60 % (6/10)            |         | 20 % (2/10)               |         |
| Interval after antituberculous therapy       |                        |         |                           |         |
| ▪ ≤1 month                                   | 80 % (8/10)            | 0.095   | 50 % (5/10)               | 0.22    |
| ▪ 1 month or longer                          | 25 % (1/4)             |         | 0 % (0/4)                 |         |

SBCE, small bowel capsule endoscopy; NSAID, nonsteroidal anti-inflammatory drug

<sup>1</sup> Calculated by body height, m / (weight, kg)<sup>2</sup> and one patient data was not available.

<sup>2</sup> According to reference 12

<sup>3</sup> Including abdominal pain and altered bowel habits;

Fisher's exact test was used for all factors except for positive degree of sputum smear, and Chi-square test was used for the exception.

by this SBCE study. Third, other factors such as NSAID use may cause intestinal lesions [14]. In the current series, there was no significant difference in the number of lesions comparing patients with long-term NSAID use and non-use. Despite these limitations, we believe that this study is meaningful because SBCE has clarified the prevalence and distribution of intestinal abnormalities in patients with active tuberculosis (► Table 3).

## Conclusion

In conclusion, SBCE identified intestinal lesions in patients with active pulmonary tuberculosis. Prevalence of intestinal tuberculous lesions is higher than previously reported and distribution of intestinal abnormalities is consistent with previous reports using conventional diagnostic modalities.

## Competing interests

None

## References

- [1] Marshall JB. Tuberculosis of the gastrointestinal tract and peritoneum. *Am J Gastroenterol* 1993; 88: 989–999
- [2] Mitchell RS, Bristol LJ. Intestinal tuberculosis: an analysis of 346 cases diagnosed by routine intestinal radiography on 5,529 admissions for pulmonary tuberculosis, 1924-49. *Am J Med Sci* 1954; 227: 241–249
- [3] Suzuki H, Nagao K, Miyazaki M. The current status and problems of the intestinal tuberculosis through a review of the Annual of the Pathological Autopsy Cases in Japan (in Japanese with English abstract). *Kekkaku* 2002; 77: 355–360

- [4] El Khechine A, Henry M, Raoult D et al. Detection of Mycobacterium tuberculosis complex organisms in the stools of patients with pulmonary tuberculosis. *Microbiology* 2009; 155: 2384–2389
- [5] Seabra J, Coelho H, Barros H et al. Acute tuberculous perforation of the small bowel during antituberculosis therapy. *J Clin Gastroenterol* 1993; 16: 320–322
- [6] Saitou M, Suzuki T, Niitsuma K. Intestinal perforation due to paradoxical reaction during treatment for miliary tuberculosis. *Respirol Case Rep* 2016; 4: e00196
- [7] Iddan G, Meron G, Glukhovskiy A et al. Wireless capsule endoscopy. *Nature* 2000; 405: 417
- [8] Rammohan A, Naidu RM. Capsule endoscopy: new technology, old complication. *J Surg Tech Case Rep* 2011; 3: 91–93
- [9] Yang XY, Chen CX, Zhang BL et al. Diagnostic effect of capsule endoscopy in 31 cases of subacute small bowel obstruction. *World J Gastroenterol* 2009; 15: 2401–2405
- [10] Enns RA, Hookey L, Armstrong D et al. Clinical Practice Guidelines for the Use of Video Capsule Endoscopy. *Gastroenterology* 2017; 152: 497–514
- [11] Brotz C, Nandi N, Conn M et al. A validation study of 3 grading systems to evaluate small-bowel cleansing for wireless capsule endoscopy: a quantitative index, a qualitative evaluation, and an overall adequacy assessment. *Gastrointest Endosc* 2009; 69: 262–270
- [12] American Thoracic Society. Diagnostic Standards and Classification of Tuberculosis in Adults and Children. *Am J Respir Crit Care Med* 2000; 161: 1376–1395
- [13] Kokuto H, Sasaki Y, Yoshimatsu S et al. Detection of mycobacterium tuberculosis (mtb) in fecal specimens from adults diagnosed with pulmonary tuberculosis using the Xpert MTB/Rifampicin test. *Open Forum Infect Dis* 2015; 2: ofv074
- [14] Iwamoto J, Mizokami Y, Saito Y et al. Small-bowel mucosal injuries in low-dose aspirin users with obscure gastrointestinal bleeding. *World J Gastroenterol* 2014; 20: 13133–13138