

# Skeletal muscle metastases from papillary and follicular thyroid carcinomas: An extensive review of the literature

LESZEK HERBOWSKI

Neurosurgery and Neurotraumatology Department, District Hospital, 71-455 Szczecin, Poland

Received September 22, 2017; Accepted January 16, 2018

DOI: 10.3892/ol.2018.8216

**Abstract.** Skeletal muscle metastasis of papillary or follicular thyroid cancer (PTC/FTC) is a rare finding; only 11 cases of skeletal muscle PTC or FTC metastasis have been included in medical literature reviews. The aim of this study was to identify all published cases of PTC and FTC muscle metastases and derive the true incidence of this malignancy. The probability of detecting the skeletal muscle metastasis of PTC and FTC was calculated based on epidemiological data. Databases of scientific literature on the Internet were searched for articles using relevant key words. The analysis of epidemiological data calculated the probability of detecting skeletal muscle lesions of this type as approximately zero. The literature search revealed 44 published international papers, reporting 58 cases of PTC or FTC skeletal muscle metastasis in 45 patients over 110 years, from 1907 to 2017. The most frequent PTC/FTC metastatic muscle was the gluteus. The majority of cases of muscle metastasis were caused by PTC, and metastatic tumors in the skeletal muscle negatively impacted the survival of patients with PTC or FTC.

## Introduction

Among the 14.1 million new cancer cases worldwide in 2012, with an age-standardized incidence of 182 per 100,000 population, the World Health Organization (WHO) reported 230,000 new cases of thyroid cancer in women and 68,000 cases in men, with an age-standardized incidence rate ( $P_{ThCa}$ ) of 3 per 100,000 for men and women combined (1). The female-to-male incidence ratio of thyroid cancer is 3.4. Among women, the incidence varies regionally by ~5-fold, from 4.7 per 100,000 in Central and East Asia, to 20 in North America. In the WHO report, the age-adjusted incidence rate for thyroid cancer in Europe in 2012 was 7.8 per 100,000 for women and 2.5 per 100,000 for men,

whereas the total number of new cancer cases was ~1,093,078 (standardized rate). Despite its rare incidence, papillary/follicular thyroid carcinoma (PTC/FTC) represents the most common type of all thyroid and endocrinological cancers (1).

In an autopsy study of 3,827 cancer patients performed between 1914 and 1943 analyzed by diSibio and French (2), 9,484 metastases were detected. Among these lesions, 96 were metastatic lesions secondary to thyroid carcinoma. The most common metastatic sites for thyroid cancer as a primary source of malignancy were the lungs ( $n=22$ ), regional lymph nodes ( $n=19$ ), distal lymph nodes ( $n=13$ ) and liver ( $n=10$ ). The report also identified 16 metastases to skeletal muscles, though none were from thyroid tumors. Thus, the annual incidence rate for muscle metastasis in patients with cancer ( $P_{Meta}$ ) was 0.0144%.

The rule for calculating the probability of two independent events occurring simultaneously is based on the conjunction formula; assuming that the incidence of skeletal muscle metastasis in PTC/FTC is the conjunction of the probability of each event, the formula is as follows:

$$P = P_{ThCa} \cap P_{Meta}$$

Given the values of these two probabilities, the calculation is as follows:

$$P = (3/100,000) \times (0.0144\%)$$

As a final result, the expected probability of detecting the skeletal muscle metastasis of PTC/FTC is 4/1,000,000,000. This event, with such a small probability, is predicted to occur only rarely. Medical cases published in the literature illustrate that events with a probability close to zero do in fact occur, thus confirming Borel's law (3). However, even in an extensive study by Haygood *et al* in 2012 (4) consisting of a literature review, clinical case reports and positron emission tomography-computed tomography (PET/CT) investigation, which included 341 patients with skeletal muscle metastases of carcinomas, no metastases derived from thyroid tumors were reported. Skeletal muscle metastases occur rarely, and metastases of PTC or FTC origin, collectively termed as differentiated thyroid carcinoma (DTC), are unique and may be clinically ignored, as noted by Song *et al* in 2011 (5); just 10 thyroid carcinoma metastases to the skeletal muscles were reported in their retrospective literature review.

The aim of the present study was to identify all published cases of PTC and FTC muscle metastasis to identify the true incidence rate for this malignancy.

---

*Correspondence to:* Dr Leszek Herbowski, Neurosurgery and Neurotraumatology Department, District Hospital, 4 Arkonska, 71-455 Szczecin, Poland  
E-mail: leszek@herbowski.eu

**Key words:** papillary thyroid carcinoma, follicular thyroid carcinoma, muscle metastasis, occult thyroid carcinoma, occult metastasis

## Materials and methods

**Database search.** Scientific databases (MEDLINE/PubMed, MEDLINE/Ebsco, Ovid, Scopus, ScienceDirect and Cochrane) on the Internet were searched for articles published prior to March 31st, 2017. The following keywords were used to identify published studies: ‘thyroid carcinoma’, ‘papillary thyroid carcinoma’, ‘follicular thyroid carcinoma’ and ‘muscle metastasis’. No limits were imposed on the language of the articles. Data concerning the following factors were collected: Age, sex, type of tumor, thyroid surgery, single or multiple metastases, metastatic size, duration time from surgery to metastasis, whether metastasis was the first manifestation of the thyroid tumor, muscle involvement and survival time. ‘Solitary metastasis’ was defined as a single lesion in the skeletal muscle, whereas ‘multiple metastases’ were defined as multiple lesions involving skeletal muscle and other organs. Multiple lesions in different muscles without metastases in other organs were identified as ‘synchronous muscle metastases’.

**Statistical analysis.** Statistical analyses were conducted using Statistica v.10 software (StatSoft, Inc., Tulsa, OK, USA). Collected data were assessed for a normal distribution with the Shapiro-Wilk and Lilliefors tests. The  $\chi^2$  and Wilcoxon tests were used to assess the associations between nominal and continuous variables, respectively. Correlations between variables were analyzed using Spearman correlation. Residual analysis was used to detect outliers in regression model. Outliers were identified when the residual values were higher than 1.5 times of the quartile range. Then, each outlier data could be excluded provided that Cook's distance was not greater than 1.0- we would consider this data influential.  $P < 0.05$  was considered to indicate a statistically significant difference.

## Results

**Identified studies.** Few accurate literature reviews are available concerning DTC metastases, with a number of additional papers providing retrospective reviews in the text. Of these, the reports described in the following section were considered to be of note.

In 2006, Pucci *et al* (6) presented a case of solitary PTC metastasis in a biceps muscle and reviewed the literature, reporting just 3 previous cases of PTC muscle metastasis. In 2009, Qiu and Luo (7) presented 2 cases of erector muscle metastasis. In a retrospective review of the literature, the authors reported a further 6 cases of DTC muscle metastasis (7). In 2011, Song *et al* (5) undertook a retrospective analysis of the literature and identified just 10 cases of DTC muscle metastasis; it was concluded that ‘most skeletal metastases are neither painful nor palpable’. In 2011, Bae *et al* (8) presented a case of PTC muscle metastasis and reported just 2 previous cases of PTC skeletal muscle metastases based on a literature review. Song *et al* reviewed the literature again in 2012 (9), and to their knowledge, just 7 cases of muscle PTC metastasis and 3 cases of muscle FTC metastasis had ever been reported. In 2013, Pirvu *et al* (10) presented a case of FTC pelvic muscle metastasis and reported just 5 cases of DTC

skeletal muscle metastasis in the literature. Tunio *et al* (11) described the FTC synchronous metastatic infiltration of 4 muscles, identifying just 7 cases of FTC skeletal muscle metastasis in the literature; the authors presented these 7 cases in a table, including 3 cases of FTC and 4 cases of PTC (*sic*). In 2014, Xue *et al* (12) investigated synchronous thigh and buttock FTC metastases, and analyzed the existing literature; this group identified just 11 cases of DTC muscle metastasis. Piplani *et al* (13) reported a patient with pelvic muscle FTC metastasis and identified ‘only a handful of cases, especially in erector spinae and biceps muscle’ in the literature, among which was an incorrectly reported case of pelvic metastasis reported by Dequanter *et al* (14); however, the tumor was an undifferentiated carcinoma and not of PTC origin. Yang *et al* (15) reported an unusual case of PTC metastasis to the gastrocnemius muscle and described just 2 cases of PTC skeletal muscle metastasis from the literature. In 2015, Portela *et al* (16) presented a case of PTC muscle metastasis within the sternocleidomastoid muscle and reviewed the literature, identifying just 1 previous case of PTC muscle metastasis. Sarma *et al* (17) described a case of FTC deltoid muscle metastasis; from reviewing the literature, the authors reported just 3 cases of solitary DTC muscle metastases. Cassidy *et al* (18) reported a case of PTC muscle metastasis; they reported 3 documented cases of symptomatic PTC muscle metastasis, and 3 cases of incidentally diagnosed PTC by single-photon emission computed tomography/CT and PET/CT, from the literature. In 2016, Li *et al* (19) discussed a case of synchronous PTC skeletal muscle metastasis and stated that there were ‘only a few reports’ of DTC skeletal muscle metastasis, without precise descriptions. Kuscic *et al* (20) published a case of PTC muscle metastasis and undertook a retrospective review of the literature, identifying only 7 reports of PTC muscle metastasis, with reference to studies by Song *et al* (5) and Iwai *et al* (21).

In total, the retrospective analysis of the medical literature revealed 44 published international studies describing 58 cases of PTC or FTC skeletal muscle metastasis in 45 patients over a period of 110 years (1907-2017; Table I)(21-51). The majority of the cases were reported during the last 10 years (Fig. 1). In 13 published studies (30%), there was no reference to PTC/FTC metastasis to the muscles in either the title or the summary (10,24,28,29,31,35,40-43,48,50,51).

## Data

**Patient characteristics.** In the present study, from 57 published cases of PTC/FTC muscle metastasis, the group analyzed included 28 females (62%) and 17 males (38%). The mean age was 56.1 years [95% confidence interval (CI), 50.9-61.2; range, 25-89]. A total of 32 patients (71%) presented with PTC, including 6 with a follicular variant, whereas 13 patients (29%) presented with FTC. The metastatic lesions were confirmed as metastases from PTC or FTC by biopsy and/or by surgical excision. Due to the lack of basic data, the case reported by Langhans (22) was not considered. The main features of the patients from all published cases are summarized in Table II.

**Age and time of diagnosis.** In total, 36 patients (82%) with a mean age of 54.7 years (95% CI, 48.7-60.3) had skeletal muscle metastasis diagnosed subsequent to thyroid surgery

Table I. Published papers with cases of papillary or follicular thyroid carcinoma-derived skeletal muscle metastases.

Year	Papers, n	Author/s	Cumulative article number	(Refs.)
1907	1	Langhans	1	(22)
1983	1	Johannessen	2	(23)
1985	1	Carcangiu <i>et al</i>	3	(24)
1990	1	Friedman <i>et al</i>	4	(25)
1996	1	Fernandez-Real <i>et al</i>	5	(26)
1999	1	Pomorski and Bartos	6	(27)
2000	1	Baloch and LiVolsi	7	(28)
2001	1	Mishra <i>et al</i>	8	(29)
2002	1	Karwowski <i>et al</i>	9	(30)
2003	1	Colella <i>et al</i>	10	(31)
2004	1	Chaffanjon <i>et al</i>	11	(32)
2005	1	Iwai <i>et al</i>	12	(21)
2006	2	Pucci <i>et al</i> ; Tamiolakis <i>et al</i>	14	(6,33)
2007	1	Panoussopoulos <i>et al</i>	15	(34)
2008	2	Kim <i>et al</i> ; Luo <i>et al</i>	17	(35,36)
2009	2	Qiu and Luo; Bruglia <i>et al</i>	19	(7,37)
2010	4	Zhao <i>et al</i> ; Krajewska <i>et al</i> ; Droz; Pascual <i>et al</i>	23	(38-41)
2011	4	Bae <i>et al</i> ; Hur <i>et al</i> ; Karaca <i>et al</i> ; Caobelli <i>et al</i>	27	(8,42-44)
2012	2	Li <i>et al</i> ; Mohapatra <i>et al</i>	29	(45,46)
2013	6	Pirvu <i>et al</i> ; Tunio <i>et al</i> ; Morita <i>et al</i> ; Califano <i>et al</i> ; Ceriani <i>et al</i> ; Madan <i>et al</i>	35	(10,11,47-50)
2014	3	Xue <i>et al</i> ; Piplani <i>et al</i> ; Yun <i>et al</i>	38	(12,13,51)
2015	4	Yang <i>et al</i> ; Portela <i>et al</i> ; Sarma <i>et al</i> ; Cassidy <i>et al</i>	42	(15-18)
2016	2	Li <i>et al</i> ; Kuscic <i>et al</i>	44	(19,20)

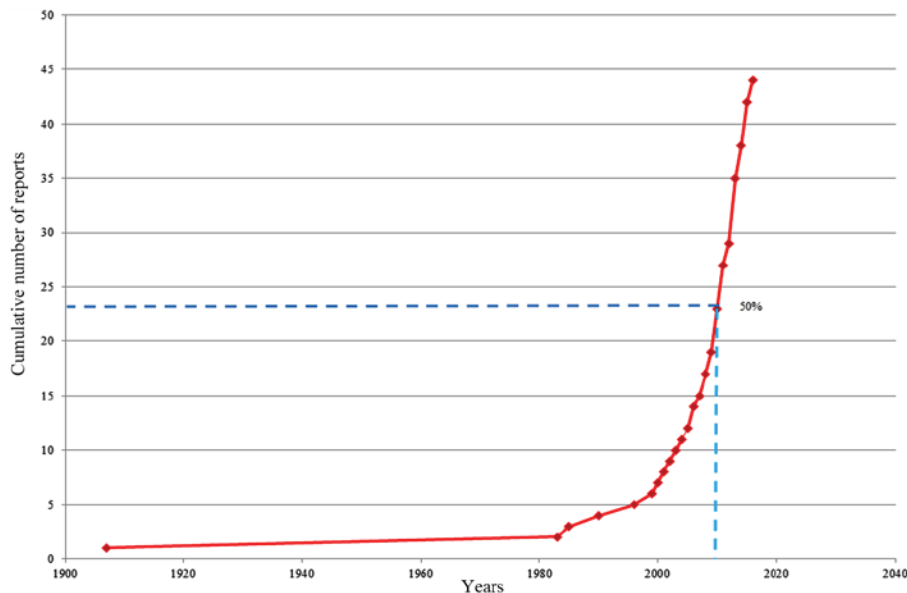


Figure 1. Cumulative number of reported papillary or follicular thyroid carcinoma-derived skeletal muscle metastases.

thyroidectomy, at a mean of 6.2 years afterwards (95% CI, 4.2-8.2; range, 1 month to 22 years). In 17 of the 36 patients, metastatic lesions were clinically silent and diagnosed only by chance. In contrast, 8 patients (18%) with a mean age of 63.4 years (95% CI, 50.8-75.9) had skeletal muscle metastasis

diagnosed prior to thyroidectomy, as the first manifestation of malignancy, including 4 cases of PTC and 4 cases of FTC.

*Metastatic muscle types.* Excluding Langhan's case, the most frequent metastatic muscles were the gluteus (9 cases),

Table II. Vital data of 44 patients with skeletal muscle metastases of PTC or FTC.

Sex	Identified	Histopathology	Number of lesions		Total
			Multiple	Solitary	
F	Pre-operatively	PTC	1	0	1
F	Pre-operatively	FTC	3	0	3
F	Post-operatively	PTC	16	1	17
F	Post-operatively	FTC	7	0	7
M	Pre-operatively	PTC	1	1	2
M	Pre-operatively	FTC	1	1	2
M	Post-operatively	PTC	9	2	11
M	Post-operatively	FTC	0	1	1
Total			38	6	44

PTC, papillary thyroid carcinoma; FTC, follicular thyroid carcinoma.

sternocleidomastoid (7 cases) and thigh (5 cases). Table III contains a detailed distribution of the muscle metastases; in summary, a total of 24 different muscles were involved in DTC. The majority of muscle metastases were associated with metastases in other organs, including other muscles, occurring in 38 patients (86%). Among them, synchronous muscle metastases were detected in 8 patients (18%). Solitary metastases were identified in 6 patients (14%), of whom 4 were diagnosed post-operatively with metastatic lesions, and 2 pre-operatively, as the first symptom of malignancy. Multiple muscles, ranging from 2 to 4 muscles, had been invaded in 8 patients (18%).

*Medical history data.* Detailed medical histories were available for 40 patients. Among them, 13 patients (32.5%) complained of painful muscle metastasis, whereas 27 (67.5%) were free of metastatic pain. A total of 11 patients had muscle metastasis detected during a palpation study. Among the 18 patients with recorded metastatic tumor sizes, the mean longest dimension was 6.3 cm (95% CI, 3.8-8.9; range, 0.9-20). Subsequent to the diagnosis of muscle metastasis, the following medical treatments were undertaken: Surgical excision alone in 18 patients, surgical excision post-biopsy in 5 patients, surgical excision and radiotherapy in 1 patient, biopsy alone in 13 patients, biopsy and radiotherapy in 3 patients, radiotherapy alone in 2 patients and sorafenib therapy in 2 patients.

*Survival time.* There were 10 reported cases of mortality, at a mean of 18.1 months (95% CI 5-41.3; between 1 week to 9 years) after muscle metastatic tumor detection. A total of 5 deceased patients had been diagnosed with PTC, 4 with FTC, and 1 with a follicular variant of PTC. Among these patients, muscle metastasis was diagnosed at a mean of 65.1 months (95% CI, 30.7-120; range, 1 month to 15 years) after the first thyroid carcinoma diagnosis and thyroid surgery. In a patient reported by Johannessen *et al* (23), survival times before and after metastasis appeared inconsistent with the remainder of the data set: metastasis-free survival was 6 years, and overall survival after metastasis was 9 years. This postmetastatic observation was identified as outlier (residual value was 11 times higher than the quartile range) and considered as non influential data (Cook's

Table III. Localization of 57 skeletal muscle metastases of papillary or follicular thyroid carcinomas.

Muscle	Identified		Total
	Pre-operatively	Post-operatively	
Gluteus muscles	6	3	9
Sternocleidomastoid	0	7	7
Thigh	1	4	5
Pterygoid	0	4	4
Erector spinae	1	3	4
Piriformis	4	0	4
Pelvic	2	1	3
Deltoid	0	2	2
Trapezoid	0	2	2
Psoas/iliopsoas	0	2	2
Masseter	1	1	2
Rectus abdominis	0	1	1
Medial rectus	1	0	1
Infraspinatus	0	1	1
Soleus	0	1	1
Biceps	1	0	1
Vastus	0	1	1
Adductor longus	0	1	1
Neck paraspinal	0	1	1
Levator ani	0	1	1
Temporal	0	1	1
Subscapularis	0	1	1
Gastrocnemius	0	1	1
Latissimus dorsi	0	1	1
Total	17	40	57

distance was 0.43). As a result, this observation was excluded from further statistical analysis.



*Associations between variables.* The survival time from metastasis to mortality was determined not to be normally distributed (Shapiro-Wilk test,  $P=0.00002$ ); however, age and survival time from thyroid surgery to metastasis were (Shapiro-Wilk test,  $P=0.06$  and  $P=0.20$ , respectively); non-parametric statistics were applied. Metastasis-free survival differed significantly from overall survival after metastasis (Wilcoxon test,  $P=0.036$ ).

Among the 44 patients, the age variable was not normally distributed (Lilliefors test,  $P<0.05$ ;  $\chi^2$  test,  $P=0.00091$ ); non-parametric statistics were applied. No association between age and sex, age and pre-/post-operative diagnosis status, or age and histopathology type was observed ( $P=0.21$ , 0.4344, and 0.7411, respectively;  $\chi^2$  test). The mean age of the patients with multiple lesions was 54.5 years (95% CI, 48.7-60.2; range, 25-89 years). In the group of patients with solitary lesions, the mean age was 66.3 years (95% CI 58.9-73.7; range, 53-72). The presence of multiple or solitary lesions was associated with age ( $P=0.0084$ ;  $\chi^2$  test).

A  $\chi^2$  test confirmed an association between the number of lesions and sex ( $P=0.0101$ ). Among the 28 women, 96% had multiple lesions, while among the 16 men, 69% had multiple lesions. The group of 6 patients with solitary lesions was predominantly comprised of men (83%), whereas the group of 38 patients with multiple lesions largely consisted of women (71%).

There was an association between the type of tumor and pre-/postoperative tumor identification ( $P=0.0239$ ;  $\chi^2$  test), with PTC bone metastases primarily identified postoperatively. Both PTC and FTC were most frequent in the postoperative period, at rates of 90 and 62%, respectively. Compared with FTC, PTC was detected 3.5-fold more often during the postoperative period. Additionally, there was a negative correlation between the survival time before or after muscle metastasis and age ( $r=-0.46$  and  $r=-0.39$ , respectively;  $P<0.05$ ).

## Discussion

Theodor Langhans is credited by Wozencraft *et al* (52) with the first observation of muscle infiltration by PTC in 1907. In the original paper, published in German in Virchows Archiv, Lanhgans presented a case of a woman with PTC where 'cellular extensions penetrated into the muscles' (21).

As defined by Mizukami *et al* (53), distant metastasis in FTC/PTC constitutes a tumor located 'outside the neck, thyroid or upper mediastinal area'. All metastatic muscles that pass the neck, including those connected to the cranium, are debatable. Therefore, in cases of carcinoma spreading to the sternocleidomastoid muscle, to avoid speculation of any type, the best solution is to use the term 'locoregional metastasis'. Among the 7 cases of sternocleidomastoid muscle metastasis published to date, 3 occurred as a result of previous endoscopic thyroid surgery (35,42,45), and 2 developed subsequent to a fine-needle aspiration biopsy (29,33). The other two cases of sternocleidomastoid muscle metastasis were likely due to carcinoma seeding from a previous thyroid operation (16,28). Among these 7 cases, 5 and 2 had PTC and FTC metastasis, respectively. In summary, all 5 jatrogenic cases should be excluded from further analysis; thus, there were only 2 cases of natural sternocleidomastoid muscle metastasis. Although

the skeletal muscles are hostile sites for cancer infiltration, malignant cells may spread to this organ (54). The mechanism for metastasis of this type may be hematogenic invasion, lymphatic metastasizing or extrathyroid extension from the post-operative bed (55,56).

In the present review of muscle PTC/FTC metastases, the female-to-male ratio was found to be 1.6, which is >2-fold lower than the incidence of primary carcinomas of this type among women and men (3.4).

In contrast to the results of Song *et al* (5), the present review identified that among the patients with muscle DTC metastasis with a detailed medical history, 1/3 complained of muscle pain, and the metastatic tumor could be detected by palpation in the majority of cases. This finding is in accordance with the statement by Tunio *et al* that 'skeletal muscle metastases present as painful masses' (11). However, it is difficult to agree with the statement by Xue *et al* that 'Most of skeletal muscle metastases are silent and may occasionally present as painful masses' (12). The mean size of the metastatic tumors was 6 cm, and this size is similar to that described by Tunio *et al* (2-12 cm) (11).

There is a likelihood that the malignancy was more aggressive, with multiple metastases in other organs, in younger patients. In general, the prognosis for PTC and FTC becomes worse with age and the conclusion of the present study supports this idea: The older the patient, the shorter the period between the onset of PTC/FTC and muscle metastases, as well as the period between muscle metastases and death.

Incidental PTC and FTC, which may not be detectable clinically, are currently identified via neck ultrasound, scintigraphy, fine-needle aspiration biopsy, CT, magnetic resonance imaging (MRI), whole-body scanning or 18F-fluorodeoxyglucose PET/CT during the pre- and post-operative management of thyroid carcinoma.

Carcinoma metastasis as an initial manifestation of occult PTC/FTC is very rare. In one of the largest Japanese studies with a cohort of 5,969 patients with PTC receiving surgery between 1987 and 2004, Ito *et al* (57) reported that distant metastasis was detected in 50 and 21 patients in the pre- and post-operative periods, respectively, using roentgenography, CT, scintigraphy and/or MRI; no muscle metastases were noted among the distant metastases. In the present review, 25 cases were identified of muscle metastasis diagnosed by chance post-operatively (17 cases) or as the first sign of occult PTC/FTC (8 cases). In contrast to the other organ metastases presented in the Japanese study, muscle PTC/FTC metastases, which were diagnosed incidentally, were 2-fold more frequent in the post-operative period. One reason for this apparent discrepancy may be the relatively higher quality and wider availability of imaging modalities, particularly PET/CT-fused images.

In a series of 449 PTC and 309 FTC patients, Pomorski and Bartos (27) detected distant metastases, predominantly to the bones and lungs, as the first sign of DTC in 4% and 1.9% of patients, respectively. According to Karaca *et al* (43), distant metastasis is detected upon the initial diagnosis of PTC in 2-5% of cases, whereas this value is just 1% according to Ito *et al* (57). In the present review, the corresponding rates were 13% for PTC and 31% for FTC. This notable difference may result from the fact that, in cases of muscle metastasis, the symptoms are more clinically visible, and are not hidden, as often occurs in cases of metastasis to deeper organs.

In the present review, the median overall survival after muscle metastasis was 18.1 months, whereas the reported median overall survival in patients with other PTC/FTC organ metastases is 49.2 months (58). Furthermore, the survival time after muscle metastasis in the present study was 3.6-fold shorter than the metastasis-free survival time. However, the differences in the rate that thyroid malignancy is revealed in the form of muscle metastasis between PTC and FTC may be attributable to the more invasive behavior of FTC relative to PTC. The aggressiveness of FTC presenting as muscle metastasis with no evidence of primary thyroid tumors could be the reason for this discrepancy. Therefore, PTC/FTC malignancy with muscle metastasis may be considered to have a worse prognosis.

The most common muscle involved in PTC/FTC malignancy was the gluteus muscle, as observed in 16% of reported cases, compared with the erector spinae muscles as concluded by other modern papers (8,10,17). The present review of the literature identified just 4 cases of erector spinae DTC metastasis (7%).

In summary, there were 58 PTC/FTC skeletal muscle metastases in 45 patients published in the medical literature over a 110-year period. The most frequently observed PTC/FTC metastatic muscle was the gluteus. The majority of the cases of muscle metastasis were caused by PTC. PTC/FTC metastasis to the skeletal muscle had a negative impact on survival. FTC may be more aggressive, as it is revealed earlier by the identification of muscle metastasis in cases of occult thyroid carcinoma.

### Acknowledgements

The author thanks Mrs Patrycja Herbowska-Tytro M.A. for help with the English translation and final preparation of the paper in terms of lexicon and grammar.

### Funding

No funding was received.

### Availability of data and materials

Not applicable.

### Author contributions

LH was responsible for the conception and design of the present study, the acquisition and interpretation of the data and drafting and revising the manuscript.

### Ethics approval and consent to participate

Not applicable.

### Consent for publication

Not applicable.

### Competing interests

The author declares that they have no competing interests.

### References

- Stewart BW and Wild CP: World Cancer Report 2014. IARC, Lyon, France, 2014.
- DiSibio G and French SW: Metastatic patterns of cancers: Results from a large autopsy study. *Arch Pathol Lab Med* 132: 931-939, 2008.
- Borel E: Elements of the Theory of Probability. Prentice-Hall, Englewood Cliffs, New Jersey, 1965.
- Haygood TM, Wong J, Lin JC, Li S, Matamoros A, Costelloe CM, Yeung H, Sandler CM, Nunez RF, Kumar R and Madewell JE: Skeletal muscle metastases: A three-part study of a not-so-rare entity. *Skeletal Radiol* 41: 899-909, 2012.
- Song HJ, Xue YL, Xu YH, Qiu ZL and Luo QY: Rare metastases of differentiated thyroid carcinoma: Pictorial review. *Endocr Relat Cancer* 18: R165-R174, 2011.
- Pucci A, Suppo M, Lucchesi G, Celeste A, Viberti L, Pellerito R and Papotti M: Papillary thyroid carcinoma presenting as a solitary soft tissue arm metastasis in an elderly hyperthyroid patient. Case report and review of the literature. *Virchows Arch* 448: 857-861, 2006.
- Qiu ZL and Luo QY: Erector spinae metastases from differentiated thyroid cancer identified by I-131 SPECT/CT. *Clin Nucl Med* 34: 137-140, 2009.
- Bae SY, Lee SK, Koo MY, Hur SM, Choi MY, Cho DH, Choe JH, Kim JH and Kim JS: Distant, solitary skeletal muscle metastasis in recurrent papillary thyroid carcinoma. *Thyroid* 21: 1027-1031, 2011.
- Song HJ, Xue YL, Qiu ZL and Luo QY: Uncommon metastases from differentiated thyroid carcinoma. *Hell J Nucl Med* 15: 233-240, 2012.
- Pirvu A, Guigard S, Blaise H and Chaffanjon P: Peroperative detection with a gamma probe of pelvic metastasis after differentiated thyroid carcinoma in female patients: About two cases and management reflections. *Chirurgia (Bucur)* 108: 126-129, 2013.
- Tunio MA, Alasiri M, Riaz K, Alshakwer W and Alarifi M: Skeletal muscle metastasis as an initial presentation of follicular thyroid carcinoma: A case report and a review of the literature. *Case Rep Endocrinol* 2013: 192573, 2013.
- Xue YL, Song HJ, Qiu ZL and Luo QY: Large thigh and buttock muscle metastases as the initial manifestation of follicular thyroid cancer. *Clin Nucl Med* 39: 363-364, 2014.
- Piplani S, Mannan R, Bhasin TS, Manjari M and Gill KS: Cytological diagnosis of follicular carcinoma thyroid metastasis in pelvic muscles-a rare and unusual site. *J Clin Diagn Res* 8: FD05-FD06, 2014.
- Dequantier D, Abdoulaye D, Lothaire P, Gebhart M and Andry G: Isolated pelvic metastasis of thyroid cancer. *Ann Endocrinol (Paris)* 62: 521-524, 2001 (In French).
- Yang J, Li LF, Zhang XM, Xu Q, Zhang J, Weng WW and Dong MJ: Unusual synchronous skeletal muscle and lung metastasis in papillary thyroid cancer: A case report and review of the literature. *Oncol Lett* 9: 727-730, 2015.
- Portela RA, Choby GW, Manni A, Campbell D, Crist H and Goldenberg D: Unusual sites of metastasis of papillary thyroid cancer: Case series and review of the literature. *Ear Nose Throat J* 94: E43-E47, 2015.
- Sarma M, Sonik B, Subramanyam P and Sundaram PS: Isolated skeletal muscle metastatic deposit in a patient with micropapillary carcinoma thyroid identified by 18F FDG PET CT. *J Egypt Natl Canc Inst* 27: 47-50, 2015.
- Cassidy DJ, Gupta GK and Graham RA: Metastasis of papillary thyroid cancer to the soft tissue of the back in the setting of recurrent disease. *AMSRJ* 1: 206-211, 2015.
- Li ZG, Lin ZC and Mu HY: Polysplenia syndrome with splenic and skeletal muscle metastases from thyroid carcinoma evaluated by FDG PET/CT: Case report and literature review: A care-compliant article. *Medicine (Baltimore)* 95: e2532, 2016.
- Kuscic LJ, Klancnik M, Paladin I and Kuna SK: Obstructive nephropathy caused by renal metastasis of papillary thyroid carcinoma: A case report. *Endocr Oncol Metab* 2: 83-86, 2016.
- Iwai H, Ohno Y, Ito H, Kiyokawa T and Aoki N: Renal rupture associated with a poorly differentiated follicular thyroid carcinoma metastasizing to the thigh muscle, lung and kidney. *Intern Med* 44: 848-852, 2005.
- Langhans T: Über die epithelialen Formen der malignen struma. *Virchows Arch f Path Anat* 89: 69-188, 2016.
- Johannessen JV, Sobrinões M, Lindmo T, Tangen KO, Kaalhus O and Brennhovd IO: Anomalous papillary carcinoma of the thyroid. *Cancer* 51: 1462-1467, 1983.

24. Carcangiu ML, Zampi G, Pupi A, Castagnoli A and Rosai J: Papillary carcinoma of the thyroid. A clinicopathologic study of 241 cases treated at the University of Florence, Italy. *Cancer* 55: 805-828, 1985.
25. Friedman J, Karesh J, Rodrigues M and Sun CC: Thyroid carcinoma metastatic to the medial rectus muscle. *Ophthalm Plast Reconstr Surg* 6: 122-125, 1990.
26. Fernández-Real JM, Villabona C, Fernández-Castañer M, Sagarra E, Gómez-Saéz JM and Soler J: Expression of ICAM-1 in distant metastatic thyroid carcinoma. *J Endocrinol Invest* 19: 183-185, 1996.
27. Pomorski L and Bartos M: Metastasis as the first sign of thyroid cancer. *Neoplasma* 46: 309-312, 1999.
28. Baloch ZW and LiVolsi VA: Encapsulated follicular variant of papillary thyroid carcinoma with bone metastases. *Mod Pathol* 13: 861-865, 2000.
29. Mishra A, Agarwal A, Agarwal G and Mishra SK: Internal jugular vein invasion by thyroid carcinoma. *Eur J Surg* 167: 64-67, 2001.
30. Karwowski JK, Nowels KW, McDougall IR and Weigel RJ: Needle track seeding of papillary thyroid carcinoma from fine needle aspiration biopsy. A case report. *Acta Cytol* 46: 591-595, 2002.
31. Colella G, Capone R and Cappabianca S: Mandibular metastasis from papillary thyroid carcinoma-a case report. *Tumori* 89: 452-454, 2003.
32. Chaffanjon PC, Sturm N, Caravel JP, Chabre O and Brichon PY: Pelvic muscular metastasis of well differentiated thyroid carcinoma. *Ann Chir* 129: 100-102, 2004 (In French).
33. Tamiolakis D, Antoniou C, Venizelos J, Lambropoulou M, Alexiadis G, Ekonomou C, Tsiminikakis N, Alifieris E, Papadopoulos N, Konstantinidis T and Kouskoukis C: Papillary thyroid carcinoma metastasis most probably due to fine needle aspiration biopsy. A case report. *Acta Dermatovenerol Alp Pannonica Adriat* 15: 169-172, 2006.
34. Panoussopoulos D, Theodoropoulos G, Vlahos K, Lazaris ACH and Papadimitriou K: Distant solitary skeletal muscle metastasis from papillary thyroid carcinoma. *Int Surg* 92: 226-229, 2007.
35. Kim JH, Choi YJ, Kim JA, Gil WH, Nam SJ, Oh YL and Yang JH: Thyroid cancer that developed around the operative bed and subcutaneous tunnel after endoscopic thyroidectomy via a breast approach. *Surg Laparosc Endosc Percutan Tech* 18: 197-201, 2008.
36. Luo Q, Luo QY, Sheng SW, Chen LB, Yu YL, Lu HK and Zhu RS: Localization of concomitant metastases to kidney and erector spinae from papillary thyroid carcinoma using (131)I-SPECT and CT. *Thyroid* 18: 663-664, 2008.
37. Bruglia M, Palmonella G, Silvetti F, Rutigliano P, Criante P, Marmorale C, Boscaro M and Tacaliti A: Skin and thigh muscle metastasis from papillary thyroid cancer. *Singapore Med J* 50: e61-e64, 2009.
38. Zhao LX, Li L, Li FL and Zhao Z: Rectus abdominis muscle metastasis from papillary thyroid cancer identified by I-131 SPECT/CT. *Clin Nucl Med* 35: 360-361, 2010.
39. Krajewska J, Olczyk T, Roskosz J, Paliczek-Ciešlik E, Smetana AK, Kaczmarek-Borowska B and Jarząb B: Treatment with sorafenib in advanced thyroid cancer-a case report. *Endokrynol Pol* 61: 492-496, 2010.
40. Droz JP: Pitfalls and uncommon problems in thyroid cancer management. *Cancer World* 37: 15-22, 2010.
41. Pascual RC, Castaneda JF and Romualdez JA: Papillary thyroid carcinoma presenting with a right preauricular and intracranial mass. *Philipp J Otolaryngol Head Neck Surg* 25: 26-30, 2010.
42. Hur SM, Kim SH, Lee SK, Kim WW, Choi JH, Kim JH, Choe JH, Lee JE, Oh YL, Nam SJ, *et al*: Is a thyroid follicular neoplasm a good indication for endoscopic surgery? *Surg Laparosc Endosc Percutan Tech* 21: e148-e151, 2011.
43. Karaca H, Lale A, Er O, Özkan M, Deniz K, Kula M, Karahan OI and Bayram F: Follicular thyroid cancer presenting as a pelvic mass: A case report. *Türk Jem* 15: 23-25, 2011.
44. Caobelli F, Paghera B, Panarotto MB, Camoni L and Giubbini R: Two distant muscular metastases from papillary carcinoma of the thyroid demonstrated by <sup>18</sup>F-FDG PET/CT and confirmed by biopsy. *Nucl Med Mol Imaging* 45: 324-325, 2011.
45. Li S, Zhang F, Zhang Y, Liang Y, Qi X, Yang X and Jiang J: Implantation at sternocleidomastoid and chest wall after endoscopic thyroid carcinoma surgery. *Surg Laparosc Endosc Percutan Tech* 22: e239-e242, 2012.
46. Mohapatra T, Arora A and Bethune NN: Coexisting iodine avid and iodine nonconcentrating lesions with multiple distant soft tissue metastasis in papillary thyroid cancer. *Indian J Nucl Med* 27: 38-41, 2012.
47. Morita N, Morimoto K, Yonezawa K, Otsuki N and Nibu K: Infratemporal fossa metastasis of papillary thyroid cancer. *Head Neck* 35: E119-E121, 2013.
48. Califano I, Quildrian S, Coduti M, Rojas Bilbao E, Otero J and Califano L: Soft tissue metastases from differentiated thyroid cancer diagnosed by <sup>18</sup>F FDG PET-CT. *Arq Bras Endocrinol Metabol* 57: 317-321, 2013.
49. Ceriani L, Treglia G, Paone G, Bongiovanni M, Franscella S and Giovanella L: Unusual muscular metastases from papillary thyroid carcinoma detected by fluorine-18-fluorodeoxyglucose PET/MRI. *J Clin Endocrinol Metab* 98: 2208-2209, 2013.
50. Madan R, Goyal S, Dinda AK and Maohanti BK: Papillary carcinoma of thyroid with paranasal sinus metastases. *Clin Cancer Invest J* 2: 90-92, 2013.
51. Yun KJ, Kim W, Kim EH, Kim MH, Lim DJ, Kang MI and Cha BY: Accelerated disease progression after discontinuation of sorafenib in a patient with metastatic papillary thyroid cancer. *Endocrinol Metab (Seoul)* 29: 388-393, 2014.
52. Wozencraft P, Foote FW and Frazell EL: Occult carcinomas of the thyroid. Their bearing on the concept of lateral aberrant thyroid cancer. *Cancer* 1: 574-583, 1948.
53. Mizukami Y, Michigishi T, Nonomura A, Hashimoto T, Terahata S, Noguchi M, Hisada K and Matsubara F: Distant metastases in differentiated thyroid carcinomas: A clinical and pathologic study. *Hum Pathol* 21: 283-290, 1990.
54. Seely S: Possible reasons for the high resistance of muscle to cancer. *Med Hypotheses* 6: 133-137, 1980.
55. Moritani S: Impact of superior mediastinal metastasis on the prognosis of papillary thyroid carcinoma. *Endocr J* 63: 349-357, 2016.
56. Schmid KW: Lymph node and distant metastases of thyroid gland cancer. Metastases in the thyroid glands. *Pathologe* 36 (Suppl 2): S171-S175, 2015 (In German).
57. Ito Y, Masuoka H, Fukushima M, Inoue H, Kihara M, Tomoda C, Higashiyama T, Takamura Y, Kobayashi K, Miya A and Miyauchi A: Prognosis and prognostic factors of patients with papillary carcinoma showing distant metastasis at surgery (M1 patients) in Japan. *Endocr J* 57: 523-531, 2010.
58. Shoup M, Stojadinovic A, Nissan A, Ghossein RA, Freedman S, Brennan MF, Shah JP and Shaha AR: Prognostic indicators of outcomes in patients with distant metastases from differentiated thyroid carcinoma. *J Am Coll Surg* 197: 191-197, 2003.



This work is licensed under a Creative Commons Attribution-NonCommercial-NoDerivatives 4.0 International (CC BY-NC-ND 4.0) License.