



Dose-response Effects of Bleomycin on Inflammation and Pulmonary Fibrosis in Mice

Soo Nam Kim¹, Jinsoo Lee^{1,2}, Hyo-Seon Yang¹, Jae-Woo Cho³, Soonjin Kwon^{1,2}, Young-Beom Kim³, Jeong-Doo Her¹, Kyu-Hyuk Cho¹, Chang-Woo Song¹ and Kyuhong Lee¹

¹Inhalation Toxicology Center, KIT Jeongeup Campus, Jeollabuk-do 580-185

²Major of Pharmacology and Toxicology, University of Science and Technology, Daejeon 305-333

³Division of Toxicologic Pathology, Korea Institute of Toxicology, Daejeon 305-343, Korea

(Received July 11, 2010; Revised August 1, 2010; Accepted August 11, 2010)

Many studies have reported that bleomycin, anti-cancer drug, induces pulmonary fibrosis as a side effect. However, few investigations have focused on the dose-response effects of bleomycin on pulmonary fibrosis. Therefore, in the present study, we investigated the effects of different doses of bleomycin in male mice. ICR mice were given 3 consecutive doses of bleomycin: 1, 2, or 4 mg/kg in bleomycin-treated (BT) groups and saline only in vehicle control (VC) groups. The animals were sacrificed at 7 and 24 days post-instillation. The severity of pulmonary fibrosis was evaluated according to inflammatory cell count and lactate dehydrogenase (LDH) activity in the broncho alveolar lavage fluid (BALF), and lung tissues were histologically evaluated after hematoxylin and eosin (H&E), and Masson's trichrome staining. BT groups exhibited changed cellular profiles in BAL fluid compared to the VC group, which had an increased number of total cells, neutrophils, and lymphocytes and a modest increase in the number of macrophages at 7 days post-bleomycin instillation. Moreover, BT groups showed a dose-dependent increase in LDH levels and inflammatory cell counts. However, at 24 days after treatment, collagen deposition, interstitial thickening, and granulomatous lesions were observed in the alveolar spaces in addition to a decrease in inflammatory cells. These results indicate that pulmonary fibrosis induced by 4 mg/kg bleomycin was more severe than that induced by 1 or 2 mg/kg. These data will be utilized in experimental animal models and as basic data to evaluate therapeutic candidates through non-invasive monitoring using the pulmonary fibrosis mouse model established in this study.

Key words: Bleomycin, Pulmonary fibrosis, Inflammation, Mouse model

INTRODUCTION

Pulmonary fibrosis is the final phase of many severe lung injuries, and is characterized as a diffuse disease of the lung parenchyma (Lazo *et al.*, 1990) and by epithelial cell damage, and fibroblast proliferation (Manoury *et al.*, 2007). Similarly, idiopathic pulmonary fibrosis (IPF) in humans is a disease characterized by alveolar epithelial cell injury and hyperplasia, inflammatory cell accumulation, and fibroblast hyperplasia. This disease results in the loss of alveolar surface area and leads to impaired gas exchange and pulmonary function (Moor and Hogaboam, 2008). The incidence of this disease may be as high as 3/10,000 in the U.S. popu-

lation. The prevalence of this disease is estimated at 20/100,000 for males and at 13/100,000 for females and age at onset is usually over 50 years (Moeller *et al.*, 2006).

To study this disease in humans, a variety of animal models of pulmonary fibrosis have been developed using profibrotic chemical agents, such as bleomycin, gene overexpression (transforming growth factor- β (TGF- β), interleukin (IL)-1, IL-13, and others) and irradiation or instillation of inorganic particles (asbestos or silica) to mimic human pulmonary fibrosis (Moeller *et al.*, 2006). Among them, the bleomycin model of pulmonary fibrosis is the best characterized rodent model presently in use (Moor and Hogaboam, 2008) because it induces fibrotic changes in a consistent manner and produces different patterns of fibrotic lesions depending on the dose and route of application (Moeller *et al.*, 2006). Moreover, pulmonary fibrosis induced by bleomycin in rodents is widely used as a model that exhibits a pathology similar to that found in human IPF

Correspondence to: Kyuhong Lee, Inhalation Toxicology Center, KIT Jeongeup Campus, 1051, Shinjeong-dong, Jeongeup, Jeollabuk-do 580-185, Korea
E-mail: khlee@kitox.re.kr

(Chaudhary *et al.*, 2006). Bleomycin is an antineoplastic compound used therapeutically against squamous cell carcinoma and lymphoma (Briggs *et al.*, 1985), but the clinical use of bleomycin is unfortunately limited by the dose-related development of pulmonary fibrosis. However, the standard models of pulmonary fibrosis are bleomycin-treated rodents (Scriabine and Rabin, 2009). Animal models for human pulmonary fibrosis ideally should reflect detailed characteristics of human disease including inflammation and aberrant epithelial repair with the induction of fibrotic foci. In addition, animal models should be highly reproducible and consistent, inexpensive to maintain, easy to perform and accessible. Although many studies and medical therapies from the animal model of pulmonary fibrosis induced by bleomycin have reported, few investigations have focused on the dose-related effects of bleomycin.

Therefore, in present study, we further elucidated the dose effects of bleomycin via assessment of the severity of pulmonary fibrosis by comparing the effects of different bleomycin doses in mice.

MATERIALS AND METHODS

Animal preparation. Male ICR mice (7-week old, $n = 24$) were obtained from Orient-bio (Sungnam, Korea). The animals were maintained in a specific pathogen free environment at a constant temperature ($23^{\circ}\text{C} \pm 3$), a relative humidity of $50\% \pm 10$, light/dark cycle of 12 hours, and with 150–300 Lux, ventilation approximately 10–20 times/hour. All mice were acclimatized to these surroundings for a week prior to experimental procedures. A gamma-ray irradiated standard laboratory rodent pellet diet (P.M.I. Nutrition International, Richmond, USA) and municipal tap water sterilized by ultraviolet light were provided to the animals *ad libitum*.

All experiments were performed in accordance with the guidelines and regulations of the Korea Institute of Toxicology, which was approved by the Institutional Animal Care and Use Committee (IACUC). All animal facilities in this study were accredited by the Association for Assessment and Accreditation of Laboratory Animal Care International (AAALAC).

Experimental design and animal treatment. All mice ($n = 24$) were divided randomly into the following 4 groups: (A) saline-only ($n = 6$, control group, VC), (B) bleomycin 1 mg/kg ($n = 6$, bleomycin-treated group, BT1), (C) bleomycin 2 mg/kg ($n = 6$, bleomycin-treated group, BT2), bleomycin 4 mg/kg ($n = 6$, bleomycin-treated group, BT4). To induce pulmonary fibrosis, bleomycin hydrochloride (Bleomycin HCl, Nippon Kayaku, Tokyo, Japan) was dissolved in sterilized 0.9% saline and administered intratracheally as a single dose of 1, 2, or 4 mg/kg in 30 μl solution per animal. The VC group was treated with 30 μl of sterile 0.9%

saline instead of bleomycin on day 0. The mice were sacrificed at 7 and 24 days post-intratracheal instillation (ITI), (VC, BT1, BT2, and BT4; $n = 3$ per each point).

Clinical signs, mortality and body weight. Clinical signs and mortality were observed daily over the entire duration of the study. Body weights were measured just before instillation and once a week post-bleomycin instillation.

Collection and inflammatory cell count of BAL fluid. Under isoflurane anesthesia, the lungs were prepared for lavage by cannulating the trachea with a polypropylene tube attached by a syringe. The lung lavage was obtained by washing 3 times with 1 ml of sterile 0.9% saline. Samples were centrifuged at 3,000 rpm for 10 minutes, cell pellets were resuspended in sterile 0.9% saline, and total immune cell counts were performed using a automated cell viability analyzer (Vi-CELLTM, Beckman Coulter). The resuspended pellets were centrifuged by Shandon Cytospin 4 (Thermo). Differential cell counts were evaluated at a magnification of $\times 1000$ by light microscopy (BX51, Olympus, Tokyo, Japan) by counting 300 cells stained with Wright-Giemsa.

Biochemical analysis. Lactate dehydrogenase (LDH) levels in the BALF supernatant were measured by a slide kit using DRY-CHEM 3500S (Fuji Film, Tokyo, Japan). Measurements were carried out according to the manufacturer's instructions.

Histological examination. Mouse lungs were inflated with 10% neutral buffered formalin after sacrifice. The trachea was tied off and the harvested lungs from all animals were fixed with 10% neutral buffered formalin for 1 week and embedded in paraffin. Next, 3–4 μm thick sections were cut and stained with hematoxylin-eosin (H&E) for histological examination and Masson's trichrome for examination of fibrotic changes in adjacent sections. The sections of each tissue specimen were evaluated at a magnification of $\times 100$ by light microscopy (BX51, Olympus, Tokyo, Japan) for histological examination.

Statistics. All values are presented as the means \pm S.E. of the results obtained from the treatment groups. All results were compared using Dunnett's test after one-way analysis of variance (ANOVA) analysis. All analyses were performed using the SAS statistical software package. Significant differences were statistically determined at the level of p value 0.05.

RESULTS

Clinical signs, mortality, and body weight changes. The VC and BT groups did not exhibit obvious clinical

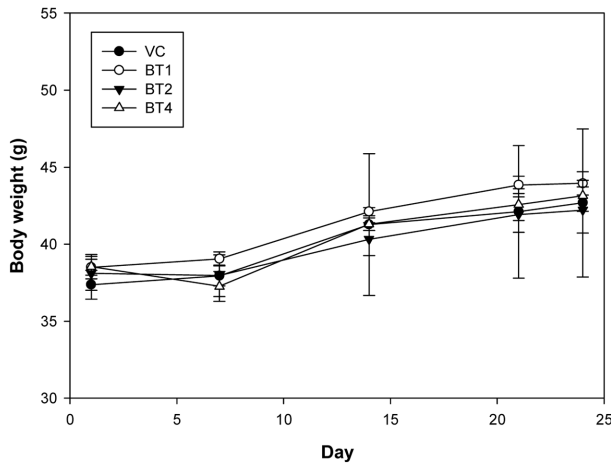


Fig. 1. Body weight changes during treatment with vehicle control (●), BT1 (○), BT2 (▼), and BT4 (▽).

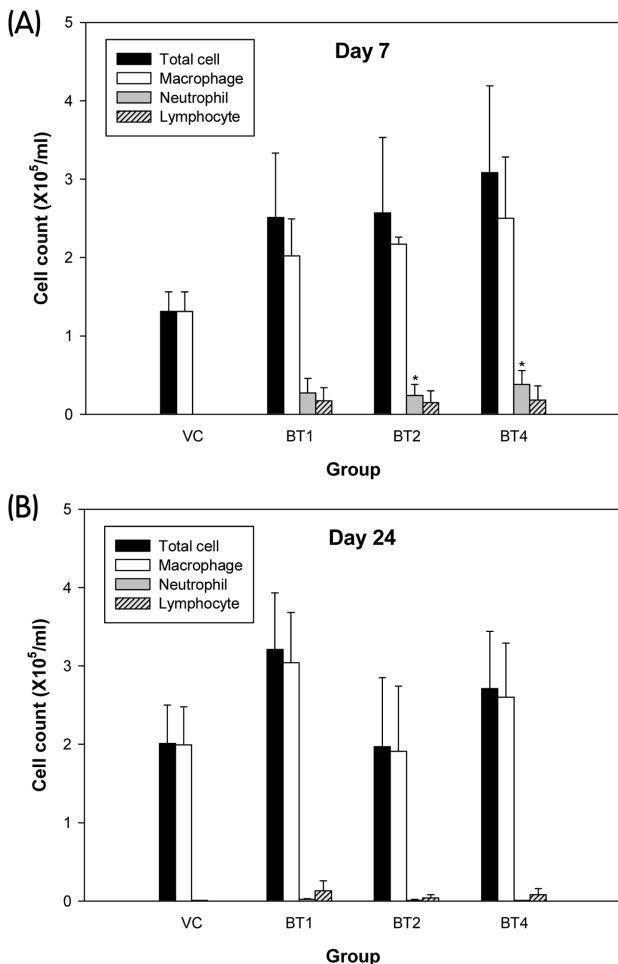


Fig. 2. Total and differential cell counts of bronchoalveolar lavage (BAL) fluid for each group at 7(A) and 24(B) days. VC: Vehicle control; BT1, BT2, BT4: bleomycin-treated 1, 2, and 4 mg/kg, respectively. * Significant difference at $p < 0.05$ level compared with vehicle control group.

signs or mortality. In the VC and BT groups, a moderately increased body weight was observed post-bleomycin instillation over the entire duration of the study with the exception of the BT4 group for the first week (Fig. 1). No significant differences were observed in the BT groups compared to the VC group and no significant differences were observed among the BT groups.

Inflammatory cell analysis. After 7 days of treatment, the BT groups exhibited increased numbers of total cells, neutrophils, and lymphocytes and a modest increase in the number of macrophages in BAL fluid compared to the VC group (Fig. 2A). The number of total cells and macrophages were increased in a dose-dependent manner in BT groups. However, neutrophils were only increased significantly in BT2 and BT4 groups. In contrast, on the 24th day after bleomycin instillation, the BT2 and BT4 groups showed a trend of decreased total cell and neutrophil number (Fig. 2B).

LDH level. The LDH activity in BAL fluid was increased in BT groups compared to the VC group 7 days post-instillation (Fig. 3). LDH levels in BT groups were increased in a dose-dependent manner. On the other hand, all BT groups exhibited markedly decreased LDH levels similar to the VC group 24 days after bleomycin instillation.

Histological evaluation. All BT groups markedly exhibited inflammatory cell infiltration, hypertrophy of peribronchial epithelial cells, and mucus secretion compared to the VC group 7 days after bleomycin instillation as observed in H&E stains (Fig. 4A~D). Collagen deposition, interstitial thickening, and granulomatous lesions were observed in the alveolar spaces in the BT groups in a dose-dependent

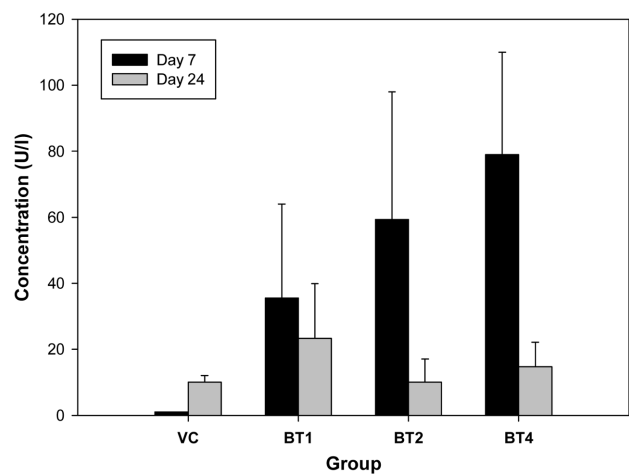


Fig. 3. Lactate dehydrogenase (LDH) level of BAL Fluid supernatant for each group at 7 and 24 days. VC: Vehicle control; BT1, BT2, BT4: bleomycin-treated 1, 2, and 4 mg/kg, respectively.

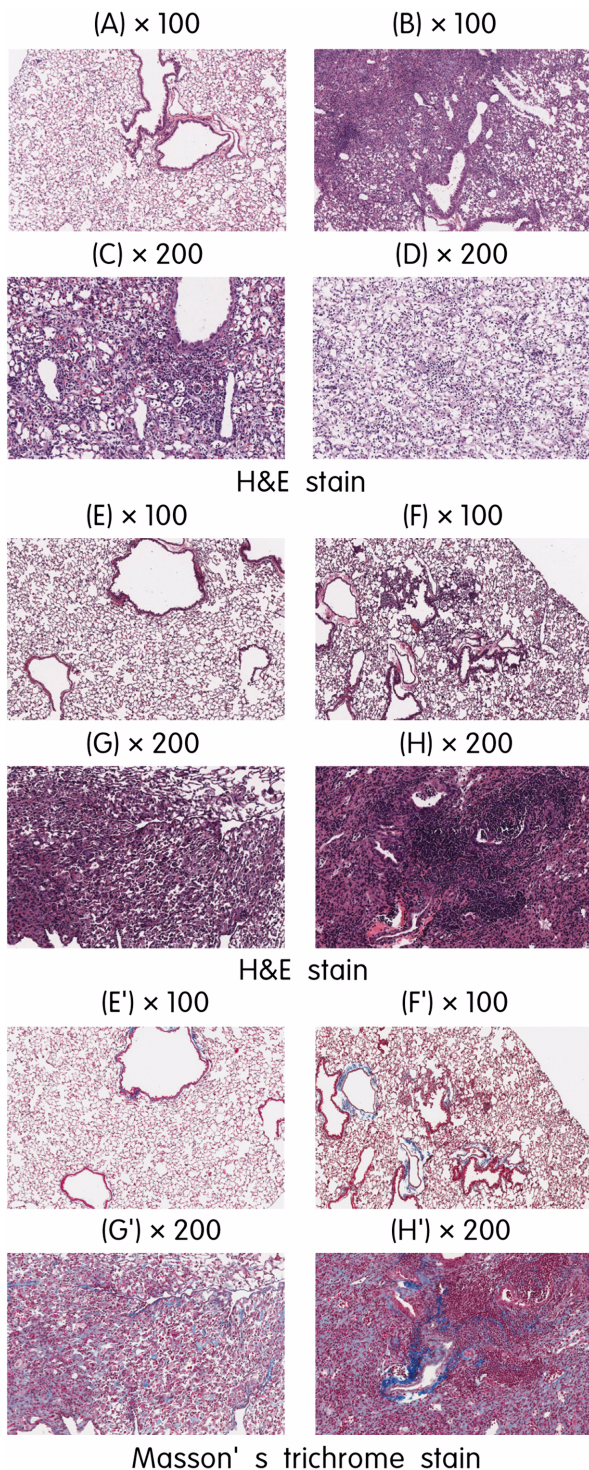


Fig. 4. Histological evaluation of lungs after bleomycin instillation (H & E, Masson's trichrome stain). Day 7 (A~D): VC (A); normal lung parenchyma from saline-treated mice, BT1 (B), BT2 (C), BT4 (D); interstitial thickening and marked inflammatory cell infiltration in alveolar septa. Day 24 (E~H, E'~H'): VC (E, E'); normal lung parenchyma from saline-treated mice. BT1 (F, F'), BT2 (G, G'), BT4 (H, H'); collagen formation, alveolar fibrosis/collapse, and decreased inflammatory cell infiltration in alveolar walls.

manner 24 days after treatment by H&E and Masson's trichrome stain (Fig. 4E~H, E'~H').

DISCUSSION

Pulmonary fibrosis induced by bleomycin has been studied physiologically, biochemically, histologically, and morphologically in various animals in an attempt to understand in more detail the pathogenesis and therapy of this disease (Hesterberg *et al.*, 1981). Moreover, a considerable amount of reviews of the bleomycin model and pulmonary research studies such as medical therapy and mechanism has been published. The availability of a well-established animal model for IPF therapy in humans is particularly important for successful development of antifibrotic drugs. Thereby, bleomycin has been widely used in rodents to model pulmonary fibrosis to study the mechanisms involved in fibrogenesis and to evaluate potential therapies. Bleomycin instillation directly into the lungs produces a more variable distribution of alveolar fibrotic foci compared to systemic administration such as intravenous (IV), intraperitoneal (IP), or subcutaneous (SC) and more closely mimics human pathology with areas of subpleural fibrosis (Walters *et al.*, 2008). Therefore, reviews of the pulmonary fibrosis model induced by bleomycin have been increasing in popularity (Mutsaers *et al.*, 2004; Moeller *et al.*, 2006; Moor and Hogaboam, 2008; Scriabine and Rabin, 2009). Until now, pulmonary fibrosis induced by bleomycin has been extensively studied biochemically, physiologically, and histologically. Using bleomycin instillation, the present study has confirmed a dose-response effect on the inflammatory and fibrotic phase by biochemical and histological analyses.

We chose to administer bleomycin intratracheally because previous studies (Gong *et al.*, 2005; Zhou *et al.*, 2007) showed that a single dose was sufficient to produce marked histological and biochemical changes in most rodents within 1~4 weeks. In contrast, if test materials such as bleomycin were given IP, IV, or SC, it was necessary to use a relatively high dose over several weeks or to use implanted osmotic mini-pumps over the entire duration of the study (Tom and Montgomery, 1980; Briggs *et al.*, 1985; Harrison and Lazo, 1987; Brown *et al.*, 1988). In present study, we used 3 consecutive levels of bleomycin to evaluate dose-response effects. Based on the safe dose reported by Mutsaers *et al.* (2004), we chose 4, and 1 mg/kg, as our high dose and low dose, respectively. We selected a third dose, 2 mg/kg, by scaling our dose by a factor 2 (Hesterberg *et al.*, 1981). These 3 consecutive levels of bleomycin were used to investigate the severity and dose-response effects of bleomycin on inflammation and pulmonary fibrosis for 1~4 weeks in male mice. The results clearly indicated that a consecutive single dose of bleomycin instillation in the lungs of male mice increased inflammatory cell count in BAL fluid and collagen deposition by fibroblasts in lung tissue, sug-

gesting severe pulmonary fibrosis.

In the present study, our results confirmed dose-response effects in most assays post-bleomycin instillation. No treatment-related effects on clinical signs, mortality, and body weight changes were observed in any of the BT groups compared to the VC group. These results were expected since a safe dose range of bleomycin has been reported in the scientific literature (Mutsaers *et al.*, 2004). Although body weights did not indicate a dose-response effect between VC and BT groups, inflammatory cell profiles, LDH activity, and histological changes showed similar dose dependent effects. Post-bleomycin instillation, the only clinical sign that we observed was moderately irregular respiration and this sign was transient. Overall, we did not observe changes in mortality or clinical signs from bleomycin or from the procedure of direct injection into the lungs. Both VC and BT groups showed moderate increases in body weight over the duration of the study but no significant differences were observed between VC and BT groups. It was thought that a moderate increase or decrease of body weight for the first week post-bleomycin instillation compared to VC group and their changes similarly returned to normal level in all BT groups. The inflammatory response is the initial response following injury and fibrosis is commonly the final outcome of the inflammatory process in the lungs (Gong *et al.*, 2005; Oku *et al.*, 2008; Ou *et al.*, 2009). We found that the inflammatory cell profiles {macrophages, PMNs (polymorphonuclear neutrophils), and lymphocytes} showed maximum effects at 1 week post-bleomycin instillation. Moreover, the LDH activity in BAL fluid, which represents an index of tissue injury or cell damage, also showed a dose-dependent increase. All BT groups showed a marked decrease of the fibrotic phase to levels similar to the VC group and a return to normal levels at 4 weeks, which is comparable to reports from Gong *et al.* (Gong *et al.*, 2005) and Ou *et al.* (Ou *et al.*, 2009). In addition, the lung damages are followed by an influx of inflammatory cells, which was characterized previously in rodents (Janick-Buckner *et al.*, 1989). The present study showed changes in the BAL cell population in ICR mice after bleomycin instillation. Lung damage induced by bleomycin was followed by a rapid influx of PMNs and lymphocytes into the lungs. Although the presence of PMNs in the lung was transient, lymphocytes remained in the lung during the fibrotic process. A similar observation was reported during the fibrotic process in rodents (Janick-Buckner *et al.*, 1989; Gong *et al.*, 2005). Surprisingly, at 24 days, the BT1 group showed increased numbers of activated macrophages and PMNs remained present in the lungs, which was in contrast to our observations in the BT2 and BT4 groups. We propose that the reason for this is a difference in bioavailability among individuals and dose not have toxicological significance.

Our data demonstrated that an influx of inflammatory cells into the lungs and a fibrotic process such as collagen

deposition occurred in a dose-dependent manner after bleomycin injury. Ou *et al.* (Ou *et al.*, 2009) reported that bleomycin administration induced fibrotic lesions and collagen deposition in mouse lungs after 28 days. Moreover, the histological data in the present study were consistent with histological changes reported by other researchers (Zhou *et al.*, 2007; Oku *et al.*, 2008). This involved the histological evidence of "fibrosis" namely collagen deposition by fibroblast, interstitial thickening, and granulomatous lesions observed in the alveolar spaces 4 weeks post-bleomycin instillation.

In conclusion, our results demonstrated that inflammatory cells and LDH levels in BAL fluid were increased at 7~10 days post-bleomycin instillation, which is known as the inflammatory phase, and they returned to normal levels at 24 days, which is regarded as the fibrotic phase. Moreover, both inflammatory cellular profiles and histological findings increased in a dose-dependent manner. In further studies, these results will be utilized as an experimental animal model and as basic data to evaluate therapeutic candidates via non-invasive monitoring with the pulmonary fibrosis mouse model established in this study.

ACKNOWLEDGMENTS

This research was supported by General Project grant from the Ministry of Knowledge and Economy through the International Inhalation Toxicology Evaluation Technology program to the Korea Institute of Toxicology.

REFERENCES

- Briggs, A.D., Chandler, D.B., Jackson, R.M. and Fulmer, J.D. (1985). The effect of endotoxin on bleomycin-induced lung fibrosis in the rat. *Toxicol. Lett.*, **27**, 91-96.
- Brown, R.F., Drawbaugh, R.B. and Marrs, T.C. (1988). An investigation of possible models for the production of progressive pulmonary fibrosis in the rat. The effects of repeated intratracheal instillation of bleomycin. *Toxicology*, **51**, 101-110.
- Chaudhary, N.I., Schnapp, A., and Park, J.E. (2006). Pharmacologic differentiation of inflammation and fibrosis in the rat bleomycin model. *Am. J. Respir. Crit. Care Med.*, **173**, 769-776
- Gong, L.K., Li, X.H., Wang, H., Zhang, L., Chen, F.P., Cai, Y., Qi, X.M., Liu, L.L., Liu, Y.Z., Wu, X.F., Huang, C.G. and Ren, J. (2005). Effect of Feitai on bleomycin-induced pulmonary fibrosis in rats. *J. Ethnopharmacol.*, **96**, 537-544.
- Harrison, J.H. and Lazo, J.S. (1987). High dose continuous infusion of bleomycin in mice: a new model for drug-induced pulmonary fibrosis. *J. Pharmacol. Exp. Ther.*, **243**, 1185-1194.
- Hesterberg, T.W., Gerriets, J.E., Reiser, K.M., Jackson, A.C., Cross, C.E. and Last, J.A. (1981). Bleomycin-induced pulmonary fibrosis: correlation of biochemical, physiological, and histological changes. *Toxicol. Appl. Pharmacol.* **60**, 360-367.
- Janick-Buckner, D., Ranges, G.E. and Hacker, M.P. (1989). Alteration of bronchoalveolar lavage cell populations following bleomycin treatment in mice. *Toxicol. Appl. Pharmacol.*, **100**, 465-473.

- Lazo, J.S., Hoyt, D.G., Sebt, S.M. and Pitt, B.R. (1990). Bleomycin: A pharmacologic tool in the study of the pathogenesis of interstitial pulmonary fibrosis. *Pharmacol. Ther.*, **47**, 347-358.
- Manoury, B., Nenau, S., Guenon, I., Lagente, V. and Boichot, E. (2007). Influence of early neutrophil depletion on MMPs/TIMP-1 balance in bleomycin-induced lung fibrosis. *Int. Immunopharmacol.*, **7**, 900-911.
- Moeller, A., Ask, K., Warburton, D., Gauldie, J. and Kolb, M. (2008). The bleomycin animal model: A useful tool to investigate treatment options for idiopathic pulmonary fibrosis? *Int. J. Biochem. Cell Biol.*, **40**, 362-382.
- Moeller, A., Rodriguez-Lecompte, J.C., Wang, L., Gauldie, J. and Korb, M. (2006). Models of pulmonary fibrosis. *J. Drug Discov. Today*, **3**, 243-249.
- Moor, B.B. and Hogaboam, C.M. (2008). *Am. J. Physiol. Lung Cell. Mol. Physiol.*, **294**, L152-L160.
- Mutsaers, S.E., McAnulty, R.J., Laurent, G.J. and Knight, D.A. (2004). Evaluation of experimental models of idiopathic pulmonary fibrosis. *Drug Discov. Today*, **1**, 329-336.
- Oku, H., Shimizu, T., Kawabata, T., Nagira, M., Hikita, I., Ueyama, A., Matsushima, S., Torii, M. and Arimura, A. (2008). Antifibrotic action of pirfenidone and prednisolone: Different effects on pulmonary cytokines and growth factors in bleomycin-induced murine pulmonary fibrosis. *Eur. J. Pharmacol.*, **590**, 400-408.
- Ou, X.M., Li, W.C., Liu, D.S., Li, Y.P., Wen, F.Q., Feng, Y.L., Zhang, S.F., Huang, X.Y., Wang, T., Wang, K., Wang, X. and Chen, L. (2009). VEGFR-2 antagonist SU5416 attenuates bleomycin-induced pulmonary fibrosis in mice. *Int. Immunopharmacol.*, **9**, 70-79.
- Scriabine, A. and Rabin, D.U. (2009). New developments in the therapy of pulmonary fibrosis. *Adv. Pharmacol.*, **57**, 419-464.
- Tom, W.M. and Montgomery, M.R. (1980). Biochemical and morphological assessments of bleomycin pulmonary toxicity in rats. *Toxicol. Appl. Pharmacol.*, **53**, 64-74.
- Walters, D.M., Cho, H.Y. and Kleeberger, S.R. (2008). Oxidative stress and antioxidants in the pathogenesis of pulmonary fibrosis: A potential role for Nrf2. *Antioxid. Redox Signal.*, **10**, 321-332.
- Wynn, T.A. (2007). Common and unique mechanisms regulate fibrosis in various fibroproliferative diseases. *J. Clin. Invest.*, **117**, 524-529.
- Zhou, X.M., Zhang, G.C., Li, J.X. and Hou, J. (2007). Inhibitory effects of Hu-qi-yin on the bleomycin-induced pulmonary fibrosis in rats. *J. Ethnopharmacol.*, **111**, 255-264.